

Treatment of Painful Nerves in the Abdominal Wall Using Processed Nerve Allografts

Andrew Bi, BS
Eugene Park, MD
Gregory A. Dumanian, MD

Summary: Neuromas can be a debilitating cause of pain and often negatively affect patients' quality of life. One effective method of treatment involves surgical resection of the painful neuroma and use of a processed nerve allograft to repair the injured nerve segment. Giving the nerve "somewhere to go and something to do" has been shown to effectively alleviate pain in upper and lower extremities. We present the first report of this concept to treat a painful neuroma of the abdominal wall that developed following a laparoscopic gastric bypass. The neuroma was excised, and the affected nerve was reconstructed using a processed nerve allograft as an interposition graft, with resolution of pain and gradual return of normal sensation. Patient-reported outcomes were measured using the Patient Reported Outcomes Measurement Information System. Neuroma excision with concurrent interposition grafting using processed nerve allografts may be a promising method of treatment for postsurgical painful neuromas of the trunk. (*Plast Reconstr Surg Glob Open* 2018;6:e1670; doi: 10.1097/GOX.0000000000001670; Published online 6 March 2018.)

INTRODUCTION

Painful neuromas can form following any surgery when nerves are injured due to cautery or traction. Nerve injury is categorized under Seddon's classification as neuropraxia, axonotmesis, or neurotmesis.¹ In both axonotmesis and neurotmesis, the distal nerve segment undergoes Wallerian degeneration and loses its glistening white appearance, becoming smaller and more fibrous. The proximal segment attempts to heal, sprouting axons to reinnervate the distal nerve segment or target organ. When regenerating axons fail to connect, a neuroma representing frustrated nerve regeneration forms.¹ This can occur after axonotmesis as a "neuroma-in-continuity," or as an end neuroma after neurotmesis.

Neuroma pain is notoriously difficult to treat, and there is no widely accepted gold standard of treatment. Described treatments include simple excision, hiding the painful nerve ending within muscle or bone, or perineural injection of chemical agents such as alcohol or corticosteroids.^{2,3} Simple neuroma excision has repeatedly been shown to be an inadequate treatment with poor pain relief

and unacceptable repeat surgical rates.² And while wrapping the distal point of a painful nerve postneuroma excision in muscle or bone has been proven to be better, it remains an inferior option to actually repairing the nerve with an autograft, the current "best" treatment.³ Injectable agents remain viable short-term option, but lack long-term efficacy and newer agents have only been studied in minute sample sizes.

Recently, interest in actually healing injured nerves to treat painful neuromas formed as an unexpected outcome of the targeted muscle reinnervation procedure—a surgery designed to improve the control of prosthetic devices in amputees.⁴ This concept that neuromas occur when axons are unable to reach a terminal nerve receptor led the senior author to routinely use neuroma excision followed by interposition grafting with processed nerve allografts as a treatment for neuroma pain in the lower extremity. In this report, we describe a case of painful neuroma, which formed in the abdominal wall of a postoperative gastric bypass patient, which was then treated successfully with the aforementioned technique.

CLINICAL REPORT

A 37-year-old woman with hypertension, diabetes, and a body mass index of 45.12 kg/m² underwent an uncomplicated laparoscopic Roux-en-Y gastric bypass at Northwestern Memorial Hospital. The patient was discharged home after 3 days, but returned 1 day later to the emergency department (ED) with significant left-sided abdominal

From the Division of Plastic Surgery, Northwestern University Feinberg School of Medicine, Chicago, Ill.

Received for publication August 6, 2017; accepted December 13, 2017.

Copyright © 2018 The Authors. Published by Wolters Kluwer Health, Inc. on behalf of The American Society of Plastic Surgeons. This is an open-access article distributed under the terms of the Creative Commons Attribution-Non Commercial-No Derivatives License 4.0 (CCBY-NC-ND), where it is permissible to download and share the work provided it is properly cited. The work cannot be changed in any way or used commercially without permission from the journal.

DOI: 10.1097/GOX.0000000000001670

Disclosure: The senior author has received compensation from the Axogen company on 2 occasions as a speaker. The Article Processing Charge was paid for by the authors.

pain unresponsive to hydrocodone. Following 1 night in the hospital and imaging that showed no evidence of intraabdominal complications, she was discharged home with tramadol.

Twenty-two days later, the patient once again presented to the emergency department with increasing left upper quadrant pain radiating to the umbilicus. She reported taking 2–4 tablets of hydrocodone every 4 hours without alleviation. The patient was admitted, and 4 days later the patient was transferred to inpatient psychiatry after endorsing depression secondary to her pain preventing everyday tasks, wishing that “someone could kill me and make this all end.” The patient was placed on duloxetine and pregabalin and gradually experienced improvement of her symptoms to permit discharge. The patient was also seen by plastic surgery where an abdominal wall neuroma was diagnosed based on point tenderness with radiating pain immediately under a laparoscopy incision scar, with some dysesthesias in the skin in the dermatome line. A diagnostic nerve block was not performed due to habitus.

Two months after discharge with continued pain only controlled with high dose narcotics, the patient was taken to the operating room for exploration of her persistent area of pain under general anesthesia, without muscle relaxation. The scar of the laparoscopy port site located 3 cm medial to the anterior border of the ribs was the center of the 6 cm incision. After dissecting down to the abdominal wall, the external oblique and internal oblique muscles were split along their fibers. Using a Checkpoint Nerve Stimulator (Checkpoint Surgical, Cleveland, Ohio), the intercostal nerve was identified traveling on the surface of the transversus abdominis muscle. A small segment of nerve immediately under the area of greatest tenderness was slightly smaller in diameter than the rest of the nerve, firm to touch, and mildly erythematous. A 2-cm segment of nerve encompassing the affected area was excised and was found to contain a neuroma on histology. A 2.5 cm long × 3 mm wide Avance (AxoGen, Alachua, Fla.) nerve allograft was used as an interposition graft to reconstruct the nerve (Fig. 1). The graft was secured in place using 7-0 polypropylene suture under loupe magnification. The procedure was completed in 43 minutes, and the patient was admitted for observation.

The patient immediately felt a change in the quality of her pain postoperatively. Nine days after surgery, she reported her pain to be much improved. By 5 weeks after surgery, the patient reported having “no pain.” The patient’s subjective report was accompanied by systematic pain ratings collected using the National Institutes of Health-developed Patient Reported Outcomes Measurement Information System (PROMIS) questionnaires for Pain Behavior and Pain Interference. The patient’s Pain Behavior and Pain Interference levels went from the 92nd and 87th percentile preoperatively (Fig. 2), respectively, from before her neuroma surgery, to the 94th and 42nd percentile postoperatively (Fig. 3). Finally, the patient was able to discontinue all duloxetine use less than 2 months following her surgery and any Norco, Oxycontin, and Dilaudid use within 7 months. She reported a

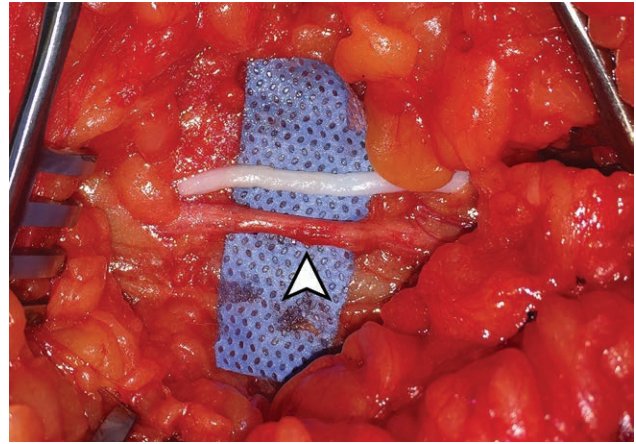


Fig. 1. Processed nerve allograft next to a segment of nerve to be excised. An erythematous portion of nerve containing a neuroma in continuity is seen (white arrow).

gradual return of sensation in the affected dermatome over time.

DISCUSSION

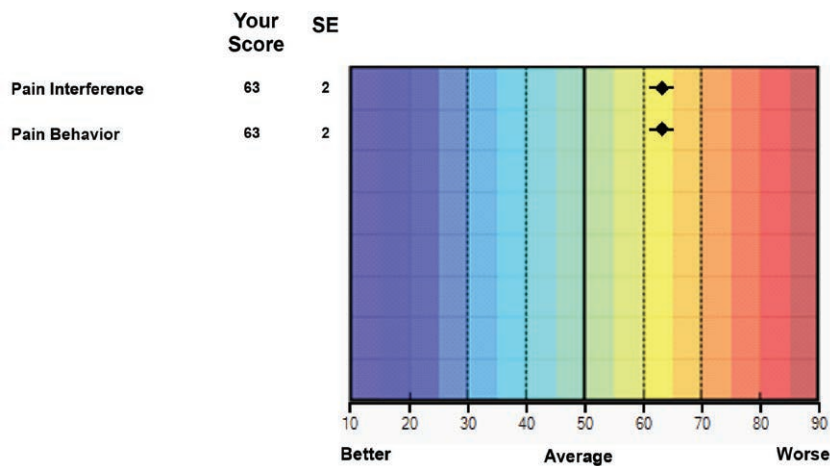
This case describes a promising technique for the treatment of neuroma-related pain, wherein a processed nerve allograft is used as an interposition graft after neuroma excision. Processed nerve allografts have been shown to be a safe and effective option for nerve reconstruction that provides functional recovery in nerve injuries with gaps up to 30 mm.⁵ The senior author has previously reported the successful use of this method in treating painful neuromas of the sural and superficial peroneal nerves.⁶ Here, we show that this technique effects a similar result in the abdominal wall, with resolution of neuroma pain and gradual return of normal sensation in the dermatome of the involved nerve.

Although the gold standard for nerve reconstruction is to use a nerve autograft, it may not make sense to harvest an intact nerve to repair a different painful nerve. Simple neuroma excision has repeatedly been associated with poor pain relief and need for secondary procedures.^{2,7} Although various treatments including the use of regenerative peripheral nerve interfaces decrease neuroma recurrence rates,^{2,8} these techniques do not have the potential for returning sensation. The use of an allograft spares the use of autogenous nerve, while providing the possibility for sensory recovery.

The patient’s subjective report of pain relief 1 month following her surgery is supported by results from her PROMIS pain interference assessments. PROMIS is a survey-based tool for evaluating various patient-reported outcomes, which derives normative values from a sample of 21,133 Americans.⁹ The patient experienced a dramatic improvement in pain interference, which refers to the degree which pain interferes with an individual’s overall activities.

The patient’s pain behavior, which measures how one’s behavior is affected by pain, remained high despite improvements in pain interference. Pain behavior scores vary significantly with levels of pain intensity and have been shown to

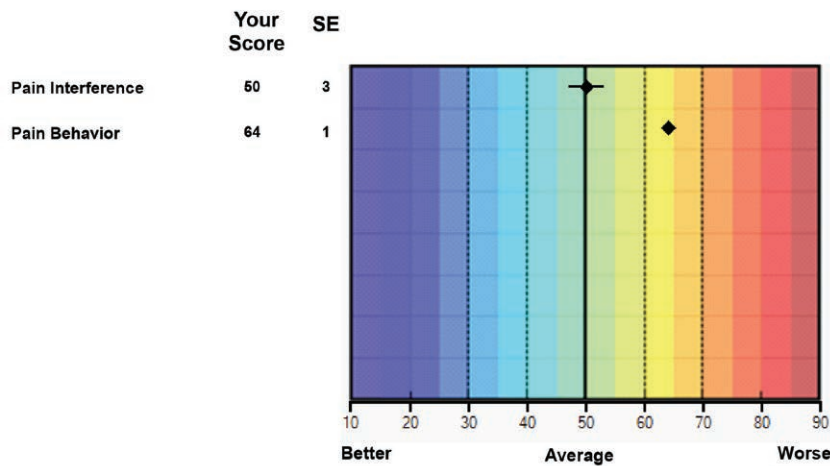
Your scores for the CATs you completed are shown below.



The diamond is your estimated score. For each of the areas above, a score of 50 is average for the United States general population. Most people will score between 40 and 60 and almost all people will score between 30 and 70. The Standard Error (SE) is a statistical measure of variance and represents a “margin of error” around your estimated score. The lines on either side of each diamond reflect the likely range of your actual score.

Fig. 2. The patient’s pain behavior and pain interference T-scores preoperatively were both 63, which represent the 92nd and 87th percentiles, respectively. CAT, computerized adaptive test.

Your scores for the CATs you completed are shown below.



The diamond is your estimated score. For each of the areas above, a score of 50 is average for the United States general population. Most people will score between 40 and 60 and almost all people will score between 30 and 70. The Standard Error (SE) is a statistical measure of variance and represents a “margin of error” around your estimated score. The lines on either side of each diamond reflect the likely range of your actual score.

Fig. 3. The patient’s pain behavior and pain interference T-scores postoperatively were 64 and 50, which represent the 94th and 42nd percentiles, respectively. CAT, computerized adaptive test.

decrease at a slower rate than mean pain interference scores following alleviation of pain intensity.¹⁰ In a study assessing changes in pain following abdominal wall reconstruction, our group has previously demonstrated this very phenomenon, with improvements in pain behavior lagging behind improvements in pain interference by about 4 months.¹⁰

Neuroma excision with interposition grafting using processed nerve allografts is an effective way to treat pain related to neuromas in all parts of the body. Further studies will be needed to demonstrate long-term resolution of pain and to compare this technique to other modalities of neuroma treatment.

Gregory A. Dumanian, MD

Division of Plastic Surgery
Northwestern University Feinberg School of Medicine
675 N. St. Clair St.
Suite 19–250
Chicago, IL 60611
E-mail: gdumania@nm.org

REFERENCES

1. Kaya Y, Sarikcioglu L. Sir Herbert Seddon (1903-1977) and his classification scheme for peripheral nerve injury. *Childs Nerv Syst.* 2015;31:177–180.
2. Guse DM, Moran SL. Outcomes of the surgical treatment of peripheral neuromas of the hand and forearm: a 25-year comparative outcome study. *Ann Plast Surg.* 2013;71:654–658.
3. Economides JM, DeFazio MV, Attinger CE, et al. Prevention of painful neuroma and phantom limb pain after transfemoral amputations through concomitant nerve coaptation and collagen nerve wrapping. *Neurosurgery.* 2016;79:508–513.
4. Cheesborough JE, Souza JM, Dumanian GA, et al. Targeted muscle reinnervation in the initial management of traumatic upper extremity amputation injury. *Hand (N Y).* 2014;9:253–257.
5. Brooks DN, Weber RV, Chao JD, et al. Processed nerve allografts for peripheral nerve reconstruction: a multicenter study of utilization and outcomes in sensory, mixed, and motor nerve reconstructions. *Microsurgery.* 2012;32:1–14.
6. Souza JM, Purnell CA, Cheesborough JE, et al. Successful treatment of foot and ankle neuroma pain with processed nerve allografts. *Foot Ankle Int.* 2016;37:1098–1105.
7. Pet MA, Ko JH, Friedly JL, et al. Traction neurectomy for treatment of painful residual limb neuroma in lower extremity amputees. *J Orthop Trauma.* 2015;29:e321–e325.
8. Woo SL, Kung TA, Brown DL, et al. Regenerative peripheral nerve interfaces for the treatment of postamputation neuroma pain: a pilot study. *Plast Reconstr Surg Glob Open.* 2016;4:e1038.
9. Cella D, Riley W, Stone A, et al; PROMIS Cooperative Group. The Patient-Reported Outcomes Measurement Information System (PROMIS) developed and tested its first wave of adult self-reported health outcome item banks: 2005-2008. *J Clin Epidemiol.* 2010;63:1179–1194.
10. Park E, Cheesborough JE, Souza JM, et al. Open repair of incisional ventral abdominal hernias with mesh leads to long-term improvement in pain interference as measured by patient-reported outcomes. *Am J Surg.* 2017;213:58–63.