

The Significance of MRI Evaluation of the Uterine Junctional Zone in the Early Diagnosis of Adenomyosis

Amela Sofic¹, Azra Husic-Selimovic², Aladin Carovac¹, Elma Jahic¹, Velda Smailbegovic³, and Jana Kupusovic²

¹Clinic of Radiology, University Clinical Center Sarajevo, Sarajevo, Bosnia and Herzegovina

²Institute of Gastroenterology and Hepatology, University Clinical Center Sarajevo, Sarajevo, Bosnia and Herzegovina

³Clinic of Oncology and Radiotherapy University Clinical Center Sarajevo, Sarajevo, Bosnia and Herzegovina

Corresponding author: Ass. prof. Amela Sofic, MD, PhD. ORCID ID: www.orcid.org/0000-0002-1577-1006. E-mail: amelasofic@yahoo.com

doi: 10.5455/aim.2016.24.103-106

ACTA INFORM MED. 2016 APR; 24(2):103-106

Received: FEB 03, 2016 • Accepted: MAR 15, 2016

© 2016 Amela Sofić, Azra Husić-Selimović, Aladin Čarovac, Elma Jahić, Velda Smailbegović, Jana Kupusović

This is an Open Access article distributed under the terms of the Creative Commons Attribution Non-Commercial License (<http://creativecommons.org/licenses/by-nc/4.0/>) which permits unrestricted non-commercial use, distribution, and reproduction in any medium, provided the original work is properly cited.

ABSTRACT

Goal: The aim of the study is to define the MRI appearance of disorder in the Junctional zone (JZ) in women with adenomyosis compared to those without it, given the importance of the JZ in the regulation of various reproductive events. **Materials and methods:** This was a prospective, comparative and open study. Patients with adenomyosis have been sorted in target group, n = 82, while the control group consisted of patients without adenomyosis, n = 82. All patients, from both groups have undergone a magnetic resonance imaging of the pelvis. Using a software tool for measurement, the thickness of the JZ was measured in T2w sag sequences in all patients from both groups (target and control) n = 164. Patients in the target group type adenomyosis were assessed and categorized either as: diffuse, focal, or Adenomyoma and the results were compared. The presence of endometriosis and myomas in both groups was evaluated and its coexistence with adenomyosis was analyzed as well. **Results:** Of the 82 patients in the target group, 81.7% of the patients had diffuse adenomyosis, while 18.3% had focal type with statistically significant difference (p < 0.05). The results of the Mann-Whitney U test showed that p < 0.05, implying that there is a statistically significant difference in the thickness of the JZ between the control and target group, therefore patients from the target group with adenomyosis had a statistically significantly thicker junctional zone than the patients in the control group. The JZ in the target group was on average M = 14,3mm, SD = 1.3mm, while the thickness of JZ in the control group without adenomyosis was M = 5,6mm, SD = 1,3. Chi-square shows that p < 0.05, implying that there is a statistically significant difference in the number of patients with myomas between the two groups, where the myomas significantly over-represented in the target group with 32,9 % vs.6 %). **Conclusion:** MRI is the method of choice for imaging and evaluation of JZ as an important diagnostic marker in the diagnosis of adenomyosis. It is important to recognize this condition as early as possible and distinguish it from other pathologies in order for timely and appropriate treatment.

Key words: Junctional zone, Adenomyosis, MRI.

1. INTRODUCTION

Adenomyosis is a gynecological disorder characterized by a benign invasion of ectopic endometrium tissue within the wall of the uterus with the adjacent smooth muscle hyperplasia (1, 2). The etiology is unclear, but as risk factors, in addition to hereditary ones, include uterine trauma during the delivery or abortion, chronic endometritis and hyperestrogenemia. In 1860, Carl von Rokitansky was the first to clearly define adenomyosis as an invasion of endometrium glands in the myometrium (3). In the past, the term Adenomyoma described a pathological entity of broader meaning used for both endometriosis and adenomyosis. Today, adenomyoma refers to a well

defined adenomyosis lesion, localized in the wall of the uterus that can mimic myoma. The Junctional zone (JZ) is a hormone dependent zone located between the endometrium and myometrium passing through cyclical changes in its thickness. In adenomyosis, the junctional zone is significantly thicker, passing over its hallmark- 12 mm (4). In the non-pregnant uterus, contractions commence exclusively from the junctional zone and participate in the regulation of various reproductive events, such as menstrual shedding, transport of the sperm and embryos. Therefore, in addition to the chronic pain, menorrhagia and dysmenorrhea, adenomyosis may be the reason for infertility (5, 6).

2. GOAL

The aim of the study is to define the MRI appearance of disorder in the Junctional zone (JZ) in women with adenomyosis compared to those without it, given the importance of the Junctional zone in the regulation of various reproductive events.

3. MATERIALS AND METHODS

During the period from January 2012 to January 2016 in University Clinical Center (UCC) Sarajevo n = 972 of MRI of the female pelvis were performed, where in n = 82 (8%) cases adenomyosis was found. Patients with adenomyosis have been sorted in target group n = 82. While the control group consisted of patients without adenomyosis n = 82. Patients from both groups (target and control) n = 164 were about the same age – around their perimenopause. The average age of the respondents was M = 44, SD = 6.4 in the target group, and in the control M = 44.2, SD = 4,1.

This was a prospective, comparative and open study. All patients, from both groups have undergone a magnetic resonance imaging of the pelvis, following the same protocol, using the same apparatus 1.5T Siemens (Germany) and 1.5 T GE (USA) manufacturer.

The protocol has had the following sequences: T1f3d cor fsFOV400, slice thickness 2 mm, TR 25.3 ms, PE 1.2 mls voxelsize, 1.7 x 1.6 x 2 mm, T2 trufi 3d cor FOV 450, slth1 mm TR 9.4 AND 1.8 voxelsize 1.6 x 1.4x 1, T2 tsesag FOV 280 slth4mmm TR 3700, TE 101 voxel size 0.7 x 0.7 x 4, Afterwards T2tse Apr FOV 210, slth 4 mm TR 3730, TET2 tse tse cor sag T2 T2 tse tra101 voxelsize 0.8 x 0.8 x 4th T2 cor FOV 300slth 4 mm, TR 5230 These 99 voxelsize 0.7 x0.7 x 4th Vibe T1 fs tra FOV 450 TR 4.99, TE2.61, slth 2.5 mm voxelsize 2.7 x 1.8 x 2.5T1 tsetra Fov210, slth4mm, TR 666, TE10, voxelsize 0.8 x 0.8 x 4th

To all patients from both groups (target and control) n = 164, the thickness of the JZ was measured in T2w sag sequences, using a software tool for measurement. The JZ thickness of the target and control group was compared.

The patients in the target group type adenomyosis were assessed and categorized either as: diffuse, focal, or Adenomyoma and the results were compared.

The presence of endometriosis and myomas in both groups was evaluated and its coexistence with adenomyosis was analyzed as well.

4. RESULTS

Of the 82 patients in the experimental group, 81.7% of the patients had diffuse adenomyosis, while 18.3% had focal type with statistically significant difference (p <0.05). Adenomyoma was found in 2.4% of patients. Using Chi-square test the statistical difference was obtained (p <.05) , meaning that there is a significantly higher number of patients who did not have Adenomyoma in comparison to the number of patients who had it.

The statistical testing has found that there is a statistically significant difference in the thickness of the junctional zone between the target and control group. The Junctional zone in the target group was on average M = 14,3mm, SD = 1.3mm, while the thickness of JZ in the control group without adenomyosis was M = 5,6mm, SD = 1,3. (Table 1). Since the

results are not normally distributed, nonparametric statistics was used for analyzing. The Mann-Whitney U test was used as a non-parametric test verifying the existence of statistical significance between the two groups.

	Junctional zone (mm)				
	Mean	Standard Deviation	Minimum	Maximum	
Group	Experimental	13.3	1.3	11.3	17.0
	Control	7.6	1.3	5.6	11.6
	Total	10.5	3.2	5.6	17.0

Table 1. Difference in the thickness of Junctional zone in the target and control group

The results of the Mann-Whitney U test showed that p <0.05, implying that there is a statistically significant difference in the thickness of the junctional zone (JZ) between the control and target group, therefore patients from the target group with adenomyosis had a statistically significantly thicker junctional zone than the patients in the control group. When it comes to endometriosis, in the target group, it was coexistent with adenomyosis in 8.5% of patients, while in the control group endometriosis was present in 2.4% of patients. Using chi-square test, the obtained results show that there was no statistically significant difference in the number of patients with endometriosis between the target and control groups (.p>0.05) Presence of myoma was measured in both target and control group. In the experimental group 32.9% of patients had myomas, while in the control group, only 6% of patients had myomas (Figure 1). Chi-square shows that p <0.05, implying that there is a statistically significant difference in the number of patients with myomas between the two groups, where the myomas significantly over-represented in the target group with adenomyosis.

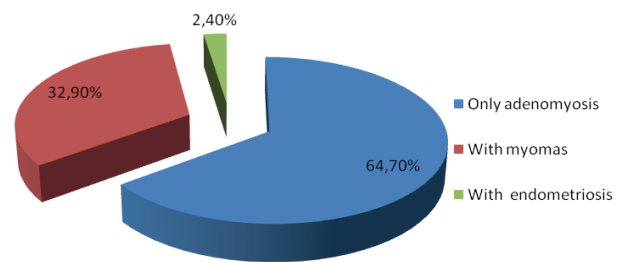


Figure 1. The presence of myomas and endometriosis with adenomyosis

5. DISCUSSION

Patients with adenomyosis have been proven to have excess levels of the hormone estrogen. The most common symptoms of adenomyosis are: chronic pelvic pain dysmenorrhea, menorrhagia, post menopausal bleeding, but these symptoms are not specific for making a clinical diagnosis. Therefore, diagnostically, imaging plays an important role in establishing an early diagnosis and prescribing an adequate therapy. In the past, adenomyosis was diagnosed primarily based on pathological evaluation of the tissue after a performed hysterectomy. Advent of high resolution diagnostic imaging modalities such as transvaginal sonography (TVS) and magnetic resonance (MRI) enabled the evaluation based on the specificity

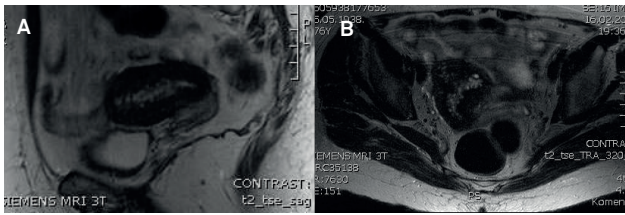


Figure 2. Diffuse type adenomyosis : a) MRI T2 w sag; b) T2w tra

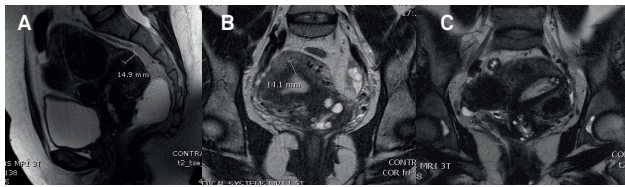


Figure 3 . MRI of adenomyosis with thickening of JZ and co-existence of myoma: a) T2w sag; b, c) T2 w cor

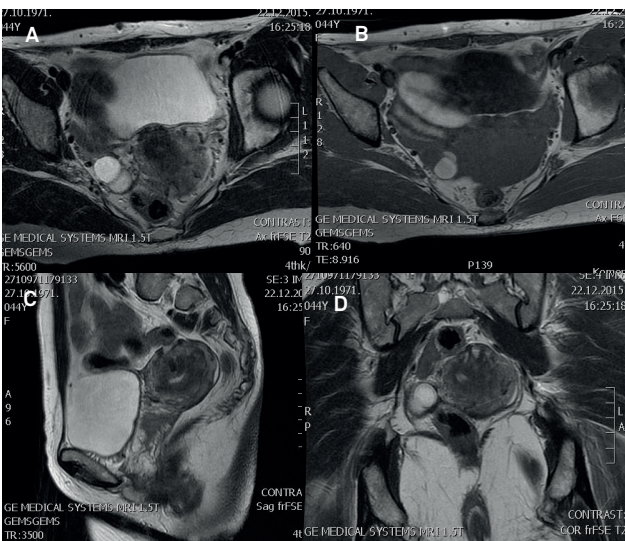


Figure 4. MRI Co-existence of endometriosis and adenomyosis of a right ovary: a) T2 w tra; b) T1 w tra c) T2 w sag; d) T2w cor

of the diagnostic image. Magnetic resonance imaging (MRI) is a non-invasive modality with a very accurate visualization of changes in adenomyosis and for differentiation of adenomyosis from other gynecological disorders. On the basis of these two modalities it is possible to distinguish three types of adenomyosis: a) diffuse adenomyosis; b) focal adenomyosis and adenomyoma (some consider them as two separate identities) and c) cystic adenomyosis. Endometrium cysts placed in the myometrium are almost specific to adolescents and young women, while cystic Adenomyoma has also been proven in the juvenile period (7, 8, 9).

In adenomyosis, it is possible for certain parts of the uterine walls to be enlarged, typically the back wall, but since the cervix remains intact, the overall contour of the uterus stays preserved.

Transabdominal ultrasound does not provide a reliable diagnosis of adenomyosis and sometimes, due to the limited spatial resolution, it does not differentiate adenomyosis from leiomyomas. TVS, which is of a higher frequency, has a better spatial resolution, but there are limitations in the characterization of tissue. Hysterosalpingogram (HSG) can show the diverticulum in the wall of the uterus. CT can point to adenomyosis, due to the local enlargement of the uterus, but there is a difficulty in distinguishing adenomyosis from myomas.

MRI diagnoses adenomyosis with a high degree of precision in which there is a close correlation between an MRI image with histopathological characteristics (10). MRI has a high diagnostic accuracy with a sensitivity of 78-88% and a specificity of 67-93% (11). MRI, especially using T2 weighted images, is good at visualization of all the different layers of the wall of the uterus including the junctional zone, which is in adenomyosis thicker than 12 mm. In general, the thickness of the junctional zone over 12 mm is in favor of adenomyosis, while a thickness of less than 8 mm generally allows the exclusion of this disease. Changes in the thickness and appearance of JZ affect its function and symptoms of adenomyosis.

Adenomyosis appears as diffuse or focal thickening of the junctional zone on the poorly-defined area of low signal intensity, sometimes with visible bright spots in hypersignal on T2-weighted images. Histologically, areas of low signal intensity correspond to smooth muscle hyperplasia, while bright foci on T2-weighted images correspond to the islands of ectopic endometrium tissue and cystic dilatation of glands. During menstrual bleeding within the ectopic endometrium tissue, the signal intensity on T1 images can become considerably high. Even without bleeding or treatment, the appearance of adenomyosis and the intensity of hypersignal of ectopic endometrium glands may fluctuate. There is no consistent parameter of endometrium penetration depth required for the diagnosis of adenomyosis. Most authors use the depth of penetration of the endometrium between 1-4 mm (12). In most cases, endometrium glands lie substantially within the myometrium deeper than half the width or equivalent to 2.5 mm or one quarter of the JZ and are not hormone-dependent as opposed to endometriosis (13). In this study, the average thickness of the JZ in the group of patients with adenomyosis was 14,7mm (12,3-16mm), with a statistically significant difference compared to those in the control group without adenomyosis, where the average thickness of JZ was 5.6 mm (3,4-7mm). 81.7% of the patients had diffuse adenomyosis (Figure 2), while 18.3% had a focal adenomyosis. In the study of Jae Young Byun an average thickness of JZ in adenomyosis was 16mm, with 66.7% of cases had a diffuse adenomyosis and 15% a focal adenomyosis (14). It is important to know that the focal thickening of the junctional zone suggests an adenomyosis, while a diffuse thickening may be physiological or hyperplastic, and needs to be discerned from one another. The presence of bright focus on T2 or T1 image supports a diagnosis of adenomyosis. The diagnosis of adenomyosis is to be placed carefully, perhaps avoiding the menstrual phase due to variations in the thickness of the junctional zone.

Kunz, in his study of 160 women with endometriosis got prevalence of adenomyosis in 79% (15). In our study no statistically significant coexistence of adenomyosis was confirmed with endometriosis (8.5%) but a statistically significant co-existence with myomas was confirmed (32.9%) (Figure 3 and 4). In the extensive research done in Tübingen, adenomyosis was histologically diagnosed in 8% of cases (149 women from 1955 women), while 70% of women diagnosed with adenomyosis were premenopausal (16). In our study adenomyosis was also diagnosed in 8% of cases (82 women out of 972 women). In our study, the average age of the experimental group with adenomyosis was 44 years, whereas in the Taran study, the average age was 41.1 years, which confirms the fact

that this pathological entity is most common in perimenopause (17). If there is a coexistence of adenomyosis with other pathological entities, its differentiation can be a problem. Endometrium hyperplasia and endometrium polyps that occur after treatment of breast cancer with Tamoxifen may mimic adenomyosis. Previously, pseudolesions due to uterine contractions were mistaken with the thickening found in adenomyosis, which is now avoided by using the multi-phase single-shot fast spin-echo technique. Rarely does the adenocarcinoma arising from adenomyosis occur, which complicates the evaluation, but due to good tissue characterization and multiplanar view, MRI is the method of choice for diagnostic evaluation. Adenocarcinoma arising from adenomyosis should be distinguished from the more common scenario in which endometrium cancer spreads to parts affected with adenomyosis, but that is not always easy. In staging of endometrium cancer, myometrial invasion is an extremely important factor in predicting prognosis (18).

The treatment for adenomyosis depends on the symptoms, age, and patient wishes to maintain fertility. Medical therapy for adenomyosis include administration of hormones and analgesics. Conservative surgery includes endometrium ablation, laparoscopic myometrium electrocoagulation, and local excision of involved myometrium. Hysterectomy is still the most common treatment in severe cases, the embolization of uterine artery is of use. Due to the fact that many of these women want to keep their uterus, and some even want to have children, a very popular treatment method is adenomyomectomy where adenomyotic tissue is radically excised from the wall of the uterus (19, 20).

6. CONCLUSION

Previously present difficulties in diagnosing adenomyosis are certainly resolved today by the application of MRI, which is the method of choice for imaging and evaluation of the junctional zone as an important diagnostic marker in the diagnosis adenomyosis. Given the symptoms and difficulties in the treatment of adenomyosis, it is important to recognize this condition as early as possible and distinguish it from other pathologies in order for a timely and appropriate treatment, while avoiding unnecessary interventions.

- Amela Sofic made substantial contribution to conception and design, final approval of the version to be published. Azra Husic-Selimovic made substantial contribution to conception and design, substantial contribution to acquisition of data, substantial contribution to analysis and interpretation of data, drafting the article. Aladin Carovac made substantial contribution to conception and design, substantial contribution to acquisition of data substantial contribution to analysis and interpretation of data, drafting the article. Elma Jahic made substantial contribution to acquisition of data substantial contribution to analysis and interpretation of data. Velda Smalibegovic made critically revising the article for important intellectual content. Jana Kupusovic made final approval of the version to be published.
- Conflict of interest: none declared.

REFERENCE

1. Byun JY, Kim SE, Choi BG, Ko GY, Jung SE, Choi KH. Diffuse and focal adenomyosis: MR imaging findings. *Radiographics*. 1999; 19: 161-70.

2. Atri M, Reinhold C, Mehio AR, Chapman WB, Bret PM. Adenomyosis: US features with histologic correlation in an in-vitro study. *Radiology*. 2000; 215: 783-90.
3. Benagiano G, Brosens I. Best History of adenomyosis. *Pract Res Clin Obstet Gynaecol*. 2006; 20(4): 449-63.
4. Gordts S, Brosens JJ, Fusi L. et al. Uterine adenomyosis: a need for uniform terminology and consensus classification. *Reprod Biomed Online*. 2008;17: 244-8.
5. Gordts S, Campo R, Brosens J. Hysteroscopic diagnosis and excision of myometrium cystic adenomyosis. *Gynecol Surg*. 2014; 11(4): 273-8.
6. Campo SI, Benagiano G. Infertility and Adenomyosis. *Obstetrics and Gynecology International*. 2012; Article ID 786132.
7. Brosens I, Gordts S, Habiba M, Benagiano GJ. Uterine Cystic Adenomyosis: A Disease of Younger Women. *Pediatr Adolesc Gynecol*. 2015; 28(6): 420-6.
8. Cucinella G, Billone V, Pitruzzella I, Lo Monte AI, Palumbo VD, Perino A.J Adenomyotic cyst in a 25-year-old woman: case report. *Minim Invasive Gynecol*. 2013; 20(6): 894-8.
9. Branquinho MM, Marques AL, Leite HB, Silva IS. Juvenile cystic adenomyoma. *BMJ Case Rep*. 2012; 9: 2012. pii: bcr2012007006.
10. Kuligowska E, Deeds L III, Lu K III. Pelvic pain: overlooked and underdiagnosed gynecologic conditions. *Radiographics*. 2005; 25: 3-20.
11. Tamai K, Togashi K, Ito T. et al. MR imaging findings of adenomyosis: correlation with histopathologic features and diagnostic pitfalls. *Radiographics*. 25(1): 21-40.
12. Bazot M, Darai E, Rouger J, Detchev R, Cortez A. et al. Limitations of transvaginal sonography for the diagnosis of adenomyosis, with histopathological correlation. *Ultrasound Obstet Gynecol*. 2002; 20: 605-11.
13. Graziano A, Lo Monte G, Piva I, Caserta M, Kerner B, Engl R, Marci R. Diagnostic findings in adenomyosis: a pictorial review on the major concerns. *European Review for Medical and Pharmacological Sciences*. 2015; 19: 1146-54.
14. Byun JY, Kim SE, Choi BG, Ko GY, Jung SE, Choi KH. *Radiographics: Diffuse and Focal Adenomyosis: MR Imaging Finding*. 1999; 19: 161-70.
15. Kunz G, Beil D, Huppert P, Noe M, Kissler S, Leyendecker G. Adenomyosis in endometriosis - prevalence and impact on fertility. Evidence from magnetic resonance imaging. *Hum Reprod*. 2005; 20(8): 2309-16.
16. Wallwiener M, Taran FA, Rothmund R. et al. Laparoscopic supracervical hysterectomy (LSH) versus total laparoscopic hysterectomy (TLH): an implementation study in 1,952 patients with an analysis of risk factors for conversion to laparotomy and complications, and of procedure-specific re-operations *Arch Gynecol Obstet*. 2013; 288(6): 1329-39.
17. Taran FA, Weaver AL, Coddington CC, Stewart EA. Understanding adenomyosis: a case control study. *Fertil Steril*. 2010; 94(4): 1223-8.
18. Gizzo S, Patrelli TS, Dall'asta A, DI Gangi S, Giordano G, Migliavacca C, Monica M, Merisio C, Nardelli GB, Quaranta M, Noventa M, Berretta R. Coexistence of adenomyosis and endometrioid endometrium cancer: Role in surgical guidance and prognosis estimation. *Oncol Lett*. 2016; 11(2): 1213-9.
19. Chudleigh P, Thilaganathan B, Chudleigh T. *Obstetric ultrasound, how, why and when*. Churchill Livingstone. 2004; ISBN:0443054711.
20. Osadac H, Silber S, Kakinuma T, Nagaishi M, Kato K. Kato O. Surgical procedure to conserve the uterus for future pregnancy in patients suffering from massive adenomyosis. *Reproductive Biomedicine Online*. 2011; 22(1): 94-9.