



Case Report

Multiple lessons learned from a single case: Complications from pineal germinoma management

Sultan Al-Saiari¹, Faisal A. Asiri¹, Ahmed A. Farag¹, Faisal Alghamdi², Essam Rezk¹, Khalid Al Orabi¹, Mohammad Ghazi Abdoh¹, Jameel Khalid Rasheedi¹, Rana Moshref¹

Departments of ¹Neurosurgery and ²Interventional Neuroradiology, King Abdullah Medical City, Makkah, Western Saudi Arabia.

E-mail: Sultan Al-Saiari - smontreal@gmail.com; Faisal A. Asiri - faisalnsurg@gmail.com; Ahmed A. Farag - ahmedns25j@gmail.com; Faisal Alghamdi - alghamdi.faisal@kamc.med.sa; Essam Rezk - es_moneer2000@yahoo.com; Khalid Al Orabi - khalidalorabi@hotmail.com; Mohammad Ghazi Abdoh - abdoh.m@kamc.med.sa; Jameel Khalid Rasheedi - rasheedi.j@kamc.med.sa; *Rana Moshref - ranahatem0987@gmail.com

*Corresponding author:

Rana Moshref,
Department of Neurosurgery,
King Abdullah Medical City,
Makkah, Western Saudi Arabia.
ranahatem0987@gmail.com

Received : 18 September 2021
Accepted : 30 December 2021
Published : 20 January 2022

DOI
10.25259/SNI_944_2021

Quick Response Code:



ABSTRACT

Background: Pineal tumors are uncommon tumors that affect <1% of adults, with 50% of them being germinomas. A combination of endoscopic third ventriculostomy (ETV) and tumor biopsy is usually used. Cerebral vasospasm in association with aneurysmal subarachnoid hemorrhage (aSAH) has been extensively studied. However, at least according to the research, this is not the case in intraventricular hemorrhage (IVH) cases. We present a case with two distinct findings: (1) an unexpected large IVH following the removal of an external ventricular drain (EVD) in a patient who had undergone ETV and tumor biopsy, resulting in severe clinical vasospasm and (2) incidental pineal region germinoma regression on follow-up magnetic resonance imaging (MRI) without any prior adjuvant chemoradiation to explain such regression.

Case Description: The authors describe an 18-year-old male patient who had a routine, uneventful combined ETV and tumor biopsy, as well as the placement of an EVD. Histopathological examination revealed germinoma. His postoperative course was complicated by IVH after EVD removal, which resulted in clinical vasospasm. Without any prior adjuvant chemoradiation, follow-up MRI of the brain revealed a significant reduction in the size of the germinoma as well as reconstitution of the patency of the previously obstructed aqueduct of Sylvius.

Conclusion: The take-home message from this case is that in the case of postoperative clinical deterioration in a patient with concurrent IVH and ETV, a high index of suspicion for vasospasm is required, as this may allow a significant amount of blood to pass down to the basal cisterns. Early detection and management of clinical vasospasm are critical for a better neurological outcome. Furthermore, unexpected tumor size changes can occur due to a variety of factors, so recent preoperative MRI of the brain should be obtained in the lead-up to surgery, and postoperative computed tomography should be used sparingly to avoid radiation-related tumor changes.

Keywords: Endoscopic third ventriculostomy, External ventricular drain, Germinoma, Hydrocephalus, Intraventricular hemorrhage, Vasospasm

INTRODUCTION

Pineal tumors are uncommon tumors that affect 1% of adults, with germinoma accounting for up to half of all cases. They cause symptoms of increased intracranial pressure due to obstructive hydrocephalus, as well as endocrine abnormalities and parinaud syndrome.^[3]

Early treatment usually includes a combination of endoscopic third ventriculostomy (ETV) and, if possible, tumor biopsy to relieve the associated hydrocephalus and obtain a tissue diagnosis.

This is an open-access article distributed under the terms of the Creative Commons Attribution-Non Commercial-Share Alike 4.0 License, which allows others to remix, transform, and build upon the work non-commercially, as long as the author is credited and the new creations are licensed under the identical terms.

©2022 Published by Scientific Scholar on behalf of Surgical Neurology International

An external ventricular drain (EVD) is usually placed at the end of the procedure as a precautionary measure.^[15] Complications of EVDs include bleeding (0–40%), catheter misplacement (30%), and infection (30%).^[6] The risk of hemorrhage is increased not only by multiple attempts at ventricular catheter insertion and low platelets but it can also occur after the EVD is removed, a finding is common in clinical practice but underreported in the literature.^[13]

Cerebral vasospasm is a clinical entity that can occur anywhere from the third to the 21st day after aneurysmal subarachnoid hemorrhage (aSAH). It can cause severe ischemic brain injury, significant morbidity, and a poor outcome if not detected early.^[10] Cerebral vasospasm is related to the amount of blood or its products present in the subarachnoid space near large cerebral vessels.^[2,4]

We present the management of a case of pineal region germinoma that included two unusual events: an unexpected large intraventricular hemorrhage (IVH) following EVD removal in a patient who underwent a successful ETV, resulting in a debilitating clinical vasospasm, and a later significant regression in the size of the pineal region germinoma with no adjuvant chemoradiation given during the patient's hospital stay.

CASE PRESENTATION

We present the case of an 18-year-old male patient who presented to our emergency department after experiencing progressive headaches for 10 days. The headache was associated with nausea, vomiting, and diplopia. He was conscious and alert at the time of his initial assessment, with a Glasgow Coma Score (GCS) of 15/15. He was ambulating normally but was ataxic on his right side. Fundoscopic examination revealed bilateral papilledema and impaired upward gaze, indicating parinaud syndrome. His laboratory results were within normal ranges. His magnetic resonance imaging (MRI) brain [Figure 1] revealed obstructive hydrocephalus caused by a pineal region mass. The patient underwent an uneventful ETV, tumor biopsy, and EVD insertion. The histopathological analysis was conclusive of germinoma.

His immediate postoperative noncontrast computed tomography (CT) of the brain [Figure 2] revealed only a trace amount of intraventricular blood in the occipital horns due to surgical biopsy. In our institution, immediate postoperative CT scans are routinely ordered following any cranial case to predict any early complications such as hematoma or brain edema and to assess catheter ventricular placement even in the absence of clinical indications or surgical complications.

From day 1 to day 7 of his ICU stay, the patient was given small dose prophylactic heparin to prevent venous thromboembolism. Our hospital requires all hospitalized surgical adult patients with limited mobility to be placed on

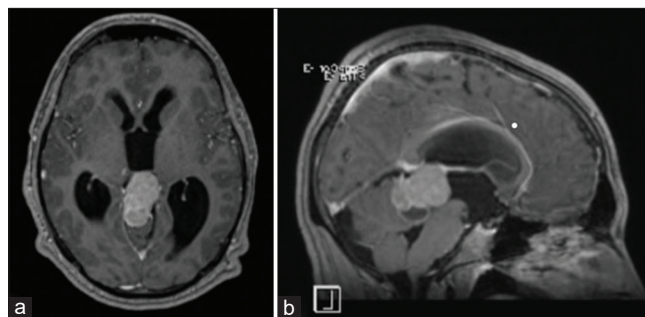


Figure 1: Preoperative axial (a) and sagittal (b) T1-weighted MRI images with contrast enhancement show pineal region mass (germinoma) with mass effect on the brainstem, cerebellum, and compression on the aqueduct of Sylvius causing hydrocephalus.

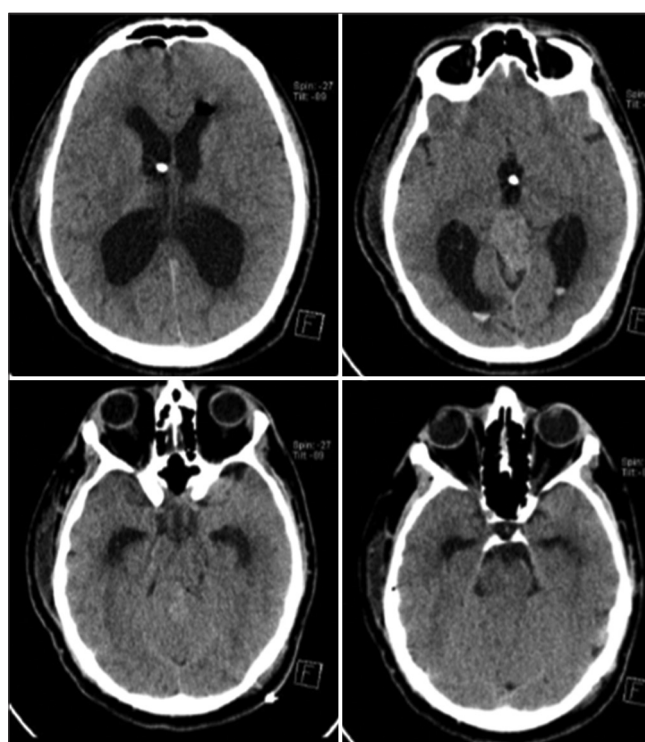


Figure 2: Noncontrast CT axial cuts performed day 1 after the ETV and tumor biopsy shows small expected IVH in the occipital horns bilaterally. The tip of the EVD is seen in the third ventricle, and the basal cisterns are free of blood. ETV: Endoscopic third ventriculostomy, EVD: External ventricular drain, IVH: Intraventricular hemorrhage.

thromboprophylaxis if no strong major contraindications are seen from prospective of the treating team's perspective.

This prophylactic heparin was stopped indefinitely shortly before the EVD was scheduled to be removed on day 7, and the patient was then free to ambulate. The first 7 postoperative days were uneventful; at the time of EVD removal, the cerebrospinal fluid (CSF) in the collecting EVD chamber was clear, with no blood to suggest an IVH.

On the 1st post-EVD removal day, the patient complained of generalized neck pain and headache. A repeated CT brain scan revealed a newly developed large IVH [Figure 3]. It was decided to replace the EVD and closely monitor patients in a neurointensive care unit. On day 17, despite the newly implanted EVD, the patient's GCS dropped from 15 to 13/15, with the development of the left gaze preference, aphasia, and right-sided weakness (Frankel Grade C). An MRI brain revealed diffuse ischemic changes that were more pronounced in the territories of the left anterior cerebral artery and middle cerebral artery [Figure 4]. Following cerebral angiography, it was discovered that there was a severely reduced caliber of bilateral supraclinoid ICA, more on the left than the right [Figure 5]. Vasospasm was determined to be the cause. In the angiography suite, the patient had blood pressure augmentation and chemical angioplasty with 2.5 mg of nimodipine administered intravenously. In addition, oral nimodipine was given for up to 3 weeks. The patient was in the neurointensive care unit for a total of 3 weeks.

In addition, a follow-up MRI brain performed during the patient's hospital stay also revealed an unexpected significant interval regression of the size of the germinoma. The Sylvius aqueduct's patency was spontaneously restored and confirmed by MRI CSF flowmetry [Figure 6]. During his total inpatient stay of about 10 weeks, the patient did not receive any adjuvant chemotherapy or radiotherapy to explain the regression in the size of the germinoma, this was due to his poor performance status following the ischemic insult. Three months after being discharged from hospital, the patient received adjuvant chemoradiation. After 1 year of follow-up, the patient remained Frankel C, with only minor improvements in speech but significant difficulty in word finding.

DISCUSSION

We present a case of a young adult with a pineal region germinoma who received standard treatment, including endoscopic biopsy, ETV, and EVD insertion, but whose course was complicated by IVH, perimesencephalic cistern bleeding, and a devastating ischemic stroke caused by severe bilateral supraclinoid vasospasm. It is uncommon for an isolated IVH to result a full-blown clinically delayed cerebral ischemia. Mensin *et al.* reviewed 208 papers describing the outcomes of perimesencephalic hemorrhage, radiographic vasospasm was seen in only 9% of them and none of them had clinical DCI.^[12] In contrast to vasospasm in aneurysmal SAH, which has a defined time frame of up to 3 weeks,^[8,21] vasospasm in an isolated IVH has not been well studied.^[8,21]

The incidence of vasospasm in IVH ranges from 5.6% to 37%.^[8,16] The age and volume of IVH both contribute to the development of vasospasm. It is postulated that younger adults seem more likely to develop vasospasm than the elderly,

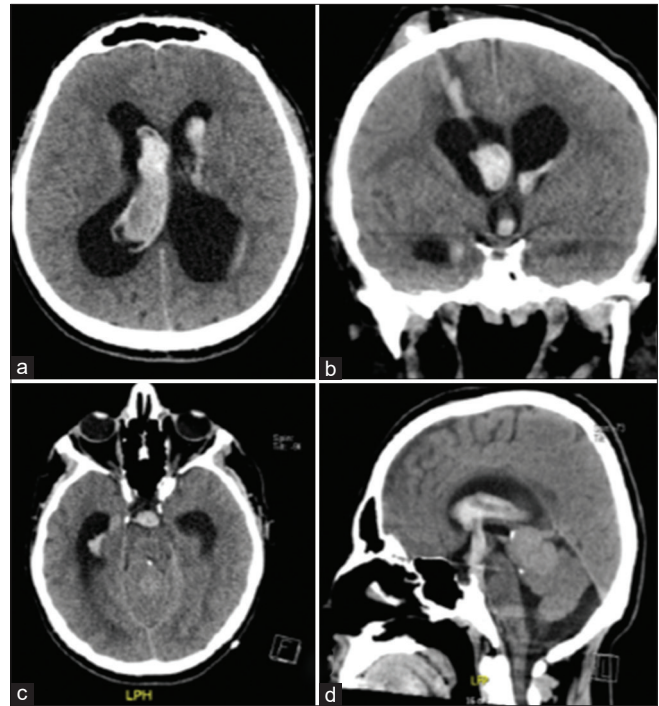


Figure 3: Noncontrast axial (a and c), coronal (b), and sagittal (d) CT cuts done day 1 post-EVD removal showing a large IVH. Blood is seen in the track of EVD and descending through the ventriculostomy ostium into the perimesencephalic cistern (b and d). EVD: External ventricular drain, IVH: Intraventricular hemorrhage.

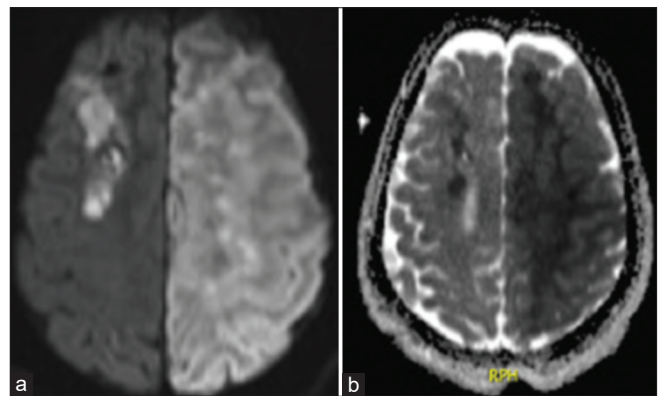


Figure 4: Diffusion-weighted image and apparent diffusion coefficient (a and b, respectively) showing the presence of the left restricted diffusion in ACA/MCA territory suggestive of ischemic stroke. ACA: Anterior cerebral artery, MCA: Middle cerebral artery.

due to their better vasoreactivity and less atherosclerosis.^[16] The mechanisms involved have not been fully elucidated. The normal physiological mechanisms and signaling molecules that regulate cerebral arterial diameter, however, are thought to be disrupted.^[1] A common hypothesis is that heme products were redistributed into subarachnoid space. This process takes time and may explain why patients with

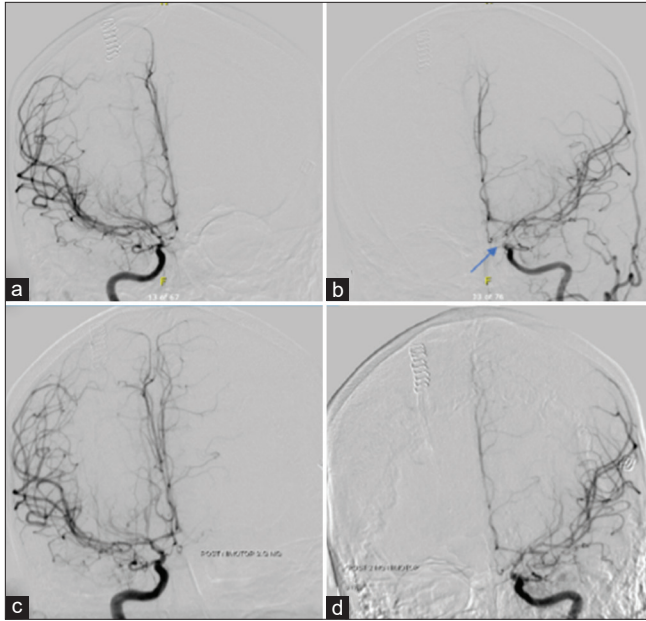


Figure 5: Catheter angiography of the right and left ICAs (a and b, respectively) shows proximal diffuse severe vasospasm bilaterally more on the left (blue arrow) than the right. Final cerebral angiography postnimodipine demonstrated significant angiographic improvement (c and d).

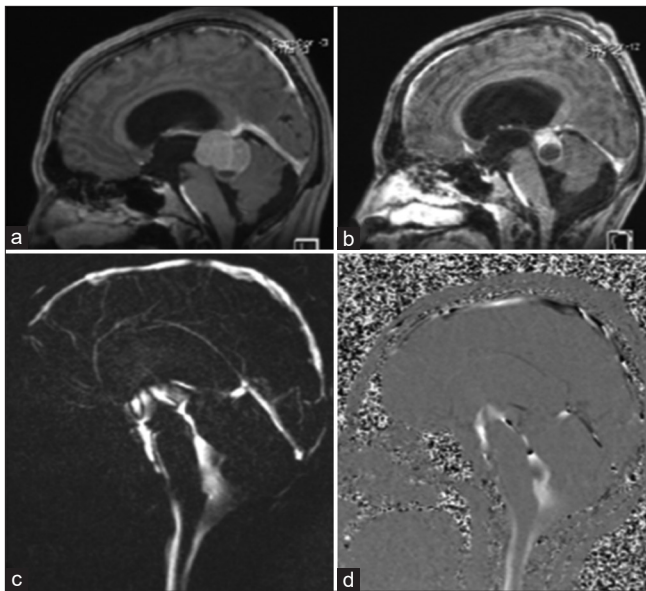


Figure 6: Sagittal T1-weighted images postgadolinium enhancement comparing preoperative (a) and postoperative (b) tumor sizes. Marked spontaneous reduction in the size of the germinoma can be seen; previously measured at 4 cm × 3.6 cm × 2.6 cm, and now measuring 2.9 cm × 2.7 cm × 2.1 cm at its maximum anteroposterior, craniocaudal, and transverse dimensions. Magnitude and phase images for CSF flow demonstrate reopening of the aqueduct of Sylvius and the presence of CSF flow in both the aqueduct and the surgically created third ventricular ostium (c and d). CSF: Cerebrospinal fluid.

IVH experience prolonged vasospasm.^[5,8,16] An imbalance in the production of nitric oxide and endothelin has been specifically implicated.^[18] Several case reports described vasospasm occurring in the setting of an isolated IVH caused by an arteriovenous malformation.^[9,11,12,14,19,22] However, our literature search did not yield any publications describing vasospasm related to an isolated IVH in the setting of ETV.

Large IVH after the removal of a temporarily EVD is extremely rare. We still do not have enough evidence to determine the cause of our patient's IVH. Our patient's coagulation profile was within normal limits. Heparin prophylaxis was stopped before the EVD was scheduled to be removed. There was no blood-tinged CSF in the EVD chamber, indicating intraventricular blood before EVD removal, and there was no resistance when it was removed. We agree Spennato *et al.* that the probable iatrogenic etiology of such bleeding was blood tracking along the path of catheter from the subgaleal space.^[20] As seen in our patient's CT brain, the catheter was adherent to the surrounding choroid plexus, ventricular walls, or brain parenchyma, with the epicenter of blood in the right lateral ventricle and a trace of blood seen along the track of the EVD. Gardner *et al.* examined 188 patients for IVH caused by EVD placement or removal. He studied 188 EVD-related hemorrhages. Thirty-seven (19.7% of all EVDs) were linked to larger hemorrhages, but none was related to EVD removal, indicating a low incidence of hemorrhages after EVD removal.^[7]

On the other hand, there was a significant reduction in the size of the germinoma seen on the patient's MRI, almost by half, in the absence of definitive treatment in the form of adjuvant chemotherapy or radiotherapy. Although spontaneous regression of intracranial germinoma is rare, it has been described in the literature. Schipmann *et al.* discovered spontaneous regression occurred in 13 cases of pineal region masses, six of which had CNS germinoma, in a review of the literature. Diagnostic radiation therapy, steroid treatment, apoplexy, surgical trauma, and immunological mechanisms were the most frequently mentioned possible causes.^[17] In our patients, we prefer diagnostic radiation as a plausible mechanism and, to a lesser extent, steroid use. During a 70-day period, our patient had multiple CT head images ($n = 19$) and one cerebral angiography, and he was on steroid treatment for a short perioperative course.

CONCLUSION

The take-home message from this case is that in the case of postoperative clinical deterioration of a patient with concurrent IVH and ETV, a high index of suspicion for vasospasm is required, as this may allow a significant amount of blood to pass down to the basal cisterns. Early detection and management of clinical vasospasm are important

predictors of a better neurological outcome. Furthermore, unexpected tumor size changes can occur due to variety factors; thus, recent preoperative MRI brain images should be obtained in the time leading up to surgery and postoperative CT should be used sparingly to avoid radiation-related tumor changes.

Acknowledgment

The authors would like to thank the patient and patient family for agreeing to publish the case report.

Declaration of patient consent

The authors certify that they have obtained all appropriate patient consent.

Financial support and sponsorship

Nil.

Conflicts of interest

There are no conflicts of interest.

REFERENCES

- Budohoski KP, Czosnyka M, Smielewski P, Kasprówicz M, Helmy A, Bulters D, *et al.* Impairment of cerebral autoregulation predicts delayed cerebral ischemia after subarachnoid hemorrhage: A prospective observational study. *Stroke* 2012;43:3230-7.
- Ciurea AV, Palade C, Voinescu D, Nica DA. Subarachnoid hemorrhage and cerebral vasospasm-literature review. *J Med Life* 2013;6:120-5.
- Favero G, Bonomini F, Rezzani R. Pineal gland tumors: A review. *Cancers (Basel)* 2021;13:1547.
- Fisher CM, Kistler JP, Davis JM. Relation of cerebral vasospasm to subarachnoid hemorrhage visualized by computerized tomographic scanning. *Neurosurgery* 1980;6:1-9.
- Fluss R, Laarakker A, Nakhla J, Brook A, Altschul DJ. Prolonged delayed vasospasm in the setting of nonaneurysmal intraventricular hemorrhage. *Surg Neurol Int* 2019;10:29.
- Fried HI, Nathan BR, Rowe AS, Zabramski JM, Andaluz N, Bhimraj A, *et al.* The insertion and management of external ventricular drains: An evidence-based consensus statement: A statement for healthcare professionals from the neurocritical care society. *Neurocrit Care* 2016;24:61-81.
- Gardner PA, Engh J, Atteberry D, Moosy JJ. Hemorrhage rates after external ventricular drain placement. *J Neurosurg* 2009;110:1021-5.
- Kiphuth IC, Huttner HB, Breuer L, Engelhorn T, Schwab S, Köhrmann M. Vasospasm in intracerebral hemorrhage with ventricular involvement: A prospective pilot transcranial Doppler sonography study. *Cerebrovasc Dis* 2011;32:420-5.
- Kobayashi M, Takayama H, Mihara B, Kawase T. Severe vasospasm caused by repeated intraventricular haemorrhage from small arteriovenous malformation. *Acta Neurochir (Wien)* 2002;144:405-6.
- Kothbauer K, Schroth G, Seiler RW, Do DD. Severe symptomatic vasospasm after rupture of an arteriovenous malformation. *AJNR Am J Neuroradiol* 1995;16:1073-5.
- Maeda K, Kurita H, Nakamura T, Usui M, Tsutsumi K, Morimoto T, *et al.* Occurrence of severe vasospasm following intraventricular hemorrhage from an arteriovenous malformation. Report of two cases. *J Neurosurg* 1997;87:436-9.
- Mensing LA, Vergouwen MD, Laban KG, Ruigrok YM, Velthuis BK, Algra A, *et al.* Perimesencephalic hemorrhage: A review of epidemiology, risk factors, presumed cause, clinical course, and outcome. *Stroke* 2018;49:1363-70.
- Miller C, Tummala RP. Risk factors for hemorrhage associated with external ventricular drain placement and removal. *J Neurosurg* 2017;126:289-97.
- Pendharkar AV, Guzman R, Dodd R, Cornfield D, Edwards MS. Successful treatment of severe cerebral vasospasm following hemorrhage of an arteriovenous malformation. Case report. *J Neurosurg Pediatr* 2009;4:266-9.
- Pople IK, Athanasiou TC, Sandeman DR, Coakham HB. The role of endoscopic biopsy and third ventriculostomy in the management of pineal region tumours. *Br J Neurosurg* 2001;15:305-11.
- Regula JU, Schill J, Ringleb PA, Sykora M. Cerebral vasospasm and delayed cerebral ischemia in intraventricular hemorrhage. *Neurocrit Care* 2014;20:460-5.
- Schipmann S, Keurhorst D, Köchling M, Schwake M, Heß K, Sundermann B, *et al.* Regression of pineal lesions: Spontaneous or iatrogenic? A case report and systematic literature review. *World Neurosurg* 2017;108:939-47.e1.
- Sobey CG, Faraci FM. Subarachnoid haemorrhage: What happens to the cerebral arteries? *Clin Exp Pharmacol Physiol* 1998;25:867-76.
- Spader HS, Doberstein CE, Rao AJ, Jayaraman MV. Central fever as an early predictor of vasospasm in a child with isolated intraventricular hemorrhage. *Clin Neurol Neurosurg* 2011;113:146-9.
- Spennato P, Mirone G, Aliberti F, Ruggiero C, di Martino G, Cinalli G. Intraventricular hemorrhage following removal of external ventricular drains: Report of 2 pediatric cases. *Interdiscip Neurosurg* 2019;16:15-7.
- Wilkins RH. Cerebral vasospasm. *Crit Rev Neurobiol* 1990;6:51-77.
- Yanaka K, Hyodo A, Tsuchida Y, Yoshii Y, Nose T. Symptomatic cerebral vasospasm after intraventricular hemorrhage from ruptured arteriovenous malformation. *Surg Neurol* 1992;38:63-7.

How to cite this article: Al-Saiari S, Asiri FA, Farag AA, Alghamdi F, Rezk E, Al Orabi K, *et al.* Multiple lessons learned from a single case: Complications from pineal germinoma management. *Surg Neurol Int* 2022;13:29.