

4H leukodystrophy

Mild clinical phenotype and comorbidity with multiple sclerosis

Stephanie M. DeGasperi, MSc, Geneviève Bernard, MD, Nicole I. Wolf, MD, PhD, Elka Miller, MD, and Daniela Pohl, MD, PhD

Correspondence

Dr. Pohl
dpohl@cheo.on.ca

Neurol Genet 2020;6:e409. doi:10.1212/NXG.0000000000000409

Hypomyelinating leukodystrophy with hypodontia and hypogonadotropic hypogonadism (4H leukodystrophy), also known as POLR3-related leukodystrophy, is a genetic disorder caused by autosomal recessive mutations in the *POLR3A*, *POLR3B*, *POLR1C*, or *POLR3K* genes.^{1–3} Most patients have progressive motor deficits.⁴ We present 2 siblings with a milder phenotype and lack of disease progression previously reported within a larger cohort of patients.⁵

Case presentation

Case 1

A 16-year-old previously healthy girl was referred to our neurology clinic with a 3-week history of numbness in her lower extremities, headaches, and blurred vision in her right eye. On examination, she had ataxic gait because of decreased sensation to touch in her lower extremities and hyperreflexia. MRI showed enhancement of the right optic nerve, diffuse symmetric signal abnormalities in the white matter of both cerebral hemispheres, and multiple spinal cord lesions (figure). The CSF analysis revealed oligoclonal bands. She was diagnosed with right optic neuritis and a hypomyelinating leukodystrophy.

She experienced 3 demyelinating relapses. The first occurred 1 month after her initial visit and presented as left optic neuritis. She was treated with monthly IV immunoglobulin for 18 months. At age 18 years, she experienced her second relapse with leg weakness and fatigue. MRI revealed new hyperintense lesions in brain areas and the spinal cord that were not present 7 months before (figure). Her care was transferred to adult neurology. She was diagnosed with multiple sclerosis (MS) and treatment with interferon- β -1a was initiated. Her third relapse, at age 21 years, again involved bilateral leg weakness. A repeat MRI showed no progression of her disease.

At age 21 years, genetic testing revealed that she was homozygous for the *POLR3B* pathogenic variant V523E, and she was diagnosed with 4H leukodystrophy. The patient continued to have no clinical symptoms of 4H leukodystrophy other than myopia. Her neurologic examination and cognition were normal. She reported suffering from some anxiety and depression.

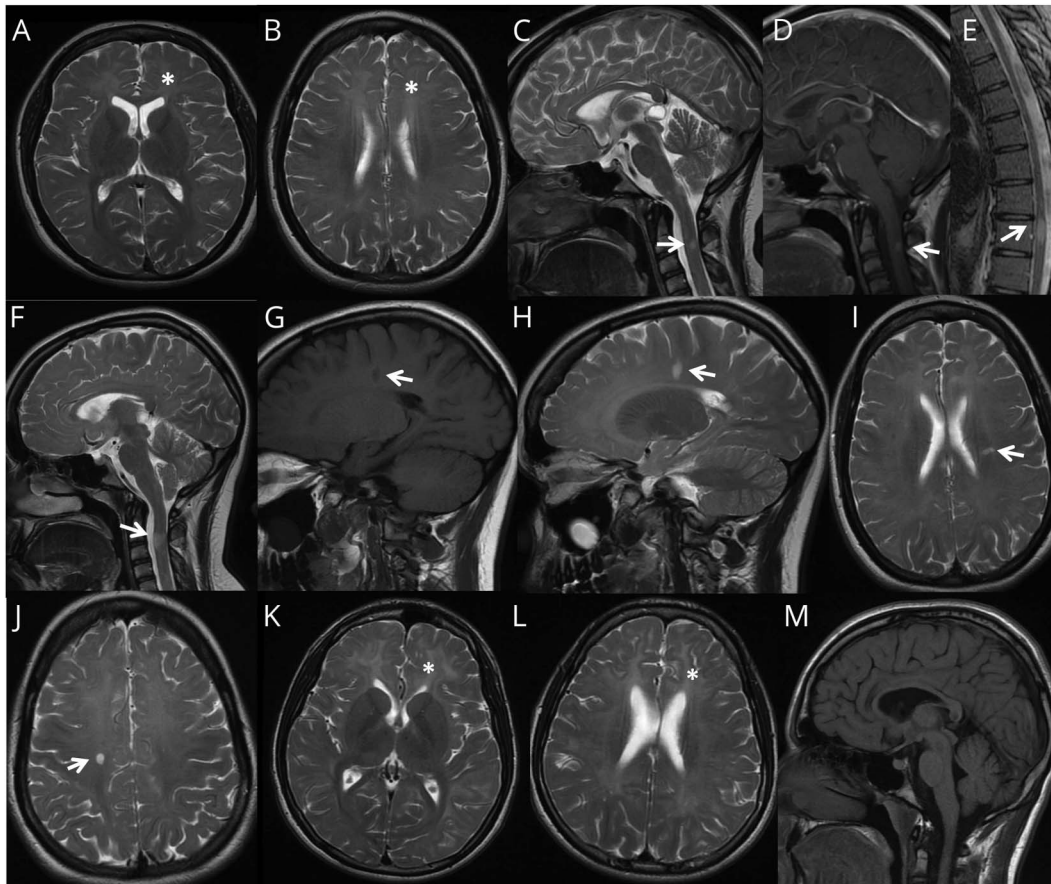
At the last clinical follow-up at age 26 years, she worked a full-time job. In view of her mood disorder, she had been switched to an immunomodulatory treatment with glatiramer acetate. She had not experienced any progression of her symptoms and had no additional MS relapses.

From the Faculty of Medicine (S.M.D., D.P.), University of Ottawa, ON, Canada; Departments of Neurology and Neurosurgery, Pediatrics and Human Genetics (G.B.), McGill University; Department Specialized Medicine (G.B.), Division of Medical Genetics, McGill University Health Center; Child Health and Human Development Program (G.B.), Research Institute of the McGill University Health Center; MyelinNeuroGene Laboratory (G.B.), Research Institute of the McGill University Health Center, Montreal, Quebec, Canada; Department of Pediatric Neurology (N.I.W.), Emma Children's Hospital, Amsterdam, Netherlands; Amsterdam Neuroscience (N.I.W.), Vrije Universiteit, Netherlands; and Department of Medical Imaging (E.M.) and Division of Neurology (D.P.), CHEO, University of Ottawa, ON, Canada.

Go to [Neurology.org/NG](https://www.neurology.org/NG) for full disclosures. Funding information is provided at the end of the article.

The Article Processing Charge was funded by the authors.

This is an open access article distributed under the terms of the Creative Commons Attribution-NonCommercial-NoDerivatives License 4.0 (CC BY-NC-ND), which permits downloading and sharing the work provided it is properly cited. The work cannot be changed in any way or used commercially without permission from the journal.



Patient 1 (A–J): MRI at 16 years of age (A–E). Axial T2 (A and B), sagittal T2 (C and E), and sagittal T1 with contrast (D). Images demonstrate T2 hyperintensity of the white matter in keeping with hypomyelination (* in A and B) with relative preservation of myelin in the anterior limb of the internal capsules, the corpus callosum, optic radiations (A), corticospinal tracts up to the apex (B). Demyelinating lesions within the spinal cord (C–E). MRI at 18 years of age (F–J). Sagittal T2 (F), sagittal T1 without contrast (G), sagittal T2 (H), and axial T2 (I and J). Enlargement of the spinal cord lesion (arrow in F). T1 hypointense and T2 hyperintense ovoid white matter lesion (arrows in G and H), along the path of the deep medullary vein (Dawson finger, arrows in H and I). Ovoid lesion of the right centrum semiovale (arrow in J). The corpus callosum is thin (F). Patient 2 (K–M): MRI at 16 years of age. Axial T2 (K and L) and sagittal T1 (M). Hypomyelination (* in K and L) and less residual myelin compared with patient 1, but more residual myelin than is typically seen in 4H leukodystrophy. No white matter lesions in the brain or spinal cord (M). The corpus callosum is thin (M).

Case 2

The younger brother of the first patient was referred to the neurology clinic at age 15 years after his first focal-to-bilateral tonic-clonic seizure. His medical history was unremarkable, apart from a learning disability diagnosed at age 11 years. His neurologic examination was normal with the exception of some stumbling on tandem gait testing and myopia. His EEG showed evidence of epileptiform discharges predominantly in the left posterior region and intermittently slow background activity.

At age 16 years, he had a second presumably bilateral tonic-clonic seizure (unwitnessed, parents found him postictal) and was administered carbamazepine. His MRI showed bilateral diffuse, symmetric signal changes in the white matter compatible with hypomyelination, thinning of the corpus callosum, and normal myelination of the spinal cord (figure).

At age 18 years, the diagnosis of 4H leukodystrophy was confirmed with genetic testing. The same V523E mutation as in

his sister was also found in his consanguineous parents who were heterozygous carriers. Both parents had short stature but were otherwise asymptomatic with normal dentition, endocrine, cognition and neurologic status. The MRIs of both parents were normal.

Repeat MRI of the patient 1 year after his first presentation was unchanged. He had no neurologic complaints. On examination, he had abnormal upgaze saccades, hyperreflexia in the lower extremities (3+), and mild dysmetria with heel-to-shin testing.

On his last follow-up, the patient was 23 years old. He had remained seizure free on carbamazepine for 5 years and did not have new neurologic deficits.

Discussion

The patients discussed have atypical presentations of 4H leukodystrophy. Most reported patients with 4H

leukodystrophy have progressive neurologic deficits, with or without dental abnormalities, endocrine problems, and/or myopia.^{2,5,6} Typical clinical presentations range from early childhood motor clumsiness to cognitive difficulties apparent from later childhood.^{2,5,6} Patients' brain MRIs show diffuse hypomyelination with relative preservation of specific structures. Our patients have significantly more residual myelin (figure). Patients with *POLR3B* mutations typically present slightly earlier but have a milder disease course than those with *POLR3A* mutations.^{5,7} It is unusual for a 4H leukodystrophy patient to have absent neurologic deficits by age 26 years.

It is common for patients to have one copy of the V523E mutation in the *POLR3B* gene; however, homozygosity is rare. We hypothesize that patients carrying 2 copies of this variant are either normal their entire life or have only mild neurologic deficits and therefore do not seek medical attention. Because no other patient with comorbidity of MS and 4H leukodystrophy has been described, we hypothesize that it is coincidental in our patient.

Study funding

No targeted funding reported.

Disclosure

Disclosures available: Neurology.org/NG.

Publication history

Received by *Neurology: Genetics* June 25, 2019. Accepted in final form December 18, 2019.

Appendix Authors

Name	Location	Contribution
Stephanie M. DeGasperis, MSc	University of Ottawa, ON, Canada	Analyzed the data; drafted the manuscript for intellectual content
Geneviève Bernard, MD	McGill University, Montreal, Quebec, Canada	Revised the manuscript for intellectual content
Elka Miller, MD	CHEO, University of Ottawa, ON, Canada	Interpreted the data; revised the manuscript for intellectual content
Nicole I. Wolf, MD, PhD	Emma Children's Hospital, Amsterdam, Netherlands	Revised the manuscript for intellectual content
Daniela Pohl, MD, PhD	CHEO, Research Institute, Ottawa, ON, Canada	Designed the study; revised the manuscript for intellectual content

References

1. Timmons M, Tsokos M, Asab MA, et al. Peripheral and central hypomyelination with hypogonadotropic hypogonadism and hypodontia. *Neurology* 2006;67:2066–2069.
2. Bernard G, Vanderver A. POLR3-related leukodystrophy. In: *GeneReviews*. Seattle, WA: University of Washington, Seattle; 2012.
3. Dorboz I, Dumay-Odelot H, Boussaid K, et al. Mutation in *POLR3K* causes hypomyelinating leukodystrophy and abnormal ribosomal RNA regulation. *Neuro Genet* 2018;4:e289. doi: 10.1212/NXG.0000000000000289.
4. Battini R, Bertelloni S, Astrea G, et al. Longitudinal follow up of a boy affected by Pol III-related leukodystrophy: a detailed phenotype description. *BMC Med Genet* 2015;16:53.
5. Wolf NI, Vanderver A, van Spaendonk RM, et al. Clinical spectrum of 4H leukodystrophy caused by *POLR3A* and *POLR3B* mutations. *Neurology* 2014;83:1898–1905.
6. Vanderver A, Tonduti D, Bernard G, et al. More than hypomyelination in Pol-III disorder. *J Neuropathol Exp Neurol* 2013;72:67–75.
7. Tewari VV, Mehta R, Sreedhar CM, et al. A novel homozygous mutation in *POLR3A* gene causing 4H syndrome: a case report. *BMC Pediatr* 2018;18:126.