

Wang Ni, MD, PhD*
Hong-Fu Li, MD, PhD*
Yi-Cen Zheng, MS
Zhi-Ying Wu, MD, PhD

Neurol Genet
2016;2:e74; doi: 10.1212/
NXG.000000000000074

FTL MUTATION IN A CHINESE PEDIGREE WITH NEUROFERRITINOPATHY

OPEN

Neuroferritinopathy is a rare autosomal dominant movement disorder caused by mutations of the *FTL* gene.¹ It is clinically characterized by adult-onset progressive extrapyramidal syndrome, including chorea, dystonia, and parkinsonism.² Brain MRI demonstrates the deposition of iron and ferritin in the basal ganglia.³ To date, several Caucasian families and 2 Japanese families have been reported worldwide.² We present a Chinese neuroferritinopathy pedigree with 5 patients and the *FTL* mutation.

Case. The proband is a 49-year-old woman who began with unsteady gait at age 44 (figure, A). Initially she noticed her left foot dragging and a tendency to fall. Two years later her gait disturbance aggregated and she exhibited tremor of the left hand. She sought medical care in the local hospital, where Parkinson disease (PD) was diagnosed. L-Dopa was prescribed, but her symptoms did not improve after 2 months of treatment. At age 47 her right hand also presented tremor and she developed dysarthria. When she was admitted to our hospital, she showed severe shuffling gait, dysarthria, and tremor of both hands. Neurologic examinations revealed normal muscle strength but increased muscle tension. The knee tendon reflexes were bilaterally brisk. There was no sensory abnormality in her extremities or trunk. Babinski sign was bilaterally negative. Finger-nose test and heel-knee-shin test were normal. Her cognition was mildly impaired, with Mini-Mental State Examination score of 25/30. Laboratory findings included normal hepatic function, renal function, blood glucose, and vitamin B₁₂. However, her serum ferritin level was 6.4 ng/mL (normal 10.0–291.0). Brain CT disclosed symmetric low density of lenticular nucleus (figure, B.a). A brain MRI revealed iron accumulation in the bilateral globus pallidus and putamen (figure, B.b–d). The proband's father presented hand tremors at age 41 and exhibited difficulty walking when he was 43 years old. He died 20 years after the onset of symptoms. The elder sister (II-2) had unsteady walking at age 38, developed dysarthria at age 40, and died of pneumonia when she was 55 years old. The brother (II-11) and second sister (II-5) had

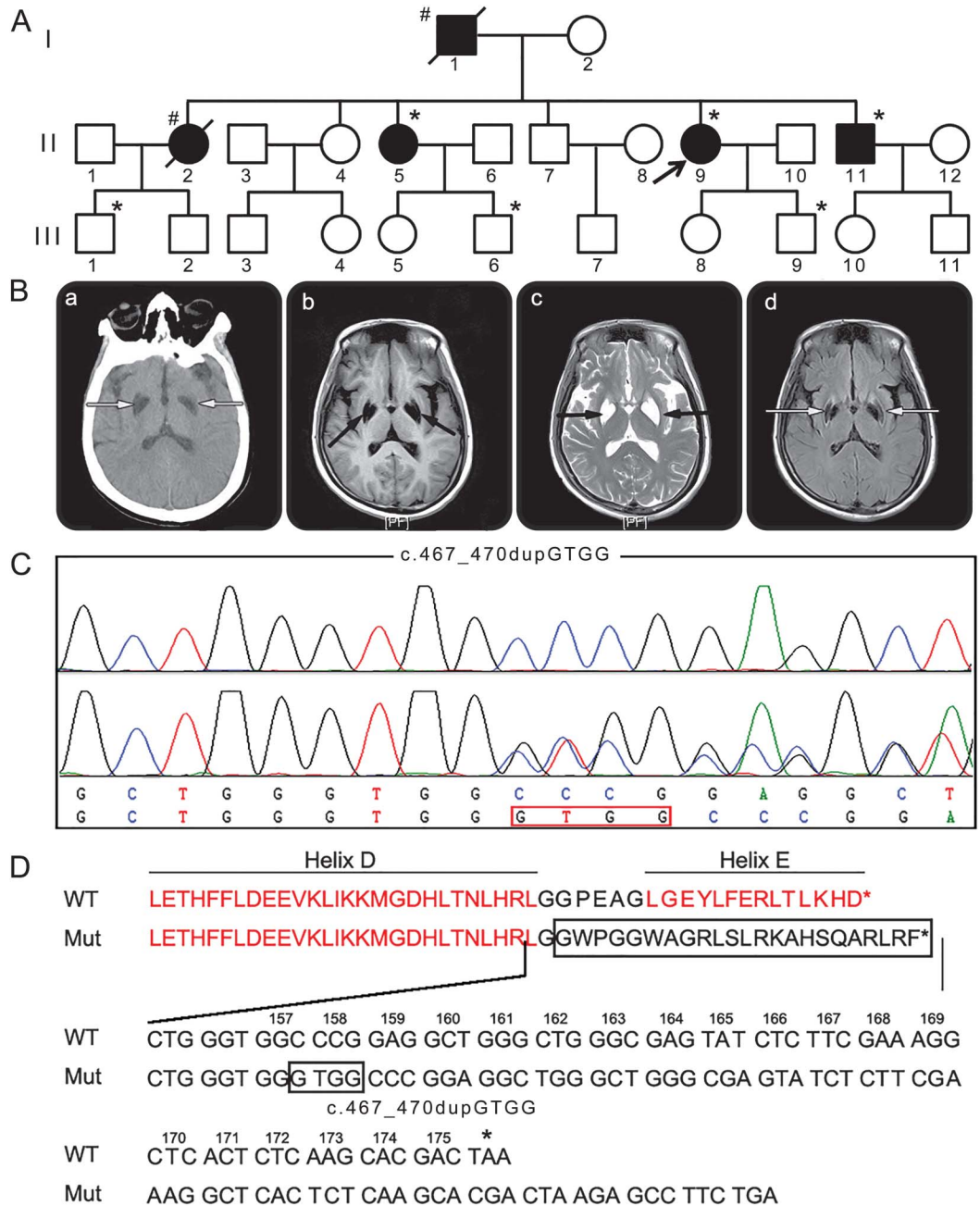
symptoms similar to those of the proband. Serum ferritin levels were 7.8 and 8.1 ng/mL, respectively. They refused brain MRI.

Methods. Informed consent was obtained from all family members and 300 unrelated healthy controls. Peripheral blood was collected and genomic DNA was extracted. The 4 exons of *FTL* gene were amplified by PCR. The purified PCR products were sequenced using an ABI 3730 Automated DNA Sequencer (Applied Biosystems, Foster City, CA).

Results. We identified a *FTL* c.467_470dupGTGG (p.Gly157Glyfs*24) mutation in patients II-5, II-9, and II-11, and in 3 unaffected family members (III-1, III-6, and III-9) (figure, C). This mutation was not present in other family members, 1000 Genome database, ExAC, and 300 control individuals. It was a frameshift mutation, resulting in prolonged protein of FTL. It might disrupt the DE loop and the E helix (figure, D), which was highly conserved and essential for iron core formation.⁴ In addition, it was predicted by Mutation Taster (<http://www.mutationtaster.org>) to be disease-causing. The ages were 29, 25, and 18 years, respectively, for the 3 unaffected mutation carriers who might be presymptomatic individuals.

Discussion. We presented a dominant inherited Chinese pedigree with tremor, dysarthria, low serum ferritin, and iron accumulation in bilateral lenticular nucleus. These features hinted at a diagnosis of neurodegeneration with brain iron accumulation, which was a group of neurodegenerative disorders characterized by extrapyramidal symptoms and abnormal iron deposition in basal ganglia. Among the neurodegeneration with brain iron accumulation subtypes, only neuroferritinopathy was autosomal dominantly inherited because of mutations of *FTL*.⁵ After sequencing *FTL*, we found a novel c.467_470dupGTGG mutation in all patients and 3 presymptomatic members. The absence in 1000 Genome database, ExAC, and 300 controls demonstrated that this mutation was probably pathogenic for neuroferritinopathy in this family. To date, a total of 10 *FTL* mutations (including c.467_470dupGTGG) have been identified worldwide. All the mutations, except p.Ala96Thr,⁶ were insertional mutations in exon 4 of the *FTL* gene, suggesting a mutation hotspot of exon 4.

Figure Pedigree, images, and mutation analysis of the neuroferritinopathy family



(A) Pedigree of the neuroferritinopathy family. Squares indicate males; circles indicate females; the black symbols indicate affected individuals; diagonal lines across symbols indicate deceased individuals; arrow indicates the proband; *indicates the individuals who carry mutation; #indicates individuals whose DNA samples were not available. (B) Brain CT scan discloses symmetric low density of lenticular nucleus (B.a). MRI exhibits bilateral T1-weighted hypointensity (B.b) and T2-weighted hyperintensity (B.c) in the lenticular nucleus. A bilateral hypointensity of globus pallidus and putamen can be observed in axial fluid-attenuated inversion recovery (B.d). (C) Chromatogram of the novel *FTL* c.467_470dupGTGG mutation. The upper panel is a normal sequence, whereas the lower panel represents a heterozygous mutated sequence. (D) Alignment of the wild-type and mutant *FTL* amino acid sequences and the nucleotide sequences encoding *FTL* amino acids 155 to the C-terminal end of each polypeptide. Box indicates the duplication of GTGG between bases 467 and 470 in codon 157.

The proband mainly presented hand tremor, dysarthria, unsteady gait, and mild cognitive impairment, which resembled the manifestations of an Italian neuroferritinopathy patient with an *FTL* c.469_484dup16 mutation.⁷ In addition, the

MRI features of brain are quite similar in these 2 cases. Considering the adjacency of the c.467_470dupGTGG and c.469_484dup16 mutation, these 2 mutations may involve a common pathogenesis. Functional experiments are required

to elucidate the potential mechanisms of neuroferritinopathy underlying *FTL* mutations in the future.

* These authors contributed equally to this work.

From the Department of Neurology and Research Center of Neurology in Second Affiliated Hospital (W.N., H.-F.L., Z.-Y.W.), and the Collaborative Innovation Center for Brain Science, Zhejiang University School of Medicine; and The High School Affiliated to Fudan University-WLSA Fudan Academy (Y.-C.Z.), Shanghai, China.

Author contributions: Dr. Ni: data acquisition, analysis and interpretation of the data, and drafting the manuscript. Dr. Li: data acquisition, analysis and interpretation of the data, and manuscript revision. Ms. Zheng: data acquisition. Prof. Wu: funding, study design and conceptualization, data acquisition, analysis and interpretation of the data, and critical revision of the manuscript.

Acknowledgment: The authors acknowledge the participants for their help and willingness to take part in this study.

Study funding: Funding for this study was granted by the National Natural Science Foundation (81125009, Beijing, China) to Zhi-Ying Wu.

Disclosure: Dr. Ni, Dr. Li, and Ms. Zheng report no disclosures. Prof. Wu has served on the editorial boards of *PLoS One* and *Neuroscience Bulletin*; and has received research support from the National Natural Science Foundation of China. Go to Neurology.org/ng for full disclosure forms. The Article Processing Charge was paid by the authors.

This is an open access article distributed under the terms of the Creative Commons Attribution-NonCommercial-NoDerivatives

License 4.0 (CC BY-NC-ND), which permits downloading and sharing the work provided it is properly cited. The work cannot be changed in any way or used commercially.

Received December 10, 2015. Accepted in final form March 10, 2016.

Correspondence to Dr. Wu: zhiyingwu@zju.edu.cn

1. Curtis AR, Fey C, Morris CM, et al. Mutation in the gene encoding ferritin light polypeptide causes dominant adult-onset basal ganglia disease. *Nat Genet* 2001;28:350–354.
2. Levi S, Rovida E. Neuroferritinopathy: from ferritin structure modification to pathogenetic mechanism. *Neurobiol Dis* 2015;81:134–143.
3. Mancuso M, Davidzon G, Kurlan RM, et al. Hereditary ferritinopathy: a novel mutation, its cellular pathology, and pathogenetic insights. *J Neuropathol Exp Neurol* 2005;64:280–294.
4. Levi S, Cozzi A, Arosio P. Neuroferritinopathy: a neurodegenerative disorder associated with L-ferritin mutation. *Best Pract Res Clin Haematol* 2005;18:265–276.
5. Tonekaboni SH, Mollamohammadi M. Neurodegeneration with brain iron accumulation: an overview. *Iran J Child Neurol* 2014;8:1–8.
6. Maciel P, Cruz VT, Constante M, et al. Neuroferritinopathy: missense mutation in *FTL* causing early-onset bilateral pallidal involvement. *Neurology* 2005;65:603–605.
7. Storti E, Cortese F, Di Fabio R, et al. De novo *FTL* mutation: a clinical, neuroimaging, and molecular study. *Mov Disord* 2013;28:252–253.