

Contents lists available at [ScienceDirect](http://www.sciencedirect.com)

International Journal of Surgery Case Reports

journal homepage: www.casereports.com

Mesenteric desmoid tumour presenting with recurrent abdominal abscess and duodenal fistula: A case report and review of literature



Kai Huang^{a,*}, Heather Stuart^a, Kirill Lyapichev^b, Andrew E. Rosenberg^b, Alan S. Livingstone^a

^a Department of Surgery, Jackson Memorial Hospital/University of Miami Miller School of Medicine, Miami, USA

^b Department of Pathology and Laboratory Medicine, Jackson Memorial Hospital/University of Miami Miller School of Medicine, Miami, USA

ARTICLE INFO

Article history:

Received 20 April 2017

Received in revised form 1 June 2017

Accepted 4 June 2017

Available online 16 June 2017

Keywords:

Desmoid tumor

Fistula

Abscess formation

Treatment

Case report

ABSTRACT

INTRODUCTION: Desmoid tumors are locally destructive but histologically benign. Their management involves close observation and surgical, medical, or hormonal treatment.

PRESENTATION OF THE CASE: A 36-year-old male was admitted for abdominal pain and fever. A CT scan showed fluid collections and air within a mesenteric mass. Diagnostic laparotomy was performed with drainage of the abscess and biopsy of the mass. The pathology suggested a desmoid tumor. His fever and abdominal pain persisted. An endoscopy was performed, which demonstrated a fistula track in the third part of the duodenum. After a multidisciplinary discussion, consensus was to pursue surgical intervention. The patient underwent an en bloc resection of the tumor including a portion of the wall of the third part of the duodenum. The final pathology confirmed a desmoid tumor with a fistula track to the duodenum. The patient had a re-laparotomy on POD2 for intra-abdominal bleeding but was discharged without further events on POD7. He had no evidence of recurrence on follow-up at 11 months.

DISCUSSION: Desmoid tumors are rarely complicated by abscess formation or fistulization. The management of intra-abdominal desmoids in this setting is challenging, as patients are often symptomatic and unresponsive to medical management. Percutaneous drainage and antibiotics are often initiated as first-line treatment, followed by surgery or medical therapy after evaluation of resectability and tumor stage.

CONCLUSION: Rare complications can arise with intra-abdominal desmoid tumors. Principles of infection control should be applied in combination with optimization of oncologic outcome. A multidisciplinary approach helps to achieve both these objectives.

Published by Elsevier Ltd on behalf of IJS Publishing Group Ltd. This is an open access article under the CC BY-NC-ND license (<http://creativecommons.org/licenses/by-nc-nd/4.0/>).

1. Introduction

The work presented in this case study has been reported in line with the SCARE criteria [1].

Desmoid tumors, also known as aggressive fibromatosis, are locally destructive but histologically benign fibroblastic neoplasms that originate from any musculoaponeurotic or fascial structure in the body. They can occur sporadically or in association with familial adenomatous polyposis (FAP). Desmoids are categorized anatomically as intra-abdominal, abdominal wall, and extra-abdominal. Intra-abdominal desmoids typically occur in the intestinal mesentery and can cause complications such as obstruction, perforation, abscess formation, and hemorrhage [2–4]. This case describes a mesenteric desmoid that fistulized into the duodenum causing chronic abscess formation. It is rare for mesenteric fibromatosis to

present with fistula and few cases have been previously reported [5,6]. This case report discusses the optimal treatment of this situation and provides a literature review of the topic.

1.1. Patient information

A 36-year-old Caucasian male walked into a community hospital emergency room with acute upper abdominal pain continuing for three hours, along with nausea and low-grade fever. He denied a change in bowel habits, rectal bleeding, or weight loss. He was a healthy non-smoker, with no relevant medical or surgical history, no medications, and no family history of malignancy. On physical examination, the abdomen was soft and non-distended, with minimal left lower quadrant (LLQ) tenderness to palpation and no palpable mass. A CT scan showed a mesenteric mass with intra-abdominal abscess. He underwent a diagnostic laparotomy at the community hospital with intra-operative drainage of the abscess and biopsy of the mesenteric mass. The final pathology showed a desmoid tumor. His postoperative course was unremarkable, and

* Corresponding author.

E-mail address: hankiefd@gmail.com (K. Huang).

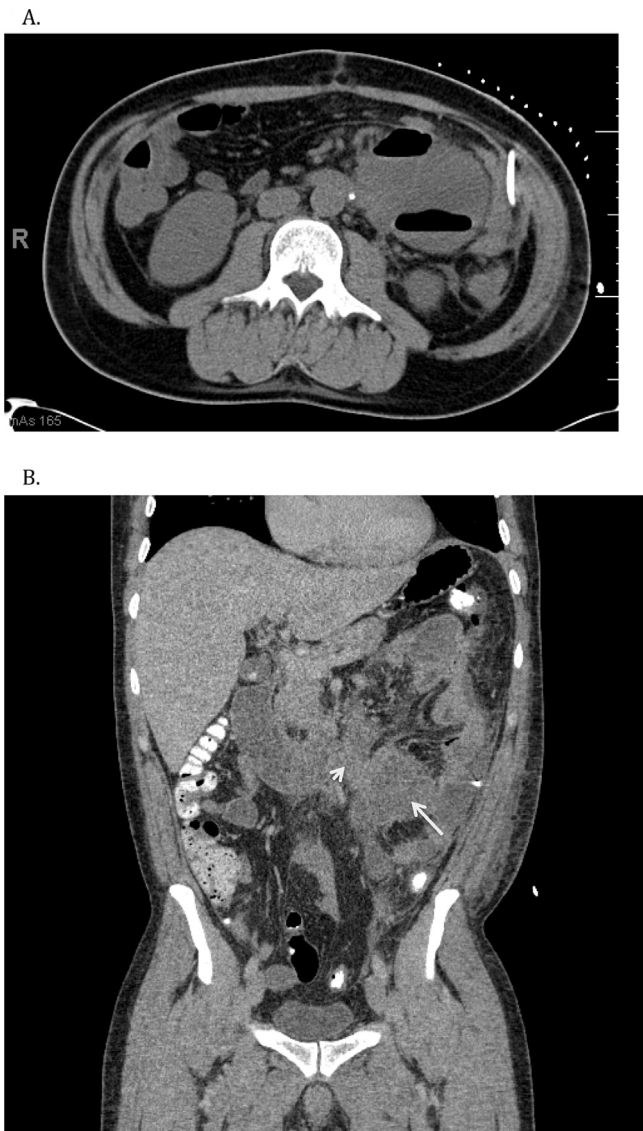


Fig. 1. A (axial view) B (coronal view), left lower quadrant mesenteric mass containing fluid collection and air locules, measuring 6.6 × 6.1 cm and about the cephalad and lateral component 6.6 × 6.9 cm. (long white arrow points to tumor, and short white arrow points to fistula track).

he was discharged home several days later to complete a course of oral antibiotics.

Three weeks later, he developed LLQ pain, fever, and decreased drainage from the left pericolic drain. He presented to the community hospital where the CT again showed an intra-abdominal abscess containing air within the mesentery mass (Fig 1). The drain was repositioned under ultrasound guidance. However, he developed a contrast-induced nephropathy from the CT and had a prolonged hospital stay for ongoing renal monitoring. The patient's family requested transfer to our tertiary hospital.

Following transfer, two additional abdominal drains were placed in an attempt to achieve infectious source control. He was maintained on broad-spectrum antibiotics but continue to have low-grade fevers. An upper and lower endoscopy was performed to assess for polyposis syndrome. During the upper endoscopy, a fistula track was found in the third portion of the duodenum, and a clip was placed just distal to this site. Both endoscopes were negative for polyps.

The patient's case was reviewed by a multidisciplinary sarcoma tumor board, and the outside pathology materials were reviewed.

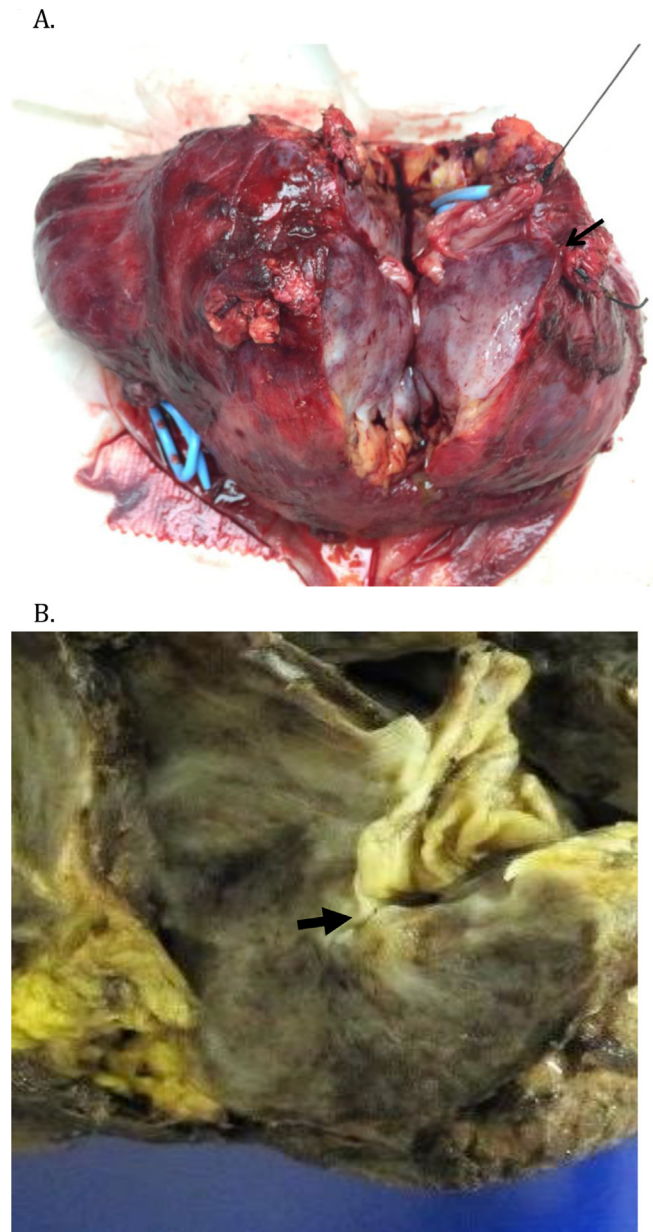


Fig. 2. A (gross specimen), B (Formalin fixed specimen). A portion of small intestine in relation to mesenteric fibromatosis with a fistula formation (black arrow points to the fistula track).

Failure of conservative management to improve the patient's condition and the finding of a neoplastic fistula led to the consensus to move forward with operative intervention. The patient underwent an en bloc resection of the tumor. A portion of the wall of the third part of the duodenum and a section of jejunum were removed with primary closure of the duodenum and side-to-side anastomosis of the jejunum. The tumor measured 12 cm and involved the small bowel mesentery and a portion of the jejunum, but the superior mesenteric artery and vein were uninvolved. There was no additional disease in the abdomen.

On postoperative day one, the patient's hemoglobin dropped from 10 to 7 g/L. He was tachycardic and required ongoing blood products and crystalloid to maintain his urine output. He was taken back to the operating room on postoperative day two for exploratory laparotomy. There was a large clot in the tumor bed. A small mesenteric vein was tied, and the staple line was oversewn to achieve hemostasis. His postoperative course was unremarkable

Table 1
Desmoid tumor staging system from the Collaborative Group of the Americas on Inherited Colorectal Cancer (CGA-ICC) [19].

Stage	
I	Asymptomatic, <10 cm maximum diameter, and not growing
II	Mildly symptomatic,* <10 cm maximum diameter, and not growing
III	Moderately symptomatic,† or bowel/ureteric obstruction, or 10–20 cm, or slowly growing
IV	Severely symptomatic,‡ septic complications such as fistula and abscess, or >20 cm or rapidly growing

* Mildly symptomatic = sensation of mass, pain, but no restriction.
 † Moderately symptomatic = sensation of mass, pain; restrictive but not hospitalized.
 ‡ Severely symptomatic = sensation of mass, pain; restrictive, and hospitalized.

from this point forward, and he was discharged after tolerating a diet on postoperative day seven.

Three months postoperatively, the patient had gained weight and resumed all normal activity. He was started on Celebrex by the medical oncology team. At his most recent follow-up at 11 months, he had no evidence of recurrence on the CT scan.

1.2. Pathological findings

The final pathology showed a firm ill-defined mass measuring 12 × 9 × 7 cm. A fistula track to the duodenum was identified measuring 1.5 cm in diameter. The tumor involved more than 80% of the resected mesentery and appeared to invade the wall of the small bowel. All margins were negative with the closest deep posterior margin 2 mm away from the tumor (Fig 2). The tumor was composed of uniform fibroblasts associated with undulating collagen fibers, consistent with fibromatosis. The fascicles of the tumor infiltrated into the mesenteric fat, and the fistula tract into the tumor was lined by granulation tissue (Fig 3).

2. Discussion

Intra-abdominal desmoid tumors are the least common type of desmoids. When present, they predominately affect the small bowel mesentery (80%) and, less frequently, the transverse colon, retroperitoneum, omentum, and the ligamentum teres [7]. The majority of patients are asymptomatic until the tumor is quite large because of their slow growth. Clinical presentation can vary depending on their size and location. Desmoids can be misdiagnosed as gastrointestinal stromal tumors (GISTs), solitary fibrous tumors (SFTs), inflammatory myofibroblastic tumors (IMTs), sclerosing mesenteritis, retroperitoneal fibrosis, or secondary malignancy, such as lymphoma [8]. Therefore, a histopathological diagnosis is imperative before treatment. A CT-guided percutaneous biopsy or EUS guided biopsy are less invasive and, therefore, preferred over surgical biopsy.

Mesenteric desmoid tumors can cause complications such as bowel obstruction, bleeding, perforation, or rarely compression of the ureters or splenic vein [3,4,9,10]. There are also case reports of uncommon presentations such as aortic rupture or abscess formation associated with desmoid tumors [11,12]. Abscess formation inside the desmoid tumor is rare, and the etiopathogenesis is not completely clear. Some researchers hypothesize that mesenteric tumors compress the vasculature leading to intestinal ischemia with bacterial transposition causing subsequent necrosis and abscess formation [4,11,13–15]. Fistulization to adjacent intestine can result, forming a nidus for recurrent abscess formation. In this case, a fistula in the third portion of the duodenum was identified preoperatively, which facilitated surgical planning. Endoscopy should be performed in patients with intra-abdominal desmoid

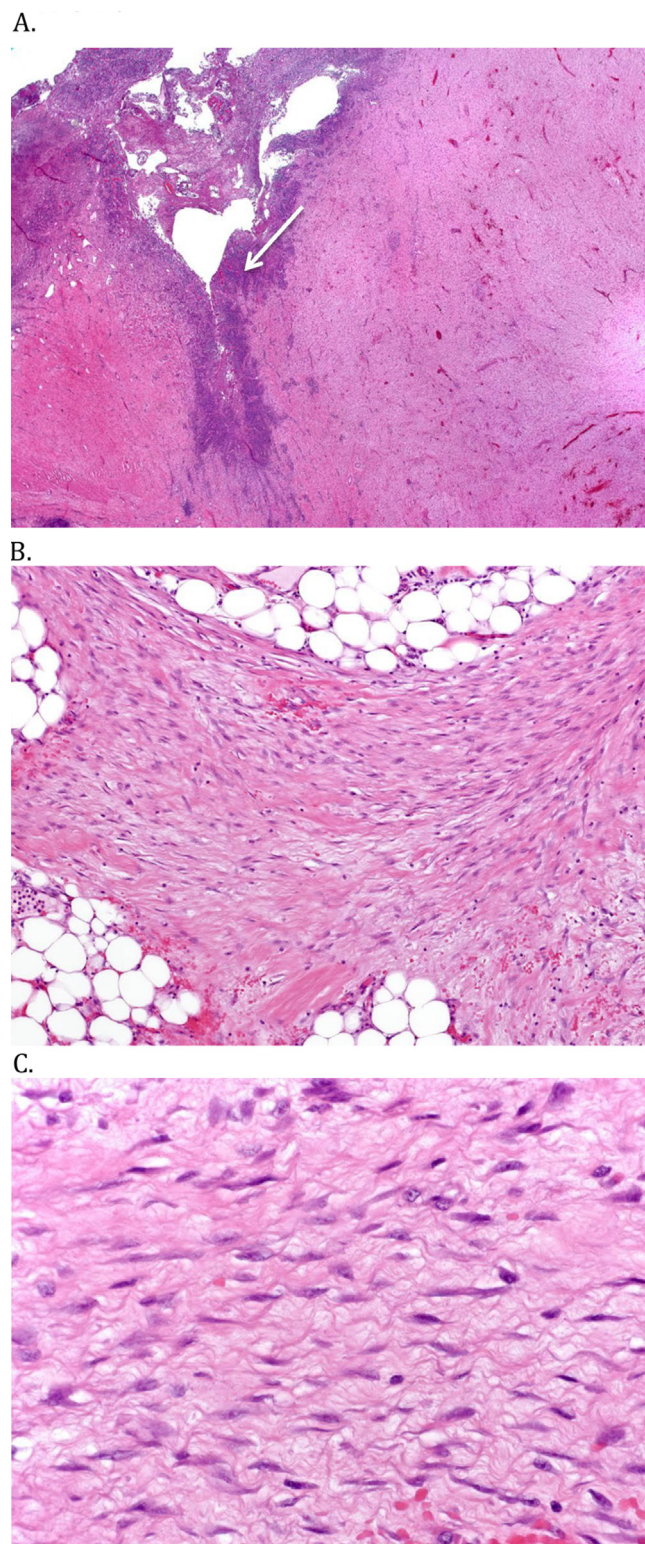


Fig. 3. A. Fibromatosis with fistula tract into the tumor lined by granulation tissue with inflammation. (white arrow points to the fistula track) B. The fascicles of tumor infiltrate into the mesenteric fat. C. The tumor is composed of broad fascicle of uniform fibroblasts associated with undulating collagen fibers.

to rule out an associated polyposis syndrome. In the setting of a chronic infectious process, endoscopy serves a dual purpose in also determining if a fistula exist. If the fistula in this case had been distal in the small bowel, a resection could be more easily performed. It

Table 2
Summary of literature of intra-abdominal Desmoids complicated by abscess formation [15].

Report	Year	No. of pts	FAP related	1st treatment	2nd treatment
Maldjian et al.	1995	3	3	Percutaneous drainage + antibiotics	Surgical resection (2)
Cholongitas et al.	2006	1	None	Percutaneous drainage + antibiotics	Surgical resection (1)
Ebrahimi et al.	2008	1	None	Antibiotics	Surgical resection (1)
Peled et al.	2012	1	None	Antibiotics	Surgical resection (1)
Giovanni et al.	2013	1	1	Percutaneous drainage + antibiotics	Tamoxifen therapy and chemo (1)

was important to know the exact location in this case as a proximal could have warranted a Whipple resection to remove the fistula.

Owing to the rarity of the disease and a lack of understanding of tumor biology, medical and surgical treatment of intra-abdominal desmoids has not been standardized. The treatment in the NCCN guidelines is based on several retrospective series. Surgery is an option for resectable intra-abdominal desmoid tumor, especially if symptomatic [16]. However, mesenteric desmoid tumors pose particular challenges because of their propensity to grow around the superior mesenteric artery at the root of the mesentery [17]. The infiltrating nature of this tumor often leads to positive resection margins, heavy intra-operative bleeding, or extensive resection of small bowel. Smith et al. reported a series of twenty-four patients with intra-abdominal desmoid tumor that underwent attempted surgical resection [18]. Eight (33%) were found to be unresectable. Of the patients that were resected, five of sixteen (31%) suffered substantial post-operative morbidities, including small bowel ischemia, short bowel syndrome, and chronic severe lower extremity lymphedema. Three of these patients died postoperatively. Despite aggressive surgical management, there was no difference in overall survival between completed resected and unresected patients (73% at 10 years). Alternatives to surgery include NSAIDs (primarily Sulindac) with or without antiestrogens, which are often used in patients with asymptomatic, uncomplicated disease [19–21]. Cytotoxic chemotherapy (doxorubicin, dacarbazine) is limited to patients with large, unresectable intra-abdominal disease that failed to respond to Sulindac and/or anti-estrogen therapy.

In 2005, the Collaborative Group of the Americas on Inherited Colorectal Cancer (CGA-ICC) proposed a staging system that graded intra-abdominal desmoid tumors by symptoms, tumor size, and growth rate (Table 1) [19]. The system was designed based on the current understanding of the natural history of desmoids and worked to stratify patients according to the clinical severity of the tumor. Guidelines for management were proposed based on stage, with early stage tumors treated with NSAIDs or local resection and later stage tumors treated with multimodal medical management. Potentially morbid surgery for late stage tumors was a “last resort if patients have progressed or deteriorated on medical therapy.” Cristiano et al. reported a series of 154 intra-abdominal desmoid tumors in patients with FAP that were classified by the CGA-ICC staging system [17]. In their study, patients with Stage I and II disease were managed by observation and surgical resection, respectively. This group had the most favorable prognosis, with almost all patients alive 15 years after diagnosis. Patients with Stage III disease were managed exclusively with combination medical therapy, including NSAIDs, antiestrogens, and chemotherapy (vinblastine/methotrexate). In contrast, Stage IV patients often required urgent surgical management with combined chemotherapy and radiation, when appropriate. Despite treatment, many Stage III and IV patients suffered a high complication rate and increased mortality, with 5-year overall survival rates of 89% and 76%, respectively. Patients at higher risk of mortality included those who suffered from severe pain, had rapidly growing tumors or tumors larger than 10 cm, or had septic complications, such as fistulae or abscesses.

Intra-abdominal desmoids are commonly more difficult to resect without serious morbidity compared with extra-abdominal and abdominal wall desmoid tumors. Surgery may be technically challenging, and the risk to the patient is high, particularly when these tumors occur in patients with FAP [22]. A period of close observation, with serial imaging, can be initiated on asymptomatic patients for an interval of 3–6 months, if symptoms permit [23]. In progressive or symptomatic disease, medical management or surgery are appropriate options [24]. Surgery is an alternative in readily resectable disease; however, the risk of surgery and recurrence should be considered. Occasionally, surgical management becomes the only resort in patients with chronic tumor-related complications, such as in this case where the patient developed chronic abscess formation despite wide drainage and medical treatment (Table 2).

Overall, the principles of managing intra-abdominal desmoid tumors should include the following:

1. Care should be guided by a multidisciplinary team experienced in the management of desmoid tumors.
2. Preoperative imaging and endoscopy are essential in operative planning.
3. Operative intervention should be performed by surgeons familiar with desmoid tumor biology to maximize oncologic outcome and minimize patient morbidity.

3. Conclusion

Intra-abdominal desmoid tumors can produce bowel ischemia, obstruction, perforation, and, in this case, fistulization. Fistulization should be considered in patients with chronic abscess formation after drainage and medical therapy. Multidisciplinary discussion should be conducted before pursuing definitive treatment, and a thorough work up should be completed to appropriately stage the patient and classify desmoid related complications [23].

Conflict of interest

None of the authors report a conflict of interest regarding this case report.

Sources of funding

None declared.

Ethical approval

Not applicable.

Consent

Informed consent for the publication of this work has been obtained.

Author contribution

Kai Huang: Concept and design of study, data collection, data interpretation and analysis, drafting, revision, approval of final manuscript.

Heather Stuart: Surgical oncology fellow, who performed operation and follow-up, data collection, interpretation and analysis, revision of final manuscript.

Alan Livingstone: Surgeon (performed operation and follow-up), Concept and design of study, revision, approval of final manuscript.

Kirill Lyapichev and Andrew Rosenberg: Pathologists (performed the histological examination and provided the H.E slides), data collection, data interpretation and analysis, approval of final manuscript.

Guarantor

Alan S. Livingstone, MD; Kai Huang, MD.

Acknowledgement

English Pro, LLC (LeAnn Garza): Professional English proofreading and editing services.

References

- [1] R.A. Agha, A.J. Fowler, A. Saeta, I. Barai, S. Rajmohan, D.P. Orgill, SCARE Group, The SCARE statement: consensus-based surgical case report guidelines, *Int. J. Surg.* 34 (2016) 180–186.
- [2] J.R. Goldblum, J.A. Fletcher, Desmoid-Type Fibromatosis, in: WHO Classification of Tumors of Soft Tissue and Bone, in: C. Fletcher, J.A. Bridge, P. Hogendoorn, F. Mertens (Eds.), 4th edition, IARC, Lyon, France, 2013, pp. 72–73.
- [3] D. Venkat, E. Levine, W.E. Wise, Abdominal pain and colonic obstruction from an intra-abdominal desmoid tumor, *Gastroenterol. Hepatol.* 6 (10) (2010) 662–665.
- [4] Z. Peled, R. Linder, H. Gilshtein, E. Kakiashvili, Y. Kluger, Cecal fibromatosis (desmoid tumor) mimicking periappendicular abscess: a case report, *Case Rep. Oncol.* 5 (3) (2012) 511–514.
- [5] L. Jalini, D. Hemming, V. Bhattacharya, Intraabdominal desmoid tumour presenting with perforation, *Surgeon* 4 (2) (2006) 114–116.
- [6] M. Shah, B. Azam, Case report of an intra-abdominal desmoid tumour presenting with bowel perforation, *McGill J. Med.* 10 (2) (2007) 90–92.
- [7] A.P. Burke, L.H. Sobin, K.M. Shekitka, B.H. Federspiel, E.B. Helwig, Intra-abdominal fibromatosis: a pathologic analysis of 130 tumors with comparison of clinical subgroups, *Am. J. Surg. Pathol.* 14 (4) (1990) 335–341.
- [8] B. Kasper, P. Stobel, P. Hohenberger, Desmoid tumors: clinical features and treatment options for advanced disease, *Oncologist* 16 (5) (2011) 682–693.
- [9] T. Gondo, K. Yoshida, M. Tachibana, A rare case of an intra-abdominal flat desmoid tumor causing ureteral obstruction, *Int. J. Urol.* 18 (11) (2011) 803–804.
- [10] C. Georgiades, N. Vallianou, T. Argyrakos, A. Aristodimou, G. Kolovelonis, E. Sioula, An unusual case of desmoid tumour presenting as haemorrhagic shock, *Ann. R. Coll. Surg. Engl.* 94 (2) (2012) e81–e82.
- [11] E. Cholongitas, D. Koulenti, G. Panetsos, G. Kafiri, E. Tzirakis, P. Thalasinou, G.V. Papatheodoridis, Desmoid tumor presenting as intra-abdominal abscess, *Dig. Dis. Sci.* 51 (1) (2006) 68–69.
- [12] T. Murayama, S. Imoto, M. Ito, K. Matsushita, S. Matozaki, T. Nakagawa, et al., Mesenteric fibromatosis presenting as fever of unknown origin, *Am. J. Gastroenterol.* 87 (10) (1992) 1503–1505.
- [13] C. Maldjian, H. Mitty, A. Garten, W. Forman, Abscess formation in desmoid tumors of Gardner's syndrome and percutaneous drainage: a report of three cases, *Cardiovasc. Intervent. Radiol.* 18 (3) (1995) 168–171.
- [14] N. Ebrahimi-Daryani, A. Momeni, M.R. AziziAsl, S. Movafaghi, Mesenteric fibromatosis (desmoid tumor) presenting as recurrent abdominal abscess: report of a rare case, *Govaresch* 13 (2) (2008) 128–132.
- [15] G. Alemanno, D. Zambonin, A. Sturiale, T. Cavalli, F. Bellucci, B. Pesi, et al., A multidisciplinary approach to desmoid tumors when intra-abdominal fibromatosis degenerates into an abscess, which is the right treatment? *Int. J. Surg. Case Rep.* 4 (9) (2013) 757–760.
- [16] NCCN guideline Soft Tissue Sarcoma. Version 2. 2016: MS 41.
- [17] C. Quintini, G. Ward, A. Shatnawei, X. Xhaja, K. Hashimoto, E. Steiger, et al., Mortality of intra-abdominal desmoid tumors in patients with familial adenomatous polyposis a single center review of 154 patients, *Ann. Surg.* 255 (3) (2012) 511–516.
- [18] A.J. Smith, J.J. Lewis, N.B. Merchant, D.H. Leung, J.M. Woodruff, M.F. Brennan, Surgical management of intra-abdominal desmoid tumours, *Br. J. Surg.* 87 (5) (2000) 608–613.
- [19] J. Church, T. Berk, B.M. Boman, J. Guillem, C. Lynch, P. Lynch, et al., Staging intra-abdominal desmoid tumors in familial adenomatous polyposis: a search for a uniform approach to a troubling disease, *Dis. Colon Rectum* 48 (8) (2005) 1528–1534.
- [20] P.J. Bus, H.W. Verspaget, J.H. van Krieken, A. de Roos, H.J. Keizer, W.A. Bemelman, et al., Treatment of mesenteric desmoid tumours with the anti-oestrogenic agent toremifene: case histories and an overview of the literature, *Eur. J. Gastroenterol. Hepatol.* 11 (1999) 1179–1183.
- [21] J. Heidemann, H. Ogawa, M.F. Otterson, V.B. Shidham, D.G. Binion, Antiangiogenic treatment of mesenteric desmoid tumors with toremifene and interferon alpha-2b: report of two cases, *Dis. Colon Rectum* 47 (1) (2004) 118–122.
- [22] S.K. Clark, K.F. Neale, J.C. Landgrebe, R.K. Phillips, Desmoid tumours complicating familial adenomatous polyposis, *Br. J. Surg.* 86 (9) (1999) 1185–1189.
- [23] M. Fiore, F. Rimareix, L. Mariani, J. Domont, P. Collini, C. Le Pechoux, et al., Desmoid-type fibromatosis: a frontline conservative approach to select patients for surgical treatment, *Ann. Surg. Oncol.* 16 (9) (2009) 2587–2593.
- [24] B. Kasper, C. Baumgarten, S. Bonvalot, R. Haas, F. Haller, P. Hohenberger, G. Moreau, W.T. van der Graaf, A. Gronchi, Desmoid Working Group, Management of sporadic desmoid-type fibromatosis: a European consensus approach based on patients' and professionals' expertise – a sarcoma patients EuroNet and European Organisation for Research and Treatment of Cancer/Soft Tissue and Bone Sarcoma Group initiative, *Eur. J. Cancer* 51 (2) (2015) 127–136.

Open Access

This article is published Open Access at [sciencedirect.com](https://www.sciencedirect.com). It is distributed under the [IJSCR Supplementing terms and conditions](#), which permits unrestricted non commercial use, distribution, and reproduction in any medium, provided the original authors and source are credited.