



ELSEVIER

Contents lists available at [ScienceDirect](https://www.sciencedirect.com)

Trauma Case Reports

journal homepage: www.elsevier.com/locate/tcr

Case Report

Irreducible traumatic pure hip dislocation by the entrapment of the lateral rotator muscle group of the hip: A case report

Zied Mansi^{a,*}, Saibi Firas^a, Ben Mahmoud Aymen^a, Tounsi Abdelkader^a,
 Islem Chneti^a, Hedi Rbai^a, Wajdi Chermiti^b, Ali Haggui^c, Bacem Zaidi^d,
 Wael Gazzah^e

^a University of Sousse, Ibn El Jazzar Hospital of Kairouan, Department of Orthopedic and Traumatology, Tunisia

^b University of Sousse, Sahloul Hospital of Sousse, Department of Orthopedic and Traumatology, Tunisia

^c University of Sousse, Hospital of Kasserine, Department of Orthopedic and Traumatology, Tunisia

^d University of Sousse, Ibn El Jazzar Hospital of Kairouan, Department of General Surgery, Tunisia

^e University of Sousse, Ibn El Jazzar Hospital of Kairouan, Department of Urology, Tunisia

ARTICLE INFO

Keywords:

Hip
 Lateral rotator muscle
 Dislocation

ABSTRACT

Introduction: Irreducibility is a rare complication of pure posterior hip dislocation requiring surgical intervention.

Case presentation: We present a case of a 22-year-old female with posterior hip dislocation following a motor vehicle accident. Despite unsuccessful closed reduction attempts, open surgical reduction successfully released the incarcerated muscles and achieved reduction. Follow-up examinations showed excellent functional outcomes without complications.

Clinical discussion: Irreducibility remains a rare complication of traumatic posterior hip dislocation. Three possible entities can cause soft tissue incarceration: labral buttonholing, intra-articular osteochondral bodies, and entrapment of the piriformis muscle. The posterior-lateral approach provides excellent exposure of the posterior hip structures, but it carries the risk of injury to the medial circumflex artery. After successfully reducing the dislocation, it is essential to perform a computed tomography (CT) scan to detect any osteochondral lesions, including femoral head impaction. Functional outcomes are better with early mobilization and prompt resumption of weight-bearing. However, femoral head osteonecrosis complicates 52.9 % of hip dislocations reduced beyond 6 h, whereas it occurs in only 4.8 % of dislocations reduced within this timeframe.

Conclusion: This case underscores the importance of prompt recognition and appropriate surgical intervention for irreducible hip dislocations to prevent further complications and optimize patient outcomes.

Introduction

Traumatic pure hip dislocation is a traumatological emergency that requires reduction as promptly as possible to avoid serious complications. Which can be obtained by closed maneuvers in the majority of cases. However Approximately 3 to 4 % of these

* Corresponding author.

E-mail address: doc.zm@hotmail.fr (Z. Mansi).

<https://doi.org/10.1016/j.tcr.2024.101049>

Accepted 4 June 2024

Available online 5 June 2024

2352-6440/© 2024 Published by Elsevier Ltd.

This is an open access article under the CC BY-NC-ND license

(<http://creativecommons.org/licenses/by-nc-nd/4.0/>).

dislocations are irreducible and necessitate an open surgical treatment, where the possibility of soft tissue incarceration, such as capsuloligamentous or, less commonly, muscular structures, must be considered. The aim of this study was to highlight the existence of this rare entity.

Case report

We present the case of a 22-year-old female patient with no significant medical history who was involved in a motor vehicle accident resulting in a closed trauma to the right hip without other associated injuries.

On the ER physical examination vital signs were stable, with no signs of hemodynamic instability.

The patient appeared in pain and the right hip exhibited a fixed posture of flexion and internal rotation, with evident deformity and visibly shortened right limb compared to the left side.

No open wounds or external injuries were observed on the skin overlying the hip. Range of motion of the right hip was significantly limited, with severe pain upon any attempted movement.

Neurovascular examination showed intact sensation and normal distal pulses in the affected limb.

Radiological assessment confirmed a pure posterior right iliac hip dislocation (Fig. 1).

The patient was promptly taken to the operating room within a 2-h timeframe for closed reduction under general anesthesia.

Despite 5 attempts using three different external manipulation techniques, reduction was unsuccessful.

A decision was made to proceed with open surgical reduction.

The posterior-external approach (Moore Approach) was chosen to provide better exposure of the posterior structures.

During the procedure, it was observed that the lateral rotator group of muscles were incarcerated (Fig. 2), leading to the sectioning of the posterior circumflex artery. Fortunately, there was no involvement of the sciatic nerve.

After successful release of the incarcerated muscles, the reduction was achieved easily (Fig. 3).

A CT scan was performed after the open reduction procedure to insure the absence of initial traumatic or an iatrogenic incarceration of a bone fragment or an associated non-displaced acetabulum fracture.

The patient was then placed on a functional treatment plan including no-weight-bearing for 6 weeks with early rehabilitation and was then allowed to resume full weight bearing gradually.

At the 4 months follow-up, the patient has returned to the anterior normal life activities. There were no signs of hip instability in the last physical examination and the radiological assessments showed no signs of avascular necrosis of the femoral head which is the main feared complication.

At the 2-year follow-up, the functional outcome was excellent with a Harris score of 100 points and no signs of necrosis or osteoarthritis (Fig. 4).

Discussion

Irreducibility remains a rare complication of traumatic posterior hip dislocation. It accounts for only 3 % [1,2] of cases, and among the various potential causes, soft tissue incarceration is the most frequent etiology.

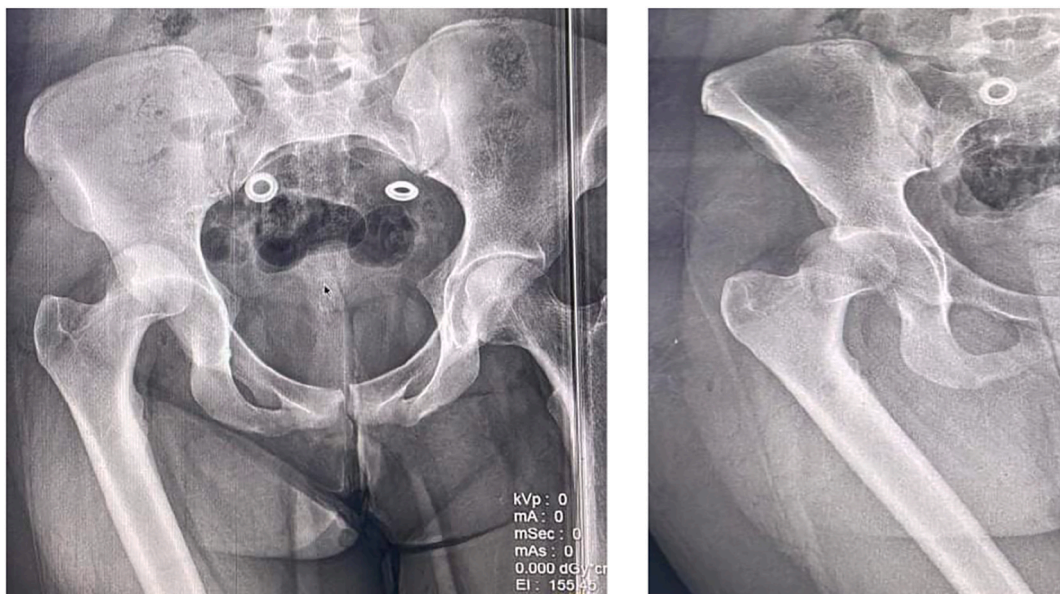


Fig. 1. Pure posterior right iliac hip dislocation.

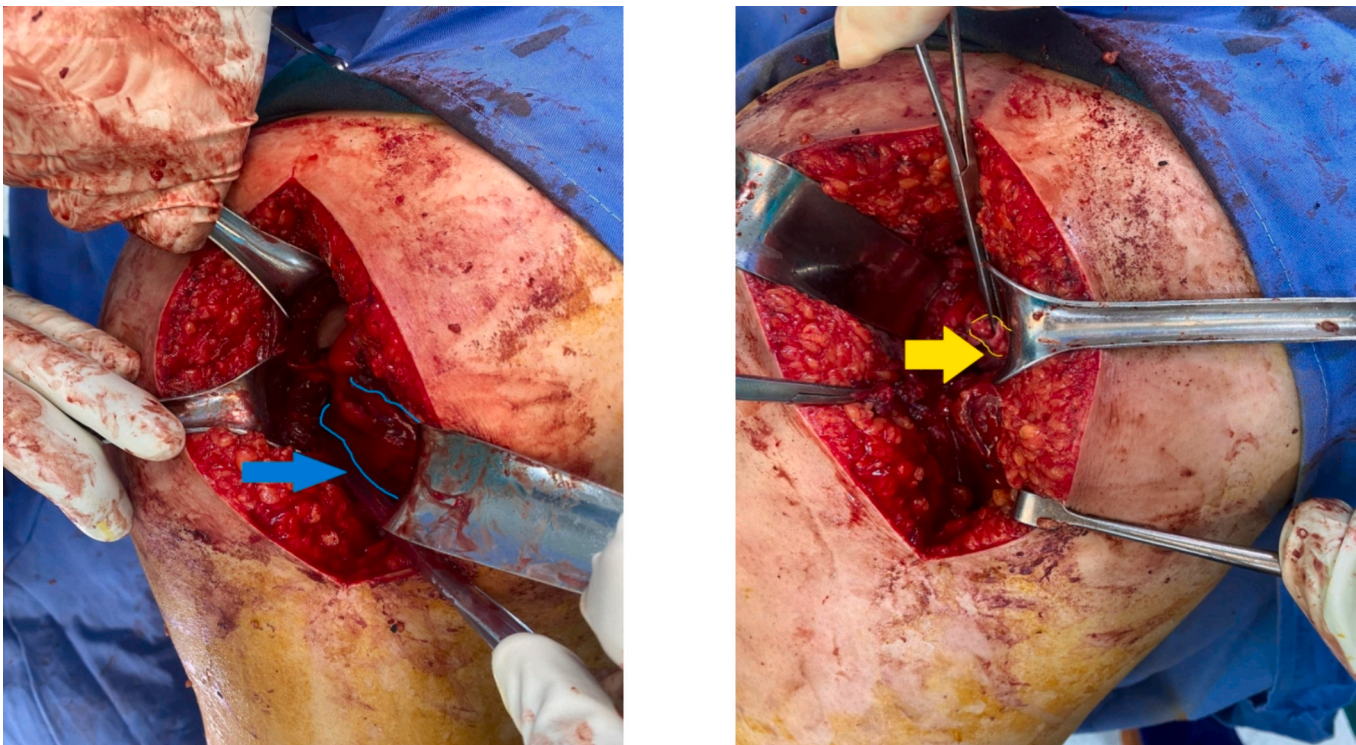


Fig. 2. Entrapment of lateral rotator group (blue) section of posterior circumflex (yellow).

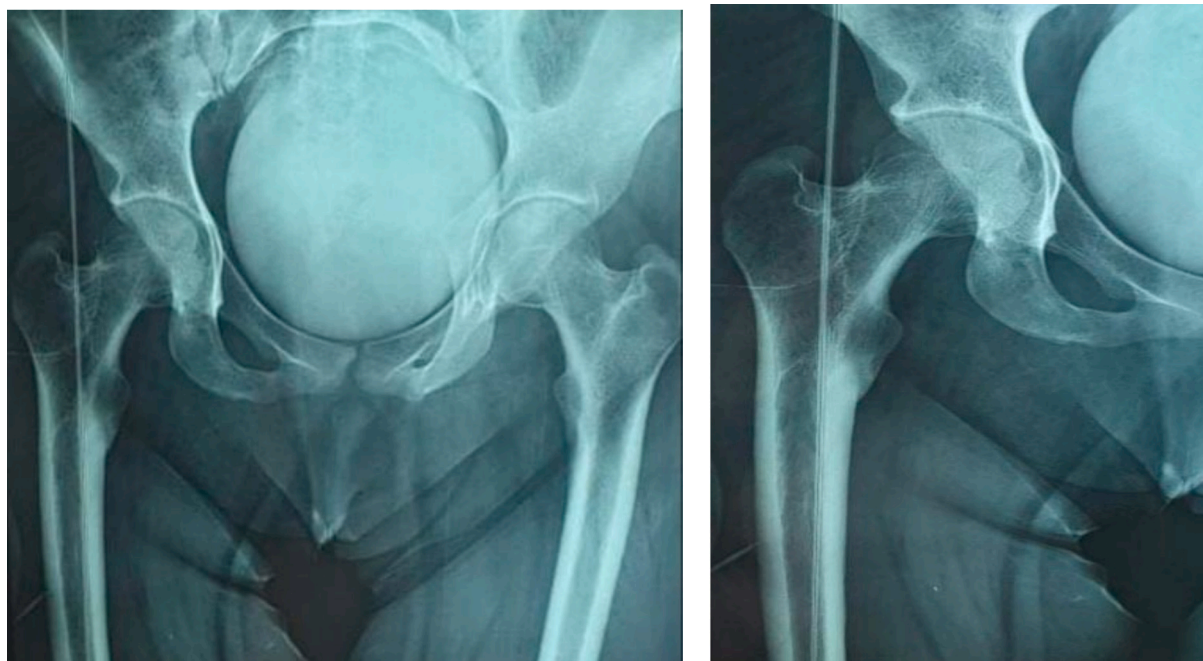


Fig. 3. Post-reduction Xrays.

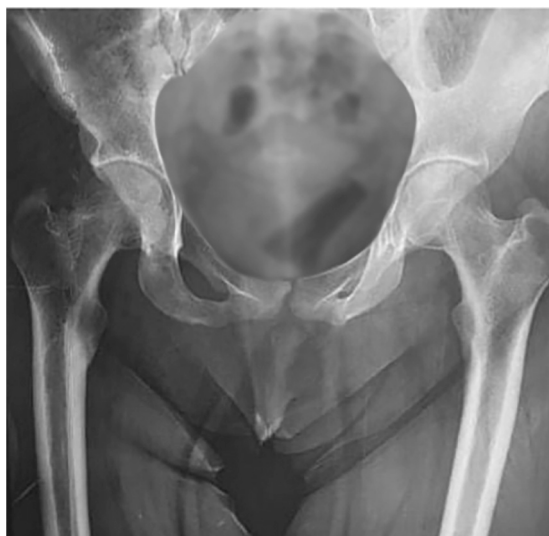

Fig. 4. Pelvic X-ray after 2 years without abnormalities.

Depending on the position of the hip at the moment of trauma [3,4], three possible entities can cause soft tissue incarceration: labral buttonholing, intra-articular osteochondral bodies, and entrapment of the piriformis muscle [2,5].

According to Kim et al. [4], in hip flexion-adduction, dislocation poses a threat to the posterior portion of the capsule and labrum, creating a buttonhole-like structure that obstructs the femoral head.

However, the neutral rotation of the femoral head at time of trauma dislocates it in a posterior-superior direction towards the piriformis muscle, which can become incarcerated within the acetabular cavity following external reduction maneuvers [2,5].

The posterior-lateral approach provides excellent exposure of the posterior hip structures, but it carries the risk of injury to the medial circumflex artery [6,7]. In our case, the patient presented with irreducible hip dislocation due to incarceration of the lateral rotator group of hip muscles. The presence of the incarcerated muscles (Fig. 2) and the subsequent sectioning of the posterior circumflex artery (Fig. 3) were identified during the surgical procedure. It is important to consider irreducibility and the possibility of soft tissue incarceration in cases of failed closed reduction attempts.

Prompt recognition and appropriate surgical intervention are necessary to achieve successful reduction and prevent further complications. Park, Kyeong Hyeon et al. [8] emphasizes the importance careful examination of plain radiographs and CT images for determining the safest treatment strategy before attempting repeated or forceful closed reduction of irreducible femoral head dislocation injuries which can result in iatrogenic femoral neck fractures with Pipkin type III injuries.

Surgical exploration allows for an initial assessment of the injuries and subsequently enables surgical reduction of the dislocation after removing the obstacle.

After successfully reducing the dislocation, it is essential to perform a computed tomography (CT) scan to detect any osteochondral lesions, including femoral head impaction. These injuries have the potential to significantly impact the long-term functional outcome of the hip [9].

Functional outcomes are better with early mobilization and prompt resumption of weight-bearing. However, femoral head osteonecrosis complicates 52.9 % of hip dislocations reduced beyond 6 h, whereas it occurs in only 4.8 % of dislocations reduced within this timeframe [10].

Conclusion

Further studies and research are warranted to explore the incidence, etiology, and optimal management strategies for irreducible traumatic hip dislocations with soft tissue incarceration.

Funding

There is no funding source.

Informed consent

Informed consent was obtained from patient participant in the study.

Consent

Written informed consent was obtained from the patient for publication and any accompanying images. A copy of the written consent is available for review by the Editor-in-Chief of this journal on request.

CRedit authorship contribution statement

Zied Mansi: Methodology, Investigation, Formal analysis, Data curation, Conceptualization. **Saibi Firas:** Software, Resources, Project administration, Methodology. **Ben Mahmoud Aymen:** Investigation, Resources, Writing – original draft. **Tounsi Abdelkader:** Writing – original draft, Validation, Supervision, Software. **Islem Chneti:** Writing – original draft, Formal analysis, Data curation. **Hedi Rbai:** Validation, Supervision. **Wajdi Chermiti:** Visualization, Validation, Software. **Ali Haggui:** Supervision, Methodology, Conceptualization. **Bacem Zaidi:** Visualization, Validation, Resources, Conceptualization. **Wael Gazzah:** Software, Resources, Investigation.

Declaration of competing interest

The authors confirm that they have no conflicts of interest associated with this publication.

The authors declare that they have no known competing financial interests or personal relationships that could have appeared to influence the work reported in this paper.

References

- [1] S.T. Canale, A.H. Manugian, Irreducible traumatic dislocations of the hip, *Journal of Bone and Joint Surgery - Series A* 61 (1) (1979), <https://doi.org/10.2106/00004623-197961010-00003>.
- [2] P. Slätis, A. Latvala, Irreducible traumatic posterior dislocation of the hip, *Injury* 5 (3) (1974), [https://doi.org/10.1016/S0020-1383\(74\)80003-3](https://doi.org/10.1016/S0020-1383(74)80003-3).
- [3] Y.E. Andaloussi, F.A. Essi, M. Arssi, D. Cohen, M. Trafen, Irreducible traumatic dislocation of the hip caused by labral and capsular entrapment with a buttonhole effect, *Revue de Chirurgie Orthopedique et Reparatrice de l'Appareil Moteur* 92 (3) (2006), [https://doi.org/10.1016/s0035-1040\(06\)75737-3](https://doi.org/10.1016/s0035-1040(06)75737-3).
- [4] Y.T. Kim, S. Ninomiya, Y. Tachibana, T. Tanabe, Y. Yano, Acetabular labrum entrapment following traumatic posterior dislocation of the hip, *J. Orthop. Sci.* 8 (2) (2003) 232–235, <https://doi.org/10.1007/s007760300039>.
- [5] B.S. Slasky, M. Liebergall, Irreducible traumatic posterior dislocations of the hip, *Emerg. Radiol.* 4 (2) (1997), <https://doi.org/10.1007/BF01508038>.
- [6] J.C. Garrett, H.C. Epstein, W.H. Harris, J.P. Harvey, V.L. Nickel, Treatment of unreduced traumatic posterior dislocations of the hip, *The Journal of Bone and Joint Surgery. American* 61 (1) (1979) 2–6.
- [7] J.J. Nepple, P.L. Schoenecker, J.C. Clohisy, Treatment of posttraumatic labral interposition with surgical hip dislocation and labral repair, *Iowa Orthop. J.* 31 (2011) 187–192.
- [8] Zied Mansi, Ben Mahmoud Aymen, Tounsi Abdelkader, al., Bilateral acetabular fractures (case report), *Int. J. Surg. Case Rep.* 116 (2024) 109424.
- [9] K.A. Chun, J. Morcuende, G.Y. El-Khoury, Entrapment of the acetabular labrum following reduction of traumatic hip dislocation in a child, *Skeletal Radiol.* 33 (12) (2004) 728–731, <https://doi.org/10.1007/s00256-004-0800-z>.
- [10] Traumatic Posterior Dislocation of the Hip—Prognostic Factors Influencing the Incidence of Avascular Necrosis of the Femoral Head | SpringerLink. <https://doi.org/10.1007/BF00435649> (Retrieved May 22, 2023, n.d.).