

Clinical Article

Radiological Significance of Ligamentum Flavum Hypertrophy in the Occurrence of Redundant Nerve Roots of Central Lumbar Spinal Stenosis

Junseok W Hur, M.D.,¹ Junho K Hur, Ph.D.,² Taek-Hyun Kwon, M.D., Ph.D.,¹ Youn Kwan Park, M.D., Ph.D.,¹ Hung Seob Chung, M.D., Ph.D.,¹ Joo Han Kim, M.D., Ph.D.¹

Department of Neurosurgery,¹ Korea University Guro Hospital, Korea University College of Medicine, Seoul, Korea
Division of Biology,² California Institute of Technology, Pasadena, CA, USA

Objective : There were previous reports of redundant nerve roots (RNRs) focused on their clinical significance and pathogenesis. In this study, we investigated the significant radiologic findings that correlate with RNRs occurrence. These relations would provide an advanced clue for clinical significance and pathogenesis of RNRs.

Methods : Retrospective research was performed with data from 126 patients who underwent surgery for central lumbar spinal stenosis (LSS). Finally, 106 patients with common denominators (inter-observer accuracy : 84%) were included on this study. We divided the patients into two groups by MRI, patients with RNRs and those with no RNRs (NRNRs). Comparative analyses were performed with clinical and radiologic parameters.

Results : RNRs were found in 45 patients (42%) with central LSS. There were no statistically significant differences between the two groups in severity of symptoms. On the other hand, we found statistically significant differences in duration of symptom and number of level included ($p < 0.05$). In the maximal stenotic level, ligamentum flavum (LF) thickness, LF cross-sectional area (CSA), dural sac CSA, and segmental angulation are significantly different in RNRs group compared to NRNRs group ($p < 0.05$).

Conclusion : RNRs patients showed clinically longer duration of symptoms and multiple levels included. We also confirmed that wide segmental angulation and LF hypertrophy play a major role of the development of RNRs in central LSS. Together, our results suggest that wide motion in long period contribute to LF hypertrophy, and it might be the key factor of RNRs formation in central LSS.

Key Words : Redundant nerve roots · Central lumbar spinal stenosis · Ligamentum flavum hypertrophy.

INTRODUCTION

Redundant nerve roots (RNRs) of the cauda equine were first reported by Verbiest²⁰ in 1954 and named by Cressman and Pawl¹¹ in 1968. Although many reports of RNRs have been published since then, the mechanism of RNRs is still unclear. It is described by a tortuosity of elongated and enlarged nerve roots in the subarachnoid space of the lumbar spine¹⁸ and a possible causal relationship between RNRs and central lumbar spinal stenosis (LSS) was recently suggested¹³.

There were several studies that have focused on the clinical significance of RNRs and its pathogenesis^{3,5,6,8,13-15,18,19}. Suzuki et al.¹⁸ suggested that advanced age, longer duration of symp-

tom, and more severe neurological signs and symptoms were significant factors for patients with RNRs while Min et al.⁶ showed different results that only advanced age had statistical significance relationship with the above parameters. The anatomic based static pathogenesis of RNRs of the cauda equine has been attributed to a mechanical trapping at the constricted spinal canal acting on the nerve roots and squeezing force at the most stenotic level¹⁸, but the dynamic mechanism of roots trapping in central LSS has not been investigated yet. In this study, we evaluated the correlation between RNRs and dynamic anatomical characteristics of central LSS to find out the clinical and radiologic evidence in the development of RNRs of cauda equine.

• Received : March 14, 2012 • Revised : June 23, 2012 • Accepted : September 17, 2012

• Address for reprints : Joo Han Kim, M.D., Ph.D.

Department of Neurosurgery, Korea University Guro Hospital, Korea University College of Medicine, 148 Gurodong-ro, Guro-gu, Seoul 152-703, Korea
Tel : +82-2-2626-3097, Fax : +82-2-863-1684, E-mail : nskjh@kumc.or.kr

• This is an Open Access article distributed under the terms of the Creative Commons Attribution Non-Commercial License (<http://creativecommons.org/licenses/by-nc/3.0>) which permits unrestricted non-commercial use, distribution, and reproduction in any medium, provided the original work is properly cited.

MATERIALS AND METHODS

We conducted retrospective research with data from 126 patients who underwent decompressive surgery for central LSS in our institute from January, 2007 to December, 2010. Exclusion criteria was revision, lack of radiologic data, low quality of MRI, infection, compression fracture on same level of central LSS,

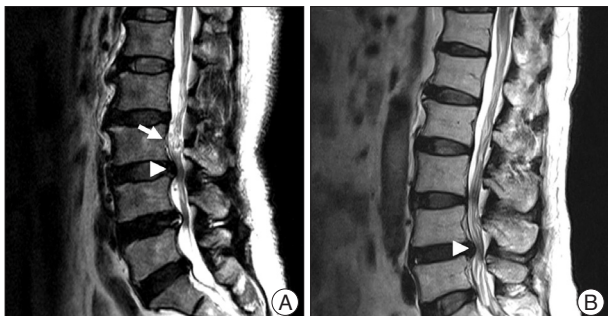

Fig. 1. Demonstration of RNRs (A) and NRNRs (B). Arrow head indicates the maximal stenotic lesion and arrow indicates RNRs.

prominent ruptured disc, and exclusive foraminal stenosis. Three neurosurgeons divided the patients into two groups. Group I included patients with RNRs of cauda equine, and group II included patients with non- RNRs (NRNRs). RNRs were defined as tortuosity of elongated and coiled nerve roots in the sub-arachnoid space associated with spinal stenosis, demonstrable by sagittal T2 weighted MRI (Fig. 1). Finally, 106 patients (inter-observer accuracy : 84%) who showed common denominators were included on this study. Comparative analyses were performed on clinical and radiologic parameters.

On clinical parameters, we analyzed age, sex, duration of symptoms, severity of symptoms (pre-op visual analogue scale (VAS), back pain/lower extremities pain and Oswestry disability index (ODI) (Table 1) score, and level included. Because symptomatic central LSS has been originated from the maximal stenotic level¹¹⁾, we measured dural sac cross-sectional area (CSA), intervertebral disc (IVD) CSA, fat CSA, thickness of lig-amentum flavum (LF), and area of LF within bony spinal canal, at the maximal stenotic level using magnetic resonance (MR)

Table 1. Oswestry disability index

Section 1-Pain intensity	I can sit in my favorite chair as long as I like.
I have no pain at the moment.	Pain prevents me from sitting for more than 1 hour.
The pain is very mild at the moment.	Pain prevents me from sitting for more than ½ hour.
The pain is moderate at the moment.	Pain prevents me from sitting for more than 10 minutes.
The pain is fairly severe at the moment.	Pain prevents me from sitting at all.
The pain is very severe at the moment.	
The pain is the worst imaginable at the moment.	Section 6-Standing
Section 2-Personal care (washing, dressing, etc.)	I can stand as long as I want without extra pain.
I can look after myself normally but it is very painful.	I can stand as long as I want but it gives me extra pain.
I can look after myself normally but it is very painful.	Pain prevents me from standing more than 1 hour.
It is painful to look after myself and I am slow and careful.	Pain prevents me from standing for more than ½ an hour.
I need some help but manage most of my personal care.	Pain prevents me from standing for more than 10 minutes.
I need help every day in most aspects of my personal care.	Pain prevents me from standing at all.
I need help every day in most aspects of self-care.	Section 7-Sleeping
I do not get dressed, wash with difficulty, and stay in bed.	My sleep is never disturbed by pain.
Section 3-Lifting	My sleep is occasionally disturbed by pain.
I can lift heavy weights without extra pain.	Because of pain, I have less than 6 hours sleep.
I can lift heavy weights but it gives extra pain.	Because of pain, I have less than 4 hours sleep.
Pain prevents me from lifting heavy weights off the floor, but I can manage if they are conveniently positioned.	Because of pain, I have less than 2 hours sleep.
Pain prevents me from lifting heavy weights, but I can manage light to medium weights if they are conveniently positioned.	Pain prevents me from sleeping at all.
I can lift only very light weights.	Section 8-Social Life
I cannot lift or carry anything at all.	My social life is normal and cause me no extra pain.
Section 4-Walking	My social life is normal but increases the degree of pain.
Pain does not prevent me walking any distance.	Pain has no significant effect on my social life apart from limitingmy more energetic interests, i.e. sports.
Pain prevents me walking more than 1mile.	Pain has restricted my social life and I do not go out as often.
Pain prevents me walking more than ¼ of a mile.	Pain has restricted social life to my home.
Pain prevents me walking more than 100 yards.	I have no social life because of pain.
I can only walk using a stick or crutches.	Section 9-Traveling
I am in bed most of the time and have to crawl to the toilet.	I can travel anywhere without pain
Section 5-Sitting	I can travel anywhere but it gives extra pain
I can sit in any chair as long as I like.	Pain is bad but I manage journeys of over two hours
	Pain restricts me to short necessary journeys under 30 minutes
	Pain prevents me from traveling except to receive treatment

images and Image J 1.44 NIH software (Fig. 2). Segmental angulation was also measured to quantify mechanical instability at the involved lesion by dynamic plain lateral radiograph (Fig. 3).

Unpaired Student's t-test was used to test the data. The level of significance was set at a probability value of less than 0.05.

RESULTS

Clinical manifestation in RNRs and NRNRs groups (Table 2)

RNRs were found in 45 patients (42%) with central LSS. Between the RNRs and NRNRs groups, the mean ages were similar (RNRs : 66.38±9.02 years vs NRNRs : 65.16±9.02 years, $p=0.495$) and sex proportions also showed no statistic difference (RNRs : m : f=1 : 1.5 vs. NRNRs : m : f=1 : 1.1, $p=0.553$). There were no statistically significant differences between the two groups in severity of symptoms : pre-op VAS back pain (RNRs : 6.17±2.90 vs. NRNRs : 5.06±3.09, $p=0.205$), pre-op VAS lower extremities (RNRs : 7.50±2.62 vs. NRNRs : 5.83±3.22, $p=0.063$), and ODI score (RNRs : 23.72±11.22 vs. NRNRs : 20.26±10.10, $p=0.260$). On the other hand, we found statistically significant differences in duration of symptoms (RNRs : 37.07±58.62 months vs. NRNRs : 19.20±30.93 months, $p=0.045$), and the number of level included (RNRs : 1.69±0.76 vs. NRNRs : 1.20±0.44, $p=0.000$). The disc space between 4 and 5 lumbar spine was major portion of spinal stenosis in both.

The difference of radiologic parameters in RNRs and NRNRs group (Table 3)

In MR images, the maximal stenotic level was frequently developed at the L4-5 and L3-4 region in both groups (RNRs : 40 cases, 89%; NRNRs : 56 cases, 92%) (Table 2). At the maximal stenotic level, the CSA of bony spinal canal (RNRs : 247.49±49.81 mm² vs. NRNRs : 263.58±69.37 mm², $p=0.189$) (Fig. 4A) and fat CSA (RNRs : 26.17±16.80 mm² vs. NRNRs : 32.85±24.53 mm², $p=0.119$) (Fig. 4D) had no significantly different between the two groups. However, dural sac CSA (RNRs : 49.41±18.66 mm² vs. NRNRs : 60.77±24.36 mm², $p=0.010$) (Fig. 4B), thickness of LF (RNRs : 5.81±1.41 mm vs. NRNRs : 4.74±1.41 mm, $p=0.000$) (Fig. 4E), LF CSA within spinal canal (RNRs : 139.99±34.37 mm²

Table 2. Demographic characteristics and clinical manifestation of both groups

parameters	RNRs	NRNRs	p value
No. of patients	45	61	
Mean age (years)	66.38±9.02	65.16±9.02	0.495
Sex (M : F)	1 : 1.15	1 : 1.1	0.553
Pre-op VAS			
Back pain	6.17±2.90	5.06±3.09	0.205
Leg pain	7.50±2.62	5.83±3.22	0.063
ODI score	23.72±11.22	20.26±10.10	0.260
Symptom duration (months)	37.07±58.62	19.20±30.93	0.045*
Number of level included	1.69±0.76	1.20±0.44	0.000*
Maximal stenotic level (cases)			
L2-3	2	1	
L3-4	18	7	
L4-5	22	49	
L5-S1	3	4	

Mean values are presented±standard deviations. *A statistical significant difference was observed between groups. ($p<0.05$). RNRs : redundant nerve roots group, NRNRs : non-redundant nerve roots group, VAS : visual analogue scale, ODI : Oswestry disability index

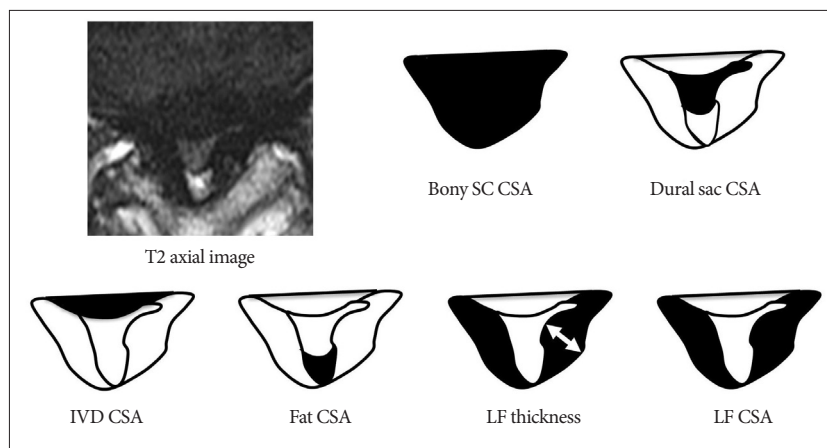


Fig. 2. Measuring anatomical structures within the maximal stenotic level using T2-weighted axial magnetic resonance (MR) image. We measured bony spinal canal (SC) cross-sectional area (CSA), dural sac CSA, intervertebral disc (IVD) CSA, fat CSA, ligamentum flavum (LF) thickness, and LF CSA within spinal canal, and calculated these parameters using Image J 1.44 NIH software.

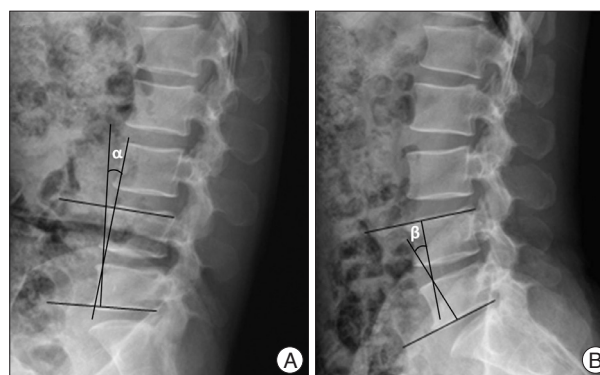


Fig. 3. Method of measurement of segmental angulation by dynamic plain lateral radiograph. We measured as the difference of intervertebral angles from flexion (α in A) to extension (β in B) using lower end plate of inferior body and upper endplate of superior body.

vs. NRNRs : $121.16 \pm 40.97 \text{ mm}^2$, $p=0.014$) (Fig. 4F), and segmental angulation (RNRs : 12.16 ± 5.05 degree vs. NRNRs : 9.36 ± 6.62 degree, $p=0.004$) (Fig. 5) showed statistically significant differences between the two groups. IVD CSA within spinal canal (Fig. 4C) is significantly larger in NRNRs group ($47.82 \pm 24.38 \text{ mm}^2$) than RNRs group ($31.92 \pm 20.93 \text{ mm}^2$).

DISCUSSION

We demonstrate that RNRs of cauda equine are not radiologically rare findings (42%) in central LSS patients, and the incidence of RNRs is consistent with the studies of Suzuki et al.¹⁸⁾ (42.3%). Many researchers tried to figure out clinical signifi-

cance of RNRs, but it remained unclear. Among clinical parameters, our results showed that longer duration of symptoms is a statistically significant factor, while clinical manifestation including VAS and ODI score are not significantly different between two groups. A previous report suggested that patients with RNRs had advanced ages, longer durations of symptoms, and more severe neurological signs and symptoms¹⁸⁾ while another report proposed only advanced age as a significant parameter⁶⁾. Considering the results together, we suggest that clinical correlation with RNRs still remain a controversy although there are radiologic differences between two groups.

Most of previous studies included only one level spinal stenosis, which is the most stenotic level. Yukawa et al.²¹⁾ found that

the patients with two or more stenotic levels walked for a significantly shorter distance preoperatively and postoperatively than patients with stenosis at only one level. In this study, RNRs patients showed more multiple level central LSS although the most stenotic lesion closely related to development of RNRs. Therefore, our study results imply a meaningful relationship between neurogenic intermittent claudication and RNRs. We also confirmed that wide segmental angulation plays a major role

Table 3. The anatomical differences in the maximal stenotic level of both groups

Parameters	RNRs	NRNRs	p-value
Bony SC CSA	247.49±49.81	261.58±66.37	0.189
Dural sac CSA	49.41±18.66	60.75±24.36	0.010*
IVD CSA in the SC	31.92±21.17	48.80±25.19	0.000*
Fat CSA	26.17±16.80	32.85±24.53	0.119
LF thickness	5.81±1.41	4.74±1.41	0.000*
LF CSA	139.99±34.37	121.16±40.97	0.014*
Segmental angulation	12.16±5.05	9.36±6.62	0.004*

Mean values are presented±standard deviations. *A statistical significant difference was observed between groups ($p<0.05$). RNRs : redundant nerve roots group, NRNRs : non-redundant nerve roots group, CSA : cross-sectional area, SC : spinal canal, LF : ligamentum flavum

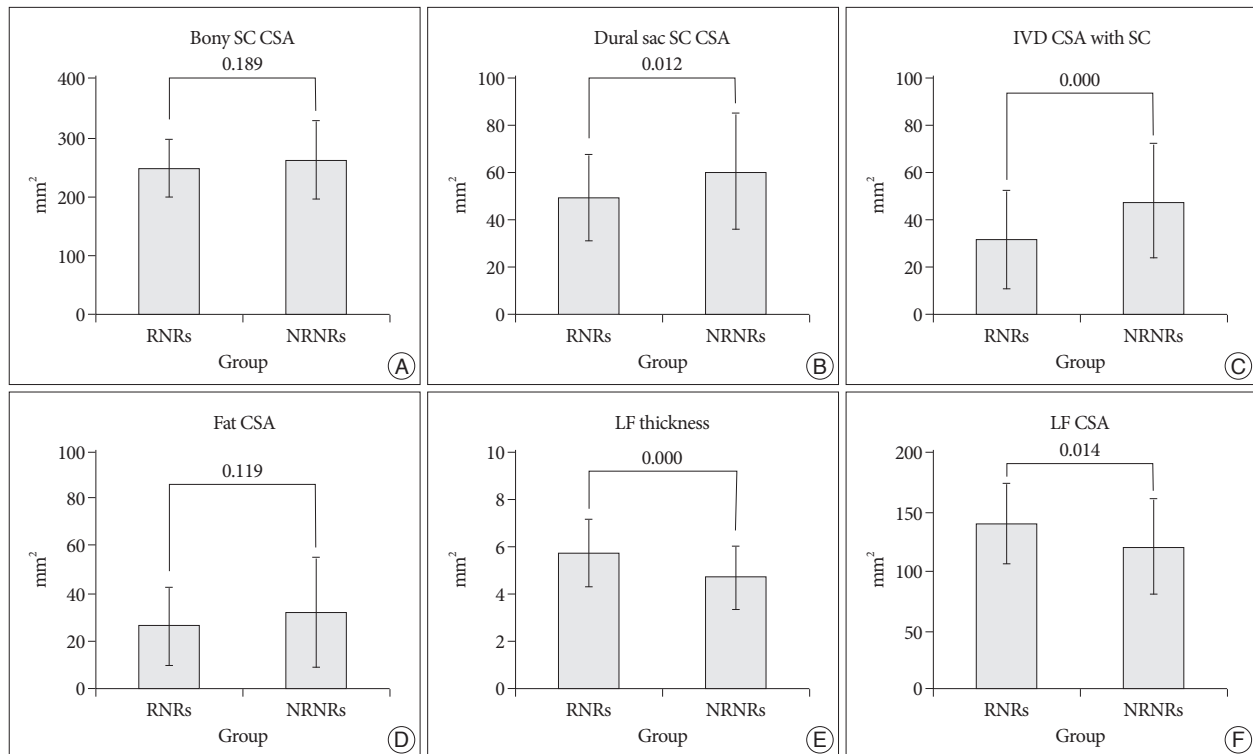


Fig. 4. Radiologic differences of anatomical structures within spinal canal (SC) between RNRs group and NRNRs group. At the maximal stenotic level, the CSA of bony SC (A) and fat CSA (D) had no significantly difference between the two groups. However, dural sac CSA (B), LF thickness (E), LF CSA (F) shows statistically significant differences between the two groups. IVD CSA within SC (C) is significantly larger in NRNRs group than RNRs group (significant p -value <0.05). Mean values are presented±standard deviations (SDs).

in the development of RNRs in central LSS, identifying that L4-5 level are the most movable segments. These results indicate multiple stenosis and wide angular movement could be one of the important factors for RNRs formation in central LSS.

In symptomatic LSS, encroachment of the cauda equine with its nerve roots is the primary cause of the symptom and signs and preoperative symptoms were related to the single most constricted level of the cauda equine, minimum CSA¹¹). In this study, the bony spinal canal CSA had no difference between the two groups although this structure could be changed in central LSS compared to normal spinal canal. Schonstrom et al.¹⁷) have reported that the mean CSA of normal dural sac was 178±50 mm², whereas in patients with degenerative LSS the mean CSA was 89.6±35.1 mm². In present study the dural sac CSA at the level of the maximal stenosis was significantly smaller in RNRs group than NRNRs groups. These results suggest that the degree of constriction in the cauda equine can be the predictive factor of RNRs development. We also measured IVD CSA within spinal canal because IVD can be compressive structure to the dural sac. We found that IVD is not related to development of RNRs. Usually IVD protrusion evoked immediate severe low back pain or radiculopathy. Therefore, we considered that IVD protrusion might not be related to continuous squeezing force at stenotic level for long duration, which is major pathomechanis of RNRs development.

In this study, our major focus was to find out most distributing factor for RNRs formation among the spinal canal structure. We observed strong positive connection between LF hypertrophy and RNRs occurrence in central LSS. Using MR axial images at the maximal stenotic level, measuring the thickness and CSA of LF provide more quantitative information about LH hypertrophy than thickness measurement alone. In this study, we confirmed that the occurrence of RNRs in central LSS show stronger association with LF hypertrophy than the other structure in the spinal canal. Multiple studies supported that LF hypertrophy is a major pathogenic factor of central LSS^{4,12,22}), and that LF hypertrophy has close relationship with mechanical stress^{2,7,9,10,16}). Furthermore, repetitive (longer duration) wide motion (wide segmental angulation) in maximal stenotic level could be considered as high mechanical stress that may lead to development of LF hypertrophy⁷). Together, the results suggest that even though there are several factors that may be related to the development of central LSS, LF hypertrophy could be the major anatomical causes of RNRs formation in central LSS patients.

CONCLUSION

In conclusion, we demonstrated that RNRs of cauda equine are radiologically common findings in central LSS patients. Although there is no significant difference of clinical manifestation besides symptom duration and included level number between RNRs and NRNRs groups, we confirmed that wide segmental angulation and LF hypertrophy play a major role of the develop-

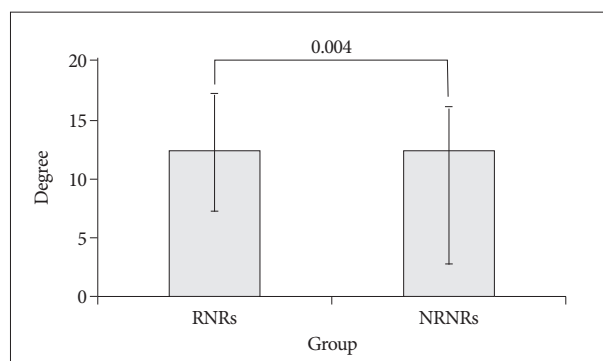


Fig. 5. Segmental angulation at maximal stenotic level. Segmental angulation shows statistically significant differences between the two groups (p -value=0.004). Mean values are presented±standard deviations (SDs).

ment of RNRs in central LSS. This study also provides a clue of pathogenesis of RNRs of cauda equine, implicating that investigation of the mechanism of LF hypertrophy would be important for future therapeutic approach of central LSS with RNRs.

• Acknowledgements

This research was supported by the Basic Science Research Program of the National Research Foundation of Korea (NRF), funded by the Ministry of Education, Science and Technology (2011-0021292).

References

- Cressman MR, Pawl RP : Serpentine myelographic defect caused by a redundant nerve root. Case report. *J Neurosurg* 28 : 391-393, 1968
- Fukuyama S, Nakamura T, Ikeda T, Takagi K : The effect of mechanical stress on hypertrophy of the lumbar ligamentum flavum. *J Spinal Disord* 8 : 126-130, 1995
- Kondo A, Koyama T, Ishikawa J, Hanakita J, Iwaki K : Redundant nerve roots of the cauda equina. *Acta Neurochir (Wien)* 42 : 209-215, 1978
- Kosaka H, Sairyo K, Biyani A, Leaman D, Yeasting R, Higashino K, et al. : Pathomechanism of loss of elasticity and hypertrophy of lumbar ligamentum flavum in elderly patients with lumbar spinal canal stenosis. *Spine (Phila Pa 1976)* 32 : 2805-2811, 2007
- Koyama T, Tsuji N, Handa J : [Redundant nerve roots--a review of its pathogenesis, clinical diagnosis and surgical treatment]. *No Shinkei Geka* 13 : 1265-1270, 1985
- Min JH, Jang JS, Lee SH : Clinical significance of redundant nerve roots of the cauda equina in lumbar spinal stenosis. *Clin Neurol Neurosurg* 110 : 14-18, 2008
- Moon HJ, Park YK, Ryu Y, Kim JH, Kwon TH, Chung HS, et al. : The angiogenic capacity from ligamentum flavum subsequent to inflammation : a critical component of the pathomechanism of hypertrophy. *Spine (Phila Pa 1976)* 37 : E147-E155, 2012
- Naguib MG, Latchaw RE, Erickson DL, Seljeskog EL : Redundant nerve roots of the cauda equina. *Neurosurgery* 9 : 444-449, 1981
- Nakamura T, Hashimoto N, Maeda Y, Ikeda T, Nakagawa H, Takagi K : Degeneration and ossification of the yellow ligament in unstable spine. *J Spinal Disord* 3 : 288-292, 1990
- Nakatani T, Marui T, Hitara T, Doita M, Nishida K, Kurosaka M : Mechanical stretching force promotes collagen synthesis by cultured cells from human ligamentum flavum via transforming growth factor-beta1. *J Orthop Res* 20 : 1380-1386, 2002
- Ogikubo O, Forsberg L, Hansson T : The relationship between the

- cross-sectional area of the cauda equina and the preoperative symptoms in central lumbar spinal stenosis. *Spine (Phila Pa 1976)* 32 : 1423-1428; discussion 1429, 2007
12. Okuda T, Baba I, Fujimoto Y, Tanaka N, Sumida T, Manabe H, et al. : The pathology of ligamentum flavum in degenerative lumbar disease. *Spine (Phila Pa 1976)* 29 : 1689-1697, 2004
 13. Ono A, Suetsuna F, Irie T, Yokoyama T, Numasawa T, Wada K, et al. : Clinical significance of the redundant nerve roots of the cauda equina documented on magnetic resonance imaging. *J Neurosurg Spine* 7 : 27-32, 2007
 14. Pau A, Viale ES, Turtas S, Viale GL : Redundant nerve roots of the cauda equina. *Surg Neurol* 16 : 245-250, 1981
 15. Rengachary SS, McGregor DH, Watanabe I, Arjunan K, Kepes JJ : Suggested pathological basis of "redundant nerve root syndrome" of the cauda equina. *Neurosurgery* 7 : 400-411, 1980
 16. Sairyo K, Biyani A, Goel V, Leaman D, Booth R Jr, Thomas J, et al. : Pathomechanism of ligamentum flavum hypertrophy : a multidisciplinary investigation based on clinical, biomechanical, histologic, and biologic assessments. *Spine (Phila Pa 1976)* 30 : 2649-2656, 2005
 17. Schonstrom NS, Bolender NF, Spengler DM : The pathomorphology of spinal stenosis as seen on CT scans of the lumbar spine. *Spine (Phila Pa 1976)* 10 : 806-811, 1985
 18. Suzuki K, Ishida Y, Ohmori K, Sakai H, Hashizume Y : Redundant nerve roots of the cauda equina : clinical aspects and consideration of pathogenesis. *Neurosurgery* 24 : 521-528, 1989
 19. Suzuki K, Takatsu T, Inoue H, Teramoto T, Ishida Y, Ohmori K : Redundant nerve roots of the cauda equina caused by lumbar spinal canal stenosis. *Spine (Phila Pa 1976)* 17 : 1337-1342, 1992
 20. Verbiest H : A radicular syndrome from developmental narrowing of the lumbar vertebral canal. *J Bone Joint Surg Br* 36 : 230-237, 1954
 21. Yukawa Y, Lenke LG, Tenhula J, Bridwell KH, Riew KD, Blanke K : A comprehensive study of patients with surgically treated lumbar spinal stenosis with neurogenic claudication. *J Bone Joint Surg Am* 84 : 1954-1959, 2002
 22. Zhong ZM, Zha DS, Xiao WD, Wu SH, Wu Q, Zhang Y, et al. : Hypertrophy of ligamentum flavum in lumbar spine stenosis associated with the increased expression of connective tissue growth factor. *J Orthop Res* 29 : 1592-1597, 2011