

# Percutaneous and surgical removal of two cases of embolized totally implantable venous access devices that were implanted a long time ago

Halil Ataş, İbrahim Sarı, Altuğ Cincin, Kürşat Tigen  
Department of Cardiology, Marmara University Training and Research Hospital; İstanbul-Turkey

## Introduction

Totally implantable venous access devices (TVAD) are commonly used to supply long-term, intermittent central venous access for the administration of chemotherapeutic drugs and intravenous (IV) antibiotics (1, 2). The most common complications related to TVAD implantation are venous thrombosis, extravasation, dislodgement, catheter leakage, and infection. Fracture and embolization of TVAD and related infective endocarditis (IE) are rarely observed, but they may be life-threatening (3-5). Herein, we report two interesting cases of embolized TVAD and their management.

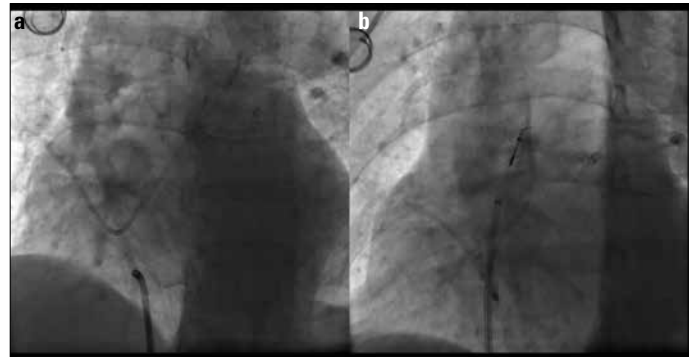
## Case Reports

### Case Report 1

A 72-year-old female with history of coronary artery disease and colon cancer was admitted with unstable angina pectoris. Coronary angiography revealed a critical lesion in the mid-segment of the left anterior descending artery (LAD) but no critical lesion in the left circumflex and right coronary artery. Fluoroscopy showed a TVAD, which was fractured, and approximately 20 cm of it was embolized from the right atrium to the pulmonary artery (Fig. 1a, Video 1). TVAD was implanted 14 years ago for chemotherapy via the left subclavian vein and was forgotten. We decided to apply a percutaneous retrieval of the fractured fragment of TVAD and percutaneous coronary intervention for the LAD lesion. The tip of the free fragment of the TVAD was captured with a micro-snare catheter in the pulmonary artery under fluoroscopy guidance and retrieved from the femoral vein (Fig. 1b, Video 2). Then, a drug eluting stent was deployed to the mid-segment of the LAD.

### Case Report 2

A 28-year-old female with a history of cystic fibrosis (CF) and CF-related diabetes mellitus (CFRDM) was admitted to the emergency department with dyspnea, cough, and green sputum. She was hospitalized with the diagnosis of pneumonia. Sputum culture was positive for *Pseudomonas aeruginosa*. Cefepime and ciprofloxacin was started. Her medical history revealed the implantation of a TVAD 3 years ago via the right cephalic vein for periodical IV antibiotic therapy. During her referral to the cardiology department, transthoracic echocardiography demonstrated a normal left ventricular systolic function but an embolized TVAD from the right atrium into the right ventricle and a nodular mass with the diameter of 1.7×1.4 cm in the right atrium related to TVAD with an irregularity on the surface of the device (Fig. 2a, Video 3). There was moderate tricuspid regurgitation. Blood culture yielded *Staphylococcus epidermidis*. Infective endocarditis (IE) was diagnosed



**Figure 1. a, b. Fluoroscopy shows the forgotten embolized totally implantable venous access device (TVAD), and it is retrieved by a micro-snare catheter**

and daptomycin was added to the therapy regime. The patient was referred to a cardiovascular surgeon, and TVAD was retrieved with the cut-down method. Ten days later, the diameter of the mass reduced to 1.0×1.3 cm with antibiotherapy (Fig. 2b, c). Then, based on her request, the patient was discharged to continue her treatment abroad.

## Discussion

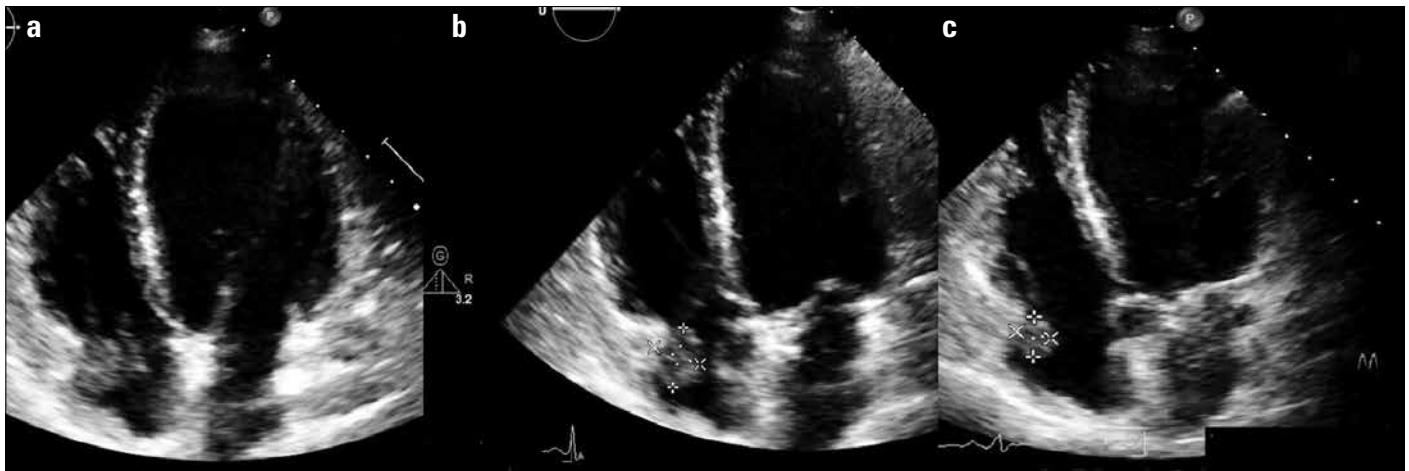Early reports showed that catheter embolism is associated with a high mortality; however, currently, the use of more flexible catheters decreased the mortality rate and other related complications. However, fractured and embolized TVAD is still associated with serious complications such as pulmonary embolism, IE, life-threatening arrhythmias and sudden death (5, 6). Embolized TVAD can stay without any complication for a long duration of time (14 years for one of our cases); conversely, it can cause a complication in a short period of time. Predicting the risk of future complications is difficult; however, the underlying disease and associated comorbidities are important. Therefore, the retrieval of TVAD is recommended (6). Percutaneous retrieval of TVAD fragments is the preferred method because it has a high success rate; however, individual patient characteristics and comorbidities should be considered to select the most appropriate strategy (6, 7).

In the first patient, the TVAD fragment, which embolized to the pulmonary artery, was easily captured in the pulmonary artery and was retrieved with the micro-snare catheter via the femoral vein. It is interesting that TVAD was implanted 14 years ago and was forgotten. To the best of our knowledge, this is the longest duration for embolized TVAD without clinically evident complications in the literature.

IE is a very rare complication, and diagnosis of IE is difficult in these patients (8). In the second patient, TVAD embolized to the right ventricle through the tricuspid valve. Device exposure to continuous turbulent flow may be among the predisposing factors for IE. In addition to intermittent bacteremia due to CF, CFRDM may have contributed to the pathophysiology of endocarditis (9).

## Conclusion

In the first case, the percutaneous retrieval of embolized TVAD was easily performed; however, surgical retrieval of embolized TVAD was planned and performed in the second patient because of the presence of TVAD-related infection and vegetation.



**Figure 2. a-c. (a) Transthoracic echocardiography reveals an embolized TVAD from the right atrium into the right ventricle and a nodular mass in the right atrium. (b) Diameter of the nodular mass is measured to be 1.4×1.7 cm before the antibiotics therapy. (c) Diameter of the nodular mass reduced to 1.0×1.3 cm 10 days after the antibiotics therapy and retrieval of embolized TVAD**

**Video 1.** Fluoroscopy showed a TVAD, which was fractured, and approximately 20 cm of it was embolized from the right atrium to the pulmonary artery

**Video 2.** Tip of the free fragment of TVAD was captured with the micro-snare catheter in the pulmonary artery under fluoroscopy guidance and retrieved from the femoral vein

**Video 3.** Transthoracic echocardiography demonstrated an embolized TVAD from the right atrium into the right ventricle and a nodular mass in the right atrium related to TVAD with irregularity on the surface of the device

**Address for Correspondence:** Dr. Halil Ataş,  
Marmara Üniversitesi Eğitim ve Araştırma Hastanesi,  
Pendik, İstanbul-Türkiye  
Phone: +90 532 546 25 35  
Fax: +90 216 657 09 65  
E-mail: dratashalil@gmail.com



©Copyright 2015 by Turkish Society of Cardiology - Available online at [www.anatoljcardiol.com](http://www.anatoljcardiol.com)  
DOI:10.5152/akd.2015.6298

## References

1. Wildgruber M, Borgmeyer S, Haller B, Jansen H, Gaa J, Kiechle M, et al. Short-term and long-term outcome of radiological-guided insertion of central venous access port devices implanted at the forearm: a retrospective mono-center analysis in 1704 patients. *Eur Radiol* 2015; 25: 606-16. [CrossRef]
2. Munck A, Malbezin S, Bloch J, Gerardin M, Lebourgeois M, Derelle J, et al. Follow-up of 452 totally implantable vascular devices in cystic fibrosis patients. *Eur Respir J* 2004; 23: 430-4. [CrossRef]
3. Groebli Y, Wuthrich R, Tschantz P, Beguelin P, Piguet D. A rare complication of permanent venous access: constriction, fracture and embolization of the catheter. *Swiss Surg* 1998; 4: 141-5.
4. Cheng CC, Tsai TN, Yang CC, Han CL. Percutaneous retrieval of dislodged totally implantable central venous access system in 92 cases: experience in a single hospital. *Eur J Radiol* 2009; 69: 346-50. [CrossRef]
5. Gowda MR, Gowda RM, Khan IA, Punukollu G, Chand SP, Bixon R, et al. Positional ventricular tachycardia from a fractured mediport catheter with right ventricular migration. *Angiology* 2004; 55: 557-60. [CrossRef]
6. Önal B, Coşkun B, Karabulut R, Ilgıt ET, Türkyılmaz Z, Sönmez K. Interventional radiological retrieval of embolized vascular access device fragments. *Diagn Interv Radiol* 2012; 18: 87-91.
7. Choksy P, Zaidi SS, Kapoor D. Removal of intracardiac fractured port-A catheter utilizing an existing forearm peripheral intravenous access site in the cath lab. *J Invasive Cardiol* 2014; 26: 75-6.
8. Royle TJ, Davies RE, Gannon MX. Totally implantable venous access devices - 20 years' experience of implantation in cystic fibrosis patients. *Ann R Coll Surg Engl* 2008; 90: 679-84. [CrossRef]
9. Dal Molin A, Di Massimo DS, Braggion C, Bisogni S, Rizzi E, D'Orazio C, et al. Totally implantable central venous access ports in patients with cystic fibrosis: a multicenter prospective cohort study. *J Vasc Access* 2012; 13: 290-5. [CrossRef]