

An 82-Year-Old Male With a Liver Abscess

Andrew Walkty,^{1,2} David Alexander,^{1,3} and John Embil¹

¹Department of Medical Microbiology & Infectious Diseases, Max Rady College of Medicine, University of Manitoba, Winnipeg, Manitoba, Canada, ²Shared Health, Winnipeg, Manitoba, Canada, and ³Cadham Provincial Laboratory, Winnipeg, Manitoba, Canada

An 82-year-old Filipino male presented to a tertiary care hospital in Canada with a 2-week history of abdominal pain, fever, and chills. Review of systems was otherwise negative. His medical history was significant for atrial fibrillation, a prior cerebrovascular accident, hypertension, dyslipidemia, and remote peptic ulcer disease. The patient was a permanent resident of Canada and had last traveled to the Philippines over a year before. At the time of presentation, he had an oral temperature of 38.8°C and a heart rate of 138 beats per minute. Abdominal tenderness was appreciated with palpation of the epigastrium. On laboratory investigations, the patient had a peripheral white blood cell count of $15.7 \times 10^9/L$, an alanine aminotransferase of 93 U/L, an aspartate aminotransferase of 135 U/L, and an alkaline phosphatase of 184 U/L. A computed tomography scan of the abdomen demonstrated multiple multiloculated cystic hepatic lesions concerning for liver abscesses (Figure 1, arrow). The patient was admitted to the hospital and empirically started on piperacillin-tazobactam. Blood cultures were collected from 2 sites before the initiation of antimicrobial therapy, and an aspirate of the liver lesions was obtained under ultrasound guidance. Gram-negative bacilli were recovered from both blood culture sites, as well as from culture of the aspirate. The isolate grew well on standard bacteriological culture media and had a very mucoid colony morphology (Figure 2, growth on a MacConkey agar plate). When a colony was touched with a bacteriologic loop and pulled up, an elongated mucoviscous string >5 mm in length was observed (positive string test, Figure 3). What is your diagnosis?

ANSWER: LIVER ABSCESS CAUSED BY HYPERVIRULENT *KLEBSIELLA PNEUMONIAE*

Pyogenic liver abscesses may be either polymicrobial or monomicrobial [1, 2]. The bacterial pathogens most commonly recovered from patients with a pyogenic liver abscess include *Escherichia coli*, *Klebsiella* spp., streptococci (including members of the *S. anginosus* group), and anaerobes [1]. In the case described here, the pathogen was identified as *Klebsiella pneumoniae* by matrix-assisted laser desorption ionization (MALDI)–time of flight mass spectrometry (Bruker MALDI Biotyper System using Compass 4.1.70 software and the MBT 7854 MSP library [last updated April 2018], Bruker Daltonics Ltd, East Milton, ON, Canada). Given the mucoid colony appearance and the patient's ethnicity, the isolate was forwarded on to a reference laboratory for further evaluation by whole-genome sequencing. DNA libraries were prepared with the Nextera XT protocol and sequenced on the MiSeq platform (Illumina, San Diego, CA, USA). Sequencing data are available as part of NCBI BioProject PRJNA511988. Contigs were generated using the Assembly and Annotation pipeline of the Rapid Infectious Disease Analysis platform (IRIDA, version 19.09.02), which combines Shovill-based de novo assembly with Prokka-based annotation and QUASt assembly assessment. The isolate was found to contain the *rmpA*, *iuc*, and *iro* genes, confirming that it was a hypervirulent strain.

K. pneumoniae is a gram-negative bacillus that belongs to the order Enterobacterales and the family Enterobacteriaceae [3]. This pathogen is commonly implicated as a cause of nosocomial infections [3, 4]. Hypervirulent *K. pneumoniae* isolates

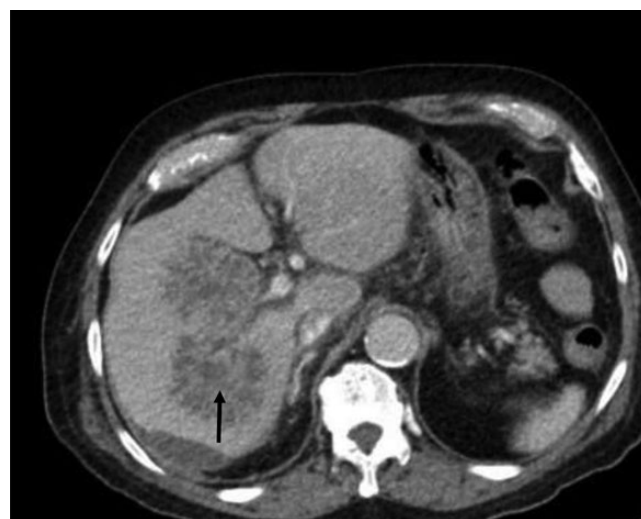

Figure 1. A computed tomography scan of the abdomen demonstrating multiloculated liver abscesses (arrow).

Received 3 June 2020; editorial decision 30 July 2020; accepted 31 July 2020.

Correspondence: Andrew Walkty, MD, MS673B Microbiology, Health Sciences Centre, 820 Sherbrook St., Winnipeg, Manitoba, R3A 1R9, Canada (awalkty@sharedhealthmb.ca).

Open Forum Infectious Diseases®

© The Author(s) 2020. Published by Oxford University Press on behalf of Infectious Diseases Society of America. This is an Open Access article distributed under the terms of the Creative Commons Attribution-NonCommercial-NoDerivs licence (<http://creativecommons.org/licenses/by-nc-nd/4.0/>), which permits non-commercial reproduction and distribution of the work, in any medium, provided the original work is not altered or transformed in any way, and that the work is properly cited. For commercial re-use, please contact journals.permissions@oup.com DOI: 10.1093/ofid/ofaa336

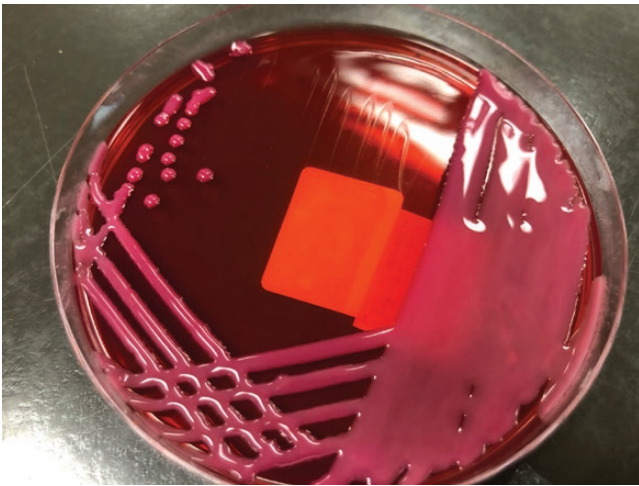


Figure 2. Hypervirulent *Klebsiella pneumoniae* isolate growing on a MacConkey agar plate.

are associated with a syndrome of bacteremia accompanied by pyogenic liver abscess, often with metastatic complications including endophthalmitis and meningitis [4–6]. The liver abscess is typically monomicrobial and occurs in the absence of biliary tract infection [4, 7]. On computed tomographic imaging studies, liver abscesses caused by *K. pneumoniae* often have the following characteristics: single abscess, unilobar involvement, multilocular appearance, solid appearance, association with thrombophlebitis, and absence of underlying biliary tract disease [8, 9]. Hypervirulent isolates have also been reported to cause a variety of other unusual primary infections such as necrotizing fasciitis, psoas abscess, and deep neck infections, as well as pneumonia [4, 5].

In contrast to classical strains, infections with hypervirulent *K. pneumoniae* isolates tend to be community-acquired [4]. This pathotype represents a common cause of liver abscess in




Figure 3. Positive string test.

countries found in the Asian Pacific Rim [2, 4]. Infections due to hypervirulent *K. pneumoniae* have been also reported among patients in Europe and North America [4, 10–12]. Pyogenic liver abscess due to hypervirulent *K. pneumoniae* remains infrequent in Canada [13]. In a population-based study of patients with community-acquired bacteremia due to *K. pneumoniae* in the city of Calgary (AB, Canada), only 4 cases of liver abscess caused by a hypervirulent strain were identified between 2001 and 2007 [13]. Infections with hypervirulent *K. pneumoniae* isolates most frequently occur among patients with an Asian, Pacific Islander, or Hispanic ethnic background, even in the absence of travel to high-prevalence areas (eg, Asian Pacific Rim) [4]. Diabetes mellitus is also reported to be a risk factor [4].

The hypervirulent pathotype may be defined by the presence of particular virulence-associated genes, including *rmpA*, *iucA*, and *iroB*, using molecular diagnostic techniques [4, 14]. The *rmpA* gene is involved in enhancing capsular polysaccharide synthesis, while the *iucA* and *iroB* genes encode the siderophores aerobactin and salmochelin, respectively [4]. Hypervirulent isolates typically produce mucoid colonies on solid agar media. They are usually positive for the string test, performed as described in the case presented here [4, 14]. The string test is reported to have a sensitivity and specificity of 89% and 91%, respectively [14].

Treatment of liver abscesses requires a prolonged course (ie, at least 4–6 weeks) of antimicrobial therapy and drainage when feasible, particularly for abscesses >5 cm in diameter [1, 2]. The choice of antimicrobial is based on the susceptibility profile of the pathogen. In a recent open-label randomized clinical trial, oral antimicrobial therapy was found to be noninferior to intravenous therapy in the treatment of liver abscesses caused by *K. pneumoniae* [15]. Recurrent infection (relapse or reinfection) has been reported following treatment of *K. pneumoniae* liver abscess in a minority of cases, and clinicians should be aware of this possibility [4, 10, 16]. The patient in this report did not have any clinical evidence of metastatic infection. He was initially treated with piperacillin-tazobactam, and then ertapenem. He improved clinically over the course after several weeks and was subsequently stepped down to oral trimethoprim-sulfamethoxazole. The liver abscesses completely resolved on follow-up imaging performed after ~12 weeks of treatment.

In summary, hypervirulent *K. pneumoniae* isolates are an important cause of pyogenic liver abscess. Infection with this pathotype should be suspected based on a combination of epidemiologic, clinical, and laboratory features. Important clues include community acquisition of infection, ethnic background, absence of biliary disease, monomicrobial infection, and metastatic infection at distant sites. A positive string test provides supportive evidence that an isolate is a hypervirulent strain, but this result should be interpreted in the context of the

patient, as the sensitivity and specificity are suboptimal. For patients suspected of having a liver abscess due to hypervirulent *K. pneumoniae*, clinicians should have a low threshold for performing additional diagnostic studies (eg, imaging, ocular exam) to fully define the extent of infection given the propensity for metastatic spread.

Acknowledgments

Potential conflicts of interest. All authors: no reported conflicts of interest. All authors have submitted the ICMJE Form for Disclosure of Potential Conflicts of Interest. Conflicts that the editors consider relevant to the content of the manuscript have been disclosed.

Patient consent. Written consent was obtained from the patient for publication of the case report. This work was also approved by the University of Manitoba Research Ethics Board.

References

1. Sifri CD, Madoff LC. Infections of the liver and biliary system (liver abscess, cholangitis, cholecystitis). In: Bennett JE, Dolin R, Blaser MJ eds. *Mandell, Douglas, and Bennett's Principles and Practice of Infectious Diseases*. 9th ed. Philadelphia, PA: Elsevier; 2020:1037–45.
2. Roediger R, Lisker-Melman M. Pyogenic and amebic infections of the liver. *Gastroenterol Clin North Am* 2020; 49:361–77.
3. Forsythe SJ, Pitout J, Charnot-Katsikas A, Alby K, Frank KM. *Klebsiella* and selected *Enterobacteriales*. In: Carroll KC, Pfaller MA, Landry ML, et al., eds. *Manual of Clinical Microbiology*. 12th ed. Washington, DC: ASM Press; 2019:724–50.
4. Russo TA, Marr CM. Hypervirulent *Klebsiella pneumoniae*. *Clin Micro Rev* 2019; 32:e00001-19.
5. Lee HC, Chuang YC, Yu WL, et al. Clinical implications of hypermucoviscosity phenotype in *Klebsiella pneumoniae* isolates: association with invasive syndrome in patients with community-acquired bacteraemia. *J Intern Med* 2006; 259:606–14.
6. Fang CT, Lai SY, Yi WC, et al. *Klebsiella pneumoniae* genotype K1: an emerging pathogen that causes septic ocular or central nervous system complications from pyogenic liver abscess. *Clin Infect Dis* 2007; 45:284–93.
7. Wang JH, Liu YC, Lee SS, et al. Primary liver abscess due to *Klebsiella pneumoniae* in Taiwan. *Clin Infect Dis* 1998; 26:1434–8.
8. Alsaif HS, Venkatesh SK, Chan DS, Archuleta S. CT appearance of pyogenic liver abscesses caused by *Klebsiella pneumoniae*. *Radiology* 2011; 260:129–38.
9. Lee JH, Jang YR, Ahn SJ, Choi SJ, Kim HS. A retrospective study of pyogenic liver abscess caused primarily by *Klebsiella pneumoniae* vs. non-*Klebsiella pneumoniae*: CT and clinical differentiation. *Abdom Radiol*. **In press**.
10. Fierer J, Walls L, Chu P. Recurring *Klebsiella pneumoniae* pyogenic liver abscesses in a resident of San Diego, California, due to a K1 strain carrying the virulence plasmid. *J Clin Microbiol* 2011; 49:4371–3.
11. Rafat C, Messika J, Barnaud G, et al. Hypervirulent *Klebsiella pneumoniae*, a 5-year study in a French ICU. *J Med Microbiol* 2018; 67:1083–9.
12. Frazee BW, Hansen S, Lambert L. Invasive infection with hypermucoviscous *Klebsiella pneumoniae*: multiple cases presenting to a single emergency department in the United States. *Ann Emerg Med* 2009; 53:639–42.
13. Peirano G, Pitout JD, Laupland KB, et al. Population-based surveillance for hypermucoviscosity *Klebsiella pneumoniae* causing community-acquired bacteraemia in Calgary, Alberta. *Can J Infect Dis Med Microbiol* 2013; 24:e61–4.
14. Russo TA, Olson R, Fang CT, et al. Identification of biomarkers for differentiation of hypervirulent *Klebsiella pneumoniae* from classical *K. pneumoniae*. *J Clin Microbiol* 2018; 56:e00776-18.
15. Molton JS, Chan M, Kalimuddin S, et al. Oral vs intravenous antibiotics for patients with *Klebsiella pneumoniae* liver abscess: a randomized, controlled noninferiority study. *Clin Infect Dis*. **In press**.
16. Cheng HC, Chang WL, Chen WY, et al. Long-term outcome of pyogenic liver abscess: factors related with abscess recurrence. *J Clin Gastroenterol* 2008; 42:1110–5.