

Transmural conduction delay and block producing a pseudo-infarction electrocardiogram during treatment of anaphylaxis



Matthew Olson, MD,* Jian-Ming Li, MD, PhD, FHRS,[†] Selçuk Adabag, MD, MS, FHRS,[†] David G. Benditt, MD, FHRS,[‡] Scott Sakaguchi, MD, FHRS^{‡*}

From the *United Hospital, St. Paul, Minnesota, [†]Division of Cardiology, Veterans Affairs Health Care System, Minneapolis, Minnesota, and [‡]Department of Medicine, Cardiovascular Division, University of Minnesota, Minneapolis, Minnesota.

Introduction

A pseudo-infarction electrocardiogram (ECG) pattern may be seen in clinical conditions including heart disease (eg, left ventricular hypertrophy, left bundle branch block, hypertrophic cardiomyopathy, Wolff-Parkinson-White syndrome, pericarditis), pulmonary disease (eg, embolism), metabolic abnormalities (eg, hyperkalemia), or channelopathy (eg, Brugada syndrome).¹ In some situations, the resemblance to acute infarction is particularly striking. We present a case of anaphylaxis in which an ECG pattern of pseudo-infarction developed 72 hours after admission and resolved within 15 hours of discontinuation of diphenhydramine (DPH). The observed ECG changes mimicked those seen in an animal model of acute coronary occlusion. This case suggests that transmural conduction slowing and block may be responsible for the acute infarction pattern seen in coronary occlusion as well as some cases of pseudo-infarction on ECG such as drugs or hyperkalemia.

Case report

A 63-year-old man presented to the Emergency Department with a chief complaint of facial swelling beginning 2 hours earlier. He reported rapid, progressive swelling of his lips and mouth after eating oysters, which was not a novel food for him. He initially denied recent use of angiotensin-converting enzyme inhibitors or nonsteroidal anti-inflammatory agents, the latter being a listed allergy for him. Although he later recalled ibuprofen consumption in the days prior to admission, the root cause of the anaphylaxis

KEY TEACHING POINTS

- QRS widening may be caused by conduction delay owing to drugs or metabolic abnormalities that impair sodium channels and slow the upstroke of ventricular action potentials. QRS widening may mimic acute myocardial infarction.
- An animal model has previously shown that acute coronary occlusion delays transmural ventricular activation that produces QRS widening that appears as ST-segment elevation and T-wave inversion. In this model, complete conduction block was seen as QRS widening without T-wave inversion.
- A pseudo-infarction electrocardiogram seen with drug or electrolyte abnormalities may be due to their effects on sodium channels that slow or, sometimes, block transmural ventricular activation.

was not definitively identified. There was no prior history of angioedema or anaphylactic allergic reactions. He had no prior cardiac history. Pertinent social history included polysubstance abuse with a recent positive urine drug screen for cocaine. His outpatient medications included loratadine, metformin, omeprazole, oxybutynin, and pravastatin.

On initial presentation he had no tongue edema and lungs were clear and without wheezing. Cardiac examination was normal; abdomen was soft, nontender, and not distended. Skin showed no erythema or urticarial, but he then developed rapid progression of angioedema and was urgently intubated. Intubation was difficult and required inhaled racemic and subcutaneous epinephrine. While ventilated, he received sedation with propofol (300 mg intravenously (iv) initially, then 60 mcg/kg/min), supplemented with midazolam and fentanyl as needed. He received no neuromuscular blocking agents. For angioedema he received methylprednisolone 125 mg iv every 6 hours, ranitidine 50 mg iv every 8 hours,

KEYWORDS Pseudo-infarction; Sodium channels; Use-dependent block; Diphenhydramine; Fentanyl; ST elevation; Hyperkalemia; T-wave inversion (Heart Rhythm Case Reports 2022;8:453–457)

Funding Sources: This research did not receive any specific grant from funding agencies in the public, commercial, or not-for-profit sectors. **Disclosures:** The authors have no conflicts to disclose. **Address reprint requests and correspondence:** Dr Scott Sakaguchi, University of Minnesota, MMC 508, 420 Delaware St SE, Minneapolis, MN 55455. E-mail address: sakag001@umn.edu.

Admission - Hospital Day 1 - 18:28:32

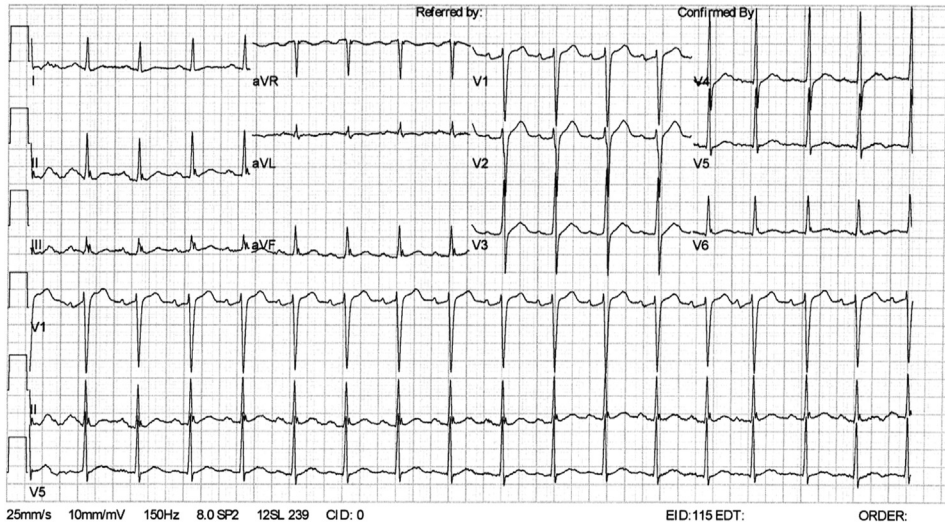


Figure 1 Presenting electrocardiogram shows normal sinus rhythm. Intervals are R-R = 588 ms, PR = 172 ms, QRS = 92 ms, QT/QTc = 354/463 ms. A J wave is noted in the inferior and lateral leads.

DPH 50 mg iv every 6 hours, and inhaled albuterol every 6 hours. His admission ECG (Figure 1) is notable for normal QRS duration and evidence of early repolarization in the inferior leads, but otherwise no significant ST-T abnormalities.

On hospital day 3, he was noted to have intermittent periods of marked QRS widening and ST elevation on cardiac monitor that corresponded to faster sinus rates in the setting of mild agitation. He was hemodynamically stable and did not require vasoconstrictors. Figure 2A and 2B shows 2 12-lead ECGs taken within 9 minutes of each other, 72 hours after admission, both in sinus rhythm. In Figure 2A the heart rate is 111 beats per minute (bpm) with marked QRS prolongation or ST elevation (discussed below). In Figure 2B the mean heart rate is 89 bpm with premature atrial complexes (PACs) that maintained a narrow QRS duration.

Figure 3 shows a 12-lead ECG taken 10 hours following those in Figure 2: QRS complexes are wide and T-wave inversions are present except when following a more closely coupled QRS complex. Bedside echocardiography showed normal left ventricular systolic function without regional wall motion abnormalities. Serial troponin levels were normal. Coronary angiography prior to hospital discharge on hospital day 7 showed no obstructive lesions.

In the absence of enzymatic or echocardiographic evidence of myocardial injury or infarction, the ECG changes were deemed to be metabolic in origin because of the acceleration- or use-dependent nature of the changes. His plasma electrolytes, including Na, K, Mg, and Ca, were normal, as was renal function.

DPH was considered a possible culprit for the ECG changes, since it had been started after admission; DHP was discontinued. The ECG changes resolved within 15 hours. Unfortunately, blood levels of DPH were not obtained. He had received a total of 11 doses of DPH over 3 days (550

mg), which is within recommendations.² He was extubated on hospital day 5. He was advised to avoid DPH and it was added to his allergy list. After 7 years of follow-up the patient has done well, without cardiac problems.

Discussion

QRS widening represents delayed ventricular activation. In this regard, several aspects of this patient's ECGs are notable. First, conduction slowing showed profound acceleration or use dependence. Second, the QRS morphology mimicked acute myocardial infarction. Third, QRS complexes were sometimes, but not always, associated with marked T-wave inversions.

Sodium channel block in ventricular myocardium causes slowing of phase 0 depolarization at the cellular level that slows ventricular conduction and activation, producing QRS prolongation on the surface ECG. Perhaps less well appreciated is that transmural conduction slowing may mimic ST-segment elevation with T-wave inversion. If transmural conduction is completely blocked, however, T-wave inversion may be absent.³

The hallmark of acute myocardial infarction due to epicardial coronary occlusion is ST-segment elevation and T-wave inversion. Using a canine ventricular wedge preparation, Di Diego and Antzelevitch³ showed that the apparent ST elevation (often called a "tombstone" pattern) in acute ischemia is actually a prolonged R wave that develops owing to marked transmural conduction delay from endocardium to epicardium. When this occurred, late epicardial depolarization manifested as T-wave inversion. At times, the wedge preparation demonstrated complete block of conduction from endocardium to epicardium. In this latter situation, the ECG showed a similarly wide QRS complex owing to

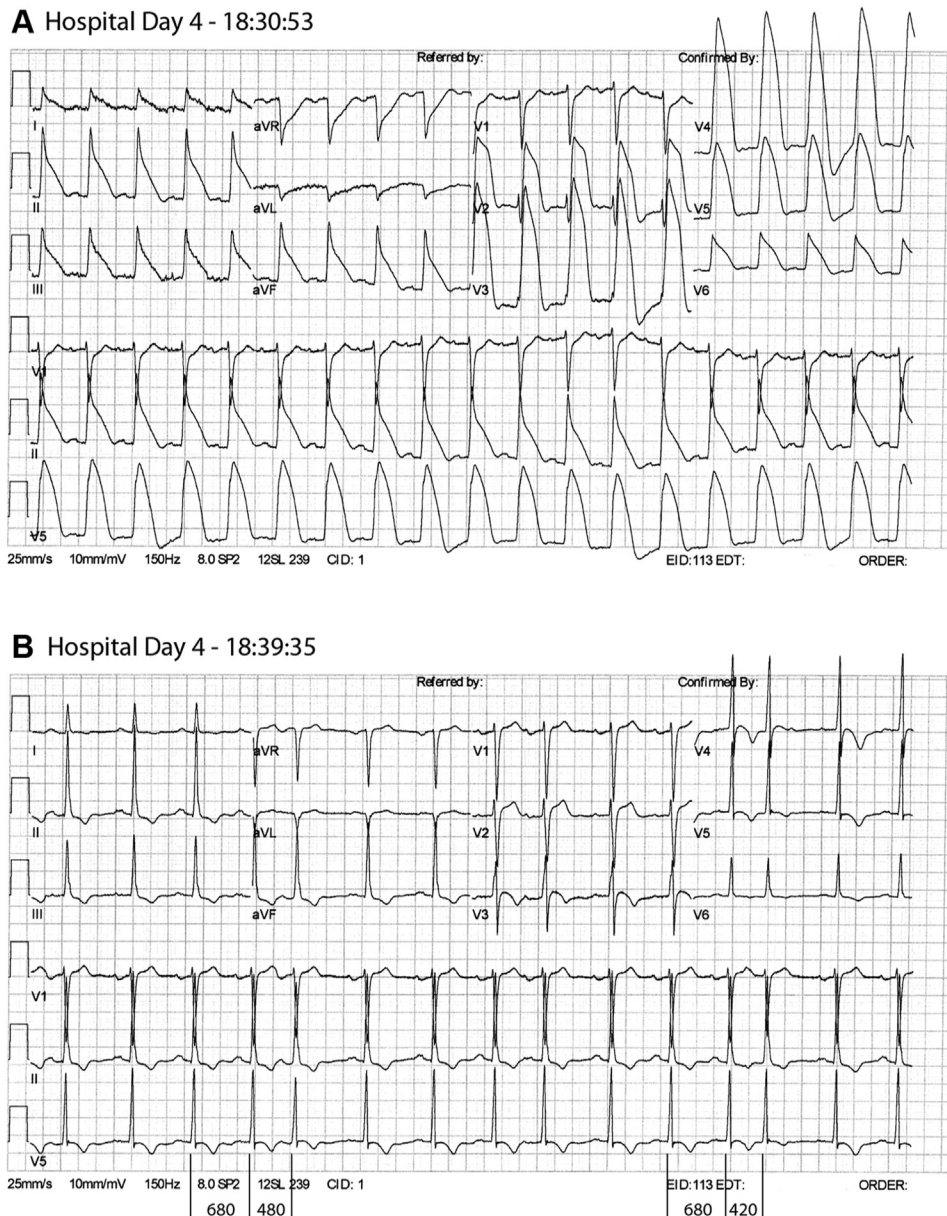


Figure 2 On hospital day 4 telemetry monitor showed periods of QRS widening at sustained faster heart rates. **A:** In the 12-lead electrocardiogram (ECG) the rate is 111 beats/min with widespread “ST elevation” in a “tombstone” pattern as seen in acute myocardial infarction from epicardial coronary occlusion. The apparent ST elevation may actually represent a prolonged QRS complex due to transmural conduction delay (see text). **B:** Here the rate is approximately 89 beats/min and the QRS is narrow. This ECG was obtained within 9 minutes of the ECG in panel A. There are premature atrial beats (eg, complexes #5 and #13) showing little, if any, QRS widening. Selected R-R intervals are shown in milliseconds.

endocardial depolarization but, in the absence of epicardial activation, T-wave inversion was absent.

ECG analysis

The ECGs in the present case can be explained by use-dependent sodium channel blockade. Use-dependent block is supported by 3 observations. First is the difference in QRS width in the ECGs in [Figure 2A](#) and [2B](#) that were obtained within 9 minutes of each other. At a sinus cycle length that varied from approximately 700 to 800 ms, the QRS duration is approximately 100 ms. At a sinus cycle

length of approximately 560 ms, the QRS shows the broad “tombstone” pattern, especially in leads V_2 and V_3 . Second, the differences in QRS width in response to PACs in [Figure 2B](#) vs premature beats in [Figure 3](#) are consistent with use-dependent slowing of depolarization. Conduction slowing or block may result from initial slowing of phase 0 depolarization, or from depolarization during the relative refractory period of phase 3. The response to a premature beat favors the former. In [Figure 2B](#), a PAC in beats 5 and 13 remains narrow despite coupling intervals of 480 ms and 420 ms, respectively, with both following a previous sinus interval of 680 ms. In [Figure 3](#), all QRS complexes

Hospital Day 5 - 05:07:33

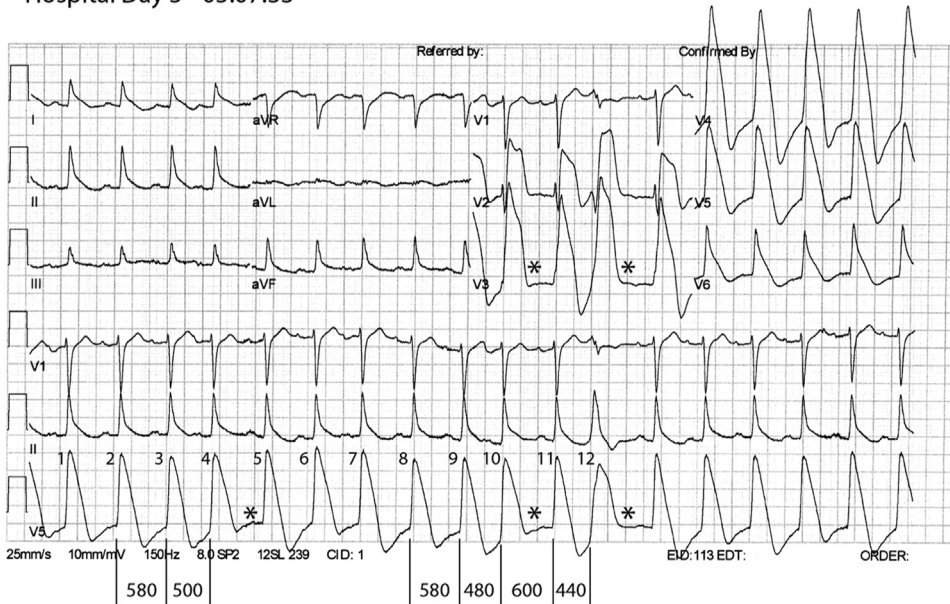


Figure 3 The electrocardiogram shows QRS complexes with a broad “tombstone” pattern, most of which are followed by apparent T-wave inversions. The sequence seen in beats 2-3-4, 8-9-10, and 10-11-12 show a “long-short” pattern of R-R intervals (intervals presented are in milliseconds). T-wave inversion is absent following the relatively premature QRS complex (*asterisks*). In a canine wedge preparation with acute coronary occlusion, T-wave inversion was demonstrated to represent delayed epicardial activation owing to transmural conduction delay caused by acute ischemia. If transmural conduction block occurred, the epicardium was not activated and T-wave inversion was absent. In the present case, rate-dependent block of I_{Na} produces transmural conduction delay leading to a wide QRS, while further rate-dependent block of I_{Na} (owing to a shorter, premature R-R interval) produces transmural conduction block that manifests as the absence of the T-wave inversion.

are wide and the intervals between beats labeled 2-3-4 and 8-9-10 are 580–500 ms and 580–480 ms, respectively. If the wide QRS complexes seen in **Figure 3** were owing to PACs impinging on the refractory period of the preceding beats, then the PACs in **Figure 2B** should also have been wide. In **Figure 2B**, the slower basic sinus rate would produce a longer refractory period than seen in **Figure 3** (sometimes referred to as reverse use dependence), and the shorter coupling interval of the PACs would have caused them to fall into the refractory period and produce wide complex PACs.

Third, use dependence is more convincingly demonstrated by premature beats in **Figure 3** that produced complete transmural conduction block from endocardium to epicardium or trans-septally, as evidenced by absent T-wave inversions. These premature beats occurred at cycle lengths that were even less likely to impinge on the refractory period than the PACs observed in **Figure 2B**. In **Figure 3** the ECG shows QRS complexes with a broad “tombstone” pattern, most of which are followed by T-wave inversions. This pattern is consistent with transmural conduction delay from endocardium to epicardium (or trans-septally). However, following a shorter R-R interval (eg, beats 2-3-4, 8-9-10, and 10-11-12; beat 12 is a premature ventricular complex), T-wave inversions are absent. The premature beat provides “additional” use-dependent block of sodium current (I_{Na}) that could produce complete transmural conduction block, as evidenced by the absence of T-wave inversion.

Likely cause of conduction slowing and block

The etiology of this patient’s conduction block was not definitively identified, but the fact that it occurred 72 hours after admission and intubation strongly favors an administered medication, since electrolytes were normal. Potential medications include DPH, propofol, and fentanyl. Although DPH levels were not measured, the dose administered was not excessive. Nevertheless, the patient could have had an idiosyncratic response to, or metabolism of, DPH. In this regard he could have a forme fruste of a channelopathy that became manifest with DPH, and it is tempting to speculate whether the seemingly benign early repolarization pattern in his baseline ECG is a marker for this potential. The ECG abnormalities resolved at a time after discontinuation of DPH that would be consistent with DPH being the causative agent. Besides blockade of histamine receptors, DPH blocks inward sodium current (I_{Na}), a property that has allowed it to be used as a local anesthetic in patients allergic to amino amide local anesthetics such as lidocaine.⁴ DPH has been reported to produce QRS widening, wide complex tachycardia, or a Brugada-pattern ECG.^{5,6} Further, DPH produces profound block of neural discharges⁷ owing to use-dependent I_{Na} blockade.⁸

Propofol is a sodium channel blocker and may produce a Brugada pattern ECG,⁹ but might have been expected to produce ECG changes shortly after intubation, and the drug was not stopped. Moreover, propofol showed only weak use-dependent block of cardiac sodium channels.¹⁰ Fentanyl was administered only intermittently. Although fentanyl has

been shown to produce use-dependent block of neuronal sodium channels¹¹, it was not shown to affect phase 0 depolarization in canine cardiac Purkinje fibers.¹² Nevertheless, it is conceivable that either drug could have potentiated an adverse effect of DPH on I_{Na} .

Other conditions that antagonize I_{Na} may produce a “pseudo-infarction” pattern on ECG. Hyperkalemia may produce a “tombstone” pattern resembling acute infarction.^{1,13} Hyperkalemia decreases the potassium gradient across the cell membrane that raises the resting membrane potential and, as a result, inactivates some fraction of sodium channels. The resulting decrease in ventricular I_{Na} slows myocardial conduction velocity, producing the wide, slurred QRS complex that is well recognized in hyperkalemia. In a similar manner to the present case or the ischemia model, transmural conduction delay caused by hyperkalemia and reduction in I_{Na} may produce the apparent ST elevation and “tombstone” ECG that mimics acute myocardial infarction.

Other models have been proposed to explain ischemic ST-segment changes,^{14,15} but detailed discussion cannot be made here. The present model is notable because the same physiologic principles appear to be applicable to ECG changes in acute infarction as well as some cases of pseudo-infarction such as drug-induced or hyperkalemia.

Conclusion

The present case describes a patient whose ECG shows transient use-dependent conduction slowing and presumed intermittent intraventricular conduction block. Conduction slowing appeared as rate-dependent QRS widening that produced a pattern simulating acute myocardial infarction. Conduction block appeared as a rate-dependent pattern of T-wave expression. The time course of events suggested that DPH antagonism of I_{Na} was responsible. We conclude that in humans certain drugs or metabolic abnormalities, such as hyperkalemia, may induce a “pseudo-infarction”

pattern on ECG in humans, most likely owing to slowing or block of transmural conduction.³

Acknowledgments

Dedicated to the memory of our colleague, Jian-Ming Li, MD, PhD, FHRS.

References

1. Wang K, Asinger RW, Marriott HJ. ST-segment elevation in conditions other than acute myocardial infarction. *N Engl J Med* 2003;349:2128–2135.
2. American Society of Hospital Pharmacists. AHFS drug information Bethesda, MD: American Society of Health-System Pharmacists; 2021.
3. Di Diego JM, Antzelevitch C. Cellular basis for ST-segment changes observed during ischemia. *J Electrocardiol* 2003;36(Suppl):1–5.
4. Pollack CV Jr, Swindle GM. Use of diphenhydramine for local anesthesia in “caine”-sensitive patients. *J Emerg Med* 1989;7:611–614.
5. Cole JB, Stellpflug SJ, Gross EA, Smith SW. Wide complex tachycardia in a pediatric diphenhydramine overdose treated with sodium bicarbonate. *Pediatr Emerg Care* 2011;27:1175–1177.
6. Sharma AN, Hexdall AH, Chang EK, Nelson LS, Hoffman RS. Diphenhydramine-induced wide complex dysrhythmia responds to treatment with sodium bicarbonate. *Am J Emerg Med* 2003;21:212–215.
7. Riccioppo Neto F. The local anesthetic effect of cyproheptadine on mammalian nerve fibres. *Eur J Pharmacol* 1979;54:203–207.
8. Kim YS, Shin YK, Lee C, Song J. Block of sodium currents in rat dorsal root ganglion neurons by diphenhydramine. *Brain Res* 2000;881:190–198.
9. Junttila M, Gonzalez M, Lizotte E, et al. Induced Brugada-type electrocardiogram, a sign for imminent malignant arrhythmias. *Circulation* 2008;117:1890–1893.
10. Stotzer C, Reuter S, Doll T, et al. Inhibition of the cardiac Na^+ channel α -subunit Nav1.5 by propofol and dexmedetomidine. *Naunyn Schmiedeberg Arch Pharmacol* 2016;389:315–325.
11. Haeseler G, Foadi N, Ahrens J, et al. Tramadol, fentanyl and sufentanil but not morphine block voltage-operated sodium channels. *Pain* 2006;126:234–244.
12. Blair JR, Pruett JK, Introna RP, Adams RJ, Balser JS. Cardiac electrophysiologic effects of fentanyl and sufentanil in canine cardiac Purkinje fibers. *Anesthesiology* 1989;71:565–570.
13. Levine HD, Wanzer SH, Merrill JP. Dialyzable currents of injury in potassium intoxication resembling acute myocardial infarction or pericarditis. *Circulation* 1956;13:29–36.
14. Li RA, Leppo M, Miki T, Seino S, Marban E. Molecular basis of electrocardiographic ST-segment elevation. *Circ Res* 2000;87:837–839.
15. MacLeod RS, Shome S, Stinstra J, Punske BB, Hoppenfeld B. Mechanisms of ischemia-induced ST-segment changes. *J Electrocardiol* 2005;38(4 Suppl):8–13.