

# Minimally Invasive Genioplasty Procedure

Nasser Nadjmi, MD, DDS, PhD,  
EFOMFS\*†‡  
Sien Van Roy, MD, DDS\*  
Elke Van de Castele, MSc, PhD\*§

**Summary:** In this technical note, we present a new surgical approach for genioplasty in which a minimally invasive procedure is used to perform the chin osteotomy. The main goal was to reduce postoperative functional recovery time and possible complications, especially reduction of lip incompetence, chin ptosis, and muscle dysfunction, by retaining the intactness of the mentalis muscles. (*Plast Reconstr Surg Glob Open* 2017;5:e1575; doi: 10.1097/GOX.0000000000001575; Published online 20 November 2017.)

## INTRODUCTION

The chin has an important role in facial harmony. Chin corrections are mainly performed for esthetic reasons. However, the functional impact such as the correction of sleep apnea due to a receding chin cannot be underestimated.<sup>1</sup>

Several techniques have been described to enhance chin appearance. Nevertheless, according to Sykes and Fitzgerald,<sup>2</sup> genioplasty is the gold standard.

Trauner and Obwegeser<sup>3</sup> were the first to describe an intraoral approach to perform a chin osteotomy. Several adjustments have been described, all with the aim to improve esthetical outcome, reduce complications and recovery time, and simplify surgical procedures.<sup>4</sup> Overall, patients who underwent genioplasty according to the standard technique with horizontal mucoperiosteal incision and transection of the mentalis may present with temporary or permanent mental nerve damage (neuro-sensory deficits), and myodysfunction (ptosis, fasciculations).<sup>5-8</sup>

The aim of the minimally invasive genioplasty (MIG) procedure presented in this article was to reduce postoperative dysfunction and recovery time and promote optimal functional recuperation of the mentalis muscles.

*From the \*Department of Maxillofacial Surgery, ZMACK, AZ MONICA Antwerpen, Antwerp, Belgium; †Department of Cranio-Maxillofacial Surgery, Antwerp University Hospital, Edegem, Belgium; ‡Faculty of Medicine & Health Sciences, University of Antwerp, Campus Drie Eiken, Antwerp, Belgium; and §All for Research vzw, Antwerp, Belgium.*

*Received for publication April 24, 2017; accepted September 29, 2017.*

*Drs. Nadjmi and Van Roy contributed equally to this work.*

*Presented at the 23rd International Conference on Oral and Maxillofacial Surgery, March 31 to April 03, 2017, Hong Kong, China.*

*Copyright © 2017 The Authors. Published by Wolters Kluwer Health, Inc. on behalf of The American Society of Plastic Surgeons. This is an open-access article distributed under the terms of the Creative Commons Attribution-Non Commercial-No Derivatives License 4.0 (CCBY-NC-ND), where it is permissible to download and share the work provided it is properly cited. The work cannot be changed in any way or used commercially without permission from the journal.*

DOI: 10.1097/GOX.0000000000001575

## TECHNIQUE

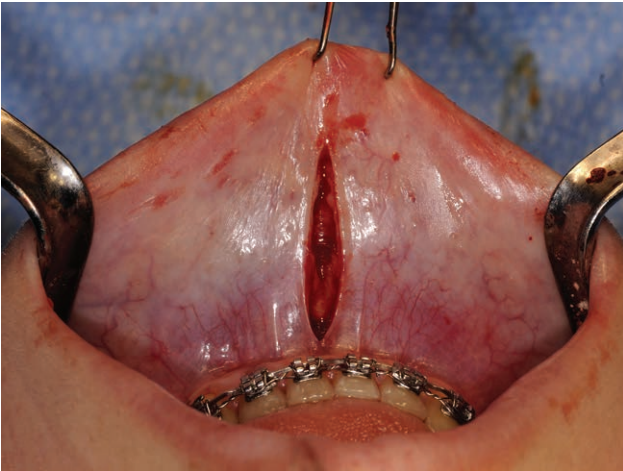
### Preoperative Procedure

When the patient is scheduled for genioplasty with or without combination of upper and/or lower jaw surgery, a cone beam computed tomography (CBCT) scan is performed to allow the surgeon to evaluate the anatomy of the jaw; the distance between the roots of the central incisors, canines, and the lower border; and the position of the mental foramen. Note that plain films are also possible for scheduling a genioplasty; however, CBCT is preferred by the first author. It gives the possibility to perform a 3D evaluation of the roots and mental nerve. In case of a combination of bimaxillary or trimaxillary surgery, all patient require a CBCT scan for 3D planning as performed in our hospital (also not obligatory).

### Surgical Intervention

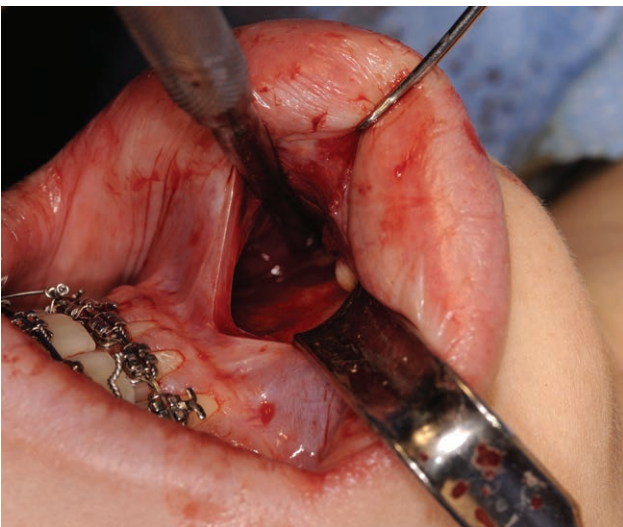
For the comfort of the patient, the surgery is performed under general anesthesia (nasotracheal intubation). Local anesthesia or sedation is not contraindicated, but our patients and the first author prefer general anesthesia. In case of an intraoperative complication, for instance a floor of mouth bleeding, general anesthesia is more comfortable to handle this problem. With the patient in a supine position with the head in a horseshoe headrest, mounted on an operating table equipped with a trapezoidal extension plate, the surgeon is able to sit close to the patient. Local anesthetic is injected in the mental region (lidocaine 10mg/ml + adrenaline 1/200,000). The facial skin is disinfected using 1% Hospital Antiseptic Concentrate and 70% ethanol. The patient is draped in a standard manner, and the oral cavity is disinfected and rinsed (2% chlorhexidine digluconate solution). The surgeon is positioned behind the head of the patient, and the lower lip mucosa is exposed by the assistants using a double skin hook placed centrally, just above the labial frenulum, and 2 small retractors. A short vertical incision is made through the lower lip frenulum, inferior to the mucogingival junction<sup>9</sup> (Fig. 1). Subsequently, a sharp in-

**Disclosure:** The authors have no financial interest to declare in relation to the content of this article. The Article Processing Charge was paid for by the authors.

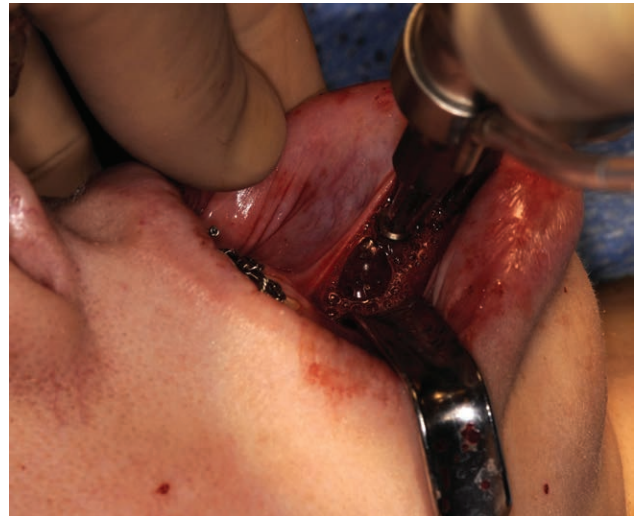

**Fig. 1.** A short vertical incision is made through the lower lip frenulum, inferior to the mucogingival junction.

cision is made through the periosteum at the midline. The surgeon is positioned on the right for the dissection of the left side and vice versa to perform subperiosteal dissection between the 2 mentalis muscles. With a dental Molt and Freer, bilateral subperiosteal dissection is performed under the mental muscles, without release or transection, toward the lower border, with identification and protection of the mental foramen and nerve (Fig. 2). While retracting both mentalis muscles, the midline of the chin is marked to provide a landmark for accurate repositioning. Subsequently, the osteotomy is commenced by marking a horizontal groove with a small Lindeman drill on both sides, from the lower border toward the midline. Care is taken to stay at a safe distance from the mental nerve and the roots of the teeth (Fig. 3). Optional, a chin hook, as used for the transmandibular midline distraction osteotomy, can facilitate the osteotomy, in this case there is no need to make the horizontal groove.<sup>10</sup> The design of the osteotomy is influenced by the esthetic re-

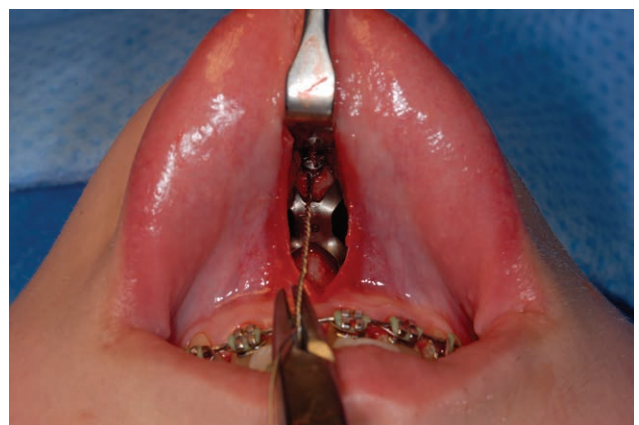

**Fig. 2.** With a dental Molt and Freer, bilateral subperiosteal dissection is performed under the mental muscles toward the lower border, with identification and protection of the mental foramen and nerve.



**Fig. 3.** After marking of the midline of the chin, the osteotomy is made with a reciprocating saw according to a groove made with a small Lindemann drill.

quirements. There are no chin wing osteotomies performed with this technique. On the other hand, transverse osteotomy (midline), impaction, and small leveling of the chin were possible to be achieved. The actual osteotomy is made with a reciprocating saw and finalized, if necessary, with a chisel. The soft-tissue lingual to the osteotomy line is probably less damaged due to a more tangential positioning of the saw. The mobility of the chin segment is checked and positioned according to the functional requirements, esthetic preferences, and physiologic possibilities. An 8mm self-taping screw is placed in the middle of the chin segment while a 0.4 metal ligature is attached and used to stabilize the segment during final fixation. Fixation of the genial segment is performed with a KLS-MARTIN 2.0mm Arnett FAB System chin plate and 4x6mm self-taping screws. Subsequently, the 8mm screw and ligature are removed (Fig. 4). After intraoperative evaluation of the chin shape, the wound is closed in 2 layers.



**Fig. 4.** An 8mm self-taping screw is placed in the middle of the chin segment while a 0.4 metal ligature is attached and used to stabilize the segment during final fixation. Fixation of the genial segment performed with a KLS-MARTIN 2.0mm Arnett FAB System chin plate and 4x6mm self-taping screws. The 8mm screw and ligature are removed after fixation.

The reapproximation of the periosteal incision is performed with 4-0 Maxon sutures, and the mucosa is closed using a fine braided 6-0 absorbable suture. A pressure bandage is placed on the skin and removed 1 week postoperatively.

#### Postoperative Procedure

Medication consisting of painkillers, an antiseptic mouthwash, and an antibiotic is prescribed for the first 5 postoperative days. The patient is discharged after 1 night in the hospital. The pressure bandage is removed 1 week after surgery.

### DISCUSSION

Lindquist and Obeid<sup>11</sup> reported an altered sensation of the lower lip as 1 complication of genioplasty. Other complications noted were abnormal response to electric pulp testing of the front teeth, increase in lower teeth show, unsatisfactory scar at the incision line, a notch at the osteotomy site, lower lip incompetence, retraction, and chin ptosis due to muscle dysfunction.<sup>6,7,12</sup>

In the presented approach, the vertical incision through the lower lip frenulum leaves a short and inconspicuous scar in the midline.<sup>9,10</sup> The mentalis muscles are kept intact, eliminating possible myodysfunction. The advantages of this technique above alloplastic implants are those of a standard genioplasty: no foreign body, effective in correcting vertical or transverse deformities of the mentum, not limited in size and shape, no bone resorption resulting from the implant, and so on.<sup>2,13</sup> This combined with the vertical incision as first described by Aynehchi et al.<sup>9</sup> as a new technique for alloplastic chin implants form the advantages of the presented MIG technique.

Until December 2015, the first author used the standard technique with a high labial incision. From January 2016 on, he started to perform genioplasties (with or without combination of Le Fort I and/or BSSO) according to the MIG technique. His preliminary results showed better postoperative recuperation and better overall functional outcome using this technique compared with the standard technique. These observations can be related to intact mentalis muscles. Transection, as performed in the standard genioplasty, destroys the muscle tissue in total, requiring a huge regenerative process leading to dysfunctional scar tissue. When the epimysium and/or intramuscular nerve are transected, repair is essential in recuperation of the mechanical and functional properties of the muscle. Suturing of the muscles promotes repair but does not prevent the formation of dense fibrotic scar tissue, leading to incomplete muscle recovery.<sup>14</sup> Since January 2016, around 55 patients have been treated according to the MIG technique, video data together with 3D imag-

ing, pre- and postoperatively, confirm the good preliminary results. Given the knowledge about muscle repair,<sup>14</sup> together with our preliminary clinical results, we think that this minimally invasive technique for genioplasty is a promising approach to perform a chin osteotomy. To objectivate and quantify these results, a prospective study has been started to compare the standard genioplasty and MIG technique.

Nasser Nadjmi, MD, DDS, PhD, EFOMFS

Harmoniestraat 68

2018 Antwerp

Belgium

E-mail: nasser@nadjmi.com

### REFERENCES

1. Song SA, Chang ET, Certal V, et al. Genial tubercle advancement and genioplasty for obstructive sleep apnea: a systematic review and meta-analysis. *Laryngoscope*. 2017;127:984–992.
2. Sykes JM, Fitzgerald R. Choosing the best procedure to augment the chin: is anything better than an implant? *Facial Plast Surg*. 2016;32:507–512.
3. Trauner R, Obwegeser H. The surgical correction of mandibular prognathism and retrognathia with consideration of genioplasty. I. Surgical procedures to correct mandibular prognathism and reshaping of the chin. *Oral Surg Oral Med Oral Pathol*. 1957;10:677–689; contd.
4. Ferretti C, Reyneke JP. Genioplasty. *Atlas Oral Maxillofac Surg Clin North Am*. 2016;24:79–85.
5. Richard O, Ferrara JJ, Cheynet F, et al. [Complications of genioplasty]. *Rev Stomatol Chir Maxillofac*. 2001;102:34–39.
6. White JB, Dufresne CR. Management and avoidance of complications in chin augmentation. *Aesthet Surg J*. 2011;31:634–642.
7. Altiparmak N, Akdeniz BS, Akdeniz SS, et al. Changes in the lower lip soft tissue after bone graft harvesting from the mandibular symphysis. *Int J Oral Maxillofac Surg*. 2017;46:129–133.
8. Warren SM, Spector JA, Zide BM. Chin surgery V: treatment of the long, nonprojecting chin. *Plast Reconstr Surg*. 2007;120:760–768.
9. Aynehchi BB, Burstein DH, Parhiscar A, et al. Vertical incision intraoral silicone chin augmentation. *Otolaryngol Head Neck Surg*. 2012;146:553–559.
10. Nadjmi N, Stevens S, Van Erum R. Mandibular midline distraction using a tooth-borne device and a minimally invasive surgical procedure. *Int J Oral Maxillofac Surg*. 2015;44:452–454.
11. Lindquist CC, Obeid G. Complications of genioplasty done alone or in combination with sagittal split-ramus osteotomy. *Oral Surg Oral Med Oral Pathol*. 1988;66:13–16.
12. Jones BM, Vesely MJ. Osseous genioplasty in facial aesthetic surgery—a personal perspective reviewing 54 patients. *J Plast Reconstr Aesthet Surg*. 2006;59:1177–1187.
13. Frodel JL, Sykes JM. Chin augmentation/genioplasty: chin deformities in the aging patient. *Facial Plast Surg*. 1996;12:279–283.
14. Jaqueline dS, Carmem G. Muscle injury: review of experimental models. *J Electromyogr Kinesiol*. 2013;23:6, 1253–1260.