

Bronchial Blocker and Double-Lumen Endotracheal Tube Combination to Facilitate Lung Isolation during Esophagectomy

Hong Liang, Mathew Thomas¹, J. Ross Renew

Departments of Anesthesiology and Perioperative Medicine, and ¹Cardiothoracic Surgery, Mayo Clinic Florida, FL, USA

ABSTRACT

Lung isolation is an essential anesthetic technique utilized in thoracic surgeries. We present a patient undergoing esophagectomy that developed an iatrogenic injury to the left mainstem bronchus that damaged the bronchial cuff of a left-sided double-lumen endotracheal tube (DLETT). A bronchial blocker (BB) was placed in the tracheal lumen of the DLETT as a rescue method to facilitate continued lung isolation. This unusual combination of a DLETT and a BB proved useful once the bronchial cuff was compromised and may serve as a viable solution to maintain lung isolation in similar circumstances.

Keywords: Bronchial blocker, double-lumen endotracheal tube, esophagectomy, one-lung ventilation

Address for correspondence: Dr. Hong Liang, Mayo Clinic Florida, 4500 San Pablo Road, Jacksonville, FL, USA.

E-mail: liang.hong@mayo.edu

Submitted: 15-Sep-2020 **Revised:** 04-Jul-2021 **Accepted:** 12-Jul-2021 **Published:** 11-Apr-2022

INTRODUCTION

Lung isolation techniques have been traditionally used in lung resection, esophageal, aortic, and thoracic spine surgeries. As minimally invasive thoracic and upper-gastrointestinal surgeries increase, the use of one-lung ventilation (OLV) remains an essential role in anesthetic management. Despite adequate lung isolation, these surgeries can still prove to be challenging. Surgical-related open esophagectomy complication rates are reported to be more than 50%. Rarely, iatrogenic airway trauma can occur in 0.2–2% of the cases.^[1] We report the successful OLV using a DLETT in combination with a bronchial blocker (BB) after the left mainstem bronchus, and the bronchial cuff of the DLETT were compromised during esophageal surgery.

CASE DESCRIPTION

A 48-year-old male (height 180 cm, weight 96.6 kg, BMI 29.8) presented for a robotic-assisted esophagectomy (Ivor Lewis procedure) for an advanced biopsy-proven leiomyosarcoma at the gastroesophageal junction. His medical history was significant for coronary artery disease status post-cardiac stents and type 2 diabetes mellitus.

The preoperative airway exam was reassuring with a Mallampati 2 and 3 finger thyromental distance. During the operation, standard American Society Anesthesiology monitors were placed, including a radial arterial catheter. The induction of anesthesia was uneventful, and a 37 Fr left-sided DLETT was successfully placed. The position was confirmed by fiberoptic bronchoscopy. The patient was laid supine for the abdominal component of the

Access this article online

Quick Response Code:



Website:

www.annals.in

DOI:

10.4103/aca.aca_236_20

This is an open access journal, and articles are distributed under the terms of the Creative Commons Attribution-NonCommercial-ShareAlike 4.0 License, which allows others to remix, tweak, and build upon the work non-commercially, as long as appropriate credit is given and the new creations are licensed under the identical terms.

For reprints contact: WKHLRPMedknow_reprints@wolterskluwer.com

How to cite this article: Liang H, Thomas M, Renew JR. Bronchial blocker and double-lumen endotracheal tube combination to facilitate lung isolation during esophagectomy. *Ann Card Anaesth* 2022;25:214-6.

surgery, and the surgeon was able to resect the esophagus and tumor uneventfully. The patient was then repositioned to the left lateral decubitus position to facilitate the intrathoracic component of the operation. The tracheal lumen of the DLETT was clamped, and the patient's left lung was selectively ventilated. The right lung collapsed and provided exposure for the robotic surgery. After struggling with adhesions, the surgical team converted from a robotic approach to video-assisted thorascopic surgery (VATS) to improve exposure.

During the dissection of the lymph nodes next to the left main bronchus, a small perforation was inadvertently created at the posterior membrane of the left main bronchus that also compromised the DLETT's bronchial cuff [Figure 1a]. To repair this lesion, the surgical team converted from VATS to an open thoracotomy. With the patient still in the left decubitus position, a posterior lateral incision was made on the patient's right chest.

The left lung needed to be isolated and deflated to provide adequate operative space to repair the lesion. However, this proved impossible with the torn bronchial cuff. To solve this challenging airway dilemma, the DLETT was retracted so that both the lumens rested in the trachea [Figure 1b]. A 9 Fr Arndt bronchial blocker (Cook Medical; Bloomington, IN) was placed through the tracheal lumen of the DLETT with the help of a 2.8 mm pediatric fiberoptic bronchoscope. This smaller bronchoscope allowed for significant maneuverability while visualizing the relevant anatomy. The bronchial blocker required significant manipulation as placing it too distally could leave the cuff vulnerable to additional surgical compromise. Placing the bronchial blocker too proximally could fail to

achieve lung isolation and potentially preclude ventilating either lung. After some manipulation, the bronchial blocker was successfully placed in the left main bronchus, just proximal to the injury. The left lung was successfully isolated and deflated [Figure 1c and 2].

After successfully repairing the left mainstem bronchus and concluding the operation, the BB was removed, and the DLETT was exchanged for a single lumen ETT. The patient was sent to the intensive care unit for further monitoring. He was successfully extubated the next day. Although a small anastomotic leak complicated his postoperative course, he was discharged 3 weeks postoperatively. He has since returned to work and is currently cancer-free.

DISCUSSION

The OLV technique is usually achieved by a DLETT or a single-lumen ETT in combination with a BB. The final positioning of these devices is confirmed with fiberoptic bronchoscopy. DLETT is utilized more frequently than BB as this technique provides several advantages. First, DLETT is generally easier to place than a BB. Narayanaswamy *et al.*^[2] compared the time from the start of laryngoscopy until achieving lung isolation with either DLETT or 1 of the 3 BBs from various manufacturers. The time to achieve lung isolation with a DLETT was significantly shorter (93 ± 62 s) than with a BB (203 ± 132 s). Additionally, the DLETT required much less repositioning than the bronchial blockers. Another advantage of DLETT is that these devices have a larger diameter that can allow for the passage of tools such as a fiberoptic bronchoscope or suction catheter. A DLETT allows the anesthesiologist to safely collapse and inflate the lung as often as needed during the surgery while a BB can achieve lung isolation but with a greater risk of balloon migration.

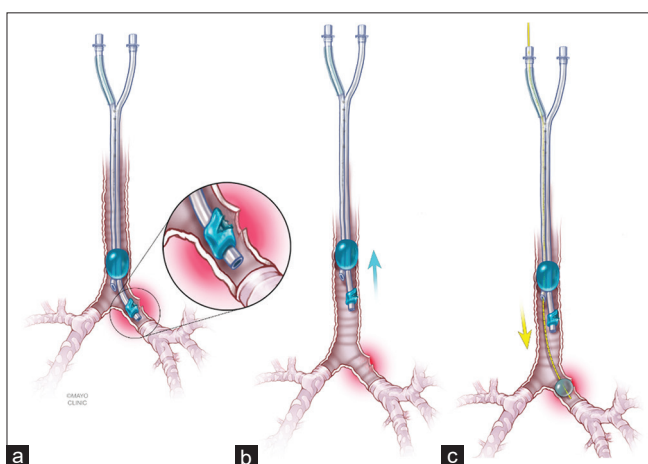


Figure 1: (a) A perforation was created at the posterior membrane of the left main bronchus that also compromised the DLETT's bronchial cuff; (b) The DLETT was retracted, both lumens rested in the trachea; (c) A 9 French BB was placed through the tracheal lumen of the DLETT

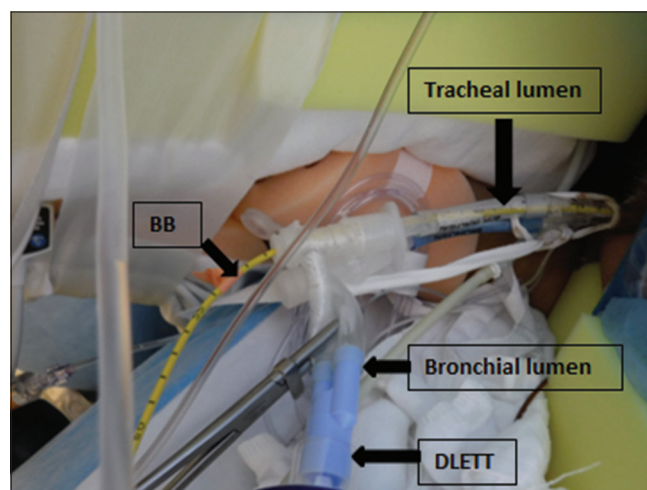


Figure 2: BB inserted in the tracheal lumen of DLETT

Depending on the location of the bronchial lumen, DLETTs can either be left-sided or right-sided in nature. Due to the anatomical difference between the left and the right mainstem bronchus, a left-sided DLETT is most commonly used in the majority of elective thoracic procedures. A left-sided DLETT is easier to place and has a higher margin of safety.^[3] Nonetheless, the right-sided DLETT may be used for surgery involving the left mainstem bronchus or when the anatomy of the left mainstem bronchus is distorted.^[4] Common complications of DLETT are airway trauma during placement or over-inflation of the bronchial cuff.^[5]

As BBs can prove more challenging to place and require more manipulation, these devices are typically selected in patients with a difficult airway, the presence of a tracheostomy, and scenarios requiring lung isolation when a single lumen endotracheal tube has already been placed. Although these devices are less frequently used than DLETT, BBs do offer some advantages. BBs can selectively collapse only a single lobe rather than an entire lung—a technique that cannot be achieved with a DLETT. Also, BBs are associated with less airway trauma due to the smaller dimension when compared to DLETTs.^[6]

The combination of a DLETT with a BB has been reported in several case reports. Beam *et al.*^[7] placed a DLETT to isolate the right lung for right lobectomy; however, the lung isolation was inadequate and a BB was inserted into the DLETT to achieve lung isolation. Capdeville *et al.*^[8] utilized a Fogarty catheter through the bronchial lumen of a DLETT when it was discovered that the patient's left main bronchus was too small to accept a bronchial lumen of the DLETT. Additionally, the combination of BB and DLETT has been utilized to prevent spillage of the infectious organism from one lung into the other during lobectomy.^[9]

Indeed, BBs and DLETTs have their specific risks, benefits, and clinical indications. The combined use of a DLETT and a BB is not a common practice; however, this combination proved very useful during an operation in which the bronchial cuff and left mainstem bronchus were damaged. This unusual combination allowed for the

maintenance of lung isolation at a critical point and may be considered a viable option as a rescue technique.

Declaration of patient consent

The authors certify that they have obtained all appropriate patient consent forms. In the form the patient(s) has/have given his/her/their consent for his/her/their images and other clinical information to be reported in the journal. The patients understand that their names and initials will not be published and due efforts will be made to conceal their identity, but anonymity cannot be guaranteed.

Financial support and sponsorship

Nil.

Conflicts of interest

There are no conflicts of interest.

REFERENCES

1. Herbella FA. Esophagectomy perianesthetic care from a surgeons point of view. *SOJ Anesthesiol Pain Manag* 2014;1:1-7.
2. Narayanaswamy M, McRae K, Slinger P, Dugas G, Kanellakos GW, Roscoe A, *et al.* Choosing a lung isolation device for thoracic surgery: A randomized trial of three bronchial blockers versus double-lumen tubes. *Anesth Analg* 2009;108:1097-101.
3. Benumof JL, Partridge BL, Salvatierra C, Keating J. Margin of safety in positioning modern double-lumen endotracheal tubes. *Anesthesiology* 1987;67:729-38.
4. Campos JH, Gomez MN. Pro: Right-sided double-lumen endotracheal tubes should be routinely used in thoracic surgery. *J Cardiothorac Vasc Anesth* 2002;16:246-8.
5. Knoll H, Ziegeler S, Schreiber JU, Buchinger H, Bialas P, Semyonov K, *et al.* Airway injuries after one-lung ventilation: A comparison between double-lumen tube and endobronchial blocker: A randomized, prospective, controlled trial. *Anesthesiology* 2006;105:471-7.
6. Bauer C, Winter C, Hentz JG, Ducrocq X, Steib A, Dupeyron JP. Bronchial blocker compared to double-lumen tube for one-lung ventilation during thoracoscopy. *Acta Anaesthesiol Scand* 2001;45:250-4.
7. Beam MR, Bader SO. Failure of lung isolation by a double-lumen endotracheal tube rescued by the concomitant use of an arndt bronchial blocker under direct visualization. *A Case Rep* 2013;1:37-8.
8. Capdeville M, Hall D, Koch CG. Practical use of a bronchial blocker in combination with a double-lumen endotracheal tube. *Anesth Analg* 1998;87:1239-41.
9. Matsunami S, Komasa N, Minami T. Combination of a double-lumen tracheal tube and bronchial blocker for a patient with continuous bleeding due to invasive lung infection. *J Clin Anesth* 2015;27:430-1.