

# A case series and review of the literature regarding coronary artery complications associated with coronary sinus catheter ablation



Paul J. Garabelli, MD, FHRS, Stavros Stavrakis, MD, PhD, Sunny S. Po, MD, PhD

From the University of Oklahoma Health Sciences Center, Heart Rhythm Institute, Oklahoma City, Oklahoma.

## Introduction

Catheter ablation of atrioventricular nodal reentrant tachycardia (AVNRT) and atrioventricular reentrant tachycardia is an established procedure with a high success rate, but procedure-related complications are not rare.<sup>1</sup> One of the feared complications is coronary injury, the frequency of which is estimated to be  $\leq 1\%$ . We have recently shown that the risk of coronary artery injury is especially high when ablating in the coronary sinus (CS) branches, such as the middle cardiac vein (MCV), and the risk correlates inversely with the distance from the ideal ablation site in the CS to the coronary artery. If this distance is  $< 2$  mm, the risk of coronary artery injury is as high as 50%.<sup>2</sup> Understanding the relationship between coronary arteries and the CS is essential to avoid this complication. We describe 2 cases in which ablation in a presumed safe area resulted in coronary injury.

## Case reports

### Case 1

A 17-year-old white male presented to our institution with severely symptomatic tachycardia refractory to medical therapy. During electrophysiology study, AVNRT was induced and targeted for ablation. A magnetic navigation catheter (Stereotaxis, St. Louis, MO) in an SR-0 sheath was used to create a CARTO map (Biosense Webster; Johnson and Johnson, New Brunswick, NJ) and to perform the ablation. A CS venogram was not performed.

In all, 3 separate radiofrequency (RF) applications at 25 W were delivered. The lesions started at the inferior triangle

**KEYWORDS** Atrioventricular nodal reentrant tachycardia; Atrioventricular reentrant tachycardia; Coronary sinus; Catheter ablation; Myocardial infarction

**ABBREVIATIONS** AP = accessory pathway; AV = atrioventricular; AVN = atrioventricular node; AVNRT = atrioventricular nodal reentrant tachycardia; CS = coronary sinus; ECG = echocardiogram; LA = left atrium; MCV = middle cardiac vein; RCA = right coronary artery; RF = radiofrequency (Heart Rhythm Case Reports 2015;1:315–319)

**Conflicts of Interest:** The authors report no conflicts of interest.  
**Address reprint requests and correspondence:** Dr Paul Garabelli, University of Oklahoma Health Sciences Center, Heart Rhythm Institute, 1200 Everett Drive, Room 6E103, Oklahoma City, OK 73104. E-mail address: paul-garabelli@ouhsc.edu.

of Koch and continued by gradually pulling the catheter toward the CS ostium, at a level of the middle CS ostium. Junctional beats were seen during the RF applications closer to the CS ostium. During the third RF application, the ablation catheter suddenly moved inferiorly, possibly into the MCV. RF energy was stopped soon after catheter movement was noted. As seen in his echocardiogram (ECG), ST elevation developed in the inferior leads (aVF, III) shortly after this RF application (Figure 1A). Reduction of his clinical arrhythmia was not attempted secondary to the presence of ST elevation. Of note, during ablation, only leads I, II, and V1 were monitored at a paper speed of 200 mm/s and ST elevation was not appreciated during RF application.

The patient was immediately transferred to the cardiac catheterization laboratory. Access was obtained via the radial artery. The right coronary artery (RCA) was angiographically dominant, and the RCA and right posterior descending artery were both normal. At the ostium of the right posterior-lateral, there was a complete occlusion, as shown in Figure 1B. Aspiration thrombectomy did not retrieve significant thrombus, and a 2 × 18-mm bare metal stent was deployed. The final angiographic result was excellent, with TIMI-3 flow, as seen in Figure 1C. A transthoracic echocardiogram performed the day after ablation revealed normal systolic function and mild hypokinesis of the inferior myocardium. The patient was discharged on acetylsalicylic acid for life and clopidogrel for 30 days. At 14 months of follow-up, he has had no clinical tachycardia recurrence or chest discomfort.

### Case 2

A 39-year-old white female with preexcitation presented to our institution after 2 previous unsuccessful ablations. A CS angiogram, performed at the start of our case, did not reveal any abnormalities. Through mapping of the right atrium during ventricular pacing, the accessory pathway (AP) was identified near the roof of the CS, approximately 1.5 cm from the ostium, which is generally thought not to be a high-risk area for coronary artery injury. We monitored antegrade preexcitation during RF application, and ablation at this site eliminated conduction in 1 second. Considering the patient's history of 2 previous failed ablations and the

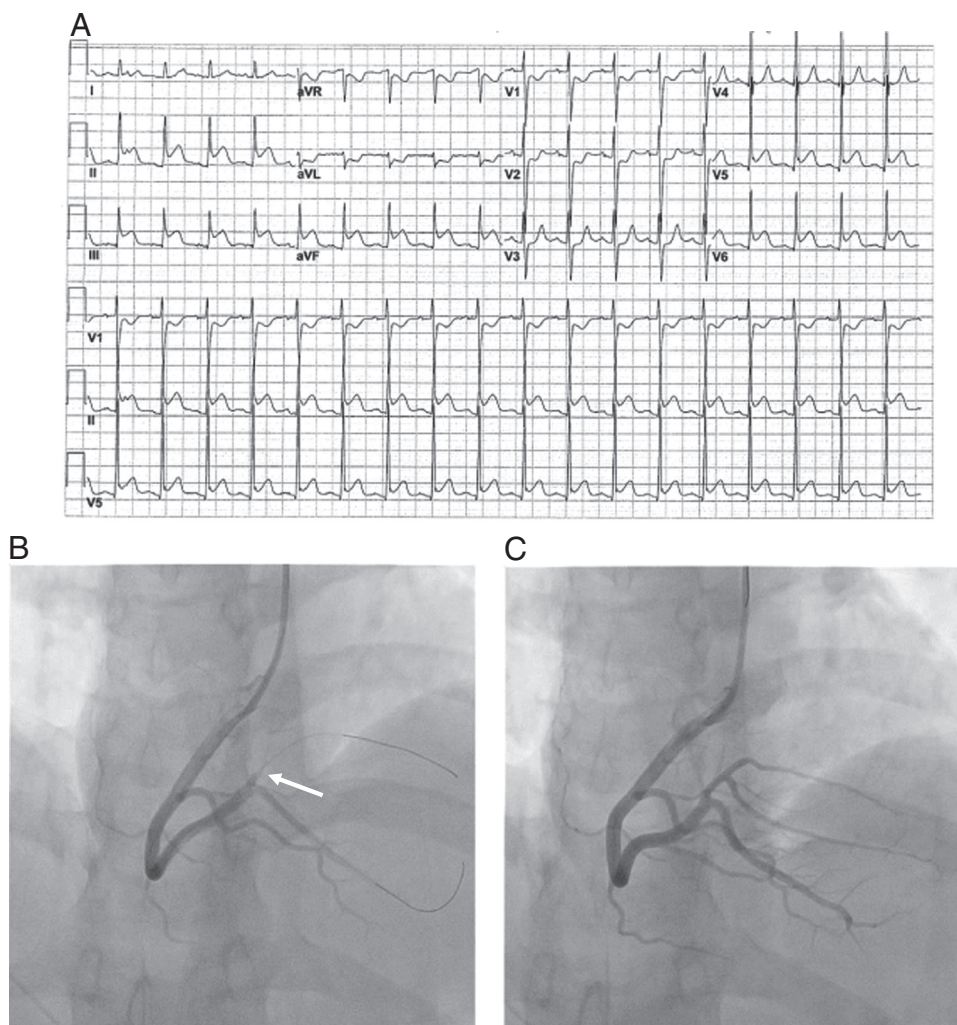
### KEY TEACHING POINTS

- Variations in coronary artery dominance and the relationship to the coronary sinus can lead to unexpected injury to a coronary artery during coronary sinus ablation. Maintaining alertness during coronary sinus radiofrequency application is critical.
- Monitoring the relevant surface electrocardiographic leads during ablation at a sweep speed of 25 mm/s in addition to monitoring of the 12-lead electrocardiogram immediately after ablation are 2 simple measures that can prevent dramatic complications.
- Performing a coronary angiogram on every patient undergoing coronary sinus ablation is excessive, tipping the risk-benefit ratio the other direction.

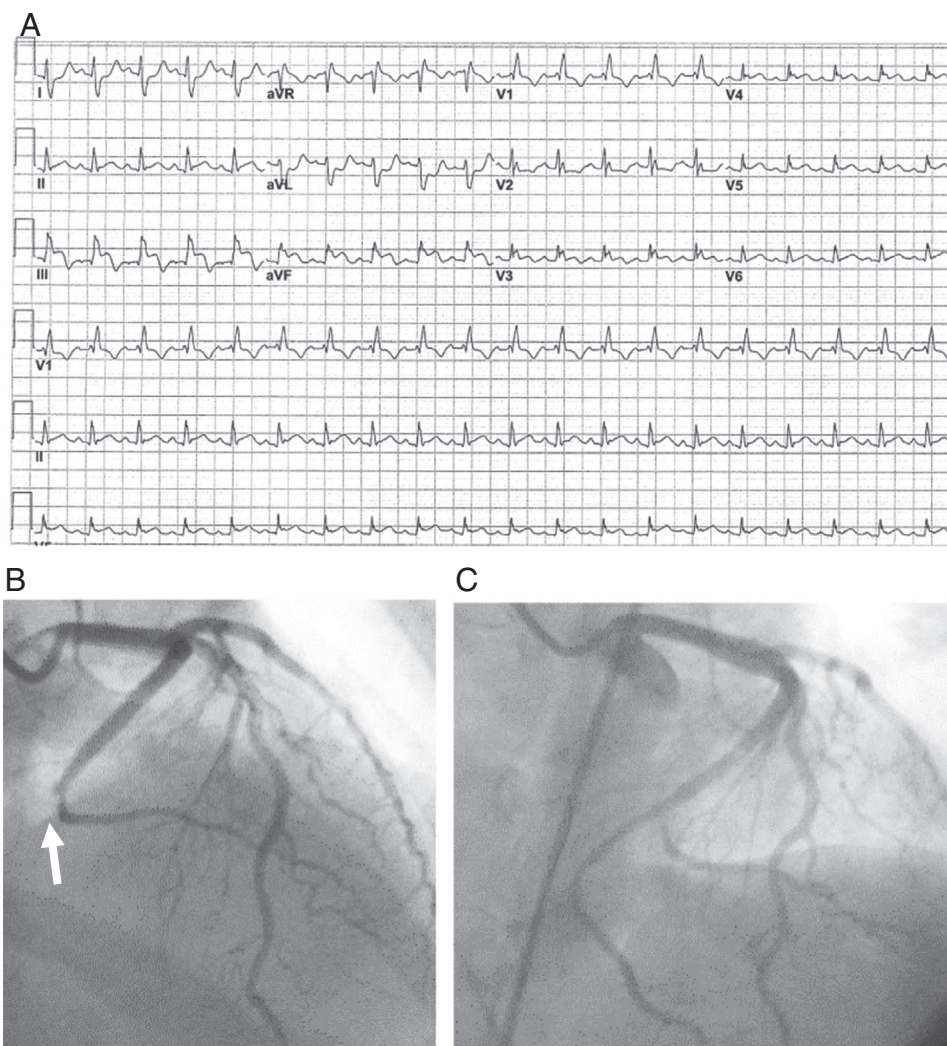
pathway slant, we elected to perform additional RF applications. 2 additional lesions were site. placed more

distal and proximal to the original A fourth application was applied to the ventricular end of the AP, at the level of mid CS ostium. Shortly after the third ablation, ST elevation was noted in the inferior leads (**Figure 2A**), and a coronary angiogram was performed via the radial artery. Of note, during ablation, only leads I, II, and V1 were monitored at a paper speed of 200 mm/s, and ST elevation was not appreciated.

An angiogram showed the RCA, left main coronary artery, and left anterior descending artery to be normal. The left circumflex was dominant. At the ostium of the second obtuse marginal, there was a 100% occlusion, as shown in **Figure 2B**. Because aspiration thrombectomy was nonproductive, a balloon and a bare metal stent resulted in TIMI-3 flow, as shown in **Figure 2C**. A transthoracic echocardiogram revealed normal systolic function with hypokinesia of the basal inferolateral and inferior myocardium. The patient was discharged on acetylsalicylic acid for life and ticagrelor for 1 year. At 15 months of follow-up, she has had no tachycardia recurrence or chest pain.



**Figure 1** A: Case 1 postablation electrocardiogram showing inferior ST elevation. B: Angiogram of right coronary artery before intervention of right posterolateral branch, with an arrow marking the occlusion and location of ablation. C: Angiogram after intervention.



**Figure 2** A: Case 2 postablation electrocardiogram showing inferior ST elevation. B: Angiogram of left circumflex dominant coronary system, before intervention, with an arrow marking the occlusion. C: Angiogram after intervention to the second obtuse marginal.

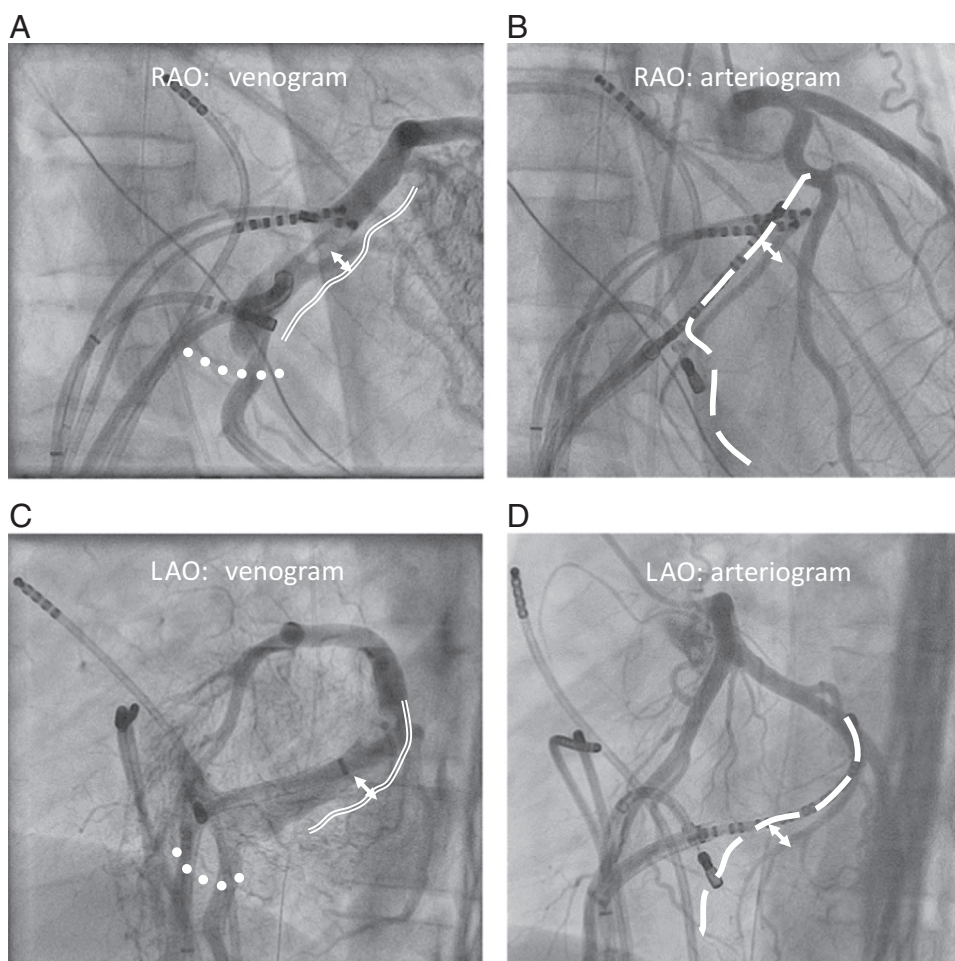
## Discussion

Understanding the relationship of the coronary arteries to the CS is critical during ablation. The left circumflex artery is located on the epicardial surface of the atrioventricular groove, near the CS. The CS is usually situated more atrial to the atrioventricular groove, as shown in Figure 3, with only 16% of cases in the “normal” atrioventricular (AV) groove position. Figures 3A and 3B show this relationship with a venogram and arteriogram in the right anterior oblique projection. Figures 3C and 3D show this in the left anterior oblique projection. The more atrial CS path varies: 1–3 mm above the AV groove is seen in 12% of patients, a moderate elevation (4–7 mm) in 50%, and an extreme elevation (8–15 mm) in 22%. As the left cardiac chambers and mitral annulus dilate, the CS shifts toward the ventricular part of the mitral valve annulus.<sup>3</sup>

Two previous studies searched for coronary artery injury and found the incidence of ablation-related coronary injury to be 1%.<sup>4,5</sup> Retrospective and prospective registries have reported coronary artery injury from ablation as low as 0.06%–0.1% in adults and 0.03% in children.<sup>6–8</sup> The

underlying mechanism for injury is not completely understood. Transient thermal irritability resulting in coronary spasm appears to be the primary mechanism, and this stenosis can be relieved with intracoronary glycerine trinitrate in 100% of patients, as described in a recent study.<sup>9</sup> However, an additional inflammatory component may exist. As noted in reports of animal experiments, the inflammatory component may result in delayed medial necrosis and intimal hyperplasia causing late stenosis.<sup>10</sup> Unfortunately, the risk factors that predispose patients to coronary artery injury are not completely defined. One proposed hypothesis is that vessels <3 mm in diameter do not have the protection of the heat-sink effect, making them more vulnerable to RF heat and therefore injury. Certain procedural situations, by virtue of the targeted site for ablation, may also increase this risk. These scenarios include linear ablation within the CS, epicardial posteroseptal APs, and ablation of AVNRT.

Linear ablation within the CS to create an LA isthmus line may lead to circumflex artery injury. Longstanding persistent atrial fibrillation with perimitral flutter is a common form of LA macroreentry. Procedural success usually requires



**Figure 3** A and B: Right anterior oblique (RAO) 30° views of a venogram and arteriogram demonstrating the relationship of the coronary sinus/middle cardiac vein (broken line), left circumflex artery (solid double line), and posterior descending artery (dots). The arrow shows the atrial aspect of the CS. C and D: The same procedures viewed at left anterior oblique (LAO) 50°.

additional ablation within the CS to either terminate the tachycardia or create an LA isthmus block, often necessitating extension ablation. Wong et al<sup>9</sup> found that 28% of their patients had circumflex artery angiographic changes post ablation, when compared with preprocedure coronary angiograms. Of note, 33% of these patients had a significant response to intracoronary glycerine trinitrate. Makimoto et al<sup>11</sup> reported a case of delayed incessant ventricular tachycardia >40 hours after the creation of an LA isthmus line in the coronary venous system.

Coronary injury may result from ablation of epicardial posteroseptal APs that used part of the CS muscle for conduction. The ablation target, where the ventricular end of the epicardial AP is located, is often within a tributary of the CS, the MCV, or the neck of a CS diverticulum. Stavrakis et al<sup>2</sup> reviewed results of 240 patients with such pathways and their preablation coronary angiograms. They found an inverse correlation between the risk of coronary artery injury and the distance from the ablation site, with a 50% risk if the target was within 2 mm of the artery.

Ablation of AVNRT can also lead to coronary artery injury. The atrioventricular node (AVN) artery is the primary blood supply to the AVN as well as the His bundle. The

posterior descending and posterolateral left ventricular branches also supply the inferior aspect of the interventricular septum. Arterial supply varies with dominance of the coronary circulation. In approximately 85% of patients in whom the circulation is right dominant, the AVN artery is supplied by a branch of the RCA. In patients who have left-dominant circulation, the AVN artery originates from the left circumflex artery.<sup>12</sup> The AVN artery usually ends as single vessel, with the remainder being shaped like a fork or as a double-stranded vessel. Lin et al<sup>13</sup> studied the risk of AV block during slow pathway ablation for AVNRT using coronary angiography either before or after ablation. Irrespective of other common electrophysiology signals, they found that an ablation distance of <2 mm to the distal end of the AV nodal artery almost always caused suprahisian block.

This case series exposes the inherent dangers to the coronary circulation when RF energy is delivered within or near the CS, especially when the targeted area is thought to be safe. Multiple ablation procedures may increase the risk of damage to coronary arteries, but this relationship has not been studied specifically. In our institute, coronary angiography is performed in patients when the ablation target may be near the coronary artery, especially if it is located in the MCV or at the

floor of the proximal CS. However, coronary angiograms are not performed on every patient when the ablation target is located at the CS ostium, such as with AVNRT.

Performing preablation angiograms on every patient in such cases seems excessive. Diagnostic cardiac catheterization is safe, with a complication rate from death, myocardial infarction, or major embolization that is well below 1%.<sup>14</sup> In centers that perform high-volume radial access, vascular complications are reduced even further.<sup>15</sup> Although there are no data specifically addressing preablation angiograms, or even cardiac computed tomography scans, when ablation within the CS is contemplated, specific pros (noninvasive, well-defined anatomy) and cons (contrast load, increased radiation exposure) of each approach will need to be evaluated by the physician for each patient. Regardless, an understanding of coronary artery variances in relation to the CS is essential, especially when ablation within the coronary sinus may be required.

## Conclusion

Keeping a high degree of suspicion for coronary artery injury with CS RF application is highly recommended. Checking relevant ECG leads for ST changes at a sweep speed of 25–100 mm/s during an ablation may not be feasible in all patients, such as when AV conduction is being monitored. However, checking a 12-lead ECG immediately after ablation is a critical step that can diagnose ST changes and possibly prevent dramatic complications. Performing imaging of the coronary circulation on every patient undergoing CS ablation, whether with a cardiac computed tomography scan or with a diagnostic catheterization, may be unnecessary and should be individualized for each case.

## References

1. Jackman WM, Beckman KJ, McClelland JH, et al. Treatment of supraventricular tachycardia due to atrioventricular nodal reentry, by radiofrequency catheter ablation of slow-pathway conduction. *N Engl J Med* 1992;327:313–318.
2. Stavrakis S, Jackman WM, Nakagawa H, Sun Y, Xu Q, Beckman KJ, Lockwood D, Sherlag BJ, Lazzara R, Po SS. Risk of coronary artery injury with radiofrequency ablation and cryoablation of epicardial posteroseptal accessory pathways within the coronary venous system. *Circ Arrhythm Electrophysiol* 2014;7:113–119.
3. Auricchio A, Singh J, Rademakers FE, eds. *Cardiac Imaging in Electrophysiology*. London: Springer; 2012.
4. Schneider HE, Kriebel T, Gravenhorst VD, Paul T. Incidence of coronary artery injury immediately after catheter ablation for supraventricular tachycardias in infants and children. *Heart Rhythm* 2009;6:461–467.
5. Solomon AJ, Tracy CM, Swartz JF, Reagan KM, Karasik PE, Fletcher RD. Effect on coronary artery anatomy of radiofrequency catheter ablation of atrial insertion sites of accessory pathways. *J Am Coll Cardiol* 1993;21:1440–1444.
6. Scheinman MM, Huang S. The 1998 NASPE prospective catheter ablation registry. *Pacing Clin Electrophysiol* 2000;23:1020–1028.
7. Kugler JD, Danford DA, Houston K, Felix G. Radiofrequency catheter ablation for paroxysmal supraventricular tachycardia in children and adolescents without structural heart disease. *Pediatric EP Society, Radiofrequency Catheter Ablation Registry*. *Am J Cardiol* 1997;80:1438–1443.
8. Calkins H, Langberg J, Sousa J, el-Atassi R, Leon A, Kou W, Kalbfleisch S, Morady F. Radiofrequency catheter ablation of accessory atrioventricular connections in 250 patients. Abbreviated therapeutic approach to Wolff-Parkinson-White syndrome. *Circulation* 1992;85:1337–1346.
9. Wong KC, Lim C, Sadarmin PP, Jones M, Qureshi N, De Bono J, Rajappan K, Bashir Y, Betts TR. High incidence of acute sub-clinical circumflex artery 'injury' following mitral isthmus ablation. *Eur Heart J* 2011;32:1881–1890.
10. Bokenkamp R, Wibbelt G, Sturm M, Windhagen-Mahnert B, Bertram H, Hausdorf G, Paul T. Effects of intracardiac radiofrequency current application on coronary artery vessels in young pigs. *J Cardiovasc Electrophysiol* 2000;11:565–571.
11. Makimoto H, Zhang Q, Tilz RR, Wissner E, Cuneo A, Kuck KH, Ouyang F. Aborted sudden cardiac death due to radiofrequency ablation within the coronary sinus and subsequent total occlusion of the circumflex artery. *J Cardiovasc Electrophysiol* 2013;24:929–932.
12. Baim DS, ed. *Grossman's Cardiac Catheterization, Angiography, and Intervention*. Philadelphia, PA: Lippincott Williams and Wilkins; 2006.
13. Lin JL, Huang SK, Lai LP, Lin LJ, Chen JH, Tseng YZ, Lien WP. Distal end of the atrioventricular nodal artery predicts the risk of atrioventricular block during slow pathway catheter ablation of atrioventricular nodal re-entrant tachycardia. *Heart* 2000;83:543–550.
14. Johnson LW, Lozner EC, Johnson S, Krone R, Pichard AD, Vetrovec GW, Noto TJ. Coronary arteriography 1984–1987: a report of the Registry of the Society for Cardiac Angiography and Interventions. I. Results and complications. *Cathet Cardiovasc Diagn* 1989;17:5–10.
15. Jolly SS, Yusuf S, Cairns J, et al. Radial versus femoral access for coronary angiography and intervention in patients with acute coronary syndromes (RIVAL): a randomised, parallel group, multicentre trial. *Lancet* 2011;377:1409–1420.