

Inferior vena cava filter misplacement in the right ovarian vein and successful removal by loop-snare technique in a patient with inferior vena cava agenesis

Peng-Xu Ding, MD, Xin-Wei Han, MD, Chao Liu, MD, and Ke-Wei Ren, MD, Zhengzhou, China

ABSTRACT

Misplacement of an inferior vena cava (IVC) filter in a gonadal vein is a rare complication of IVC filter placement. We report a case of a filter misplaced in the ovarian vein of a pregnant woman with agenesis of the infrarenal IVC and bilateral lower extremity deep venous thrombosis. The filter was removed by a loop-snare technique through an internal jugular vein. IVC agenesis and dilated right gonadal vein should be kept in mind when an IVC filter is being inserted in the infrarenal location through the jugular approach. (*J Vasc Surg Cases and Innovative Techniques* 2018;4:324-6.)

An inferior vena cava (IVC) filter provides short-term protection from pulmonary embolism in patients with deep venous thrombosis (DVT).¹ The procedure is usually technically simple without significant complications. Misplacement of an IVC filter in a gonadal vein is extremely rare. Herein we report a case of misplacement of a filter in the ovarian vein in a pregnant woman with infrarenal IVC agenesis and bilateral lower extremity DVT. The filter was removed with a loop-snare passed through the right internal jugular vein.

This study was approved by the ethics committee, and written informed consent of the patient for the publication of this report was obtained.

CASE REPORT

A 25-year-old nulliparous woman with a history of surgical repair of a strangulated intestinal obstruction at the age of 8 months was referred for removal of a temporary IVC filter (Aegisy; LifeTech Scientific Co, Ltd, Shenzhen, China). Four weeks earlier, at 12 weeks' gestation, an IVC filter was deployed through the right jugular vein at another institution because of bilateral femoral vein and lower extremity DVT, confirmed by color Doppler ultrasound examination, manifested by lower extremity swelling and pain. After the implantation, abortion was induced, and anticoagulation with low-molecular-weight heparin and warfarin was instituted; symptoms gradually resolved, and no pulmonary embolism occurred. One week before admission at another institution, attempted removal of the filter through

the femoral approach failed because the vein containing the filter could not be accessed.

At our institution, venography revealed a slender infrarenal IVC and bilateral iliac veins with chronic thrombosis (Fig 1), a dilated right ovarian vein (Fig 2), and pelvic varicosities. Venous flow from the lower extremities entered the pelvic varicosities mainly through the pelvic cavity, forming anastomotic collateral vessels draining into the ovarian vein and the normal suprarenal IVC. A dilated right ovarian vein was distinguished from the IVC by finding the ovarian vein communicating with the pelvic varicosities and the IVC communicating with the bilateral common iliac vein. IVC agenesis and misplacement of the filter in the right ovarian vein were diagnosed.

A loop-snare technique was used to remove the filter. First, a 12F, 60-mm-long sheath was inserted through the right jugular vein. Through the catheter, a 0.035-inch guidewire (Cook Medical, Bloomington, Ind) looped the superior apex of the filter by use of a 5F pigtail catheter and a 20-mm Amplatz GooseNeck snare device (ev3, Plymouth, Minn). Over the loop, the sheath was advanced to capture the filter (Fig 3), and the filter was drawn into the sheath and removed. Final venography revealed no complications, and the patient had no discomfort.

A three-dimensional reconstruction computed tomography image after the IVC filter was removed more clearly and directly displayed a dilated ovarian vein and pelvic varicosities (Fig 4). The patient was discharged without procedure-related complications. Lifelong anticoagulation therapy is planned.

DISCUSSION

IVC agenesis is a rare vascular abnormality, with an estimated incidence of 0.0005% to 1% in the general population, and it is mostly asymptomatic.² Agenesis is a risk factor for DVT in young adults, occurring in about 5% of unprovoked lower extremity DVTs in patients <30 years of age.³ This patient is representative of this demographic; IVC agenesis was incidentally discovered because of symptoms of DVT appearing during pregnancy.

Although the cause of IVC agenesis is unclear, isolated agenesis of the infrarenal IVC is thought to result from intrauterine or perinatal IVC thrombosis rather than from congenital anomalies.⁴ Our patient had neither a history

From the Department of Intervention, First Affiliated Hospital of Zhengzhou University.

Author conflict of interest: none.

Correspondence: Peng-Xu Ding, MD, Department of Intervention, First Affiliated Hospital of Zhengzhou University, 1 E Jian She Rd, Zhengzhou, Henan Province, China 450052 (e-mail: jieru375@sina.com).

The editors and reviewers of this article have no relevant financial relationships to disclose per the Journal policy that requires reviewers to decline review of any manuscript for which they may have a conflict of interest.

2468-4287

© 2018 Published by Elsevier Inc, on behalf of Society for Vascular Surgery. This is an open access article under the CC BY-NC-ND license (<http://creativecommons.org/licenses/by-nc-nd/4.0/>).

<https://doi.org/10.1016/j.jvscit.2017.12.006>

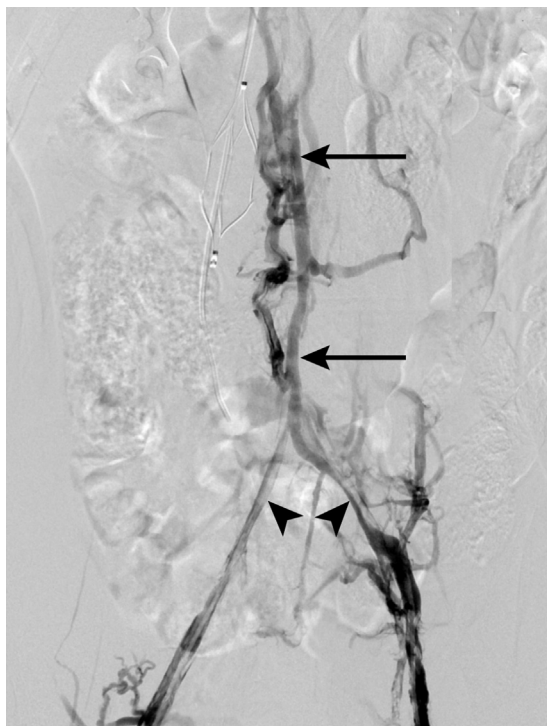


Fig 1. Venography through the bilateral femoral vein approach reveals the slender infrarenal inferior vena cava (IVC; *arrows*) and bilateral iliac veins complicated with chronic thrombosis (*arrowheads*).

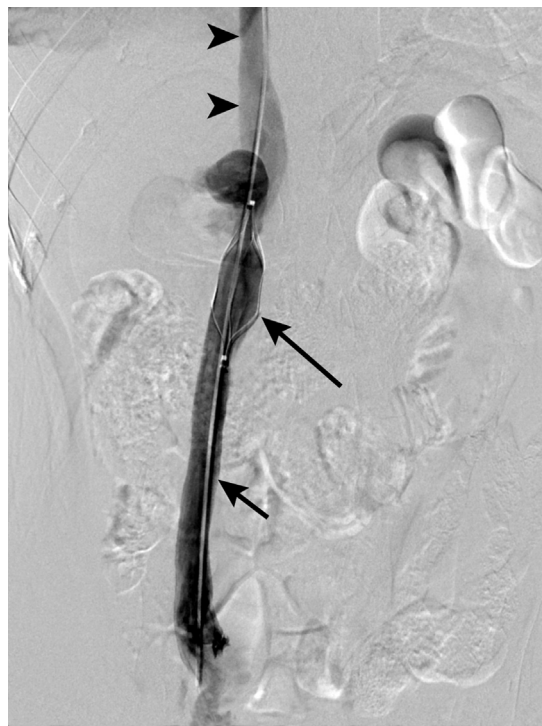

Fig 2. Venography through the right jugular approach shows the dilated right ovarian vein (*short arrow*), misplaced inferior vena cava (IVC) filter (*long arrow*), and normal retrohepatic IVC (*arrowheads*).

of venous thromboembolism nor laboratory data to suggest inherited thrombophilia. Thus, her childhood operation for intestinal obstruction seems likely to have caused the infrarenal IVC and iliac vein thromboses. In the isolated absence of the infrarenal IVC, the gonadal venous system usually is the main collateral route for blood flow between the femoral veins and the suprarenal IVC, with compensatory enlargement of the gonadal vein; this was likely the vascular anatomy of our patient.

Given the rarity of IVC agenesis, there are no clinical trials to determine the best treatment strategy.⁵ The mainstay of treatment is conservative; lifelong warfarin anticoagulation to prevent venous thrombosis or recurrence is recommended. Compression stockings and leg elevation to relieve venous stasis are also recommended. Surgical thrombectomy, endovascular catheter-directed thrombolysis, and mechanical thrombectomy are indicated in cases with acute DVT. Surgical and endovascular reconstruction can be performed in cases of severe venous stasis symptoms and with inadequate response to medical and conservative treatment.⁶ In our patient, no surgical or endovascular intervention was performed for IVC agenesis because the gonadal venous system had sufficiently compensated for it.

Implantation of a temporary retrievable IVC filter often is used for patients with DVT and pulmonary embolus

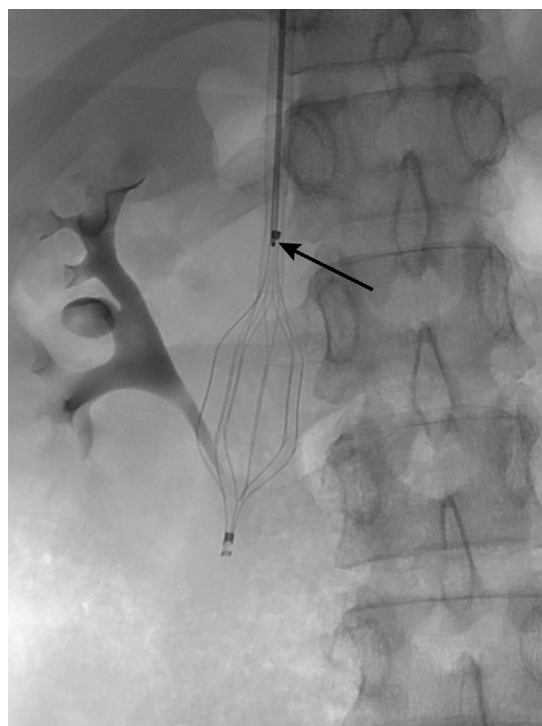


Fig 3. Radiograph shows that the 12F sheath is advanced over the filter while it is retained with the wire loop placed through the filter apex (*arrow*).

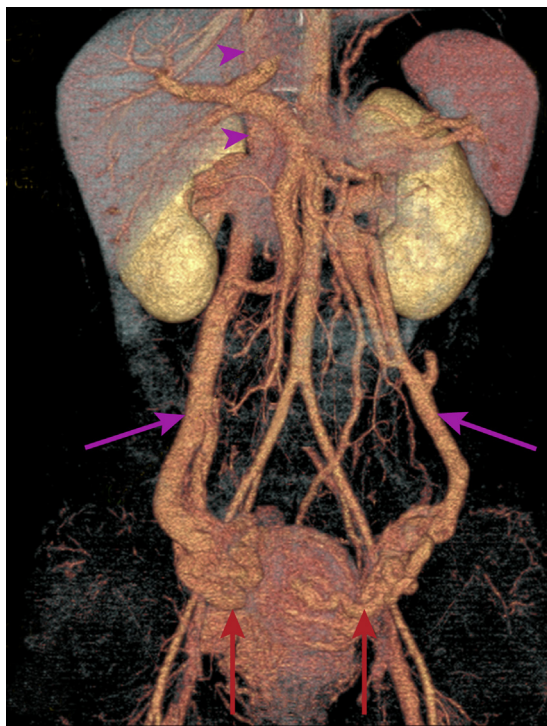


Fig 4. Three-dimensional reconstruction computed tomography image after removal of the inferior vena cava (IVC) filter shows the dilated ovarian veins (pink arrows), extensive pelvic varices (red arrows), and normal retrohepatic IVC (arrowheads).

in the acute phase. The procedure has a high technical success rate and minimal complications.⁷ Misplacement of an IVC filter in a gonadal vein is an extremely rare but recognized complication of filter placement from a jugular vein approach⁶; we have found only three documented cases.⁸⁻¹⁰ This case is the first of which we are aware with IVC agenesis and compensatory enlargement of the gonadal vein.

In our case, the filter was inadvertently deployed into the right gonadal vein. We suspect that the misplacement could have resulted from at least four reasons. First, most IVC filters are inserted through the femoral vein, and consequently, catheterization of the right gonadal vein is averted because of the vein's position; however, in our patient, the filter was placed by the jugular route. Second, the right gonadal vein was significantly enlarged because of the infrarenal IVC agenesis. Third, the right gonadal vein drains directly into the IVC at an acute angle just inferior to the level of renal veins after coursing nearly in line with the IVC. Fourth, there was a lack of pre-deployment venography to differentiate the IVC from the right gonadal vein.

Nonstandard endovascular techniques have been described for difficult retrieval of IVC filters. These techniques include the buddy wire, balloon-assisted,

aggressive traction, excimer laser sheath, forceps-assisted, and loop-snare techniques. We chose to use the loop-snare technique because of the retrievable nature of the IVC filter, with a diamond-shaped double basket, like that of the Optease (Cordis, Bridgewater, NJ) retrievable IVC filter.¹¹ This technique, with removal of the filter through the internal jugular vein, is similar to that reported by Scher et al.¹¹

CONCLUSIONS

This case illustrates that IVC agenesis and dilated gonadal vein must be considered in inserting an IVC filter through the jugular approach in young women who have bilateral lower extremity DVT. Otherwise, the filter might be inadvertently inserted into the gonadal vein.

REFERENCES

- Decousus H, Leizorovicz A, Parent F, Page Y, Tardy B, Girard P, et al. A clinical trial of vena caval filters in the prevention of pulmonary embolism in patients with proximal deep-vein thrombosis. Prevention du Risque d'Embolie Pulmonaire par Interruption Cave Study Group. *N Engl J Med* 1998;338:409-15.
- Sneed D, Hamdallah I, Sardi A. Absence of the retrohepatic inferior vena cava: what the surgeon should know. *Am Surg* 2005;71:502-4.
- Skeik N, Wickstrom KK, Schumacher CW, Sullivan TM. Infrahepatic inferior vena cava agenesis with bilateral renal vein thrombosis. *Ann Vasc Surg* 2013;27:973.e19-23.
- Kawata E, Kondoh E, Kawasaki K, Baba T, Ueda A, Kido A, et al. Utero-ovarian varices and absent inferior vena cava in pregnancy. *J Obstet Gynaecol Res* 2015;41:631-4.
- Tufano A, Cannavacciuolo F, Gianno A, Carbone AM, Mangiacapra S, Coppola A, et al. Inferior vena cava agenesis and deep vein thrombosis in the young: a review of the literature and local experience. *Semin Thromb Hemost* 2017;43:827-35.
- Ali B, Ali Rana M, Langsfeld M, Marek J. A rare cause of claudication treated with IVC reconstruction: a case report. *Int J Surg Case Rep* 2015;14:69-71.
- Johnson MS, Nemcek AA Jr, Benenati JF, Baumann DS, Dolmatch BL, Kaufman JA, et al. The safety and effectiveness of the retrievable option inferior vena cava filter: a United States prospective multicenter clinical study. *J Vasc Interv Radiol* 2010;21:1173-84.
- Kazmers A, Ramnauth S, Williams M. Intraoperative insertion of Greenfield filters: lessons learned in a personal series of 152 cases. *Am Surg* 2002;68:877-82.
- Sharma S, Mukund A, Agarwal S, Srivastava DN. Case of a misplaced IVC filter: a lesson to learn. *Cardiovasc Intervent Radiol* 2010;33:880-2.
- Tan WP, Sherer BA, Khare N. Unfriendly filter: an unusual cause of hydronephrosis and hematuria. *Urology* 2016;87:9-10.
- Scher D, Venbrux A, Okapal K, Gabriel G, Dufour R, Chun A, et al. Retrieval of TRAPEASE and OPTASE inferior vena cava filters with extended dwell times. *J Vasc Interv Radiol* 2015;26:1519-25.

Submitted Nov 8, 2017; accepted Dec 14, 2017.