

This is an Open Access article licensed under the terms of the Creative Commons Attribution-NonCommercial 3.0 Unported license (CC BY-NC) ([www.karger.com/OA-license](http://www.karger.com/OA-license)), applicable to the online version of the article only. Distribution permitted for non-commercial purposes only.

# Pulmonary *Mycobacterium avium* Infection in a Patient with Crohn's Disease under Azathioprine Treatment

Tomonori Hirano Minoru Matsuura Hiroshi Nakase

Department of Gastroenterology and Hepatology, Kyoto University Hospital, Kyoto, Japan

## Key Words

*Mycobacterium avium* infection · Crohn's disease · Azathioprine

## Abstract

Anti-tumor necrosis factor alpha therapy is known as a risk factor of non-tuberculous mycobacteria (NTM) infection. However, there are few reports of NTM infection under treatment with thiopurine agents. We herein report a first case of pulmonary infection caused by *Mycobacterium avium* complex (MAC) in a patient with Crohn's disease under treatment with thiopurine. After starting antibiotics therapy for NTM including clarithromycin, rifampicin, ethambutol and streptomycin, MAC infection was well controlled, and she kept clinical remission even without azathioprine. In conclusion, our case emphasizes the importance of considering NTM infection in respiratory complications of inflammatory bowel disease patients under immunosuppressive therapies.

© 2014 S. Karger AG, Basel

## Introduction

Immunomodulators and anti-tumor necrosis factor alpha (anti-TNF $\alpha$ ) agents are widely used for patients with refractory Crohn's disease (CD). Physicians are always concerned about an increased risk of serious and opportunistic infections related to immunosuppressive drugs. Particularly, anti-TNF $\alpha$  treatment is documented as a risk of infection of *Mycobacterium tuberculosis* and non-tuberculous mycobacteria (NTM) [1–4]. However, *M. tuberculosis* and NTM infections have been reported in few individuals with CD receiving immunomodulators, such as thiopurine agents [5, 6]. Herein we describe a first case of

Minoru Matsuura, MD, PhD  
Department of Gastroenterology and Hepatology, Kyoto University Hospital  
54 Shogoin-Kawaharacho, Sakyo-ku  
Kyoto City, Kyoto 606-8507 (Japan)  
E-Mail [minomats@kuhp.kyoto-u.ac.jp](mailto:minomats@kuhp.kyoto-u.ac.jp)

pulmonary *Mycobacterium avium* infection during long-term immunosuppressive treatment with azathioprine for CD.

## Case Report

A 39-year-old-woman with CD had been treated with mesalamine since undergoing ileal resection due to bowel obstruction in her early 20s. She was referred to our hospital on July 2009 with a chief complaint of right lower quadrant pain. Her Crohn's Disease Activity Index score was 280 points. Laboratory data revealed normocytic normochromic anemia (hemoglobin 10.5 g/dl, normal 10.7–14.5 g/dl), hypoalbuminemia (2.4 g/dl, normal 3.9–5.1 mg/dl), hypocholesterolemia (65 mg/dl, normal 140–220 mg/dl) and a slight increase in C-reactive protein (0.3 mg/dl, normal <0.2 mg/dl), with no other abnormalities. Abdominal computed tomography showed remarkable wall thickness of the ileocecum and distal ileum. Ileocolonoscopy revealed a stricture of the terminal ileum with active mucosal inflammation, which a scope could not pass through. She was diagnosed with a flare of CD and we started azathioprine 25 mg. Two months after starting thiopurine treatment combined with oral mesalamine, her abdominal symptoms had subsided and stayed in clinical remission.

Three years later the patient complained of sustained cough for 1 month. Laboratory data showed no abnormalities. However, on chest X-ray patchy interstitial inflammatory infiltrates were predominantly observed in the right lung (fig. 1), and chest computed tomography revealed multifocal bronchiectasis in both lungs with cavernous lesions in the right S2 and S10 (fig. 2). Sputum culture was positive for *M. avium* twice, but negative for other bacterial and fungal microorganisms. Polymerase chain reaction for *M. avium* of sputum was positive, whereas polymerase chain reaction for *M. tuberculosis* and QuantiFERON-TB® assay was negative. She was diagnosed with pulmonary *M. avium* infection. We administered a combination of clarithromycin 400 mg, rifampicin 300 mg, ethambutol 500 mg and streptomycin 500 mg per day, after discontinuation of azathioprine. Nine months after starting this antibiotics therapy, culture of her septum had become negative, and infiltration of her chest X-ray had disappeared. During this antibiotic treatment, she kept clinical remission even without azathioprine.

## Discussion

This is a first case of a patient with CD accompanied by *M. avium* complex (MAC) infection under thiopurine treatment, and she was successfully treated with a combination of antibiotics therapy.

NTM are a group of environmental bacteria and opportunistic pathogens which can cause various pathological conditions, most commonly pulmonary infection. They usually occur in immunosuppressed individuals, especially in impaired T helper 1 or macrophage function, such as AIDS, and conditions under treatment with anti-TNF $\alpha$  therapy. The incidence and prevalence of *M. tuberculosis* are decreasing in the developed countries, whereas those of NTM are increasing throughout the world. NTM infection is mainly caused by MAC (about 80%). A variety of drugs and their combinations have been reported to be effective against MAC strains. However, no standardized therapeutic regimen has yet been established. Patients with NTM infection often require long-term antibiotic treatment and sometimes develop severe and chronic infection.

Azathioprine is known to be associated with an increased risk of opportunistic infections and neoplasms [5]. Herpes zoster virus, herpes simplex virus, cytomegalovirus virus and Epstein-Barr virus are known to be common causes of opportunistic infections associated with thiopurine drugs [5]. So far, there are few reports of NTM infection caused by *Mycobacterium fortuitum* [5] and *Mycobacterium xenopi* [6] in patients with CD receiving thiopurine agents; however, there is no report of that caused by MAC. Considering that the incidence of NTM infections becomes increased and use of immunomodulators and biologics drugs for the treatment of inflammatory bowel disease is widespread, we must keep in mind that NTM infection is a differential diagnosis of respiratory infections in inflammatory bowel disease patients under immunosuppression treatment.

Interestingly, the patient stayed in clinical remission only by the antibiotics treatment without azathioprine. There are many reports about antibiotics therapy for maintenance of clinical remission in CD. The therapy is based on the hypothesis that *M. avium* subspecies *paratuberculosis* (MAP) or other bacteria play a role in the etiology of CD. Clarithromycin, one of macrolide antibiotics, is among the key drugs because it acts not only as an effective antibiotic against *M. avium*, but also as an immunomodulating drug [7]. Previously, we reported that a subpopulation of CD patients treated with clarithromycin could achieve and maintain remission [8]. On the other hand, a randomized controlled trial failed to demonstrate efficacy of a combination of antibiotics in CD [9], although the existence of MAP in the CD patients enrolled in that trial was not assessed. Thus, whether antibiotics therapy could be effective for CD remains unclear. However, considering the clinical course of this case, clarithromycin may have beneficial effects to maintain clinical remission of her CD.

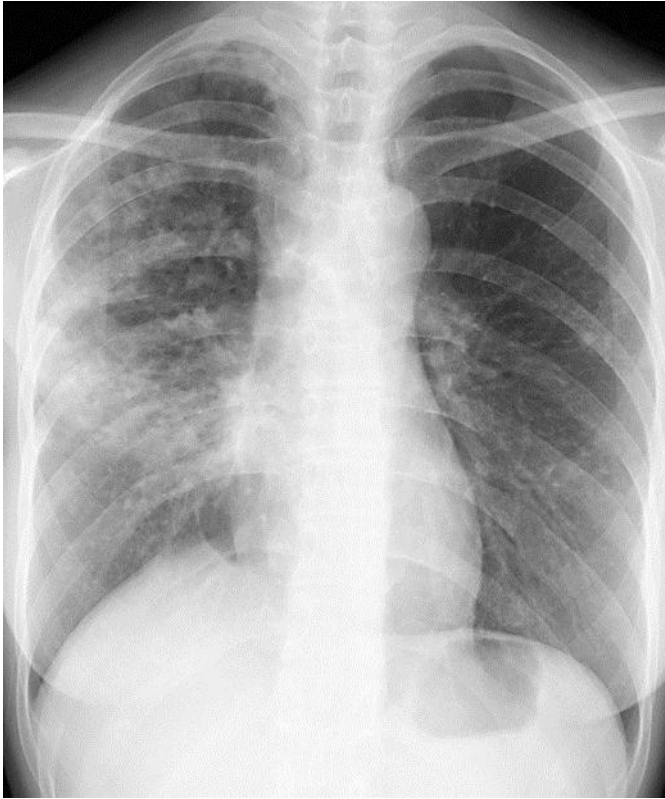
In conclusion, our case emphasizes the importance of considering NTM infection in respiratory complications of inflammatory bowel disease patients under immunosuppressive therapies.

### Disclosure Statement

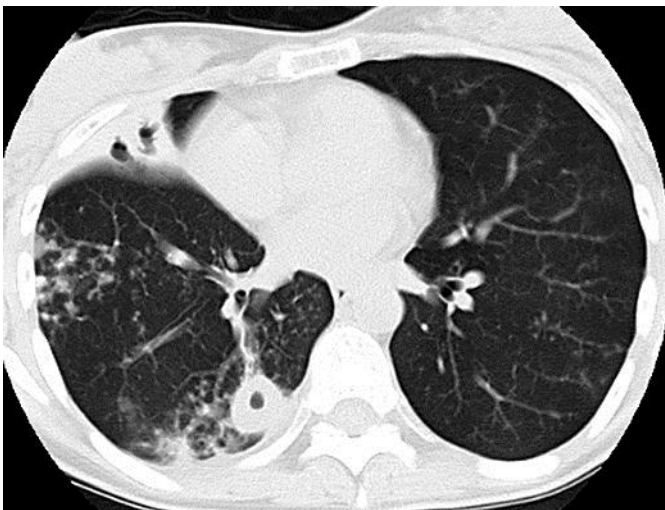
The authors declare no conflict of interest.

### References

- 1 Keane J, Gershon S, Wise RP, et al: Tuberculosis associated with infliximab, a tumor necrosis factor alpha-neutralizing agent. *N Engl J Med* 2001;345:1098–1104.
- 2 Wallis RS, Broder M, Wong J, Beenhouwer D: Granulomatous infections due to tumor necrosis factor blockade: correction. *Clin Infect Dis* 2004;39:1254–1255.
- 3 Tissot C, Couraud S, Meng L, et al: Life-threatening disseminated tuberculosis as a complication of treatment by infliximab for Crohn's disease: report of two cases, including cerebral tuberculomas and miliary tuberculosis. *J Crohns Colitis* 2012;6:946–949.
- 4 Nunez Martinez O, Ripoll Noiseux C, Carneros Martin JA, et al: Reactivation tuberculosis in a patient with anti-TNF-alpha treatment. *Am J Gastroenterol* 2001;96:1665–1666.
- 5 Toruner M, Loftus EV Jr, Harmsen WS, et al: Risk factors for opportunistic infections in patients with inflammatory bowel disease. *Gastroenterology* 2008;134:929–936.
- 6 Majoro CJ, Schreurs AJ, Weers-Pothoff G: *Mycobacterium xenopi* infection in an immunosuppressed patient with Crohn's disease. *Thorax* 2004;59:631–632.
- 7 Shinkai M, Henke MO, Rubin BK, et al: Macrolide antibiotics as immunomodulatory medications: proposed mechanisms of action. *Pharmacol Ther* 2008;117:393–405.
- 8 Inoue S, Nakase H, Matsuura M, et al: Open label trial of clarithromycin therapy in Japanese patients with Crohn's disease. *J Gastroenterol Hepatol* 2007;22:984–988.
- 9 Selby W, Pavli P, Crotty B, et al: Two-year combination antibiotic therapy with clarithromycin, rifabutin and clofazimine for Crohn's disease. *Gastroenterology* 2007;132:2313–2319.



**Fig. 1.** Chest radiography showed a bilateral diffuse or patchy interstitial infiltrate predominantly in the right lung.



**Fig. 2.** Chest computed tomography showed multiple centrilobular or panlobular lesions, bronchiectasis and cavernous lesions predominantly in the right lung.