

Sigmoid carcinoma localized in the sac of a right inguinoscrotal hernia

**Evangelos Falidas,
Stavros Gourgiotis,
Marios
Papachrysostomou,
Christiana Oikonomou,
Constantinos Villias**

Department of Surgery, 417 NIMTS Military Veterans' Fund Hospital of Athens, Athens, Greece

Address for correspondence:

Dr. Stavros Gourgiotis, 41 Zakinthinou Street, 15669, Papagou, Athens, Greece.

E-mail: drgourgiotis@yahoo.gr

Abstract

The inguinoscrotal hernia with colonic malignancy in the sac presents rare but severe consequence. The most common side of this type of hernia is the left one while the most common part of the large bowel is the sigmoid colon. The clinical picture can be easily confused with simple inguinoscrotal hernia unless the clinician is alert to the presence of certain sinister symptoms and signs. We report an extremely rare case of a 91-year-old man presented with anemia who had a right inguinoscrotal hernia containing a sigmoid colon carcinoma.

Key words: Adenocarcinoma, inguinoscrotal hernia, malignancy, sigmoid colon

INTRODUCTION

Although inguinal hernias may contain small or large bowel, only 10% of them cause bowel obstruction or strangulation and in extremely rare cases malignant lesions are observed in their sacs.^[1] The most intrasaccular neoplasms are colonic, especially of the sigmoid colon and usually in a left inguinoscrotal hernia.^[2] We herein report an interesting and extremely rare case of a 91-year-old man who had a right inguinoscrotal hernia containing a sigmoid colon carcinoma.

CASE REPORT

A 91-year-old man was admitted due to a right inguinoscrotal hernia [Figure 1]. His past medical history included triple aortocoronary bypass, chronic obstructive pulmonary disease, and prostate benign hypertrophy. No signs of obstruction were observed. Digital examination of the rectum was negative for blood while the laboratory findings revealed anemia (hemoglobin: 6.8 g/dl, hematocrit: 23.3%). The abdominal and pelvic computer tomography (CT) demonstrated a thick-walled segment of sigmoid colon in the inguinoscrotal hernia, which was suspicious of a tumour, dysomogeneous paracolic fat, and small local lymph nodes [Figure 2]. Colonoscopy revealed a large, hard

and ulcerous mass of the sigmoid colon. Completion CT of the thorax confirmed no evidence of metastasis.

During the operation, a consistent part of the sigmoid colon was localized within the hernia. A large tumor of the sigmoid colon (5 cm × 9 cm in diameter) was observed obstructing the lumen. A temporary end colostomy was fashioned, and the rectal stump was oversewn (Hartmann's procedure) [Figure 3]. The hernia was repaired with primary sutures. Histology revealed a low differentiated



Figure 1: The right inguinoscrotal hernia

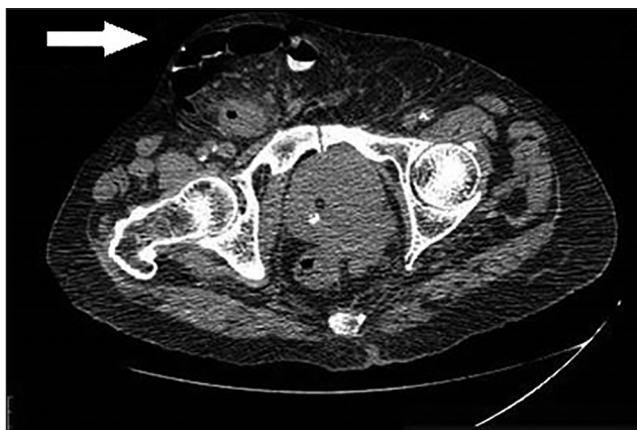


Figure 2: The abdominal computer tomography demonstrates the sigmoid carcinoma in the right inguinoscrotal hernia (arrow)

adenocarcinoma of the sigmoid colon (stage pT3N0Mx). The postoperative course was uneventful, and the patient was discharged the seventh postoperative day.

DISCUSSION

A percentage of 10% of inguinal hernias may become irreducible while malignancies in inguinoscrotal hernias are rare conditions and constitute <0.5% of the existed sacs.^[3] They can be classified as intrasaccular or saccular: The first group includes primary neoplasms incarcerated into the hernias while the second one involves tumors with peritoneal metastasis (mesothelioma, metastasis).^[2] A review performed by Ruiz-Tovar *et al.*^[3] identified approximately 31 cases of intrasaccular tumors. The intrasaccular tumors are uncommon in comparison with saccular tumors, and most of them are discovered during surgery as an incidental finding. Most of the cases involve the sigmoid colon, but malignancies involving caecum and ascending colon have also been described.^[4] Some authors reported perforated carcinoma within an incarcerated inguinal hernia.^[1,2,4] The most intrasaccular colonic neoplasms are usually in a left inguinoscrotal hernia.^[2] We hypothesize that the most common side of this type of hernia is the left due to the length, the anatomic place, and the mobility of the sigmoid colon.

Signs and symptoms may be limited to the already commonly reported signs for the inguinal hernia. Patients with history of intra-abdominal malignancy presented with a new inguinal hernia should always be investigated for a possible recurrence. Additional findings such as loss of weight, changes in bowel habits and defecation, bleeding or anemia not otherwise attributed, and the contemporaneous presence of inguinal hernia should raise the suspicion of a herniated colonic neoplasm.^[2] According the question whether patients who present with inguinal hernias should have colon imaging as part of their initial workup, we

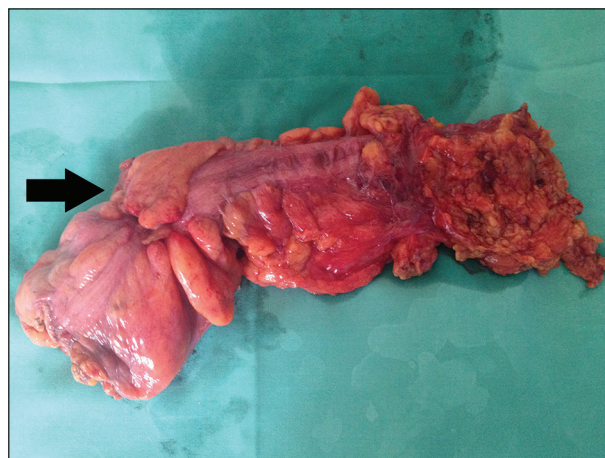

Figure 3: The tumor in the resected specimen of the sigmoid colon (arrow)

strongly believe that if there are signs and symptoms of anemia and colonic obstruction or changes in bowel habits, a colonic investigation should be performed because partial colonic obstruction could be a precipitating factor in the development of a groin hernia.

Although various surgical approaches have been proposed, the optimal one remains uncertain. It is unclear whether the best surgical approach is via an abdominal or inguinal incision or both; this will depend on the patient's anatomy, the surgical findings and the surgeon's experience. Ruiz-Tovar *et al.*^[3] performed formal laparotomy and inguinal incision. Others authors were able to deliver the sigmoid colon through the internal ring, resected the sigmoid colon and the mesentery and repaired the hernia via the internal ring.^[4] We performed this technique in our reported case because we strongly believe that the selected procedure must achieve a resection based on oncological principles and ensure a secure hernia repair. A transverse left iliac fossa incision has also been proposed.^[5] This surgical approach has the advantage of allowing good access to both the left colon and inguinal canal.

Our clinical suspicion was mainly based on patient's clinical (sizable, hard, and irreducible groin hernia) and laboratory findings (anemia). The CT described the large bowel into the sac and the possibility of tumor while the colonoscopy confirmed the diagnosis. During the operation, we focused to perform an oncological procedure and at the same time to repair the hernia keeping always in mind our patient's advanced age and his comorbidities.

CONCLUSION

Inguinal hernia containing colonic neoplasm should always be considered in patient with an irreducible mass in the

inguinal region or with a mass with a steady increasing of volume. Surgical approaches vary and depend on patient's anatomy, surgical findings, and surgeons experience.

REFERENCES

1. Kouraklis G, Kouskos E, Glinavou A, Raftopoulos J, Karatzas G. Perforated carcinoma of the sigmoid colon in an incarcerated inguinal hernia: Report of a case. *Surg Today* 2003;33:707-8.
2. Tan GY, Guy RJ, Eu KW. Obstructing sigmoid cancer with local invasion in an incarcerated inguinal hernia. *ANZ J Surg* 2003;73:80-2.
3. Ruiz-Tovar J, Ripalda E, Beni R, Nistal J, Monroy C, Carda P. Carcinoma of the sigmoid colon in an incarcerated inguinal hernia. *Can J Surg* 2009;52:E31-2.
4. Boormans JL, Hesp WL, Teune TM, Plaisier PW. Carcinoma of the sigmoid presenting as a right inguinal hernia. *Hernia* 2006;10:93-6.
5. Mai CM, Chen CY, Hsu KF, Hsiao CW, Jao SW, Wu CC. Colonic neoplasm in a strangulated inguinal hernia. *Rev Esp Enferm Dig* 2010;102:339-41.

How to cite this article: Falidas E, Gourgiotis S, Papachrysostomou M, Oikonomou C, Villias C. Sigmoid carcinoma localized in the sac of a right inguinoscrotal hernia. *J Nat Sc Biol Med* 2015;6:S150-2.

Source of Support: Nil. **Conflict of Interest:** None declared.

Access this article online	
<p>Quick Response Code:</p> 	<p>Website: www.jnsbm.org</p> <hr/> <p>DOI: 10.4103/0976-9668.166125</p>