

MINI-FOCUS ISSUE: INTERVENTIONAL CARDIOLOGY

BEGINNER

CASE REPORT: CLINICAL CASE

A Cautionary Tale of Triple Therapy



Negeen Shahandeh, MD, Jeffrey Harrell, MD, Eric H. Yang, MD, Rushi V. Parikh, MD

ABSTRACT

A 54-year-old man with a history of atrial flutter presented with anterior ST-segment elevation myocardial infarction complicated by cardiogenic shock and underwent percutaneous coronary intervention of the left main coronary artery. He was placed on triple antithrombotic therapy and ultimately recovered. However, before discharge, he developed hypotension, confusion, and hemiplegia. **(Level of Difficulty: Beginner.)** (J Am Coll Cardiol Case Rep 2021;3:789-94)
© 2021 The Authors. Published by Elsevier on behalf of the American College of Cardiology Foundation. This is an open access article under the CC BY-NC-ND license (<http://creativecommons.org/licenses/by-nc-nd/4.0/>).

HISTORY OF PRESENTATION

A 54-year-old man was transferred to our institution for management of cardiogenic shock following anterior ST-segment elevation myocardial infarction (STEMI) status post-percutaneous coronary intervention (PCI) of the left main coronary artery (LMCA) with a drug-eluting stent (**Figure 1**). Before transfer, he developed tachycardia (heart rate: 150 beats/min) and hypotension (blood pressure: 80/44 mm Hg), with an electrocardiogram revealing atrial flutter with 2:1 conduction, for which intravenous heparin and intravenous amiodarone (150 mg bolus followed by

drip at 1 mg/min for 6 h and then 0.5 mg/min thereafter) were initiated. On arrival to our institution, the patient's cardiogenic shock was treated with aggressive diuresis, an intra-aortic balloon pump, and intravenous milrinone and norepinephrine drips. He ultimately recovered from cardiogenic shock and reverted to normal sinus rhythm. In preparation for hospital discharge and in light of his recent LMCA stent and atrial flutter, he was placed on short-term triple antithrombotic therapy (aspirin 81 mg daily, clopidogrel 75 mg daily, and apixaban 5 mg twice daily) and transitioned to oral amiodarone. However, 1 day before discharge (hospital day 20), he acutely developed hypotension, altered mentation, and hemiplegia. Vital signs included a blood pressure of 68/47 mm Hg and pulse of 86 beats/min. The examination was notable for left-sided hemiplegia and hemineglect with right gaze preference. A bedside echocardiogram was performed to further evaluate his hypotension. This revealed a new, large pericardial effusion with echocardiographic evidence of tamponade physiology (**Figure 2, Video 1**). An arterial line was placed for hemodynamic monitoring, and the waveform demonstrated pulsus paradoxus (**Figure 3A**). Collectively, these data were consistent with clinical cardiac tamponade.

LEARNING OBJECTIVES

- To identify clinical and/or echocardiographic features of and review management strategies for cardiac tamponade.
- To review the recent randomized controlled trial data and current guidelines for various antithrombotic regimens for patients with atrial fibrillation and/or flutter undergoing PCI.
- To understand the indications for and risks of reversal of anticoagulant therapy.

From the Division of Cardiology, University of California-Los Angeles, Los Angeles, California, USA.

The authors attest they are in compliance with human studies committees and animal welfare regulations of the authors' institutions and Food and Drug Administration guidelines, including patient consent where appropriate. For more information, visit the [Author Center](#).

Manuscript received September 20, 2020; revised manuscript received February 26, 2021, accepted March 12, 2021.

ABBREVIATIONS AND ACRONYMS

DOAC = direct oral anticoagulant

ICA = internal carotid artery

LMCA = left main coronary artery

PCI = percutaneous coronary intervention

STEMI = ST-segment elevation myocardial infarction

PAST MEDICAL HISTORY

The patient's medical history included coronary artery disease, chronic kidney disease, and chronic right internal carotid artery (ICA) occlusion.

DIFFERENTIAL DIAGNOSIS

The patient presented with left-sided neurological deficits and a pericardial effusion causing cardiac tamponade. Considerations for the etiology of his pericardial effusion included late complications of myocardial infarction (e.g., free wall rupture or pericarditis) and hemorrhagic effusion due to antithrombotic therapy. The differential diagnosis of his neurological deficits included right hemisphere hypoperfusion due to cardiogenic shock in the setting of a chronic right ICA occlusion and hemorrhagic stroke in the right ICA territory.

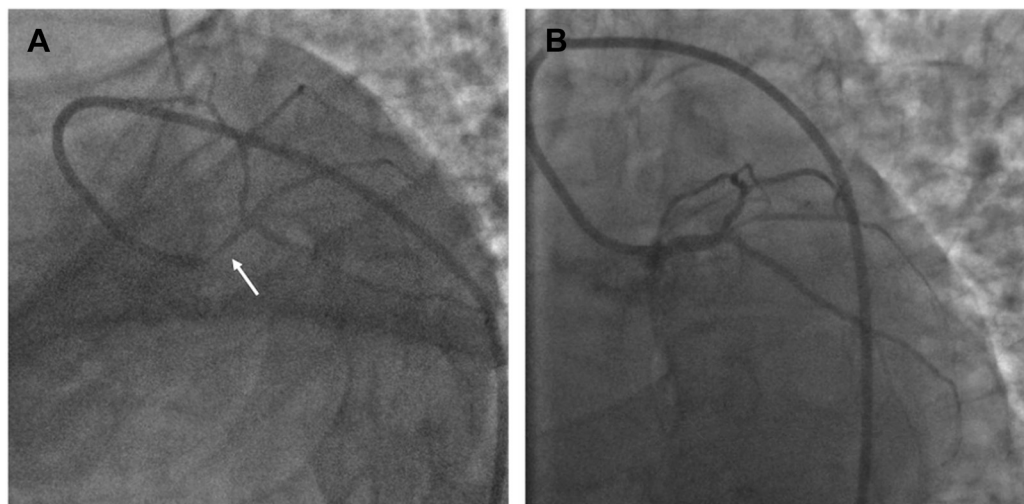
INVESTIGATIONS

Laboratory evaluation revealed acute abnormalities, including creatinine of 2.8 mg/dl (increased from 1.3 mg/dl 12 h earlier), an international normalized ratio of 3.7 (previously 1.2), hemoglobin of 6.6 g/dl (baseline 10 g/dl), and lactate of 56 mg/dl. Computed tomography imaging of the head was unremarkable.

MANAGEMENT AND INTERVENTIONS

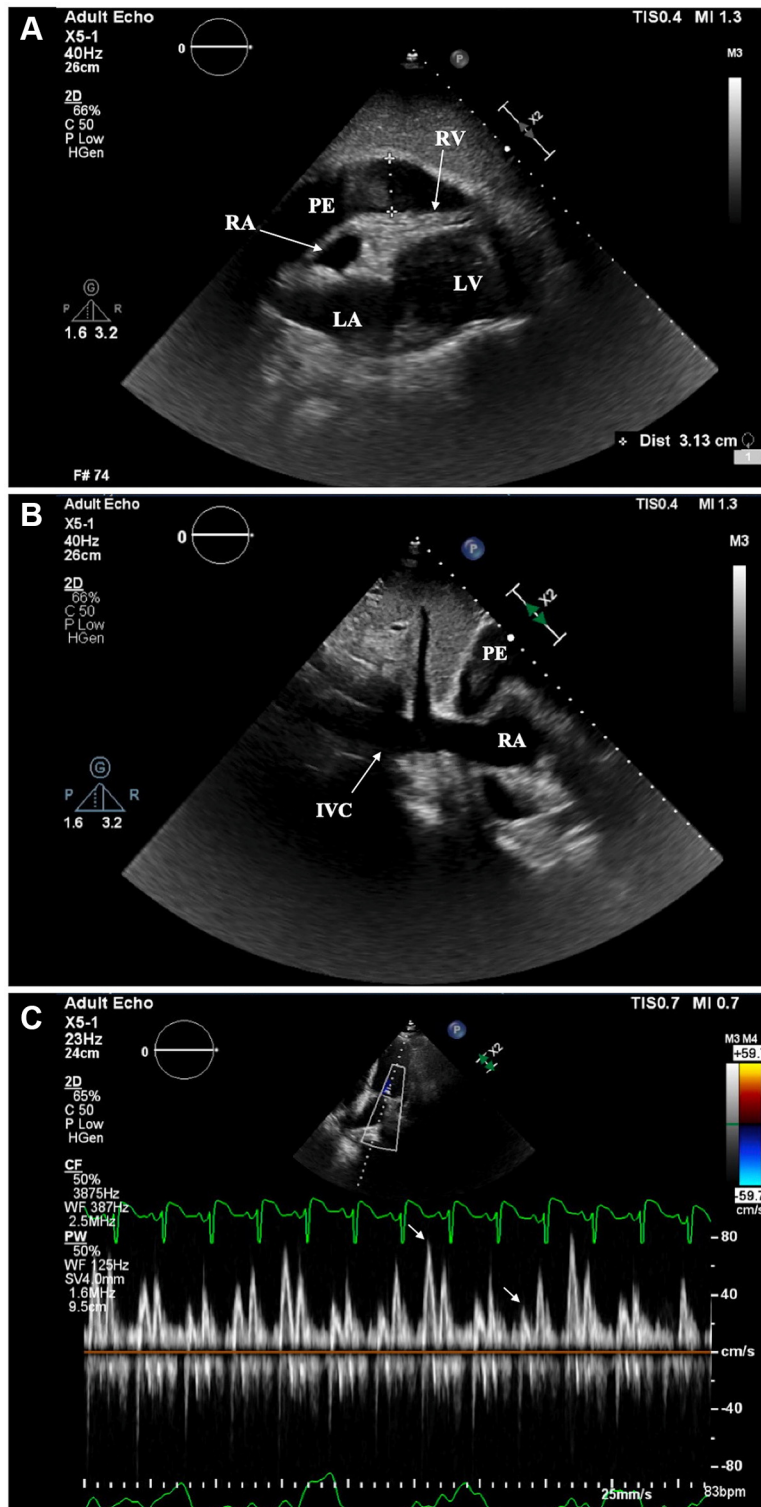
Apixaban was held, and the patient's hypotension and neurological deficits initially responded to intravenous fluids and blood transfusion. Because of his improving hemodynamics and prohibitive bleeding risk in the setting of active triple therapy, pericardiocentesis was initially deferred to allow the effects of apixaban to wane. The neurology consultants expressed concern about the possibility of a large territory ischemic stroke and requested brain magnetic resonance imaging to evaluate his candidacy for potential embolectomy. Unfortunately, the patient developed recurrent hypotension and progressive cardiogenic shock with multiorgan injury over the next 6 h, which precluded further brain imaging. During this time, high-risk pericardiocentesis with reversal of anticoagulant therapy was revisited after detailed discussions with the patient and his family regarding the risks of coronary and cerebrovascular thromboses with reversal. The patient received andexanet alfa and fresh frozen plasma and underwent successful echocardiography-guided sub-xiphoid pericardiocentesis with evacuation of 300 ml of hemorrhagic fluid. Pericardial pressure dropped from 24 to 4 mm Hg. Post-procedure, the patient's blood pressure markedly improved, and pulsus paradoxus resolved (**Figure 3B**). In addition, his neurological deficits completely resolved, and laboratory markers of shock normalized. A subsequent brain

FIGURE 1 Coronary Angiogram Before and After Left Main Coronary Artery Intervention

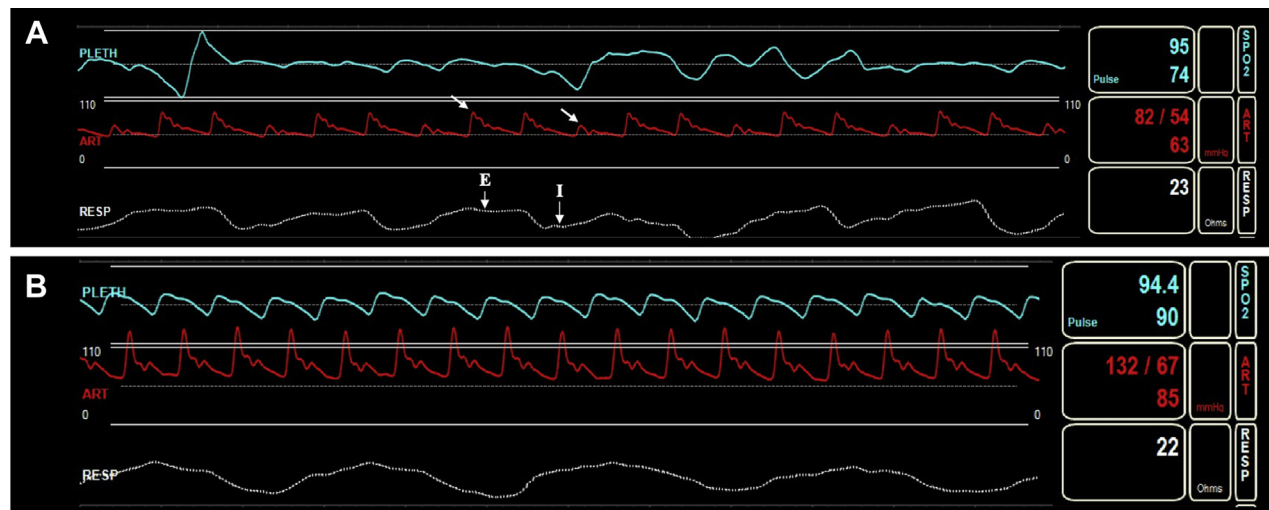


Selective angiography of the **(A)** left coronary artery revealed critical disease of the ostial left main coronary artery (**white arrow**), which was the **(B)** target of percutaneous coronary intervention.

FIGURE 2 Echocardiographic Findings Suggestive of Tamponade Physiology



Transthoracic echocardiography in the subxiphoid window revealed (A) a large pericardial effusion (3.0 cm at end-diastole) with diastolic collapse of the right ventricle (RV) and (B) a dilated inferior vena cava (IVC) measuring 2.4 cm. (C) Pulsed-wave Doppler demonstrated >25% respirophasic variation of mitral inflow velocities. LA = left atrium, LV = left ventricle; PE = pericardial effusion; RA = right atrium.

FIGURE 3 Arterial Line Waveforms

(A) The patient's arterial line tracing initially demonstrated marked hypotension and pulsus paradoxus, with >20 mm Hg decrease in systolic blood pressure (white arrows) during inspiration (I) compared with expiration (E). (B) These findings resolved after pericardiocentesis.

magnetic resonance imaging scan demonstrated acute strokes in a watershed territory (Figure 4), which suggested cerebral hypoperfusion as the etiology of his previous neurological deficits.

DISCUSSION

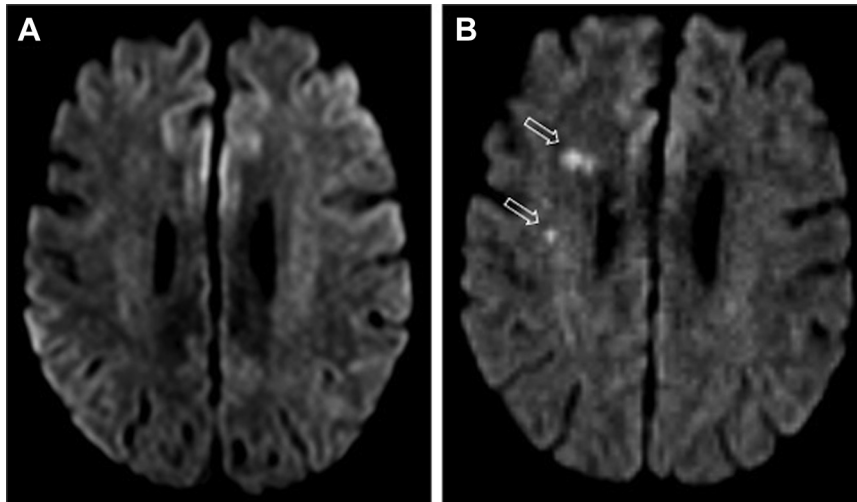
Cardiac tamponade results from compression of the cardiac chambers due to increased intrapericardial pressure. Typical clinical findings include tachycardia, hypotension, jugular venous distention, and pulsus paradoxus. These findings can be blunted or absent in certain scenarios (i.e., normocardia in patients on beta-blockers or low jugular venous pressure in hypovolemic patients) (1). In these cases, indirect signs of poor tissue perfusion and end-organ malperfusion can provide additional clinical clues.

Hemorrhagic cardiac tamponade associated with direct oral anticoagulants (DOACs) is uncommon (reported incidence: 0.02%) (2). In this case, the patient's bleeding risk was likely increased by the presence of chronic kidney disease as well as the drug-drug interactions among apixaban, amiodarone, and dual antiplatelet therapy. Amiodarone (a P-glycoprotein inhibitor) can increase DOAC plasma concentrations, although the clinical relevance of this interaction remains uncertain (3). One retrospective study from Taiwan reported an increased risk of major bleeding associated with concurrent use of amiodarone and DOACs (4); in contrast, post hoc analyses

of 2 large DOAC trials did not find a significant difference in bleeding among patients on amiodarone (3). Apixaban dose reduction is recommended if combined P-glycoprotein and strong CYP3A4 inhibitors are co-administered, but there are no specified dose adjustments solely for co-administration of P-glycoprotein inhibitors (5). In addition, a reduced dose of apixaban (2.5 mg twice daily) is recommended for patients with at least 2 of the following: age 80 years or older, weight ≤ 60 kg, or creatinine ≥ 1.5 mg/dl (6).

For patients with atrial fibrillation and/or flutter undergoing PCI, the American Heart Association/American College of Cardiology/Heart Rhythm Society guidelines provide a Class IIa recommendation that it is acceptable to use a thienopyridine and/or DOAC dual agent regimen, even in the setting of acute coronary syndrome. Triple therapy retains a Class IIb recommendation, with efforts being made to minimize duration to 4 to 6 weeks (6). However, since the publication of these guidelines, a number of studies, including the AUGUSTUS (Antithrombotic Therapy after Acute Coronary Syndrome or PCI in Atrial Fibrillation) trial, have consistently demonstrated the safety and efficacy of dual agent therapy compared with triple therapy (7). In addition, a meta-analysis of randomized controlled trials that assessed different antithrombotic regimens also found that triple therapy was associated with increased risks of bleeding compared with double therapy without conferring

FIGURE 4 Magnetic Resonance Imaging Findings



Diffusion weighted imaging sequences of the patient's brain magnetic resonance image demonstrated new acute infarcts in the right frontal deep white matter (**B**, white arrows) compared with a magnetic resonance image obtained 5 days previously (**A**).

reductions in the rates of major adverse cardiovascular events (8). When bleeding complications occur, anticoagulant reversal is recommended if there is hemodynamic compromise or bleeding in anatomically critical sites, as occurred in this case (9).

Although pericardiocentesis can be performed with reasonable safety in anticoagulated patients, it was believed that the combination of acute anemia, coagulopathy, and active triple antithrombotic therapy portended a prohibitive bleeding risk without reversal of the apixaban and coagulopathy. In light of the improvement in the patient's hemodynamics with volume resuscitation, the risk of bleeding was initially believed to outweigh the risks of thrombosis associated with reversal and further multiorgan injury resulting from delayed intervention. Furthermore, the pericardial effusion was suspected to be a hemorrhagic complication of anticoagulant therapy, which provided an additional indication for anticoagulant reversal. Nonetheless, reversal of DOAC therapy with andexanet alfa confers a substantial thrombotic risk. The possibility of LMCA stent thrombosis was most concerning, especially because abrupt discontinuation of anticoagulant therapy for bleeding is associated with increased risk of thrombotic events (10). Andexanet alfa carries a box warning for increased risks of thromboembolic, ischemic, and cardiac events. In the ANNEXA-4 (Full Study Report of Andexanet Alfa for Bleeding Associated with Factor Xa Inhibitors) trial, 10% of patients had a

thrombotic event, and 14% died within 30 days following treatment, although most of these events occurred in patients in whom anticoagulation had not been restarted (10). However, once the patient's clinical status deteriorated with recurrent hypotension and multiorgan injury unresponsive to further volume resuscitation, the risk/benefit calculation shifted, and urgent reversal followed by pericardiocentesis was pursued. Great care was taken to outline the thrombotic risks when obtaining informed consent.

FOLLOW-UP

The patient was restarted on anticoagulation within 48 h of pericardiocentesis and discharged on double therapy with rivaroxaban and clopidogrel as per the PIONEER-AF (Prevention of Bleeding in Patients with Atrial Fibrillation Undergoing PCI) trial (11). His mental status returned to baseline despite his cerebrovascular disease. An echocardiogram repeated before discharge showed no recurrence of pericardial effusion.

CONCLUSIONS

Hemorrhagic cardiac tamponade is a rare complication of DOAC therapy that may require the use of anticoagulant reversal agents. This case highlights the risks associated with triple antithrombotic therapy and underscores the nuanced risk/benefit

assessment required when considering the use of anticoagulant reversal agents for bleeding complications in the setting of recent ischemic events and need for urgent invasive procedures. Clinicians may face challenging, time-sensitive decisions when patients develop life-threatening bleeding, especially when there is concomitant concern and risk for thrombotic events.

ACKNOWLEDGMENT The authors thank Dr. Avetis Azizyan for his contributions to this paper.

FUNDING SUPPORT AND AUTHOR DISCLOSURES

The authors have reported that they have no relationships relevant to the contents of this paper to disclose.

ADDRESS FOR CORRESPONDENCE: Dr. Rushi V. Parikh, Division of Cardiology, University of California-Los Angeles, 100 Medical Plaza, Suite 630 West, Los Angeles, California 90095, USA. E-mail: rparikh@mednet.ucla.edu. Twitter: [@rushiparikh11](https://twitter.com/rushiparikh11).

REFERENCES

- Spodick DH. Acute cardiac tamponade. *N Engl J Med* 2003;349:684-90.
- Caldeira D, Barra M, Gonçalves N, et al. Pericardial bleeding risk with non-vitamin K oral anticoagulants: a meta-analysis. *Int J Cardiol* 2015;182:187-8.
- Forbes HL, Polasek TM. Potential drug-drug interactions with direct oral anticoagulants in elderly hospitalized patients. *Ther Adv Drug Saf* 2017;8:319-28.
- Chang S-H, Chou I-J, Yeh Y-H, et al. Association between use of non-vitamin k oral anticoagulants with and without concurrent medications and risk of major bleeding in nonvalvular atrial fibrillation. *JAMA* 2017;318:1250-9.
- Eliquis (apixaban) [prescribing information]. New York, NY: Pfizer Inc, July 2016.
- January CT, Wann LS, Calkins H, et al. 2019 AHA/ACC/HRS focused update of the 2014 AHA/ACC/HRS guideline for the management of patients with atrial fibrillation: a report of the American College of Cardiology/American Heart Association Task Force on Clinical Practice Guidelines and the Heart Rhythm Society in collaboration with the Society of Thoracic Surgeons. *Circulation* 2019;140:e125-51.
- Lopes RD, Heizer G, Aronson R, et al. Antithrombotic therapy after acute coronary syndrome or PCI in atrial fibrillation. *N Engl J Med* 2019;380:1509-24.
- Lopes RD, Hong H, Harskamp RE, et al. Safety and efficacy of antithrombotic strategies in patients with atrial fibrillation undergoing percutaneous coronary intervention: a network meta-analysis of randomized controlled trials. *JAMA Cardiol* 2019;4:74-155.
- Tomaselli GF, Mahaffey KW, Cuker A, et al. 2017 ACC expert consensus decision pathway on management of bleeding in patients on oral anticoagulants: a report of the American College of Cardiology Task Force on Expert Consensus Decision Pathways. *J Am Coll Cardiol* 2017;70:3042-67.
- Connolly SJ, Crowther M, Eikelboom JW, et al. Full study report of andexanet alfa for bleeding associated with factor Xa inhibitors. *N Engl J Med* 2019;380:1326-35.
- Gibson CM, Mehran R, Bode C, et al. Prevention of bleeding in patients with atrial fibrillation undergoing PCI. *N Engl J Med* 2016;375:2423-34.

KEY WORDS acute coronary syndrome, anticoagulation, echocardiography, hemorrhage, pericardial effusion, tamponade

APPENDIX For a supplemental video, please see the online version of this paper.