




Since January 2020 Elsevier has created a COVID-19 resource centre with free information in English and Mandarin on the novel coronavirus COVID-19. The COVID-19 resource centre is hosted on Elsevier Connect, the company's public news and information website.

Elsevier hereby grants permission to make all its COVID-19-related research that is available on the COVID-19 resource centre - including this research content - immediately available in PubMed Central and other publicly funded repositories, such as the WHO COVID database with rights for unrestricted research re-use and analyses in any form or by any means with acknowledgement of the original source. These permissions are granted for free by Elsevier for as long as the COVID-19 resource centre remains active.



## Arthritis following COVID-19 vaccination: report of two cases

Ayşe Unal Enginar \*

Ordu State Hospital, Rheumatology, Ordu, Turkey

### ARTICLE INFO

**Keywords:**  
 COVID-19  
 SARS-CoV-2  
 Arthritis  
 Vaccination  
 Vaccine

### ABSTRACT

While most patients with coronavirus disease 2019 (COVID-19) present with mild or moderate symptoms, 15% may develop severe pneumonia, 5% develop acute respiratory distress syndrome (ARDS), septic shock, and multiple organ failure. Some patients may also experience arthralgia or arthritis. Cases of reactive arthritis have been reported during or after COVID-19. With the approval of the use of COVID-19 vaccines, the vaccination program was started in our country and is still continuing. Here we present two patients who developed arthritis after COVID-19 vaccination.

### 1. Introduction

Severe acute respiratory syndrome coronavirus 2 (SARS-CoV-2) first emerged in Wuhan, China, in December 2019, and the infection spread rapidly across the world. The disease caused by the virus was named coronavirus disease 2019 (COVID-19), and was declared a global pandemic by the World Health Organisation (WHO) in March 2020 [1]. The first case of COVID-19 in Turkey was recorded in 11 March 2020 [2]. At the time of writing, the COVID-19 pandemic has infected approximately 145 million people worldwide, with 3 million deaths [3]. While the symptoms are mild or moderate in most patients, severe pneumonia can develop in 15%, and acute respiratory distress syndrome (ARDS), septic shock, and multiple organ failure in 5% [1]. With the advent of COVID-19 vaccinations, a vaccination program was started and is still ongoing in Turkey [4]. The cases are here presented of two patients who developed arthritis following COVID-19 vaccination. To the best of our knowledge, these types of cases have not been previously reported.

#### 1.1. Case 1

A 74-year-old female presented at our clinic with complaints of swelling and pain in the right hand, which had been ongoing for approximately 20 days. The pain and swelling in the right hand had started 2 days after the patient had received the first dose of SARS-CoV-2 inactive (Sinovac) vaccination administered to the left deltoid region. In the physical examination, arthritis was determined in the right wrist, the 2nd–4th metacarpophalangeal and 2nd–4th proximal interphalangeal

joints (Fig. 1). Hypertension and type II diabetes mellitus were present in the patient's history but there was no history of arthritis or rheumatic disease. The patient did not have diabetic hand syndrome. Nasopharyngeal and oropharyngeal swabs were negative for COVID-19. The pulmonary radiograph and thorax tomography examinations were normal. The patient had not contracted COVID-19. In the laboratory tests, the erythrocyte sedimentation rate (ESR) and C-reactive protein (CRP) level were elevated (ESR: 84 mm/h, CRP: 20.2 mg/dl). The full blood count, uric acid and urine analysis results were normal. Rheumatoid factor, anti-nuclear, anti-cyclic citrullinated peptide antibodies, and HLA-B27 were negative. Brucella, Hepatitis B and C, serology were negative in serum. Treatment was started of 10 mg/day prednisolone. After 1 week, the complaints of the patient were reduced and the ESR and CRP values had decreased. A program of tapering prednisolone was applied. While using 5 mg/day prednisolone, the patient received the second dose of SARS-CoV-2 inactive (Sinovac) vaccination and no side-effects developed. The arthritis did not recur.

#### 1.2. Case 2

A 76-year-old male presented at our clinic with complaints of pain and swelling in the left hand that had been ongoing for 10 days. The pain and swelling in the left hand had started 1 week after the patient had received the second dose of SARS-CoV-2 inactive (Sinovac) vaccination administered to the right deltoid region. In the physical examination, with the exception of the left hand distal interphalangeal joints, arthritis was determined in all the joints (Fig. 2). Cervical and lumbar movements were limited and the hip joint range of movement was restricted. An

\* Corresponding author.

E-mail address: [frdrayseenginar@gmail.com](mailto:frdrayseenginar@gmail.com).

<https://doi.org/10.1016/j.intimp.2021.108256>

Received 8 August 2021; Received in revised form 8 October 2021; Accepted 10 October 2021

Available online 15 October 2021

1567-5769/© 2021 Elsevier B.V. All rights reserved.

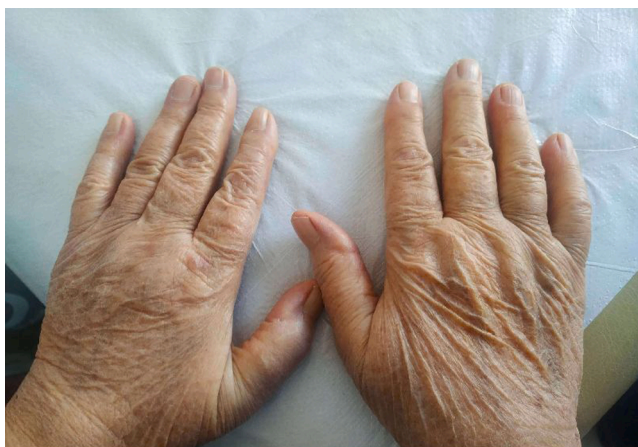


Fig. 1. Right hand arthritis.

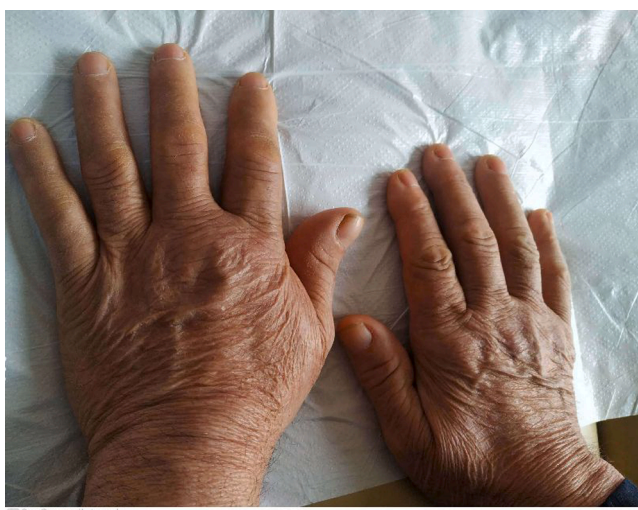

Fig. 2. Left hand arthritis.

increase was seen in thoracic kyphosis. In the patient history, there was seen to be ankylosing spondylitis for approximately 30 years. There was no history of peripheral arthritis or psoriasis. The patient had been previously followed up at another centre and had used non-steroid anti-inflammatory drugs (NSAID) at different times. Sulfasalazine was used for approximately 7–8 years, but not in the last 10 years. Infliximab was used for 6 years with the last dose taken approximately 2 years ago. For the last 2 years the patient had used low-dose NSAID or paracetamol when in pain. Nasopharyngeal and oropharyngeal swabs were negative for COVID-19. The pulmonary radiograph examination was normal. The patient had not contracted COVID-19. In the laboratory tests, ESR and CRP were elevated (ESR: 85 mm/h, CRP: 11.2 mg/dl). The full blood count, uric acid and urine analysis results were normal. Rheumatoid factor, anti-nuclear, and anti-cyclic citrullinated peptide antibodies were negative. HLA-B27 was positive. Brucella, Hepatitis B and C, serology were negative in serum. Treatment was started of 10 mg/day prednisolone. The complaints of the patient were reduced during follow up and a steroid tapering program was applied. The arthritis did not recur.

## 2. Discussion

Vaccinations are the primary tool in combating infectious diseases. However, local, systemic, and autoimmune (autoimmune/inflammatory

syndrome induced by adjuvants [ASIA syndrome]) side-effects have been reported associated with vaccinations. It is thought that vaccinations can trigger or develop autoimmunity, although the effect mechanism is not fully known [5]. It has been reported that this may be caused by the immunogenic content (inactivated virus) or adjuvants found in the vaccination. Therefore, while vaccines prevent the development of autoimmune diseases triggered by infections, autoimmunity can also be triggered after vaccination.

Risk factors for ASIA syndrome include a history of autoimmune phenomenon following vaccination, a history of autoimmunity or allergic reaction especially to vaccinations, family history of autoimmunity, or being an asymptomatic autoantibody carrier [6]. Autoimmune conditions such as arthritis, systemic lupus erythematosus, diabetes mellitus, thrombocytopenia, vasculitis, dermatomyositis, and Guillain-Barré syndrome have been reported to be seen following vaccinations [7].

Arthritis was reported in 2 cases following the diphtheria, poliomyelitis, and tetanus toxoid combined vaccination. The first case was a 17-year-old female who developed arthritis in the right knee 12 days after vaccination, and was applied with synovectomy as no response was obtained to intra-articular steroids. The second case was a 22-year-old female who developed arthritis in the right ankle one day after vaccination, and recovered in 3 days with NSAID treatment [8]. In another case report, a patient who developed reactive arthritis after tetanus vaccination is presented [9].

In a study by Geier et al, a significant correlation was determined between adult hepatitis B and rubella vaccinations and chronic arthritis. Following rubella vaccination, arthritis was determined 3-fold more in females than males. The mean age was approximately 45 years and arthritis developed within a period of mean 10–11 days after the vaccination. Following hepatitis B vaccination, arthritis was seen 3.5-fold more in females than in males. The mean age was mean 33 years and arthritis was determined approximately 16 days after the vaccination [10]. Asakawa et al presented the case of a 79-year-old male who developed migratory polyarthritis starting from the 4th metacarpophalangeal joint 2 days after an influenza vaccination [11].

There are also case reports in literature of reactive arthritis developing during or after COVID-19 infection [12,13]. Ono et al reported the development of bilateral ankle arthritis in a 50-year-old male patient on the 21st day after extubation following 11 days of intubation because of COVID-19 pneumonia. The complaints recovered with NSAID and intra-articular steroids [12]. Lopez et al reported 4 cases of males aged 45–71 years who developed arthritis during COVID-19 infection. Arthritis was seen in the knee, ankle, and 1st metatarsophalangeal joints. The time interval from the onset of COVID-19 symptoms to the onset of arthritis was approximately 8–27 days. A history of gout was present in 3 of the 4 patients [13]. Left elbow arthritis was reported 1 week after vector-based SARS-CoV-2 vaccination [14]. In another case report, a patient who developed reactive arthritis 1 week after inactive SARS-CoV-2 vaccination is presented [15]. Watad et al. presented 27 patients with post-vaccine attack or newly developed immune-mediated disease. Unlike my cases, the majority of vaccines are mRNA vaccines and only 2 are vector-based vaccines. 21 patients had autoimmune or rheumatic disease prior to vaccination. 17 patients developed flare and 10 patients developed new-onset immune-mediated disorders. Polymyalgia rheumatica, myasthenia gravis, arthritis and skin manifestations have been reported [16]. We cannot talk about a definite causal relationship between arthritis and vaccine. However, these post-vaccination disorders should be closely monitored.

Sinovac, which is one of the COVID-19 vaccinations, is an inactive vaccination and contains alum as an adjuvant [4]. The two patients presented in this paper were administered the vaccinations in a hospital. Arthritis developed 2 days after the first dose in one patient and 7 days after the second dose in the other patient. Both patients were elderly. In Turkey, individuals aged 65 and over were vaccinated in the first place after health personnel. In both cases, arthritis developed on the side

contralateral to where the vaccination had been administered. Treatment with steroids was effective in both cases.

Although there is a lack of reporting of all the vaccinations worldwide, autoimmune reactions develop in approximately 0.01% and most of these are mild and self-limiting findings [6]. Vaccination is of critical importance for infectious diseases and in the current global situation of the COVID-19 pandemic. Further studies with the reporting of arthritis related to COVID-19 and vaccinations will be able to provide more clarification.

#### Declaration of Competing Interest

The authors declare that they have no known competing financial interests or personal relationships that could have appeared to influence the work reported in this paper.

#### References

- [1] C. Huang, et al., Clinical features of patients infected with 2019 novel coronavirus in Wuhan, China, *Lancet* 395 (2020) 497–506.
- [2] Z.K. Tufan, B. Kayaaslan, Crushing the curve, the role of national and international institutions and policy makers in COVID-19 pandemic, *Turk. J. Med. Sci.* 50 (2020) 495–508.
- [3] Johns Hopkins University & Medicine Coronavirus Resource Center, <https://coronavirus.jhu.edu/map.html>.
- [4] S. Kashte, A. Gulbake, S.F. El-Amin III, A. Gupta, COVID-19 Vaccines: Rapid Development, Implications, Challenges and Future Prospects, *Hum. Cell.* 34 (3) (2021) 711–733, <https://doi.org/10.1007/s13577-021-00512-4>.
- [5] E. Shoenfeld, A. Aron-Maor, Vaccination and autoimmunity-vaccinosis: a dangerous liaison, *J. Autoimmun.* 14 (2000) 1–10.
- [6] A. Soriano, G. Neshet, Y. Shoenfeld, Predicting post-vaccination autoimmunity: who might be at risk? *Pharmacol. Res.* 92 (2015) 18–22.
- [7] C. Perricone, S. Colafrancesco, R.D. Mazar, A. Soriano, N. Agmon-Levin, Y. Shoenfeld, Autoimmune/inflammatory syndrome induced by adjuvants (ASIA): unveiling the pathogenic, clinical and diagnostic aspects, *J. Autoimmun.* (2013) 1–16.
- [8] J.F. Mailliefert, I. Tonolli-Serabian, A. Cherasse, et al., Arthritis following combined vaccine against diphtheria, polyomyelitis, and tetanus toxoid, *Clin. Exp. Rheumatol.* 18 (2000) 255–256.
- [9] N. Sahin, A. Salli, A.U. Enginar, H. Ugurlu, Reactive arthritis following tetanus vaccination: a case report, *Mod. Rheumatol.* 19 (2) (2009) 209–211.
- [10] D.A. Geier, M.R. Geier, A one year followup of chronic arthritis following rubella and hepatitis B vaccination based upon analysis of the Vaccine Adverse Events Reporting System (VAERS) database, *Clin. Exp. Rheumatol.* 20 (2002) 767–771.
- [11] J. Asakawa, S. Kobayashi, K. Kaneda, H. Ogasawara, M. Sugawara, M. Yasuda, H. Hashimoto, Reactive arthritis after influenza vaccination: report of a case, *Modern Rheumatol.* 15 (4) (2005) 283–285.
- [12] K. Ono, M. Kishimoto, T. Shimasaki, H. Uchida, D. Kurai, G.A. Deshpande, Y. Komagata, S. Kaname, Reactive arthritis after COVID-19 infection, *RMD Open* 6 (2) (2020) e001350, <https://doi.org/10.1136/rmdopen-2020-001350>.
- [13] M.D. López-González, M.L. Peral-Garrido, I. Calabuig, et al., Case series of acute arthritis during COVID-19 admission, *Ann. Rheum. Dis.* (2020), <https://doi.org/10.1136/annrheumdis-2020-217914>.
- [14] C. Baimukhamedov, Arthritis of the left elbow joint after vaccination against SARS-CoV-2 infection, *Int. J. Rheum. Dis.* 24 (9) (2021) 1218–1220.
- [15] Q.J. An, D.A. Qin, J.X. Pei, Reactive arthritis after COVID-19 vaccination, *Hum. Vaccin. Immunother.* 17 (9) (2021) 2954–2956.
- [16] A. Watad, G. De Marco, H. Mahajna, A. Druyan, M. Entity, et al., Immune-mediated disease flares or new-onset disease in 27 subjects following mRNA/DNA SARS-CoV-2 vaccination, *Vaccines* 9 (5) (2021) 435.