



CASE REPORT

REVISED Case Report: An occurrence of steinstrasse in retrograde intra renal surgery (RIRS) for large staghorn kidney stone: a difficult experience in managing surgical outcomes [version 2; peer review: 2 approved]

Previously titled: Case Report: An occurrence of steinstrasse in retrograde intra renal surgery for large staghorn kidney stone: a difficulty managing surgical outcomes

Ponco Birowo , Nur Rasyid , Widi Atmoko , Bobby Sutojo

Department of Urology, Faculty of Medicine Universitas Indonesia - Cipto Mangunkusumo Hospital, Jakarta Pusat, DKI Jakarta, 10430, Indonesia

V2 First published: 12 Mar 2020, 9:184
<https://doi.org/10.12688/f1000research.22448.1>
 Latest published: 29 May 2020, 9:184
<https://doi.org/10.12688/f1000research.22448.2>

Abstract

Immediate removal of staghorn kidney stones is important to prevent life-threatening complications. With the advancement of endoscopic technology, retrograde intrarenal surgery (RIRS) is now an alternate treatment to the standard percutaneous nephrolithotomy (PCNL) for stones removal. However, when used to treat large stones (>3cm), RIRS can cause the formation steinstrasse (SS). Here, we present the case of a 68-year-old man with multiple stones in the collecting system of the right kidney after initial treatment with RIRS. After two years of multiple interventions, the SS was completely removed. To prevent this complication in patients, a detailed assessment of the stone (size, location) and renal anatomy should be completed before RIRS is performed.

Keywords

retrograde intrarenal surgery, staghorn stones, steinstrasse, complication

Open Peer Review

Reviewer Status

	Invited Reviewers	
	1	2
version 2 (revision) 29 May 2020	 report	 report
version 1 12 Mar 2020	 report	 report

- 1 **Doddy Soebadi** , Airlangga University, Surabaya, Indonesia
- 2 **Hammad Ather** , Aga Khan University, Karachi, Pakistan

Any reports and responses or comments on the article can be found at the end of the article.

Corresponding author: Ponco Birowo (ponco.birowo@gmail.com)

Author roles: **Birowo P:** Conceptualization, Data Curation, Formal Analysis, Funding Acquisition, Investigation, Methodology, Project Administration, Resources, Supervision, Visualization, Writing – Review & Editing; **Rasyid N:** Conceptualization, Data Curation, Formal Analysis, Supervision; **Atmoko W:** Conceptualization, Data Curation, Formal Analysis, Methodology, Validation, Visualization; **Sutojo B:** Conceptualization, Visualization, Writing – Original Draft Preparation

Competing interests: No competing interests were disclosed.

Grant information: The author(s) declared that no grants were involved in supporting this work.

Copyright: © 2020 Birowo P *et al.* This is an open access article distributed under the terms of the [Creative Commons Attribution License](#), which permits unrestricted use, distribution, and reproduction in any medium, provided the original work is properly cited.

How to cite this article: Birowo P, Rasyid N, Atmoko W and Sutojo B. **Case Report: An occurrence of steinstrasse in retrograde intra renal surgery (RIRS) for large staghorn kidney stone: a difficult experience in managing surgical outcomes [version 2; peer review: 2 approved]** F1000Research 2020, 9:184 <https://doi.org/10.12688/f1000research.22448.2>

First published: 12 Mar 2020, 9:184 <https://doi.org/10.12688/f1000research.22448.1>

REVISED Amendments from Version 1

We have addressed each of the Reviewer's critiques point by point and incorporated appropriate revisions into the text of the manuscript. This includes revisions to the title, introduction, discussion and case presentation sections, with these changes reflected in the abstract. We have changed [Figure 1](#), updated [Table 1](#) and added references as suggested by the reviewer.

Any further responses from the reviewers can be found at the end of the article

Introduction

The term "staghorn" describes the configuration of large, branched renal stones that occupy the pelvis and extend to at least two renal calyces. Immediate removal of the stones is compulsory to prevent serious kidney injury and life-threatening sepsis¹. According to the American Urological Association, percutaneous nephrolithotomy (PCNL) is the standard treatment for staghorn removal². Recently, urologists have started using retrograde intrarenal surgery (RIRS) to treat large stones as it is less invasive and simpler than PCNL³. However, RIRS might cause the formation of steinstrasse (SS), especially in large stones (2–3 cm) cases, which requires a series of interventions. This multiple procedure approach to renal stone treatment can impact patient quality of life, especially when the stone is hard (> 1000 Hounsfield Units)^{4,5}.

The aim of this study is to address the formation of SS and the impact of prolonged treatment on the patient's psychological health following the use of RIRS for large staghorn stone removal.

Case presentation

A 68-year-old man came to our hospital in April 2016 with multiple stones in the collecting system of his right kidney. He had been experiencing flank pain that was not influenced by body position for one month. He denied any treatment relating to the pain that he experienced in this period. He also

denied having a family history of this symptom or ever having this symptom before. Physical examination revealed only right flank tenderness.

Computed tomography (CT) urography at the previous hospital showed a staghorn stone at the right inferior calyx with a size of 45.7 × 59.3 × 27.5 mm (stone hardness in Hounsfield unit was not available) with a grade 3 right-side hydronephrosis and left kidney cyst. ([Figure 1](#)). Post-RIRS imaging showed a double J (DJ) stent with multiple tiny stones from the right pelvis-calices to vesicoureteral junction ([Figure 2a](#)).

A month later, when the patient came to our hospital for a second opinion, his kidney-ureter-bladder (KUB) imaging result had not changed ([Figure 2b](#)). Right ureteroscopy (URS), right nephrostomy, and right PCNL were performed and post-operative KUB imaging was conducted ([Figure 3a](#)). Another right URS was performed two weeks later, showing the remaining 8-mm stone at the ureter-pelvic junction (UPJ; [Figure 3b](#)).

Extracorporeal shock wave lithotripsy (ESWL) had been performed twice in June 2016, resulting in a decrease stone size to 6 mm. ([Figure 3c](#)). Another ESWL was performed the next month ([Figure 3d](#)). In July 2016, the patient underwent a right laser URS followed by replacement of the DJ stent ([Figure 3e](#)). Three months later, another ESWL was performed ([Figure 3f](#)). Shortly after, the remaining DJ stent was removed. KUB imaging still showed residual right nephrolithiasis. ([Figure 3g](#)). In 2017, the patient presented with significant depression that he attributed to the numerous procedures, and he decided to end the treatment for his remaining stone. He reported a lack of spirit throughout the day since the failure of the last ESWL procedure and had a feeling that this stone would never be adequately treated, and his constant need for pain medication would continue.

Almost two years later (January 2018), routine KUB imaging and CT urography showed no change in his right nephrolithiasis ([Figure 3h, i](#)). In June 2019, he was persuaded by his family

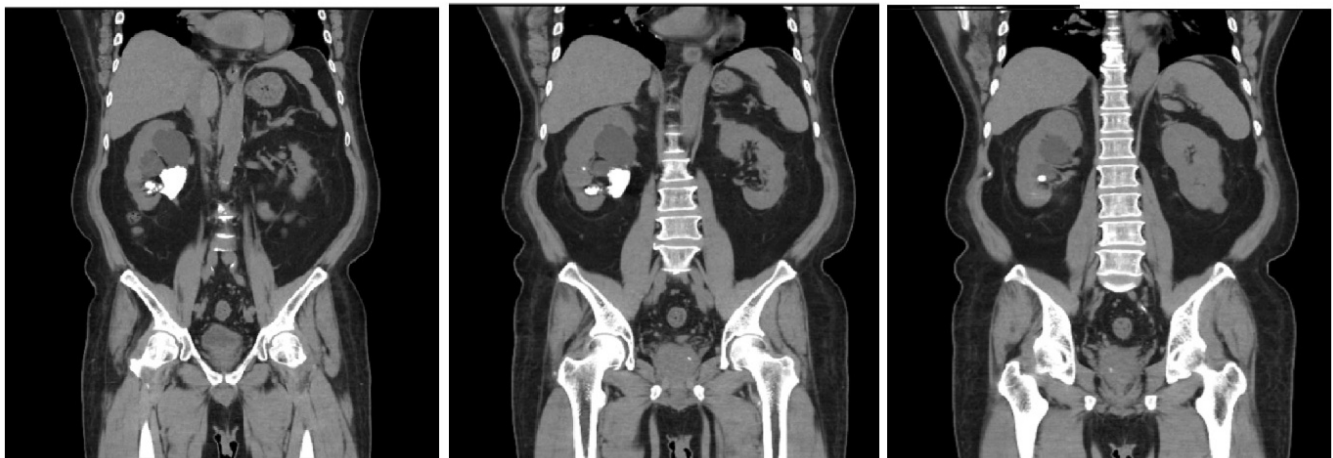

Figure 1. Initial computed tomography (CT) urography. The first CT Urography of the patient shows right staghorn stone with grade 3 hydronephrosis and left kidney cyst.

to re-try stone management and had the final RIRS at another hospital, with successful complete removal of the remaining stone (Figure 3j). In November 2019, he visited our hospital

for DJ stent removal. Neither stone nor DJ stent were observed in his KUB imaging. The summary of the patient's history of illness is presented in Table 1.

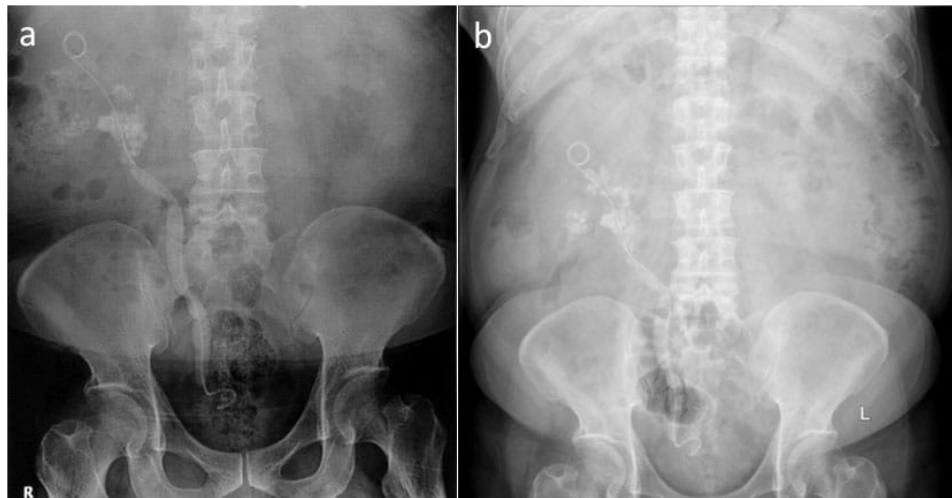


Figure 2. Steinstrasse formation. Immediate (a) and one-month (April 2016) (b) Kidney-Ureter-Bladder imaging following retrograde intrarenal surgery shows the right urinary system with multiple tiny stones.

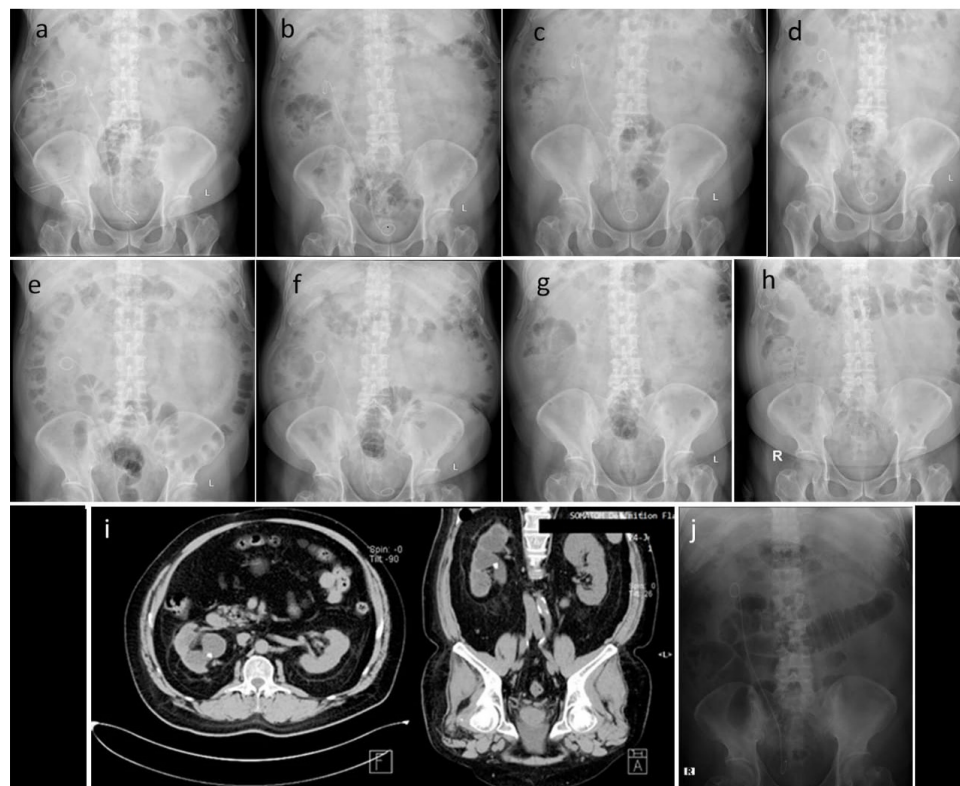


Figure 3. Sequential imaging photos. Imaging after right ureterorenoscopy, right nephrostomy, and right percutaneous nephrolithotomy in April 2016 (a), imaging after ureterorenoscopy and percutaneous nephrolithotomy in June 2016 (b), imaging after the second extracorporeal shock wave lithotripsy in June 2016 (c), imaging after the third extracorporeal shock wave lithotripsy in July 2016 (d), imaging after right laser ureterorenoscopy and replacement of right double J stent in July 2016 (e), imaging after extracorporeal shock wave lithotripsy in October 2016 (f), imaging after double J stent removal in October 2016 (g), imaging as a routine control in January 2018 (h & i), imaging after retrograde intrarenal surgery which shows no residual stone in June 2019 (j).

Table 1. Summary of the patient's history of illness.

Time	Initial condition	Procedure	Result
December 2015	KUB Imaging showed right staghorn stone (45.7 × 59.3 × 27.5 mm); Grade 3 hydronephrosis	RIRS and DJ stent insertion	Multiple tiny stones along the right urinary system from pelvio-calyces to vesico-ureteral junction (Figure 2)
April 2016	KUB imaging showed multiple tiny stones along the right urinary system from pelvio-calyces to vesico-ureteral junction	Right URS; Right nephrostomy; Right PCNL; Insertion of a new DJ stent	A remaining radio opaque stone with a diameter of 8 mm at the ureteropelvic junction (Figure 3a)
June 2016	KUB imaging showed an 8 mm radio opaque stone	ESWL twice	The stone size was decreased to 6 mm (Figure 3b, c)
July 2016	KUB imaging showed a 6 mm radio opaque stone	ESWL; DJ stent replacement; Right laser URS	Small residual stones at the right kidney (Figure 3d, e)
October 2016	A residual right nephrolithiasis	ESWL; DJ stent removal	A residual right nephrolithiasis (Figure 3f)
January 2018	KUB imaging and CT urography showed right nephrolithiasis	N/A	Figure 3g
June 2019	CT urography showed right nephrolithiasis	RIRS and DJ stent insertion	Right DJ stent <i>in situ</i> ; No residual stone (Figure 3h, i)
November 2019	Right DJ stent <i>in situ</i> ; No residual stone	DJ stent removal	No stone was found on the final KUB imaging (Figure 3j)

CT, computed tomography; DJ, double J; ESWL, extracorporeal shock wave lithotripsy; KUB, kidney-ureter-bladder; PCNL, percutaneous nephrolithotomy; RIRS, retrograde intrarenal surgery; URS, Ureteroscopy.

Discussion

The management of nephrolithiasis has changed dramatically over time, shifting from open surgery to less-invasive procedures, such as PCNL and ESWL⁶. According to the American Urological Association and European Association of Urology guidelines, the standard treatment for staghorn stone removal is PCNL^{2,5}. PCNL has a high stone-free rate (SFR), similar to that of an open surgery (93%). It also results in lower morbidity, shorter operative time, shorter hospital stays, and earlier back to work compared to open surgery. However, it can cause severe complications, such as renal trauma with severe uncontrollable bleeding^{7,8}.

On the other hand, the development of flexible ureteroscopes allows for excellent visualization that makes RIRS a favourable procedure for most urologists. The possibility to use holmium lasers along with the ureteroscope, and lower cost compared to the other treatment methods, has made this procedure even more popular⁹. Initially, the use of RIRS is limited to patients who cannot undergo PCNL or ESWL due to several contraindications. However, with the development of technology, the usage of RIRS for large stone is now possible. Compared to PCNL, RIRS has a slightly lower SFR of 87% and also lower morbidity and complication rate of 2%¹⁰. In our case, use of RIRS instead of PCNL as the first treatment was due to the patient's preference for a less invasive method.

RIRS is a less-invasive procedure compare to PCNL. Complications may arise intra- or post-operatively in some cases but are usually minor and manageable. The common complications

of RIRS include hemorrhage, intrapelvic hematoma, mucosal injury, ureteral perforation and avulsion, urinary tract infection, and sepsis¹¹. In a study by Niwa *et al.*, the most common complication associated with RIRS in treating staghorn stones was urinary tract infection (Clavien-Dindo II, 28.2%), followed by fever (7.7%), general malaise (2.6%), and malposition of a ureteral stent (2.6%)¹².

In Indonesia, PCNL is still the first choice for treating large renal calculi according to *Ikatan Ahli Urologi Indonesia* (the Indonesian Urologist Association). However, the use of PCNL in Indonesia is still limited due to the lack of technology and expertise, particularly in remote areas¹³. The incidence of SS formation after RIRS is 20% among those with large renal stone, while hydronephrosis is also common⁴. The development of SS was also observed in the patient we have described, who was initially treated with RIRS. To address this complication, a scoring system was developed by Resorlu *et al.* that includes four indicators: a renal stone size >20 mm, lower pole stone with an infundibulum-pelvic angle <45°, a stone number in different calyces >1, and abnormal renal anatomy¹⁴. A greater score is associated with a lower SFR. This score can be calculated prior to RIRS.

Another efficacy parameter for RIRS is stone composition. According to a study by Xue *et al.*, stones that are made of calcium oxalate dihydrate, uric acid, and magnesium ammonium phosphate show an excellent response to RIRS treatment¹⁵. Unfortunately, in the present case, the stone composition was not analyzed due to financial constraints.

In the previous hospital, the ureteral stent was placed after RIRS treatment. The necessity for routine stent insertion before or after RIRS to increase stone clearance remains unclear. The primary purpose of stent insertion is to prevent ureteral stricture, accelerate healing, and facilitate stone passing¹⁶. On the other hand, stent insertion increases the possibility of urinary tract infection, dysuria, pollakiuria, hematuria, and may require repeated cystoscopy in cases of stent migration and need for extraction¹⁷. Stent insertion before ESWL does not eliminate the need for intervention in the management of SS¹⁸. In cases like the one we have presented, considering the size and the position of the stone, ureteral stent placement before RIRS would be difficult and other options should be considered.

Urolithiasis is a painful chronic disease that has significantly impacts on a patient's quality of life. In addition to chronic pain, the acute pain of urolithiasis resulting from stone movement often causes fear of recurrence. Recent studies have suggested an association between the disease and anxiety and depression¹⁹. In the present study, our patient developed symptoms of depression during the second year of his treatment because he had to undergo multiple surgical procedures within a year to remove the SS. In addition, the patient had to endure the pain associated with recovery after each procedure, as well as the pain caused by the remaining stone. After receiving support from his family and reassurance by clinicians, the patient was finally convinced to continue with treatment for his remaining stones.

RIRS may be used in cases where open surgery and ESWL are risky or inadequate, such as in patients with obesity, bleeding disorders, musculoskeletal deformities, renoureteral malformations, and infundibular stenosis¹⁶.

This study was limited in that we did not know the hardness (Hounsfield units) of the patient's stone before he visited our clinic; therefore, we could not more precisely determine the cause of his previous treatment failure, as our characterization was based only on the size of the stone.

Conclusions

RIRS is not the preferred option for removal of large stag-horn calculi due to low efficacy and other possible complications. However, it can be used in circumstances where open surgery or PCNL are not possible. Careful assessment is essential to determine whether the procedure will be beneficial and safe for the patient.

Data availability

All data underlying the result are available as part of the article and no additional source data are required.

Consent

Written informed consent for publication of their clinical details and/or clinical images was obtained from the patient/parent/guardian/relative of the patient.

References

- Healy KA, Ogan K: **Pathophysiology and management of infectious staghorn calculi.** *Urol Clin N Am.* 2007; **34**(3): 363–74. [PubMed Abstract](#) | [Publisher Full Text](#)
- Preminger GM, Assimos DG, Lingeman JE, et al.: **Chapter 1: AUA guideline on management of staghorn calculi: diagnosis and treatment recommendations.** *J Urol.* 2005; **173**(6): 1991–2000. [PubMed Abstract](#) | [Publisher Full Text](#)
- Zengin K, Tanik S, Karakoyunlu N, et al.: **Retrograde intrarenal surgery versus percutaneous lithotripsy to treat renal stones 2-3 cm in diameter.** *Biomed Res Int.* 2015; **2015**: 914231. [PubMed Abstract](#) | [Publisher Full Text](#) | [Free Full Text](#)
- Hyams ES, Munver R, Bird VG, et al.: **Flexible ureterorenoscopy and holmium laser lithotripsy for the management of renal stone burdens that measure 2 to 3 cm: a multi-institutional experience.** *J Endourol.* 2010; **24**(10): 1583–1588. [PubMed Abstract](#) | [Publisher Full Text](#)
- Turk C, Neisius A, Petrik A, et al.: **EAU Guidelines on Urolithiasis.** 2018. [Reference Source](#)
- Yuri P, Hariwibowo R, Soeroharjo I, et al.: **Meta-analysis of Optimal Management of Lower Pole Stone of 10 - 20 mm: Flexible Ureteroscopy (FURS) versus Extracorporeal Shock Wave Lithotripsy (ESWL) versus Percutaneous Nephrolithotomy (PCNL).** *Acta Med Indones.* 2018; **50**(1): 18–25. [PubMed Abstract](#)
- Al-kohlany KM, Shokeir AA, Mosbah T, et al.: **Treatment of complete staghorn stones: a prospective randomized comparison of open surgery versus percutaneous nephrolithotomy.** [abstract]. *J Urol.* 2005; **173**(2): 469–73. [PubMed Abstract](#) | [Publisher Full Text](#)
- El-Nahas AR, Shokeir AA, El-Assmy AM, et al.: **Post-percutaneous nephrolithotomy extensive hemorrhage: a study of risk factors.** *J Urol.* 2007; **177**(2): 576–9. [PubMed Abstract](#) | [Publisher Full Text](#)
- Krambeck AE, Murat FJ, Gettman MT, et al.: **The evolution of ureteroscopy: a modern single-institution series.** *Mayo Clin Proc.* 2006; **81**(4): 468–73. [PubMed Abstract](#) | [Publisher Full Text](#)
- Prabhakar M: **Retrograde ureteroscopic intrarenal surgery for large (1.6-3.5 cm) upper ureteric/renal calculus.** *Indian J Urol.* 2010; **26**(1): 46–9. [PubMed Abstract](#) | [Publisher Full Text](#) | [Free Full Text](#)
- Kilic O, Akand M: **Retrograde intrarenal surgery for renal stones.** [internet]. *Recent Advances in Urology.* [Reference Source](#)
- Niwa N, Matsumoto K, Ohigashi T, et al.: **Clinical outcomes of retrograde intrarenal surgery as a primary treatment for staghorn calculi: a single-center experience.** *Clin Med Insights Urol.* 2019; **12**: 1–6. [PubMed Abstract](#) | [Publisher Full Text](#)
- Rasyid N, Kusuma GW, Atmoko W, editor: **Ikatan Ahli Urologi Indonesia: Panduan penatalaksanaan klinis batu saluran kemih Edisi pertama.** Jakarta. 2018. [Reference Source](#)
- Resorlu B, Unsal A, Gulec H, et al.: **A new scoring system for predicting stone-free rate after retrograde intrarenal surgery: the "resorlu-unsal stone score".** *Urology.* 2012; **80**(3): 512–8. [PubMed Abstract](#) | [Publisher Full Text](#)
- Xue Y, Zhang P, Yang X, et al.: **The effect of stone composition on the efficacy of retrograde intrarenal surgery: kidney stones 1-3 in diameter.** *J Endourol.* 2015; **29**(5): 537–41. [PubMed Abstract](#) | [Publisher Full Text](#)
- Cleyenbreugel BV, Kilic O, Akand M: **Retrograde intrarenal surgery for renal stones-part 1.** *Turk J Urol.* 2017; **43**(2): 112–21. [PubMed Abstract](#) | [Free Full Text](#)
- Ozyuvall E, Resorlu B, Oguz U, et al.: **Is routine ureteral stenting really necessary after retrograde intrarenal surgery?** *Arch Ital Urol Androl.* 2015; **87**(1): 72–5. [PubMed Abstract](#) | [Publisher Full Text](#)
- Ather MH, Shrestha B, Mehmood A: **Does ureteral stenting prior to Shock Wave Lithotripsy influence the need for intervention in steinstrasse and related complications?** *Urol Int.* 2009; **83**(2): 222–5. [PubMed Abstract](#) | [Publisher Full Text](#)
- Lien CS, Huang CP, Chung CJ, et al.: **Increased risk of anxiety among patients with urolithiasis: A nationwide population-based cohort study.** *Int J Urol.* 2015; **22**(10): 937–42. [PubMed Abstract](#) | [Publisher Full Text](#)

Open Peer Review

Current Peer Review Status:  

Version 2

Reviewer Report 06 July 2020

<https://doi.org/10.5256/f1000research.26885.r64109>

© 2020 Ather H. This is an open access peer review report distributed under the terms of the [Creative Commons Attribution License](#), which permits unrestricted use, distribution, and reproduction in any medium, provided the original work is properly cited.



Hammad Ather 

Department of Surgery, Aga Khan University, Karachi, Pakistan

The authors have successfully incorporated the suggestions and modified the manuscript. I have no further observations on the current submission (V2).

Competing Interests: No competing interests were disclosed.

I confirm that I have read this submission and believe that I have an appropriate level of expertise to confirm that it is of an acceptable scientific standard.

Reviewer Report 24 June 2020

<https://doi.org/10.5256/f1000research.26885.r64110>

© 2020 Soebadi D. This is an open access peer review report distributed under the terms of the [Creative Commons Attribution License](#), which permits unrestricted use, distribution, and reproduction in any medium, provided the original work is properly cited.



Doddy Soebadi 

Department of Urology, Faculty of Medicine, Airlangga University, Surabaya, Indonesia

The authors have revised the article from the first manuscript. The revision could be seen from the title and also in the introduction, discussion as well as the case presentation sections. We could see that the results are encouraging and make this article better in terms of the art of writing as well as from the scientific manuscript.

Competing Interests: No competing interests were disclosed.

Reviewer Expertise: General urology, voiding dysfunction, sexual medicine, endourology, laser urology.

I confirm that I have read this submission and believe that I have an appropriate level of expertise to confirm that it is of an acceptable scientific standard.

Version 1

Reviewer Report 04 May 2020

<https://doi.org/10.5256/f1000research.24773.r61757>

© 2020 Ather H. This is an open access peer review report distributed under the terms of the [Creative Commons Attribution License](#), which permits unrestricted use, distribution, and reproduction in any medium, provided the original work is properly cited.

**Hammad Ather**

Department of Surgery, Aga Khan University, Karachi, Pakistan

1. Steinstrasse is a legacy of SWL (Does ureteral stenting prior to shock wave lithotripsy influence the need for intervention in steinstrasse and related complications? (Ather *et al.*, 2009¹)) and RIRS for larger stones is no different from performing SWL under endoscopy. The authors should discuss this point.
2. Conclusions are contrary to the case account. The conclusions should be that larger stones (Staghorn) would preferably not be treated by RIRS.
3. Few minor issues:
 - In the abstract I don't agree with the word "compulsory" - a more preferable alternative would be "desirable" or "important" etc.
 - RIRS is not mentioned as a treatment option for large kidney stones.
 - Mention other complications of the use of RIRS besides steinstrasse for large renal stones.
 - The phrase "RIRS to remove a staghorn stone" in the abstract is not an appropriate reflection of the abilities of RIRS in that set up.
 - There are many grammatical errors that need attention.
 - The authors used the phrase "which led to depression in the patient after the use of RIRS for staghorn stone removal". This needs to be rephrased for clarity as to what the authors are implying. Are they saying prolonged treatment causes psychological issues, like depression? Please cite a reference.
 - In the case presentation, the authors write "multiple stones along his right urogenital system" - this needs to be rewritten for clarity. Stones were in the collecting system of the right kidney.
 - With the limited access to single section I disagree with the authors' interpretation of the CT. I see a Staghorn stone with a major component in the renal pelvis and branching calculi in lower and

middle pole calyces. There is dilatation and obstruction with ballooning of the upper pole calyx due obstruction of the infundibulum of the upper pole calyx. There is no cyst visible in these scans.

- It is grade three, not third grade hydronephrosis, which is incidentally also not clear in the CT cut shown.
- The authors should avoid using term “genitourinary”.
- What is the stone composition?

References

1. Ather MH, Shrestha B, Mehmood A: Does ureteral stenting prior to shock wave lithotripsy influence the need for intervention in steinstrasse and related complications?. *Urol Int.* 2009; **83** (2): 222-5 [PubMed Abstract](#) | [Publisher Full Text](#)

Is the background of the case’s history and progression described in sufficient detail?

No

Are enough details provided of any physical examination and diagnostic tests, treatment given and outcomes?

Yes

Is sufficient discussion included of the importance of the findings and their relevance to future understanding of disease processes, diagnosis or treatment?

Yes

Is the case presented with sufficient detail to be useful for other practitioners?

Partly

Competing Interests: No competing interests were disclosed.

Reviewer Expertise: Urolithiasis and Bladder cancer

I confirm that I have read this submission and believe that I have an appropriate level of expertise to confirm that it is of an acceptable scientific standard, however I have significant reservations, as outlined above.

Author Response 23 May 2020

Ponco Birowo, Faculty of Medicine Universitas Indonesia - Cipto Mangunkusumo Hospital, Jakarta Pusat, Indonesia

Comments from Reviewer and Author Response:

- Steinstrasse is a legacy of SWL (Does ureteral stenting prior to shock wave lithotripsy influence the need for intervention in steinstrasse and related complications? (Ather et al., 2009¹) and RIRS for larger stones is no different from performing SWL under endoscopy. The authors should discuss this point.

Author response:

We have revised and added this additional paragraph to our manuscript:

The necessity for routine stent insertion before or after RIRS to increase stone clearance remains unclear. The main purpose of stent insertion is to prevent ureteral stricture, accelerate healing, and facilitate stone passing (Cleynenbreugel, et al., 2017). On the other hand, stent insertion increases the possibility of urinary tract infection, dysuria, pollakiuria, hematuria, and repeated cystoscopy may be required in cases of stent migration and to assess the need for extraction (Ozyuvali, et al., 2015). Stent insertion before shockwave lithotripsy (SWL) does not eliminate the need for intervention in the management of steinstrasse (Ather et al., 2009). In the present case, considering the size and the position of the stone, ureteral stent placement prior to RIRS would be difficult and other options should be considered.

- Conclusions are contrary to the case account. The conclusions should be that larger stones (Staghorn) would preferably not be treated by RIRS.

Author response:

Thanks for your advice. We have revised our conclusion to become: RIRS is not the preferable option to remove large staghorn calculi due to lower efficacy and other possible complications. It can be used in circumstances where open surgery or PCNL is not possible, but careful assessment is necessary to determine whether the procedure will be beneficial and safe for the patient.

- In the abstract I don't agree with the word "compulsory" - a more preferable alternative would be "desirable" or "important" etc.

Author response:

Thank you for your advice, we have changed the word according to your advice.

- RIRS is not mentioned as a treatment option for large kidney stones.

Author response:

We have revised and added this additional paragraph to our manuscript:

Initially, the use of RIRS is limited to patients who cannot undergo PCNL or shockwave lithotripsy (SWL) due to several contraindications. However, with the development of technology, the usage of RIRS for large stone is now possible. Compared to PCNL, RIRS has a slightly lower SFR of 87% and also lower morbidity and complication rate of 2%.¹⁰ In our case, the use of RIRS instead of PCNL as the first treatment was due to the patient's preference for a less invasive method.

- Mention other complications of the use of RIRS besides steinstrasse for large renal stones.

Author response:

We have revised and added this additional paragraph to our manuscript:

RIRS is a less-invasive procedure compared to PCNL. Complications may arise intra- or post-operatively in some cases but are usually minor and manageable. The common complications of RIRS include hemorrhage, intrapelvic hematoma, mucosal injury, ureteral perforation and avulsion, urinary tract infection, and sepsis. In a study by Niwa et al., the most common complication associated with RIRS in treating staghorn stones was urinary tract infection (Clavien-Dindo II, 28.2%), followed by fever (7.7%), general malaise (2.6%), and malposition of a

ureteral stent (2.6%).

- The phrase “RIRS to remove a staghorn stone” in the abstract is not an appropriate reflection of the abilities of RIRS in that set up.

Author response:

We have revised our abstract as it is not aligned with the insight of our case presentation that do not recommend the use of RIRS for large stones removal. Here is the revised version: Immediate removal of staghorn kidney stones is important to prevent life-threatening complications. With the advancement of endoscopic technology, retrograde intrarenal surgery (RIRS) is now an alternate treatment to the standard percutaneous nephrolithotomy (PCNL) for stones removal. However, when used to treat large stones (>3cm), RIRS can cause the formation steinstrasse (SS).

- There are many grammatical errors that need attention.

Author response:

Thank you for addressing your concern. We have revised the grammatical error that we found.

- The authors used the phrase “which led to depression in the patient after the use of RIRS for staghorn stone removal”. This needs to be rephrased for clarity as to what the authors are implying. Are they saying prolonged treatment causes psychological issues, like depression? Please cite a reference.

Author response:

We have added some information to clarify this issue.

Urolithiasis is a painful chronic disease that has significant impacts on a patient’s quality of life. In addition to chronic pain, the acute pain of urolithiasis resulting from stone movement often causes fear of recurrence. Recent studies have suggested an association between the disease and anxiety and depression. In the present study, our patient developed symptoms of depression during the second year of his treatment because he had to undergo multiple surgical procedures within a year to remove the SS. In addition, the patient had to endure the pain associated with recovery after each procedure, as well as the pain caused by the remaining stones.

- In the case presentation, the authors write “multiple stones along his right urogenital system” - this needs to be rewritten for clarity. Stones were in the collecting system of the right kidney.

Author response:

Thank you for your correction. We have updated the term accordingly.

- With the limited access to a single section I disagree with the authors' interpretation of the CT. I see a Staghorn stone with a major component in the renal pelvis and branching calculi in lower and middle pole calyces. There is dilatation and obstruction with ballooning of the upper pole calyx due to obstruction of the infundibulum of the upper pole calyx. There is no cyst visible in these scans.

Author response:

Thank you for your concern. We have decided to change the picture:

- It is grade three, not third-grade hydronephrosis, which is incidentally also not clear in the CT cut shown.

Author response:

We have changed “third grade” to “grade three” hydronephrosis.

- The authors should avoid using term “genitourinary”.

Author response:

Thank you. We have altered “genitourinary” to urinary system.

- What is the stone composition?

Author response:

Unfortunately, in the present case, the stone composition was not analyzed due to financial constraints.

- This is a good example of how minimally invasive surgeries can take a long journey before they come to a satisfactory result.

Author response:

Thank you for your appreciation.

- The authors did not mention the drawbacks of these lengthy managements, i.e. the opinion from the patient side and the cost of the serial treatments.

Author response:

The patient self-funded the whole treatment but he refused to tell the amount he had to pay. As for his opinion about the lengthy procedure, the patient complained of slight depression due to the continuous pain, either from the remaining stone and from the procedures. This information is mentioned in the case presentation and discussion section.

- But this is a very good clinical experience to be one of the considerations before the urologist(s) offer this minimally invasive procedure(s).

Author response:

Thank you. We hope this study provides a handful of insight regarding the disadvantage of RIRS to treat large kidney stone.

Competing Interests: No competing interests were disclosed.

Reviewer Report 14 April 2020

<https://doi.org/10.5256/f1000research.24773.r61758>

© 2020 Soebadi D. This is an open access peer review report distributed under the terms of the [Creative Commons Attribution License](#), which permits unrestricted use, distribution, and reproduction in any medium, provided the original work is properly cited.



Doddy Soebadi 

Department of Urology, Faculty of Medicine, Airlangga University, Surabaya, Indonesia

- This is a good example of how minimally invasive surgeries can take a long journey before they come to a satisfactory result.
- The authors did not mention the drawbacks of these lengthy managements, i.e. the opinion from the patient side and the cost of the serial treatments.
- But this is a very good clinical experience to be one of the considerations before the urologist(s) offer this minimally invasive procedure(s).

Is the background of the case's history and progression described in sufficient detail?

Yes

Are enough details provided of any physical examination and diagnostic tests, treatment given and outcomes?

Yes

Is sufficient discussion included of the importance of the findings and their relevance to future understanding of disease processes, diagnosis or treatment?

Yes

Is the case presented with sufficient detail to be useful for other practitioners?

Yes

Competing Interests: No competing interests were disclosed.

Reviewer Expertise: General urology, voiding dysfunction, sexual medicine, endourology, laser urology.

I confirm that I have read this submission and believe that I have an appropriate level of expertise to confirm that it is of an acceptable scientific standard.

The benefits of publishing with F1000Research:

- Your article is published within days, with no editorial bias
- You can publish traditional articles, null/negative results, case reports, data notes and more
- The peer review process is transparent and collaborative
- Your article is indexed in PubMed after passing peer review
- Dedicated customer support at every stage

For pre-submission enquiries, contact research@f1000.com

F1000Research