



Dexamethasone does not affect endolymphatic hydrops (EH) in patients with Meniere's disease within 24 h, and intratympanic administration of gadolinium plus dexamethasone simplifies high-quality imaging of EH using a novel protocol of 7 min[☆]

Jing Zou^{a, c, *}, Zikai Zhao^a, Hongbin Li^a, Guoping Zhang^a, Qing Zhang^a, Jianping Lu^b, Ilmari Pyykkö^d

^a Department of Otolaryngology-Head and Neck Surgery, Changhai Hospital, Second Military Medical University, Shanghai, China

^b Department of Radiology, Changhai Hospital, Second Military Medical University, Shanghai, China

^c Faculty of Information Technology and Communication Sciences, Tampere University, Tampere, Finland

^d Hearing and Balance Research Unit, Field of Otolaryngology, School of Medicine, Faculty of Medicine and Health Technology, Tampere University, Tampere, Finland

ARTICLE INFO

Article history:

Received 25 January 2022

Received in revised form

23 February 2022

Accepted 28 February 2022

Keywords:

Meniere's disease

Endolymphatic hydrops

MRI

Contrast agent

Therapeutics

Topical administration

ABSTRACT

Background: Intratympanic administration of gadolinium chelate allows for a better visualization of endolymphatic hydrops (EH) using MRI than intravenous injection and was recently further improved to facilitate high-quality imaging of EH in 7 min. The aim of the present study was to simplify the intratympanic administration protocol by mixing gadolinium chelate with therapeutic dexamethasone and to evaluate the effects of this mixture on the visualization of EH in MRI.

Materials and methods: In an in vitro study, the potential impact of gadolinium-diethylenetriamine pentaacetic acid (Gd-DTPA) on the stability of dexamethasone was evaluated by analyzing dynamic changes in dexamethasone with high-performance liquid chromatography (HPLC) after mixing with Gd-DTPA. Ten patients with definite Meniere's disease (MD) were recruited to study the potential interference of dexamethasone on MRI visualization of EH, and 49 patients with MD were recruited to evaluate the effect of intratympanic injection of Gd-DTPA mixed with dexamethasone on MRI of EH using a 3T MR machine and a novel heavily T2-weighted 3-dimensional fluid-attenuated inversion recovery reconstructed using a magnitude plus zero-filled interpolation (hT₂FLAIR-MZFI) sequence.

Results: The retention times and peak area of dexamethasone in HPLC were not modified by the addition of Gd-DTPA. EH grading in the cochlea and vestibule was not influenced in any ear by intratympanic injection of dexamethasone. Excellent inner ear images were obtained from all patients, and EHs with various grades were displayed. There were significant correlations between diagnosis and cochlear EH ($p < 0.01$, Spearman's Rho), between diagnosis and vestibular EH ($p < 0.01$, Spearman's Rho), and between cochlear and vestibular EH ($p < 0.01$, Spearman's Rho). The distribution of Gd-DTPA plus dexamethasone negatively correlated with the grade of vestibular EH. Injury of the endolymph-perilymph barrier was detected in one cochlea and three vestibules of 59 inner ears with MD.

Conclusions: Intratympanic administration of Gd-DTPA plus dexamethasone yielded high-quality MRI images of EH in patients with MD using a novel 7-min protocol and simplified the clinical application. Intratympanic administration of Gd-DTPA plus dexamethasone might be used to test its therapeutic effect in future work.

Level of evidence: 3.

© 2022 PLA General Hospital Department of Otolaryngology Head and Neck Surgery. Production and hosting by Elsevier (Singapore) Pte Ltd. This is an open access article under the CC BY-NC-ND license (<http://creativecommons.org/licenses/by-nc-nd/4.0/>).

[☆] This work was supported by the National Natural Science Foundation of China (81771006).

* Corresponding author. Department of Otolaryngology-Head and Neck Surgery, Changhai Hospital, Second Military Medical University, Changhai Road #168, Shanghai, 200433, China.

E-mail address: Jing.Zou@tuni.fi (J. Zou).

Peer review under responsibility of PLA General Hospital Department of Otolaryngology Head and Neck Surgery.

1. Background

Intratympanic administration of gadolinium chelate allows for a better visualization of endolymphatic hydrops (EH) using MRI than intravenous injection with respect to the uptake of contrast agents in the inner ear and potential adverse effects but adds extra work for the otologist (Naganawa et al., 2019; Nakashima et al., 2007; Pyykko et al., 2010; Zou et al., 2005). Intravenous injection of gadolinium chelate has been favored by both radiologists and otologists due to the convenience of the procedure, which is usually performed by a nurse. However, the general low concentration of gadolinium chelate in the perilymph of the inner ear reduced the diagnostic accuracy of EH even though the MRI method was improved several times (Naganawa et al., 2010, 2013, 2019; Ohashi et al., 2020). The application of intravenous injection of gadolinium chelate might be limited for patients with renal diseases due to potential complications such as nephrogenic systemic fibrosis (Pyykko et al., 2010). Intratympanic injection of corticosteroids has become a treatment option for Meniere's disease (MD) given its shortage of adverse effects and relatively good vertigo control without compromising hearing when compared with ablative treatments, such as the use of gentamicin (Basura et al., 2020; Boleas-Aguirre et al., 2008; Clyde et al., 2017; Patel et al., 2016). Intratympanic injection of dexamethasone resulted in higher perilymph steroid levels in the inner ear of animals than did intravenous injection, with variations among species (Chandrasekhar et al., 2000; Wang et al., 2011). If gadolinium chelate is included in therapeutic agents such as dexamethasone and applied intratympanically, the procedure for detecting EH using MRI will be significantly simplified while guaranteeing sufficient uploading of contrast agents in the inner ear.

There is a potential that the anti-inflammatory effect of intratympanic injection of glucocorticoid steroids could influence EH because EH may be induced by inflammation and consequential modification of the blood-endolymph barrier (Zou et al., 2007). It was reported that intratympanic injection of dexamethasone reduced EH in patients with MD after one month, as evaluated by electrocochleography (Martin-Sanz et al., 2015). An *in vitro* study on the semicircular canal duct epithelium of rats indicated that therapeutic glucocorticoids, including dexamethasone, stimulated cation absorption via epithelial sodium channels in the vestibular system (Pondugula et al., 2004). An *in vivo* study measuring mRNA levels in the cochlea of mice showed that intratympanic injection of prednisolone and dexamethasone upregulated inflammatory cytokine genes as well as ion homeostasis genes in the cochlea and that the upregulation peaked at 6 h (MacArthur et al., 2015). However, the clinical relevance and mechanism of these findings are unknown, and the inner ears of patients with MD may respond differently.

We recently reported a novel sensitive heavily T2-weighted 3-dimensional fluid-attenuated inversion recovery reconstructed using magnitude plus zero-filled interpolation (hT₂FLAIR-MZFI) sequence, to demonstrate strong and homogenous enhancement by minimum gadolinium-diethylenetriamine pentaacetic acid (Gd-DTPA) in the inner ear (including the apex). The hT₂FLAIR-MZFI yielded high-quality images with sharp borders between the endolymph and perilymph (Zou et al., 2021b). The present study aimed to analyze the potential interference of intratympanically administered dexamethasone on EH in patients with MD observed by MRI with the novel technique and test the hypothesis that EH could be evaluated by MRI after intratympanic injection of Gd-DTPA plus dexamethasone. The results of this study may also provide information on the passage of steroids from the middle ear

into the inner ear and predict the therapeutic effect.

2. Materials and methods

2.1. *In vitro* study

2.1.1. Potential impact of Gd-DTPA on the stability of dexamethasone

In principle, the behavior of dexamethasone in chromatography would be modified if it interacts with Gd-DTPA. Therefore, dynamic changes in the retention time and peak area of dexamethasone in high-performance liquid chromatography (HPLC) were analyzed after mixing with Gd-DTPA as follows: Gd-DTPA (500 mmol/L, Beijing Beilu Pharmaceutical CO., LTD, Beijing, China) was diluted 20-fold using sodium chloride injection (0.9% w/v, China Otsuka Pharmaceutical CO., LTD, Tianjin, China). Dexamethasone (5 mg, Ma An Shan Fengyuan Pharmaceutical CO., LTD, Anhui Province, China) was recovered by 0.5 mL of the abovementioned diluted Gd-DTPA, which resulted in a concentration of 10 mg/ml. For HPLC analysis, the mixtures were further diluted 8-fold using sodium chloride injection and stored at ambient temperature for 0, 24, 48, and 72 h before the measurements. The control dexamethasone sample was prepared by recovering dexamethasone with a 0.5-ml sodium chloride injection (10 mg/mL) and was further diluted 8-fold using sodium chloride injection for HPLC analysis. Gd-DTPA diluted 20-fold was used as a control Gd-DTPA sample. Three repeats were prepared for each sample. Five microliters of the abovementioned final diluted samples was added to a chromatographic column (Agilent XDB-C18, 5 μm 250 × 4.6 mm, Agilent Technologies, Inc., California, USA), which was installed in an HPLC (Ultimate 3000, Thermo Fisher Scientific, Germering, Germany). The column temperature was 25 °C, and acetonitrile/0.1% phosphoric acid at a ratio of 30/70 (v/v%) was selected as the mobile phase at a flow rate of 0.62 mL/min. The analyte was monitored spectrophotometrically at 242 nm.

2.2. *In vivo* studies

2.2.1. Participants

The clinical studies were carried out in accordance with the Code of Ethics of the World Medical Association (Declaration of Helsinki) for experiments involving humans with a subsequent update (2014), and the protocol was reviewed and approved by the ethics committee of Shanghai Changhai Hospital (CHEC 2020–107). All participants provided written informed consent. The inclusion criteria were definite or probable MD during interphase diagnosed according to the criteria of the Barany Society in 2015 (Lopez-Escamez et al., 2015). The exclusion criteria were as follows: vertigo with other origins, such as benign paroxysmal positional vertigo and diseases in the central nervous system. In total, 59 patients (aged 30–77 years, average age 51.6 years; 26 males and 34 females) who visited author JZ at the Department of Otolaryngology-Head & Neck Surgery, Changhai Hospital, Second Military Medical University, during the period from November 2020 to June 2021 were assigned to two groups. Among them, 10 patients (9 unilateral and 1 bilateral) with definite MD were assigned to the clinical study on the potential interference of intratympanically administered dexamethasone on EH of patients with MD observed by MRI, and 49 patients with definite (39) or probable (10) MD (40 unilateral and 9 bilateral sides) were assigned to the clinical study to evaluate EH after intratympanic injection of Gd-DTPA plus dexamethasone. Patients were assigned to the two different clinical study groups according to the time of their visit.

2.2.2. Potential impact of dexamethasone on the visualization of EH within 24 h in MD

Gd-DTPA was diluted 20-fold with sodium chloride injection (v/v 1:19), and 0.1 ml of the solution was injected onto the posterior upper surface of the tympanic medial wall of both ears using a specifically designed catheter passing through the perforated tympanic membrane in each patient according to the previously reported procedure (Zou et al., 2018; Zou et al., 2019; Zou et al., 2018). The perforation closed immediately after penetration, and the catheter was inserted through the tiny sanguineous edge of the trauma. The first MRI was performed 24 h after the intratympanic injection of Gd-DTPA, and then 0.1 ml of dexamethasone (10 mg/ml) was delivered to the ear presenting with EH using the same procedure as Gd-DTPA. A second MRI was performed 24 h after intratympanic administration of dexamethasone in 9 patients and 60 h after intratympanic injection of dexamethasone in 1 patient (Table 1).

2.2.3. EH observed by MRI after intratympanic injection of Gd-DTPA plus dexamethasone

The aim of the study was to realize the conclusion drawn from the above study that intratympanic dexamethasone did not influence EH detection by MRI. Therefore, dexamethasone was mixed with Gd-DTPA for MRI. The mixture of dexamethasone and Gd-DTPA was prepared as follows. Gd-DTPA was diluted 20-fold using the abovementioned protocol (v/v 1:19). Dexamethasone powder was recovered using 0.5 ml of diluted Gd-DTPA, and 0.1 ml of the mixture was injected onto the posterior upper surface of the tympanic medial wall of the middle ear on the diseased side as mentioned above. MRI was performed 24 h later (Table 1).

2.2.4. MRI measurement

MRI was performed 24 h post-intratympanic injection of a mixture of dexamethasone and Gd-DTPA using a 3T MR machine (Skyra, Siemens, Munich, Germany) equipped with a 20-channel head/neck coil (Siemens, Munich, Germany). The inner ear was imaged using T2-sampling perfection with application-optimized contrasts using a flip angle evolution (SPACE) sequence to detect potential inner ear fibrosis or vestibular schwannoma and using heavily T2-weighted 3-dimensional fluid-attenuated inversion recovery reconstructed using magnitude plus zero-filled interpolation (hT₂FLAIR-MZFI) sequence to display EH with the same parameters as a previous report (Zou et al., 2021a).

2.2.5. Image analysis

All images were sent to an advanced workstation (Leonardo, Siemens Healthcare, Germany) for further analysis by author JZ, who has more than 21 years of experience in inner ear imaging (Zou et al., 2000, 2003). A full set of images covering the cochlea and vestibule was inspected to evaluate the inner ear distribution of gadolinium together with dexamethasone. The cross-sectional slices of the cochlea and vestibule that displayed the structures of interest were selected for image analysis reporting EH. Based on morphological changes as reported in the literature, EH in the

cochlea was graded using a 3-stage scale method, and EH in the vestibule was graded using a 4-stage scale method (Bernaerts et al., 2019). The criteria of grading EH were previously described in detail (Table 2) (Zou et al., 2021a), and the criterion in the cochlea was modified as follows: when EH exists in both the basal and second turns to various degrees, the cochlear turn with more severe EH will be chosen for grading. EH in the cochlear apex was graded as 0 (no hydrops) or 1 (obvious hydrops that formed an invaginated arc). ImageJ (version 1.51j8) software was applied to evaluate vestibular EH using the ratio of the area of vestibular endolymphatic space to the total vestibular fluid space for comparison with the abovementioned 4-stage scale method (Nakashima et al., 2009). In addition, suspected injury of the endolymph-perilymph barrier was defined when merged bright images of endolymphatic and perilymphatic compartments appeared in the cochlea and/or vestibule.

2.3. Statistical analysis

IBM SPSS 27 software was used for statistical analysis. For the in vivo study on the potential impact of dexamethasone on the visualization of EH, the ratio of the area of endolymphatic space to the vestibular fluid space among patients with various degrees of vestibular EH based on morphological criteria in MRI images acquired before dexamethasone injection was compared using analysis of variance. The ratio of the area of endolymphatic space to the vestibular fluid space in the same patient in MRI obtained before and after dexamethasone injection was compared using a paired sample *t*-test. Correlations between the grade of vestibular EH using a 4-stage scale method and the ratio of the area of endolymphatic space to the vestibular fluid space were analyzed using Spearman's rho test. For the in vivo study on EH observed by MRI after intratympanic injection of Gd-DTPA plus dexamethasone, the degrees of EH in the cochlea and vestibule were compared among definite MD, probable MD, and non-symptomatic ears using Spearman's rho test. *P* < 0.05 was considered statistically significant.

3. Results

In general, all patients tolerated the intratympanic injection very well. Transient vertigo was experienced by very few patients immediately after the injection and improved without any treatment. There was no perforation left on the tympanic membrane in any patient during the follow-up.

3.1. HPLC of dexamethasone in the appearance of Gd-DTPA

As shown in Fig. 1 and Table 3, under the abovementioned chromatographic conditions, the mean retention time of dexamethasone was 5.6 min, with a mean peak area of 18486 mAU². A minor peak also appeared at a mean time of 3.8 min. The mean retention time of Gd-DTPA was 2.1 min. The retention times of dexamethasone and Gd-DTPA were not significantly modified by

Table 1
Protocol for the in vivo studies.

Study	Injection 1	Injection 2	MRI 1	MRI 2
Dexamethasone interference [#]	Gd-DTPA	Dexamethasone [§]	24 h	48 h [®]
Gd-DTPA & dexamethasone [*]	Gd-DTPA & dexamethasone		24 h	

[#] Potential interference of dexamethasone on visualization of endolymphatic hydrops (EH) in patients with Meniere's disease (MD).

^{*} EH demonstrated by MRI after intratympanic injection of Gd-DTPA mixed with dexamethasone.

[§] Performed immediately after MRI 1.

[®] Performed 60 h post injection 2 in 1 patient.

Table 2
Grading endolymphatic hydrops in the cochlea and vestibule of Meniere's disease on MRI.

Location	Grade of endolymphatic hydrops			
	0: normal	1: mild hydrops	2: marked hydrops	3: extreme hydrops
Cochlea	The interscalar septum, the scala tympani, and scala vestibuli are recognizable with the scala media normally minimally visible.	The scala media becomes nodular black area with narrow scala vestibuli.	The scala vestibuli becomes totally invisible.	Not applicable.
Vestibule	The smaller saccule and larger utricle are visibly separated and occupy less than half of the surface of the vestibule.	The saccule becomes equal to or larger than the utricle but is not yet merged with the utricle.	The saccule merges with the utricle, and the surrounding perilymphatic space appears as a bright peripheral rim.	The perilymphatic enhancement of the vestibule is no longer visible.

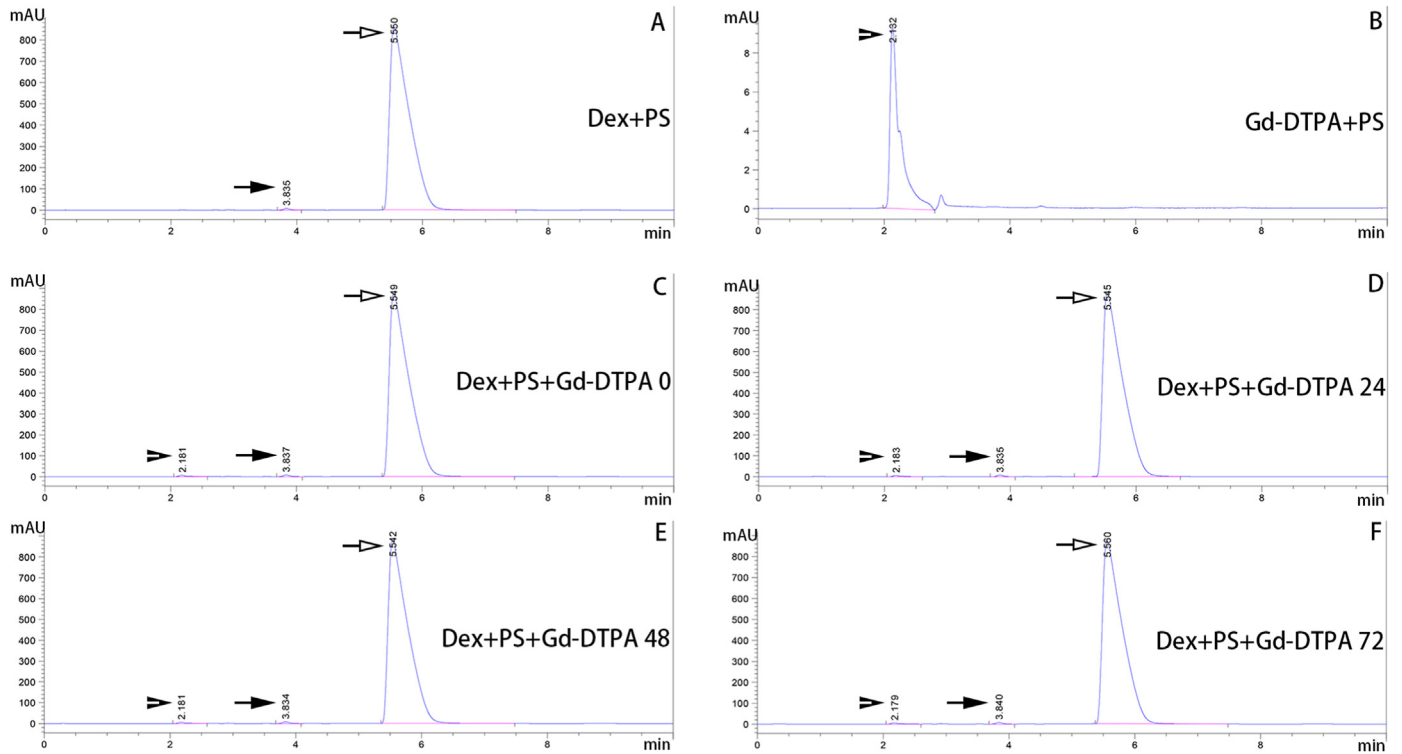


Fig. 1. Representative high-performance liquid chromatography (HPLC) chromatogram of dexamethasone with and without Gd-DTPA.

Table 3
Retention times of dexamethasone and Gd-DTPA and peak area of dexamethasone in high-performance liquid chromatography (HPLC).

Groups	n	Time (min) (mean ± SD)			Area (mAU ²) (mean ± SD)
		Dex-major	Dex-minor	Gd-DTPA	
Dex + PS	3	5.553 ± 0.002	3.837 ± 0.002		18485.733 ± 12.675
Dex + PS + Gd-0	3	5.551 ± 0.002	3.838 ± 0.001	2.182 ± 0.001	18889.800 ± 4.928
Dex + PS + Gd-24	3	5.548 ± 0.004	3.836 ± 0.002	2.183 ± 0.001	18924.167 ± 0.351
Dex + PS + Gd-48	3	5.549 ± 0.008	3.837 ± 0.004	2.182 ± 0.001	18912.200 ± 19.992
Dex + PS + Gd-72	3	5.545 ± 0.134	3.838 ± 0.006	2.181 ± 0.002	18914.067 ± 6.830
Gd + PS	3			2.133 ± 0.001	

Dex + PS: dexamethasone recovered by sodium chloride injection (physiological saline); Dex + PS + Gd-0: dexamethasone recovered by 20-fold diluted Gd-DTPA without storage time; Dex + PS + Gd-24: dexamethasone recovered by 20-fold diluted Gd-DTPA and stored at ambient temperature for 24 h; Dex + PS + Gd-48: dexamethasone recovered by 20-fold diluted Gd-DTPA and stored at ambient temperature for 48 h; Dex + PS + Gd-72: dexamethasone recovered by 20-fold diluted Gd-DTPA and stored at ambient temperature for 72 h; Gd + PS: Gd-DTPA was 20-fold diluted using physiological saline; mAU: mean arbitrary unit.

mixing the two compounds within the observation period of 72 h. The peak area of dexamethasone was insignificantly modified by the addition of Gd-DTPA during the observation period of 72 h.

3.2. Dexamethasone and visualization of EH within 24 h in MD

Twenty-four hours after the intratympanic injection of Gd-DTPA without dexamethasone, excellent enhancements of the perilymphatic spaces in both the cochlea and vestibule were achieved, and EH was demonstrated (Figs. 2 and 3). Various grades of EH were

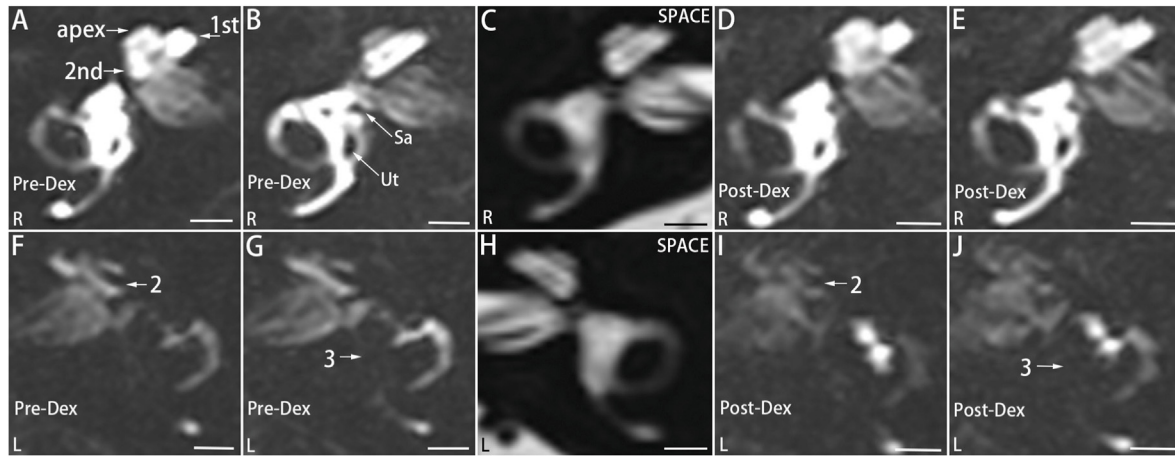


Fig. 2. Dynamics of endolymphatic hydrops of a patient with definite Meniere's disease on the left side after intratympanic administration of Gd-DTPA interfered with by intratympanic dexamethasone. The first MRI was performed 24 h postintra-tympanic injection of 20-fold diluted Gd-DTPA, followed by intratympanic administration of dexamethasone (10 mg/mL). The second MRI was performed 24 h after dexamethasone administration. The contrast effect of Gd-DTPA in the inner ear was imaged using the hT₂FLAIR-MZFI sequence (A, B, D, E-G, I, J). Before dexamethasone administration (Pre-Dex), grade 2 endolymphatic hydrops (2) was detected in the left cochlea (F), grade 3 endolymphatic hydrops (3) was demonstrated in the vestibule, and the right cochlea (A) and vestibule (B) were normal. Twenty-four hours post injection of dexamethasone (Post-Dex), EH was not modified in either the cochlea (I) or the vestibule (J) on the left side, and the cochlea and the vestibule remained normal on the right side (D, E). Signal intensity significantly decayed in the hydropic inner ear on the second MRI (I, J) compared to the first MRI (F, G). Fibrosis in the inner ear was ruled out by MRI with the SPACE sequence (C, H). 1st: the basal turn; 2nd: the second turn; Sa: the saccule; Ut: the utricle. Scale bars = 3.0 mm.

detected in 9/11 cochleae of patients with MD using a 3-stage method based on morphological changes (Bernaerts et al., 2019; Zou et al., 2021a). EH in the cochlear apex was detected in 7 of 11 ears with MD but not in the contralateral ears. In the vestibule, EH was detected in all 11 cases evaluated using a 4-stage scale method based on morphological changes (Bernaerts et al., 2019; Zou et al., 2021a). However, using the ratio of the area of endolymphatic space to the vestibular fluid space, vestibular EH was identified in only 9/11 ears evaluated (Nakashima et al., 2009). There was a tendency for the grade of vestibular EH using a 4-stage scale method to correlate with the ratio of the area of endolymphatic space to the vestibular fluid space ($p = 0.063$, Spearman's rho).

Twenty-four hours after the intratympanic injection of dexamethasone, a decrease in the signal intensity ratio of enhancement occurred in both the cochlear and vestibular perilymph. However, EH remained the same grade in the cochlea, including the apex, compared to that without dexamethasone intervention. Grades in the vestibular EH did not change in all ears evaluated using either a 4-stage scale method or the semiquantitative method by analyzing the ratio of the area of endolymphatic space to the vestibular fluid space (Fig. 2) (Table 4). Grading of EH in both the cochlea and vestibule was not modified even 60 h after intratympanic injection of dexamethasone (Fig. 3).

3.3. EH in MD observed by MRI 24 h postintra-tympanic administration of Gd-DTPA plus dexamethasone

Enhancement of the cochleae and vestibule was displayed in all 49 patients with MD after intratympanic administration of Gd-DTPA plus dexamethasone. Inner ear images were examined for all patients displaying normal perilymphatic compartments or EH with various grades. The enhancement of the vestibule negatively correlated with the grades of vestibular EH, which was not the case for the cochlea (Figs. 4 and 5). Injury of the endolymph-perilymph barrier was suspected when the endolymphatic compartments could not be distinguished from the perilymphatic compartments (Figs. 5–7). As a result, 46 ears with definite MD, 13 ears with probable MD, and 8 ears without symptoms were imaged 24 h after the intratympanic administration of Gd-DTPA mixed with

dexamethasone. EH was not detected in the non-symptomatic ear. *In the cochlea*, grade 2 EH was detected in 23 ears, grade 1 EH was detected in 11 ears, EH in the cochlear apex was detected in 38 ears, no EH was demonstrated in 18 ears, and injury of the endolymph-perilymph barrier was depicted in 1 of 59 ears with MD. *In the vestibule*, grade 3 EH was confirmed in 20, grade 2 EH was displayed in 12, grade 1 EH was found in 2, no EH was shown in 22, and injury of the endolymph-perilymph barrier was depicted in 3 of 59 ears with MD (Table 5). Significant correlations between probable and certain MDs and cochlear EH ($p < 0.01$, Spearman's rho), between probable and certain MDs and vestibular EH ($p < 0.01$, Spearman's rho), and between cochlear and vestibular EH ($p < 0.01$, Spearman's rho) were observed.

4. Discussion

The present study used HPLC to demonstrate that the retention time and peak area of dexamethasone were not modified by mixing with Gd-DTPA within the observation time of 72 h, indicating that no interaction occurred between the two compounds. The observation window of the *in vitro* study was defined according to a report in the literature that gadolinium had almost disappeared from the inner ear six days post-intra-tympanic injection (Nakashima et al., 2007). We observed that intratympanic injection of 0.1 ml of dexamethasone (10 mg/ml) did not interfere with the grade of EH in either the cochlea or the vestibule. Therefore, mixing dexamethasone with Gd-DTPA for intratympanic injection does not compromise either the efficacy of the compounds used or safety. Although Gd-DTPA may also be included in gentamicin, it is better to confirm the diagnosis of MD with MRI before destroying vestibular function. Intratympanic gentamicin therapy can only be offered to patients with active MD who are not responsive to nonablative therapy (Basura et al., 2020). Therefore, the present study did not include gentamicin. Glucocorticoid steroids have several different actions but are speculated to stabilize vascular endothelial cells, improve blood flow in the inner ear, and maintain ionic homeostasis in the inner ear (MacArthur et al., 2015; Otake et al., 2009; Pondugula et al., 2004; Shirwany et al., 1998). We could not rule out that the EH of the inner ear might be influenced

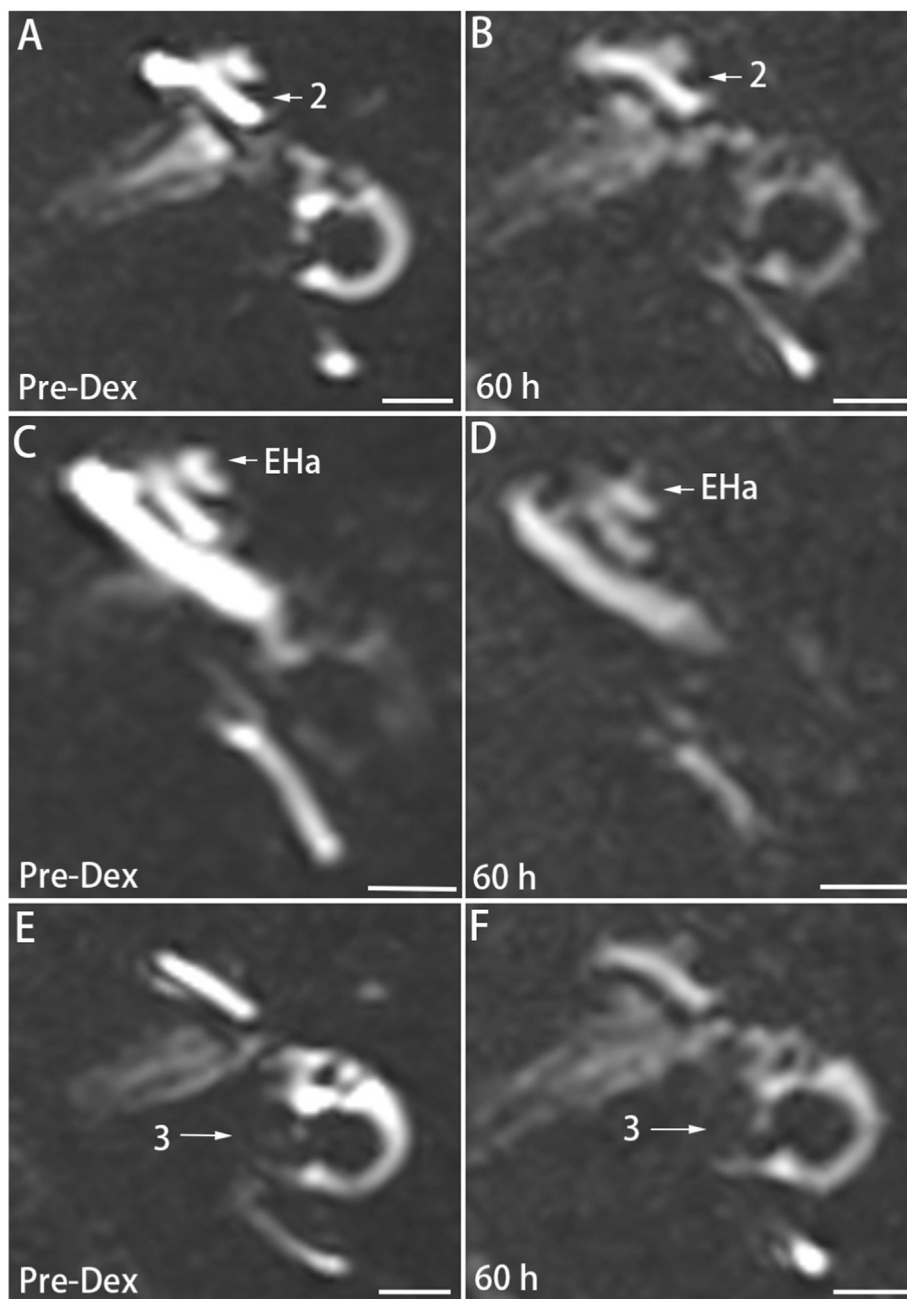


Fig. 3. Dynamics of endolymphatic hydrops in the left ear of a patient with definite Meniere's disease after intratympanic administration of Gd-DTPA interfered by intratympanic dexamethasone (60 h). The first MRI was performed 24 h postintra-tympanic injection of 20-fold diluted Gd-DTPA, followed by intratympanic administration of dexamethasone (10 mg/mL). The second MRI was performed 60 h after dexamethasone administration. The contrast effect of Gd-DTPA in the inner ear was imaged using the hT_2 FLAIR-MZFI sequence. EH grading in neither the cochlea (A, B) nor the apex (C, D) nor the vestibule (E, F) on the left side was modified 60 h after intratympanic injection of dexamethasone (60 h) compared to the predexamethasone injection (Pre-Dex). EHa: endolymphatic hydrops in the cochlear apex; 2: grade 2 endolymphatic hydrops in the cochlea; 3: grade 3 endolymphatic hydrops in the vestibule. Scale bars = 3.0 mm.

Table 4
Endolymphatic hydrops detected by MRI 24 h postinratympanic Gd-DTPA and after interference with intratympanic injection of dexamethasone.

Patient	EH-Coch		EHa		EH-Vest		VestRatio ⁵	
	Bef	Aft	Bef	Aft	Bef	Aft	Bef	Aft
1	2	2	1	1	3	3	0.518	0.570
2*	2	2	1	1	3	3	0.578	0.539
3	1	1	0	0	2	2	0.474	0.388
4	2	2	1	1	3	3	0.660	0.713
5	1	1	1	1	2	2	0.197	0.252
6	2	2	1	1	3	3	0.753	0.743
7L [#]	0	0	1	1	2	2	0.602	0.343
7R [#]	2	2	0	0	3	3	0.522	0.595
8	0	0	0	0	2	2	0.274	0.365
9	1	1	1	1	3	3	0.395	0.526
10	1	1	0	0	2	2	0.383	0.364

Aft: after intratympanic administration of dexamethasone; Bef: before intratympanic injection of dexamethasone; EHa: endolymphatic hydrops in the cochlear apex; EH-Coch: EH in the cochlea; EH-Vest: EH in the vestibule; VestRatio: ratio of the area of endolymphatic space to the vestibular fluid space. *The second MRI was performed 60 h after intratympanic injection of dexamethasone. #7L: left ear of patient no. 7, 7R: right ear of patient no. 7. †There was an insignificant difference between the VestRatio before and after dexamethasone administration ($p > 0.05$, paired sample *t*-test).

and modulated by dexamethasone in the long term; however, potential changes in EH in patients with MD were insignificant at 24 h and did not occur at 60 h in 1 patient.

As a comparison, grading vestibular EH using the criteria of the 4-stage scale method based on morphological changes is more accurate than using the ratio of the area of endolymphatic space to the vestibular fluid space (Bernaerts et al., 2019; Nakashima et al., 2009). Based on our experience applying the two criteria to evaluate EH, the morphological criteria consistently yielded the same results, which can be attributed to the stable presentation of characteristic structures used for identification. However, when

analyzing the ratio of the area of endolymphatic space to the vestibular fluid space, errors always occurred due to difficulty determining the boundary points of the fluids.

Intratympanic administration of dexamethasone mixed with Gd-DTPA in 49 MD patients yielded high-quality MRI images obtained 24 h post-intratympanic injection, suggesting that it is clinically feasible to deliver Gd-DTPA and dexamethasone intratympanically simultaneously for the evaluation of EH. The vestibular enhancement was compromised by vestibular EH. This interference could reflect a mechanism whereby Gd-DTPA plus dexamethasone enter the vestibule mainly through the oval window, and the hydropic saccule “squeezes” the perilymphatic space beneath the stapes, subsequently restricting the passage of agents from entering the vestibule. In contrast, the perilymph in the scala tympani was not influenced by cochlear EH, and the pathway for agent transportation into the cochlea mainly via the round window remained patent (Zou et al., 2011, 2012). There were significant correlations between probable and definite MD and cochlear and vestibular EH and between cochlear EH and vestibular EH, suggesting that it is clinically relevant to detect EH in MD using MRI. Postmortal histological evidence of EH has been previously used as the necessary criterion in the definition of certain MDs ((Committee on Hearing and, 1995)). The accuracy of detecting EH using MRI was verified by an identical histological study in an animal model (Zou et al., 2003). Previous studies have reported that grades of EH correlate with impairments in audio-vestibular function, albeit with controversial results regarding vestibular disorder (Gurkov et al., 2011; Jerin et al., 2018; Kahn et al., 2020; Yang et al., 2018). Variability with respect to the correlation between vestibular EH and vestibular function might be caused by the inaccuracy of defining EH grading and MRI protocols as well as vestibular functional evaluations in most previous studies.

In the present study, injury to the endolymph-perilymph barrier was also detected in one cochlea and three vestibules among 69

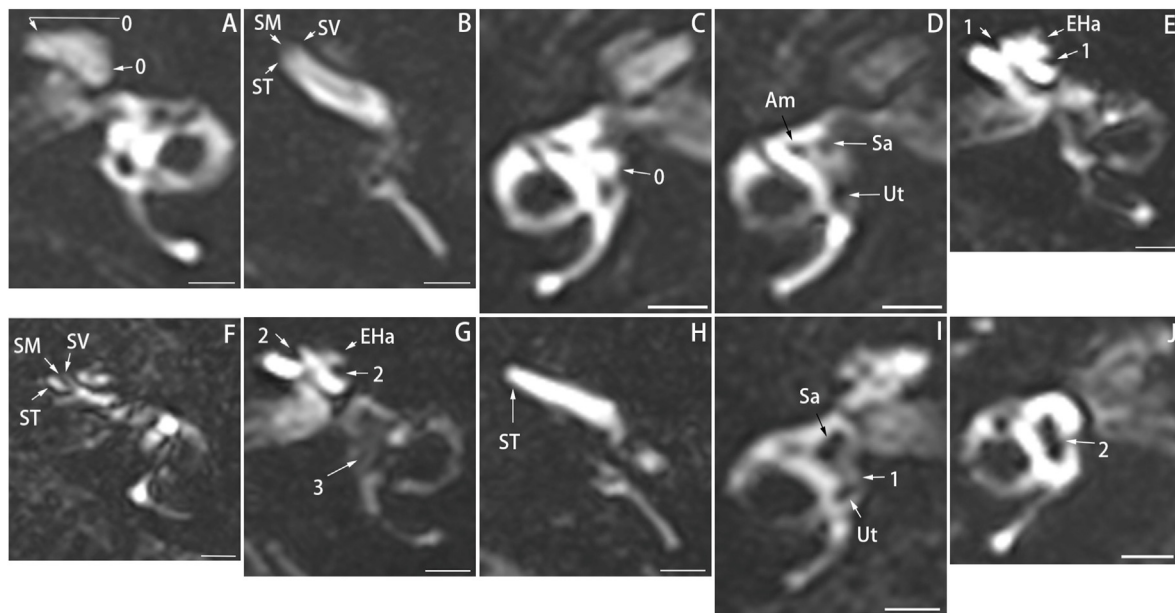


Fig. 4. Representative MRIs in patients with MD displaying various degrees of endolymphatic hydrops (EH) imaged 24 h postinratympanic administration of Gd-DTPA mixed with dexamethasone. In the normal cochlea (grade 0) (A, B), the scala media (SM) was almost visible. In the normal vestibule (grade 0) (C, D), the smaller saccule (Sa) and larger utricle (Ut) was visibly separated and occupied less than half of the surface of the vestibule. In mild cochlear EH (grade 1) (E, F), the SM became a nodular black area with narrow scala vestibuli (SV). In marked cochlear EH (grade 2) (G, H), the SV became completely invisible. In mild vestibular EH (grade 1) (I), the saccule became larger than the utricle but did not yet merge with the utricle. In marked vestibular EH (grade 2) (J), the Sa merged with the Ut, and the surrounding perilymphatic space appeared as a bright peripheral rim. In extreme vestibular EH (grade 3) (G), the perilymphatic enhancement of the vestibule was no longer visible. Vestibular distribution of dexamethasone plus Gd-DTPA (arrowhead) was negatively correlated with the grades of vestibular EH. Scale bars = 3.0 mm.

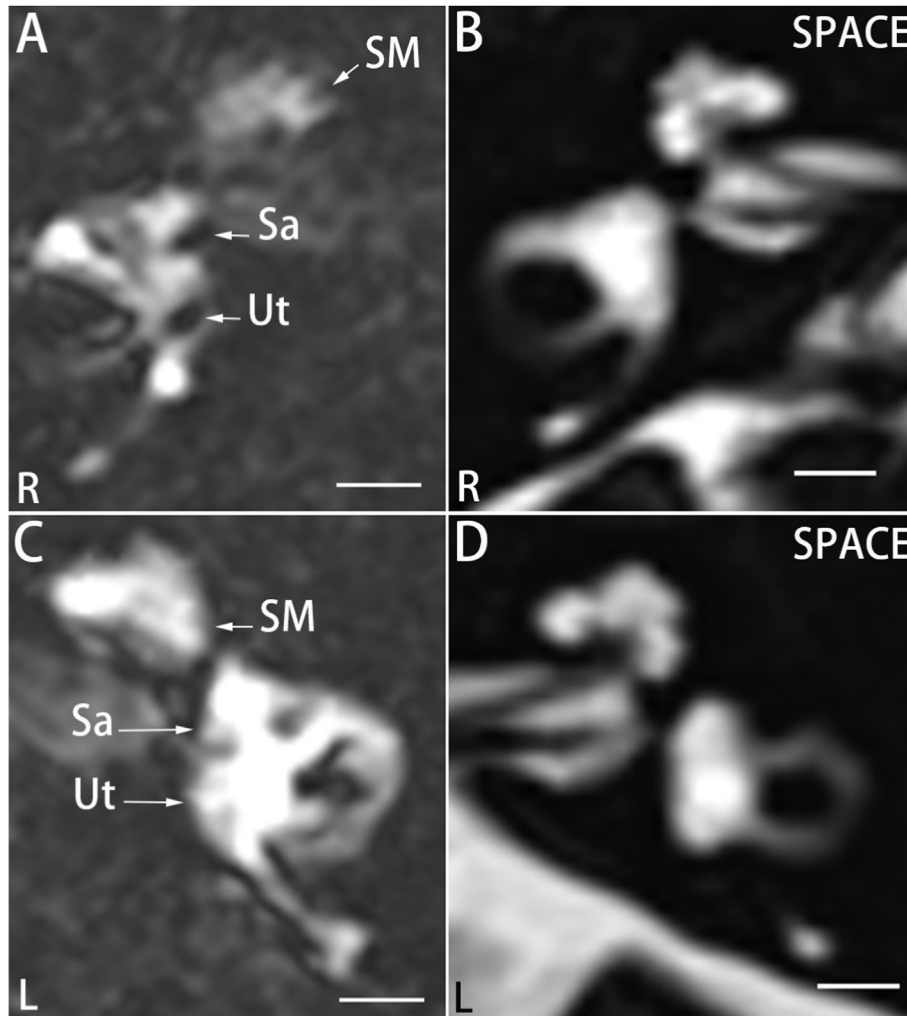


Fig. 5. Representative MRI in patients with MD displaying impairment in the endo-perilymphatic barrier in the vestibule. There was endolymphatic hydrops grade 1 in which the Sa became equal to the Ut but did not merge with the utricle on the right side (L) (A). The scala media (SM) appeared as a nodular black area, indicating mild EH (grade 1) in the cochlea of the right ear (R) (A). The endolymphatic compartments of the sacculus (Sa) and the utricle (Ut) on the left side were not distinguished from the surrounding perilymph, indicating impairment of endo-perilymphatic barriers (C). Potential inner ear fibrosis was ruled out by SPACE (B, D). Scale bars = 3.0 mm.

imaged inner ears. Impairment of the endolymph-perilymph barrier may occur at various locations of either the cochlea or the vestibule and by varying degrees. Schuknecht et al. detected ruptures of membranous labyrinths in ten of 24 temporal bones of MD patients (Schuknecht et al., 1991). The incidence of ruptures in the membranous labyrinths reported by Schuknecht et al. was significantly higher than in the current study, which might be caused by histological preparations as artifacts during specimen collection and processing of postmortal histological study. A previous *in vivo* MRI study on guinea pigs only demonstrated the rupture of Reissner's membrane in one of the 11 observed animals, which was associated with extreme EH (Zou et al., 2003). Kimura et al. reported wide gaps between mesothelial cells in the distended areas of Reissner's membrane in an electron microscopic study of MD (Kimura et al., 1976). Cureoglu et al. detected significantly higher cellular densities of epithelial cells in the basal and middle turns and a significantly decreased number of mesothelial cells in the basal turn of Reissner's membrane in MD patients compared with controls (Cureoglu et al., 2004). The mechanism of injury in the endolymph-perilymph barrier is unknown, but the above-mentioned mechanisms are feasible. Additionally, mitochondrial

dysfunction was reported to result in cellular impairment involving the barrier in an animal model study (Zou et al., 2013).

5. Conclusions

Gd-DTPA does not interfere with dexamethasone in the mixture during the 72-h observation period. Degrees of EH observed by MRI in patients with MD were not affected by dexamethasone after 24 h. Intratympanic administration of Gd-DTPA plus dexamethasone allowed for high-quality MRI images to detect EH in patients with MD, which combines therapeutic procedures with imaging techniques. Vestibular entry of dexamethasone was compromised by vestibular EH, which was not the case in the cochlea. Intratympanic administration of Gd-DTPA plus dexamethasone might be used to test its therapeutic effect in future work.

Declaration of conflicting interests

The authors declare no potential conflicts of interest with respect to the research, authorship, and/or publication of this article.

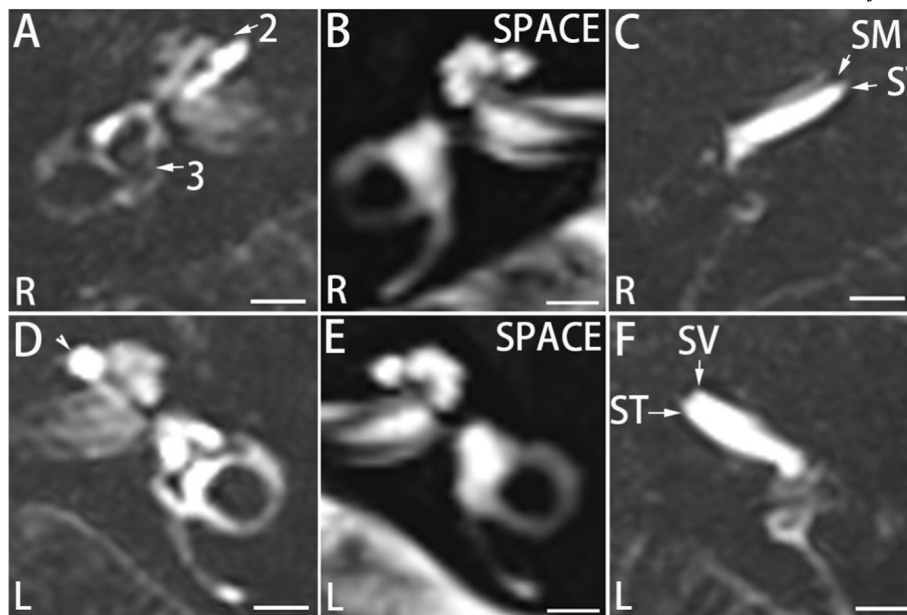


Fig. 6. Representative MRI in patients with MD displaying impairment of the endo-perilymphatic barrier in the cochlea. There was endolymphatic hydrops grade 2 (2) in the cochlea and grade 3 (3) in the vestibule of the right ear (A). The SV almost disappeared in the basal turn of the right ear (C) but was fully visible in that of the left ear (F). The scala media (SM) fully merged with the scala tympani (ST) and the scala vestibuli (SV) of the left basal turn, indicating impairment of the endo-perilymphatic barrier (arrowhead in D). Potential inner ear fibrosis was ruled out by SPACE (B, E). Scale bars = 3.0 mm.

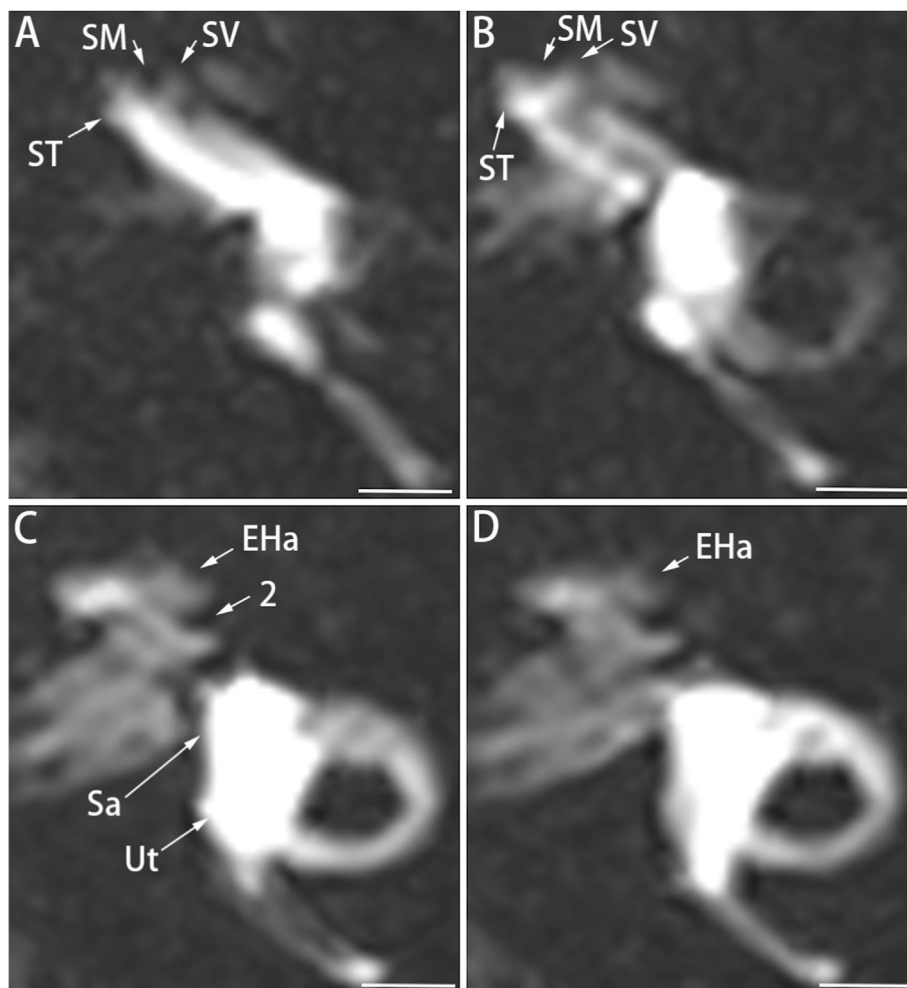


Fig. 7. Representative MRI in patients with MD displaying cochlear endolymphatic hydrops (EH) were diagnosed with modified criteria. The EH was mild in the basal turn (A, B) but was marked in the second turn (C) of the left cochlea, which was used as a reference to diagnose grade 2 EH in the cochlea. Notable EH in the cochlear apex (EHa) formed an invaginated arc (C, D). The endolymphatic compartments of the saccule (Sa) and the utricle (Ut) were not distinguished from the surrounding perilymph, indicating impairment of endo-perilymphatic barriers (C). SM: scala media; ST: scala tympani; SV: scala vestibuli. Scale bars = 3.0 mm.

Table 5
Endolymphatic hydrops demonstrated by MRI 24 h after intratympanic administration of Gd-DTPA plus dexamethasone.

Diag	Ear	EH stage-Coch				EH stage-Vest				BI-Coch	BI-Vest
		0	1	2	Ap	0	1	2	3		
dMD	46	9	15	21	35	12	3	10	19	1	2
pMD	13	9	3	1	3	9	0	2	1	0	1
Norm	8	8	0	0	0	8	0	0	0	0	0

BI-Coch: injury of the endolymph-perilymph barrier of cochlea; BI-Vest: injury of the endolymph-perilymph barrier of vestibule; Diag: diagnosis; dMD: definite MD; EH stage-Coch: cochlear endolymphatic hydrops graded using a 3-stage method; EH stage-Vest: vestibular endolymphatic hydrops graded using a 4-stage scale method; Norm: nonsymptomatic ear; pMD: probable MD.

Funding

This work was supported by the National Natural Science Foundation of China (81771006).

Appendix A. Supplementary data

Supplementary data to this article can be found online at <https://doi.org/10.1016/j.joto.2022.02.002>.

References

Basura, G.J., Adams, M.E., Monfared, A., Schwartz, S.R., Antonelli, P.J., Burkard, R., Bush, M.L., Bykowski, J., Colandrea, M., Derebery, J., Kelly, E.A., Kerber, K.A., Koopman, C.F., Kuch, A.A., Marcolini, E., McKinnon, B.J., Ruckenstein, M.J., Valenzuela, C.V., Vosooney, A., Walsh, S.A., Nnacheta, L.C., Dhepyasuwan, N., Buchanan, E.M., 2020. Clinical practice guideline: meniere's disease. *Otolaryngol. Head Neck Surg.* 162, S1–S55.

Bernaerts, A., Vanspauwen, R., Blaivie, C., van Dinther, J., Zarowski, A., Wuyts, F.L., Vanden Bossche, S., Offeciers, E., Casselman, J.W., De Foer, B., 2019. The value of four stage vestibular hydrops grading and asymmetric perilymphatic enhancement in the diagnosis of Meniere's disease on MRI. *Neuroradiology* 61, 421–429.

Boleas-Aguirre, M.S., Lin, F.R., Della Santina, C.C., Minor, L.B., Carey, J.P., 2008. Longitudinal results with intratympanic dexamethasone in the treatment of Meniere's disease. *Otol. Neurotol.* 29, 33–38.

Chandrasekhar, S.S., Rubinstein, R.Y., Kwartler, J.A., Gatz, M., Connelly, P.E., Huang, E., Baredes, S., 2000. Dexamethasone pharmacokinetics in the inner ear: comparison of route of administration and use of facilitating agents. *Otolaryngol. Head Neck Surg.* 122, 521–528.

Clyde, J.W., Oberman, B.S., Isildak, H., 2017. Current management practices in meniere's disease. *Otol. Neurotol.* 38, e159–e167.

Committee on Hearing and Equilibrium Guidelines for the Diagnosis and Evaluation of Therapy in Meniere's Disease. American Academy of Otolaryngology-Head and Neck Foundation, Inc. *Otolaryngol Head Neck Surg* vol. 113, 181–185.

Cureoglu, S., Schachern, P.A., Paul, S., Paparella, M.M., Singh, R.K., 2004. Cellular changes of Reissner's membrane in Meniere's disease: human temporal bone study. *Otolaryngol. Head Neck Surg.* 130, 113–119.

Gurkov, R., Flatz, W., Louza, J., Strupp, M., Krause, E., 2011. In vivo visualization of endolymphatic hydrops in patients with Meniere's disease: correlation with audiovestibular function. *Eur. Arch. Oto-Rhino-Laryngol.* 268, 1743–1748.

Jerin, C., Floerke, S., Maxwell, R., Gurkov, R., 2018. Relationship between the extent of endolymphatic hydrops and the severity and fluctuation of audiovestibular symptoms in patients with meniere's disease and MRI evidence of hydrops. *Otol. Neurotol.* 39, e123–e130.

Kahn, L., Hautefort, C., Guichard, J.P., Toupet, M., Jourdain, C., Vitaux, H., Herman, P., Kania, R., Houdart, E., Attye, A., Eliezer, M., 2020. Relationship between video head impulse test, ocular and cervical vestibular evoked myogenic potentials, and compartmental magnetic resonance imaging classification in meniere's disease. *Laryngoscope* 130, E444–E452.

Kimura, R.S., Ota, C.Y., Schuknecht, H.F., Takahashi, T., 1976. Electron microscopic cochlear observations in bilateral Meniere's disease. *Ann. Otol. Rhinol. Laryngol.* 85, 791–801.

Lopez-Escamez, J.A., Carey, J., Chung, W.H., Goebel, J.A., Magnusson, M., Mandala, M., Newman-Toker, D.E., Strupp, M., Suzuki, M., Trabalzini, F., Bisdorff, A., Classification Committee of the Barany, S., Japan Society for Equilibrium, R., European Academy of, O., Neurology, Equilibrium Committee of the American Academy of, O.-H., Neck, S., Korean Balance, S., 2015. Diagnostic criteria for Meniere's disease. *J. Vestib. Res.* 25, 1–7.

MacArthur, C., Hausman, F., Kempton, B., Trune, D.R., 2015. Intratympanic steroid

treatments may improve hearing via ion homeostasis alterations and not immune suppression. *Otol. Neurotol.* 36, 1089–1095.

Martin-Sanz, E., Esteban-Sanchez, J., Rodriganez-Riesco, L., Sanz-Fernandez, R., 2015. Transitory effect on endolymphatic hydrops of the intratympanic steroids for Meniere's disease. *Laryngoscope* 125, 1183–1188.

Naganawa, S., Yamazaki, M., Kawai, H., Bokura, K., Sone, M., Nakashima, T., 2010. Visualization of endolymphatic hydrops in Meniere's disease with single-dose intravenous gadolinium-based contrast media using heavily T(2)-weighted 3D-FLAIR. *Magn. Reson. Med. Sci.* 9, 237–242.

Naganawa, S., Suzuki, K., Nakamichi, R., Bokura, K., Yoshida, T., Sone, M., Homann, G., Nakashima, T., Ikeda, M., 2013. Semi-quantification of endolymphatic size on MR imaging after intravenous injection of single-dose gadodiamide: comparison between two types of processing strategies. *Magn. Reson. Med. Sci.* 12, 261–269.

Naganawa, S., Kawai, H., Taoka, T., Sone, M., 2019. Improved 3D-real inversion recovery: a robust imaging technique for endolymphatic hydrops after intravenous administration of gadolinium. *Magn. Reson. Med. Sci.* 18, 105–108.

Nakashima, T., Naganawa, S., Sugiura, M., Teranishi, M., Sone, M., Hayashi, H., Nakata, S., Katayama, N., Ishida, I.M., 2007. Visualization of endolymphatic hydrops in patients with Meniere's disease. *Laryngoscope* 117, 415–420.

Nakashima, T., Naganawa, S., Pyykko, I., Gibson, W.P., Sone, M., Nakata, S., Teranishi, M., 2009. Grading of endolymphatic hydrops using magnetic resonance imaging. *Acta Otolaryngol. Suppl.* 5–8.

Ohashi, T., Naganawa, S., Takeuchi, A., Katagiri, T., Kuno, K., 2020. Quantification of endolymphatic space volume after intravenous administration of a single dose of gadolinium-based contrast agent: 3D-real inversion recovery versus HYDROPS-mi2. *Magn. Reson. Med. Sci.* 19, 119–124.

Otake, H., Yamamoto, H., Teranishi, M., Sone, M., Nakashima, T., 2009. Cochlear blood flow during occlusion and reperfusion of the anterior inferior cerebellar artery—effect of topical application of dexamethasone to the round window. *Acta Otolaryngol.* 129, 127–131.

Patel, M., Agarwal, K., Arshad, Q., Hariri, M., Rea, P., Seemungal, B.M., Golding, J.F., Harcourt, J.P., Bronstein, A.M., 2016. Intratympanic methylprednisolone versus gentamicin in patients with unilateral Meniere's disease: a randomised, double-blind, comparative effectiveness trial. *Lancet* 388, 2753–2762.

Pondugula, S.R., Sanneman, J.D., Wangemann, P., Milhaud, P.G., Marcus, D.C., 2004. Glucocorticoids stimulate cation absorption by semicircular canal duct epithelium via epithelial sodium channel. *Am. J. Physiol. Ren. Physiol.* 286, F1127–F1135.

Pyykko, I., Zou, J., Poe, D., Nakashima, T., Naganawa, S., 2010. Magnetic resonance imaging of the inner ear in Meniere's disease. *Otolaryngol. Clin.* 43, 1059–1080.

Schuknecht, H.F., Rutherford, A., 1991. Blockage of longitudinal flow in endolymphatic hydrops. *Eur. Arch. Oto-Rhino-Laryngol.* 248, 209–217.

Shirwany, N.A., Seidman, M.D., Tang, W., 1998. Effect of transtympanic injection of steroids on cochlear blood flow, auditory sensitivity, and histology in the Guinea pig. *Am. J. Otol.* 19, 230–235.

Wang, X., Fernandez, R., Dellamary, L., Harrop, A., Ye, Q., Lichter, J., Lau, D., Lebel, C., Piu, F., 2011. Pharmacokinetics of dexamethasone solution following intratympanic injection in Guinea pig and sheep. *Audiol. Neuro. Otol.* 16, 233–241.

Yang, S., Zhu, H., Zhu, B., Wang, H., Chen, Z., Wu, Y., Chen, B., Shi, H., Li, Y., Zou, J., Yin, S., 2018. Correlations between the degree of endolymphatic hydrops and symptoms and audiological test results in patients with meniere's disease: a reevaluation. *Otol. Neurotol.* 39, 351–356.

Zou, J., Pyykko, I., Bjelke, B., Bretlau, P., Tayamaga, T., 2000. Endolymphatic Hydrops Is Caused by Increased Porosity of Stria Vascularis? Barany Society Meeting, Uppsala, Sweden.

Zou, J., Pyykko, I., Bretlau, P., Klason, T., Bjelke, B., 2003. In vivo visualization of endolymphatic hydrops in Guinea pigs: magnetic resonance imaging evaluation at 4.7 tesla. *Ann. Otol. Rhinol. Laryngol.* 112, 1059–1065.

Zou, J., Pyykko, I., Bjelke, B., Dastidar, P., Toppila, E., 2005. Communication between the perilymphatic scalae and spiral ligament visualized by in vivo MRI. *Audiol. Neuro. Otol.* 10, 145–152.

Zou, J., Pyykko, I., Bjelke, B., Toppila, E., 2007. In vivo MRI visualization of endolymphatic hydrops induced by keyhole limpet hemocyanin round window immunization. *Audiol. Med.* 182–187, 2007.

Zou, J., Yoshida, T., Ramadan, U.A., Pyykko, I., 2011. Dynamic enhancement of the rat inner ear after ultra-small-volume administration of Gd-DOTA to the medial wall of the middle ear cavity. *ORL J. Otorhinolaryngol. Relat. Spec.* 73, 275–281.

Zou, J., Poe, D., Ramadan, U.A., Pyykko, I., 2012. Oval window transport of Gd-DOTA from rat middle ear to vestibulum and scala vestibuli visualized by in vivo magnetic resonance imaging. *Ann. Otol. Rhinol. Laryngol.* 121, 119–128.

Zou, J., Zhang, Y., Zhang, W., Poe, D., Zhai, S., Yang, S., Pyykko, I., 2013. Mitochondria toxin-induced acute cochlear cell death indicates cellular activity-correlated energy consumption. *Eur. Arch. Oto-Rhino-Laryngol.* 270, 2403–2415.

Zou, J., Wang, Z., Chen, Y.K., Zhang, G.P., Lu, J.P., Zheng, H.L., 2018a. [Optimization of delivering minimum Gd-DTPA at the posterior upper point on tympanic medial wall and hT2W-3D-FLAIR sequence for detecting endolymphatic hydrops]. *Zhonghua er bi yan hou tou jing wai ke za zhi* 53, 931–938.

Zou, J., Wang, Z., Chen, Y., Zhang, G., Lu, J., Zheng, H., 2018b. Detecting endolymphatic hydrops with posterior tympanic medial wall Gd-DTPA delivery and 8 min-MRI. In: The XXX Barány Society Meeting. *J Vestib Res, Uppsala, Sweden, p.* 204.

Zou, J., Wang, Z., Chen, Y., Zhang, G., Chen, L., Lu, J., 2019. MRI detection of endolymphatic hydrops in Meniere's disease in 8 minutes using MIIRMR and a 20-channel coil after targeted gadolinium delivery. *World J Otorhinolaryngol Head Neck Surg* 5, 180–187.

Zou, J., Chen, L., Li, H., Zhang, G., Pyykko, I., JWorld J. Otorhinolaryngol. Head Neck Surg. Lu, 2021a. High-quality imaging of endolymphatic hydrops acquired in 7 minutes using sensitive hT2W-3D-FLAIR reconstructed with magnitude and

zero-filled interpolation. *Eur. Arch. Oto-Rhino-Laryngol.* <https://doi.org/10.1007/s00405-021-06912-4>.

Zou, J., Chen, L., Li, H., Zhang, G., Pyykko, I., Lu, J., 2021b. High-quality Imaging of Endolymphatic Hydrops Acquired in 7 Minutes Using Sensitive hT2W-3d-FLAIR Reconstructed with Magnitude and Zero-Filled Interpolation. *European Archives of Oto-Rhino-Laryngology*.