



Contents lists available at ScienceDirect

## International Journal of Surgery Case Reports

journal homepage: [www.casereports.com](http://www.casereports.com)

# Minimally invasive management for a giant lumbar intervertebral disc herniation: A case report, and literature review

Rodolfo Pedro Molina-Martínez\*, Carlos Betancourt-Quiroz,  
Mario Alberto Dueñas-Espinoza, Daniel Alejandro Vega-Moreno,  
Julio César López-Valdés, Ulises García-González

Department of Neurosurgery, Hospital Central Sur de Alta Especialidad, Mexican Oil Company (PEMEX), Anillo Periferico. 4091, Fuentes del Pedregal, Tlalpan, 14140, Ciudad de México, Mexico

## ARTICLE INFO

## Article history:

Received 23 February 2021

Received in revised form 23 March 2021

Accepted 23 March 2021

Available online 26 March 2021

## Keywords:

Lumbar

Giant

Herniated disc

Minimally invasive

Tubular retractor

Case report

## ABSTRACT

**INTRODUCTION AND IMPORTANCE:** Low back pain and lower limb radiculopathy are some of the most common diagnoses in our neurosurgery department. Giant lumbar intervertebral disc herniation, are not a common find in our daily practice. Management for this kind of pathology is controversial. The quest for the best surgical approach is still a matter of debate. This case report intends to demonstrate the advantages of minimally invasive procedures.

**CASE PRESENTATION:** 40-year-old female, diagnosed with giant lumbar L5-S1 disc herniation with localized lower back electric-type pain, 5/10 intensity in the visual analog scale (VAS) and an Oswestry Disability Index (ODI) score of 76 points, underwent minimally invasive surgery (MIS) with tubular retractor system. 6-month post-op, the patient referred no pain, and an ODI score of 4 points was obtained.

**CLINICAL DISCUSSION:** There is no clear classification, regarding the lumbar intervertebral disc herniated content. We didn't find any clear indications or contraindications regarding the relationship of the size of herniated disc content and surgical approach (MIS vs Open). We perform on average 175 spine cases per year and educational commitment with spine pathology is demonstrated with our spine fellowship since 3 years ago.

**CONCLUSION:** We believe giant extruded regardless of migration, single-level intervertebral disc herniation, could be effectively and safely treated by MIS.

© 2021 The Authors. Published by Elsevier Ltd on behalf of IJS Publishing Group Ltd. This is an open access article under the CC BY-NC-ND license (<http://creativecommons.org/licenses/by-nc-nd/4.0/>).

## 1. Introduction

Low back pain and lower limb radiculopathy due to lumbar disc herniation is one of the most prevalent causes of neurosurgical consultation in the out-patient clinic [1]. Prevalence of this type of pain in any individual life may reach up to 77.9% [2].

Giant lumbar intervertebral disc herniation, are not a common find in our daily practice. Management for this kind of pathology is controversial.

Microsurgical techniques for lumbar disc surgery were first introduced in 1977 by Caspar and Yasargil [3]. 43 years later the quest for the best surgical approach is still a matter of debate.

*Abbreviations:* MIS, minimally invasive surgery; MRI, magnetic resonance imaging; ODI, Oswestry Disability Index; VAS, visual analogue scale.

\* Corresponding author.

*E-mail addresses:* [rpmolinam@gmail.com](mailto:rpmolinam@gmail.com) (R.P. Molina-Martínez), [cbetancourtquiroz@gmail.com](mailto:cbetancourtquiroz@gmail.com) (C. Betancourt-Quiroz), [malbert.dues@hotmail.com](mailto:malbert.dues@hotmail.com) (M.A. Dueñas-Espinoza), [d2206@hotmail.com](mailto:d2206@hotmail.com) (D.A. Vega-Moreno), [jc.lopez@live.com](mailto:jc.lopez@live.com) (J.C. López-Valdés), [ulises.med@gmail.com](mailto:ulises.med@gmail.com) (U. García-González).

<https://doi.org/10.1016/j.ijscr.2021.105843>

2210-2612/© 2021 The Authors. Published by Elsevier Ltd on behalf of IJS Publishing Group Ltd. This is an open access article under the CC BY-NC-ND license (<http://creativecommons.org/licenses/by-nc-nd/4.0/>).

This case report is compliant with the Updating Consensus Surgical Case Report (SCARE) guidelines. A complete SCARE checklist was submitted along with the original manuscript [4].

## 2. Presentation of case

We present a 40-year-old female, with no relevant past medical history. In December 2019 debuted with localized lower back electric-type pain, 5/10 intensity “visual analog scale” (VAS), worsened with exercise, this pain was controlled with over-the-counter pain medication. In May 2020, the pain exacerbated, reaching 10/10 VAS with irradiation to the tip of the toes in the right leg. Conservative treatments including acupuncture, chiropractic therapy, and ozone injection was tried with little to no benefit.

The patient was referred to the neurosurgery service of our institute in August 2020, a lumbar magnetic resonance imaging (MRI) (Fig. 1) was performed. On patient's examination antalgic gait was noted at first. Higher cortical functions, cranial nerves, and cerebellum examination were all normal. Strength; right planar flexion and extension diminished 4-/5 “Medical research council strength scale”. Reflexes; the right patellar reflex diminished and

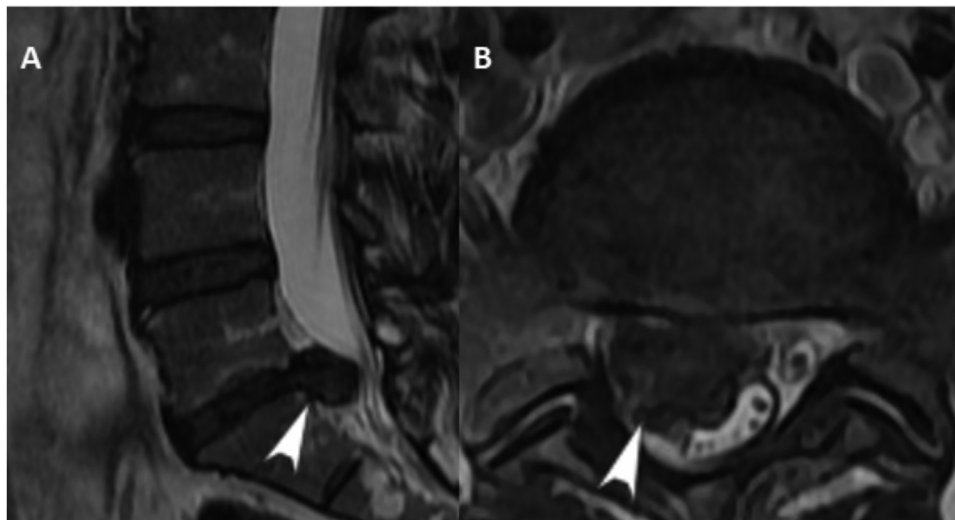


Fig. 1. Pre-operative MRI T2 sequence, sagittal view (A), axial view (B). An L5-S1 disc extrusion is observed (white arrowhead).

Table 1

Collection of the most common described Neurotension maneuvers on physical examination.

Maneuver	Exploration
Neri 1	Painful stimuli produced during the elevation and extension of the symptomatic leg in sitting position.
Neri 2	Painful stimuli produced by flexing the neck during the Neri 1 maneuver
Lasègue	Acute intensive pain produced during the elevation of the symptomatic leg in supine position. Positive Lasègue sign is detonate between 20°–60° degrees of elevation
Lasègue-Mountaud-Martin (cross Lasègue)	Painful stimuli produced in the symptomatic leg during the elevation of the asymptomatic leg in supine position.
Indirect Lasègue	Painful stimuli produced in the symptomatic leg during the change of position from supine to sit.
Bragard	After a positive Lasègue maneuver. Painful stimuli produced by the dorsiflexion of the affected leg after lowering to the point where no pain is referred.
Barraquer Ferré	Painful stimuli produced during the extension of the leg outside the bed in prone position. Positive Barraquer Ferré sign is detonate between 20°–60° degrees
Milgram	Inability to raise the legs 3 in. above the bed for 30 s or more
Naffzinger	Painful stimuli produced by the compression of both internal jugular veins for 10 s or less

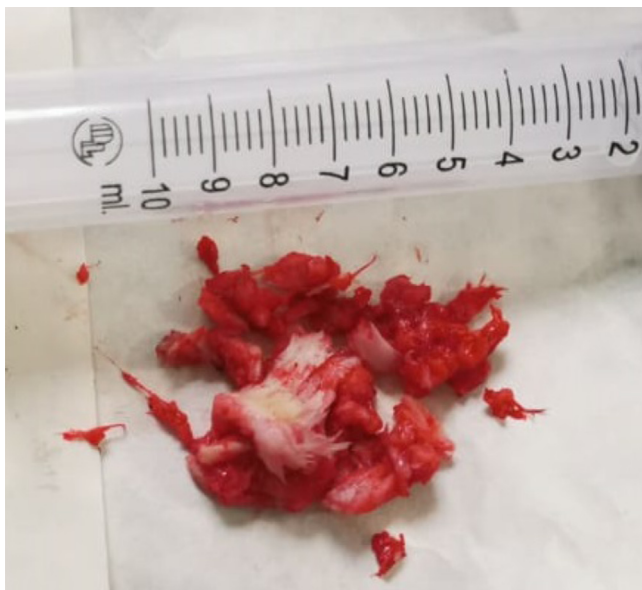


Fig. 2. Discectomy of L5-S1 extruded disc.

the right Achilles absent. Sensitive; dysesthesia in right S1 and S2 dermatome was noted. Neurotension maneuvers represented in Table 1 [5–7] were all positive. Score of 76 points Oswestry Disability Index (ODI) was obtained. Electromyography was concordant with right L5-S1 radiculopathy.

MIS approach was proposed and was performed by senior author García-González on August 31, 2020. The patient was set in the prone position, reference level guided with fluoroscopy and a 1.5 cm midline incision was made and MIS tube probes were inserted according to the MIS standard technique. Final probe 18 mm diameter and 40 mm deep tubular probe was used. With microscopic visualization and high speed drill assistance a right L5 partial laminectomy was performed until Flavum ligament was observed, once dissected, a swollen upward displaced L5-S1 posterior nerve root was mobilized medially, exposing L5-S1 Giant extruded intervertebral disc. Extruded disc resection and regular MIS microdiscectomy was achieved (Fig. 2). Surgical field irrigation with saline solution and hemostasis were conventionally performed before closure.

A Post-operative MRI (Fig. 3) was indicated before patient's discharge on 3rd postop day with significant clinical improvement (ODI 56 points), pain 2/10 pts VAS, Routine physical therapy was recommended. The patient was seen 6 months after surgery with no pain and recovery of all neurologic abnormalities on the right leg, full strength and the patellar and Achilles reflex back to normal ODI is now of 4 points, the patient has made an almost full recovery and is pleased with the results.

### 3. Discussion

Lower back pain and radiculopathy are demonstrated in up to 85% of patients by a lumbar disc herniation. Electric-type pain and irradiation throughout the leg, with localized affected dermatome, is mostly explained due to posterior root compression [8]. Mag-

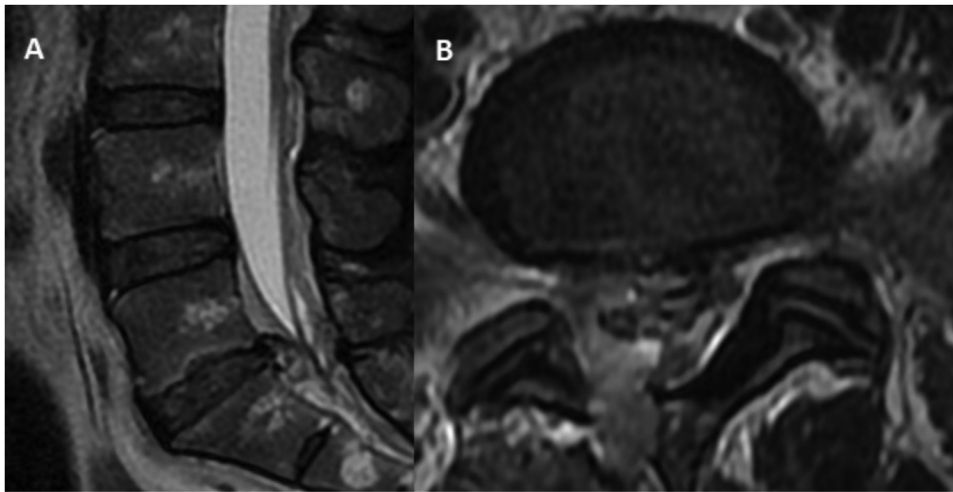


Fig. 3. Post-operative MRI T2 sequence, sagittal view (A), axial view (B).

netic resonance imaging is the gold standard for the diagnostic of intervertebral disc herniation due to its superior visualization of root nerves and surrounding soft tissue [9].

In 2014 multiple North American medical societies, formed a task forced to established the nomenclature and classification of lumbar disc pathology. The patient's lumbar disc herniation classifies as an extruded disc, as the distance between the edges of the herniated content is greater than those of the intervertebral space [10].

No clear consensus has been made regarding classification by measurement of the actual herniated content. In a series of 1334 patients who underwent surgery for lumbar disc herniation, Akhaddar et al. classified as giant (154 patients) those in which more than half of the sagittal diameter of the lumbar spinal canal was occupied [11].

Different approaches have been described in the management of lumbar disc herniation. MIS tube system was first introduced in 1997 by Foley and Smith [12]. Since then numerous operations using this technique are performed worldwide. The use of different techniques varies depending on different factors such as surgeon's preferences and abilities and none the less, hospital capabilities regarding medical equipment. In Mexico, not all neurosurgery departments in public hospitals own MIS devices. At our neurosurgery department, 50% of our neurosurgery practice is on spine pathology, including degenerative, trauma, and tumor. From this 90% are performed with a Minimally Invasive Philosophy.

A systematic review by Alvi et al. on approaches for lumbar disc herniation comparing minimally invasive approaches (MIS) V.S. open approaches reported no significant difference for VAS and ODI at 1 year, however, MIS was associated with fewer length of stay and blood loss but a higher recurrent herniation [13].

Using the keyword; Giant Herniated Disc, Giant Extruded Disc, Giant Lumbar Herniation, we didn't find any clear indications or contraindications regarding the relationship of the size of herniated disc content and surgical approach (MIS vs Open).

At our hospital, MIS management was initiated in 2012, since now the number of MIS procedures increased from 30% up to 90% on the current days with a significant improvement of postoperative results on diminishing in-patient days of hospitalization and laboral inability index. MIS is the preferred approach for the treatment of lumbar disc herniation regarding the size. We perform on average 175 spine cases per year and educational commitment with spine pathology is demonstrated with our spine fellowship since 3 years ago. We strongly believe that specialized training courses like

this are relevant for attendee's residents and fellows in the process of mastering this technique.

#### 4. Conclusion

Lumbar disc herniation is one of the most common procedures performed worldwide by spine surgeons. MIS management of single-level lumbar disc herniation should be part of every spine surgeon's reservoir. We believe giant extruded regardless of migration, single-level intervertebral disc herniation, could be effectively and safely treated by MIS with a better outcome on fewer hospitalization days and blood loss with no significantly higher complications.

#### Declaration of Competing Interest

None of the authors have anything to disclose that inappropriately influence this work.

#### Sources of funding

No source of funding was received for this work.

#### Ethical approval

Ethical approval was granted by our institution, as it does not include any personal information that compromises patient identity. Patient was not a subject of a clinical trial.

#### Consent

Written informed consent was obtained from the patient for publication of this case report and accompanying images. A copy of the written consent is available for review by the Editor-in-Chief of this journal on request.

#### Author contribution

Molina-Martínez: conceptualization, investigation, writing – original draft. Betancourt-Quiroz: investigation, visualization. Dueñas-Espinoza: writing – original draft. Vega-Moreno: investigation. López-Valdés: investigation. García-González: writing – review & editing, supervision.

**Registration of research studies**

Not applicable.

**Guarantor**

Rodolfo Pedro Molina-Martinez.

**Provenance and peer review**

Not commissioned, externally peer-reviewed.

**Disclosure**

Patient consent was obtained during hospitalization. Prior to the submission, our local ethics board reviewed and approved for publication.

**Acknowledgments**

We would like to thank Nadia Ruth Cruz Cruz, M.D. and attending physician of the radiology department of our hospital.

**References**

- [1] H. Kanno, T. Aizawa, K. Hahimoto, E. Itoi, Minimally invasive discectomy for lumbar disc herniation: current concepts, surgical techniques, and outcomes, *Int. Orthop.* 43 (2019) 917–922, <http://dx.doi.org/10.1007/s00264-018-4256-5>.
- [2] S. Osorio Peralta, Características Epidemiológicas de la Hernia Discal por RM. Experiencia Inicial en el Hospital Juárez de México, *An. Radiol. México* 2 (2003) 17–22.
- [3] A.J. Clark, M.M. Safaee, N.R. Khan, M.T. Brown, K.T. Foley, Tubular microdiscectomy: techniques, complication avoidance, and review of the literature, *Neurosurg. Focus* 43 (2017) 1–9, <http://dx.doi.org/10.3171/2017.5.FOCUS17202>.
- [4] R.A. Agha, T. Franchi, C. Sohrabi, G. Mathew, for the SCARE Group, The SCARE 2020 guideline: updating consensus Surgical CAse REport (SCARE) guidelines, *Int. J. Surg.* 84 (2020) 226–230.
- [5] J. Aso Escario, J.V. Martínez Quiñones, A. Aso Vizán, R. Arregui Calvo, M. Bernal Lafuente, A. Alcázar Crevillén, Simulación en patología espinal, *Reumatol. Clin.* 10 (2014) 396–405, <http://dx.doi.org/10.1016/j.reuma.2014.03.003>.
- [6] K. Buckup, J. Buckup, *Clinical Test for the Musculoskeletal System*, 3rd ed., Thieme, Stuttgart, 2005, Chapter 1.
- [7] S. Hoppenfeld, *Exploración física de la columna vertebral y las extremidades*, 1st ed., Manual Moderno, Mexico D.F, 1999, Chapter 6.
- [8] P.D. Delgado-López, A. Rodríguez-Salazar, J. Martín-Alonso, V. Martín-Velasco, Lumbar disc herniation: natural history, role of physical examination, timing of surgery, treatment options and conflicts of interests, *Neurocirugía* 28 (2017) 124–134, <http://dx.doi.org/10.1016/j.neucir.2016.11.004>.
- [9] R.M. Amin, N.S. Andrade, B.J. Neuman, Lumbar disc herniation, *Curr. Rev. Musculoskelet. Med.* 10 (2017) 507–516, <http://dx.doi.org/10.1007/s12178-017-9441-4>.
- [10] D.F. Fardon, A.L. Williams, E.J. Dohring, F.R. Murtagh, S.L. Gabriel Rothman, G.K. Sze, Lumbar disc nomenclature: version 2.0 recommendations of the combined task forces of the north american spine society, the american society of spine radiology and the american society of neuroradiology, *Spine J.* 14 (2014) 2525–2545, <http://dx.doi.org/10.1016/j.spinee.2014.04.022>.
- [11] A. Akhaddar, H. Belfquih, M. Salami, M. Boucetta, Surgical management of giant lumbar disc herniation: analysis of 154patients over a decade, *Neurochirurgie* 60 (2014) 244–248, <http://dx.doi.org/10.1016/j.neuchi.2014.02.012>.
- [12] K.T. Foley, M.M. Smith, Microendoscopic discectomy, *Tech Neurosurg.* 3 (1997) 301–307.
- [13] M.A. Alvi, P. Kerezoudis, W. Wahood, A. Goyal, M. Bydon, Operative approaches for lumbar disc herniation: a systematic review and multiple treatment meta-analysis of conventional and minimally invasive surgeries, *World Neurosurg.* 114 (2018) 391–407.e2, <http://dx.doi.org/10.1016/j.wneu.2018.02.156>.

**Open Access**

This article is published Open Access at [sciencedirect.com](https://www.sciencedirect.com). It is distributed under the [IJSCR Supplemental terms and conditions](#), which permits unrestricted non commercial use, distribution, and reproduction in any medium, provided the original authors and source are credited.