



# Can Right-Handed Surgeons Insert Upper Thoracic Pedicle Screws in much Comfortable Position? Right-Handedness Problem on the Left Side

Göktuğ Akyoldaş, M.D.,<sup>1</sup> Salim Şentürk, M.D.,<sup>1</sup> Onur Yaman, M.D.,<sup>1</sup> Nail Özdemir, M.D.,<sup>2</sup> Emre Acaroğlu, M.D.<sup>3</sup>

Department of Neurosurgery,<sup>1</sup> Koç University, Istanbul, Turkey

Department of Neurosurgery,<sup>2</sup> Tepecik Education and Training Hospital, Izmir, Turkey

Department of Orthopedics,<sup>3</sup> Memorial Hospital, Ankara, Turkey

**Objective :** Thoracic pedicles have special and specific properties. In particular, upper thoracic pedicles are positioned in cranio-caudal plane. Therefore, manipulation of thoracic pedicle screws on the left side is difficult for right-handed surgeons. We recommend a new position to insert thoracic pedicle screw that will be much comfortable for spine surgeons.

**Methods :** We retrospectively reviewed 33 patients who underwent upper thoracic pedicle screw instrumentation. In 15 patients, a total of 110 thoracic pedicle screws were inserted to the upper thoracic spine (T1–6) with classical position (anesthesiologist and monitor were placed near to patient's head. Surgeons were standing classically near to patient's body while patients were lying in prone position). In 18 patients, a total of 88 thoracic pedicle screws were inserted to the upper thoracic spine with the new standing position—surgeons stand by the head of the patient and the anesthesia monitor laterally and under patient's belt level. All the operations performed by the same senior spine surgeons with the help of C-arm. Postoperative computed tomography scans were obtained to assess the screw placement. The screw malposition and pedicle wall violations were divided and evaluated separately. Cortical penetration were measured and graded at either : 1–2 mm penetration, 2–4 mm penetration and >4 mm penetration.

**Results :** Total 198 screws were inserted with two different standing positions. Of 198 screws 110 were in the classical positioning group and 88 were in the new positioning group. Incorrect screw placement was found in 33 screws (16.6%). The difference between total screw malposition by both standing positions were found to be statistically significant ( $p=0.011$ ). The difference between total pedicle wall violations by both standing positions were found to be statistically significant ( $p=0.003$ ).

**Conclusion :** Right-handedness is a problem during the upper thoracic pedicle screw placement on the left side. Changing the surgeon's position standing near to patient's head could provide a much comfortable position to orient the cranio-caudal plane of the thoracic pedicles.

**Key Words :** Thoracic vertebrae · Pedicle screws · Right handed · Positioning.

• Received : March 13, 2018 • Revised : April 12, 2018 • Accepted : May 15, 2018

• Address for reprints : Göktuğ Akyoldaş, M.D.

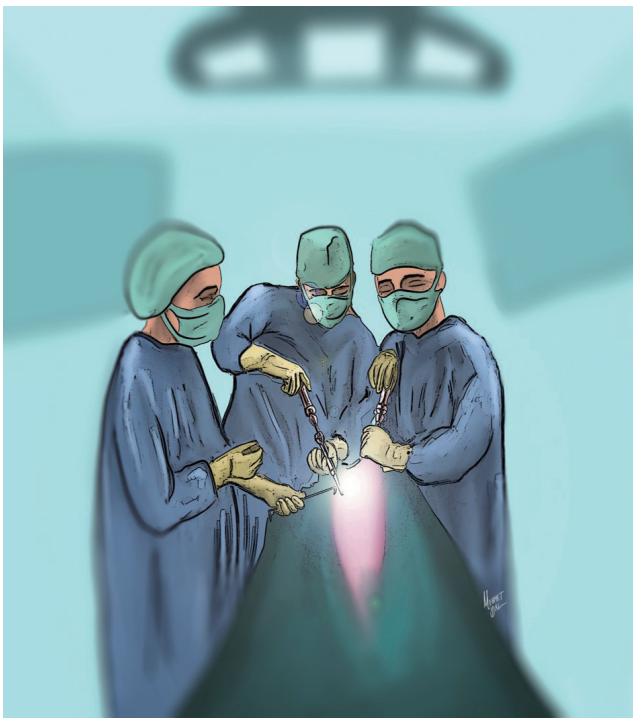
Department of Neurosurgery, Koç University Hospital, Davutpaşa Caddesi No:4 Topkapı, Istanbul 34010, Turkey  
Tel : +90-850250825, Fax : +90-2324867070, E-mail : goktug\_akyoldas@hotmail.com

This is an Open Access article distributed under the terms of the Creative Commons Attribution Non-Commercial License (<http://creativecommons.org/licenses/by-nc/4.0>) which permits unrestricted non-commercial use, distribution, and reproduction in any medium, provided the original work is properly cited.

## INTRODUCTION

Pedicle screws are widely used for treatment of trauma, spinal tumors, deformity, spinal instability and infections. Insertion of pedicle screws in thoracic spine, even in the experienced hands, was noted to have high incidences of pedicle violation<sup>7,10,15,18</sup>.

Correct insertion of thoracic pedicle screws is much important in correct position because of the closeness of the spinal cord and relative narrowed spinal canal<sup>10,12</sup>. Moreover, insertion of thoracic pedicle on the left side needs more caution because aorta is placed close to posterolateral side of the vertebral column<sup>8,16</sup>. In particular, upper thoracic pedicles between T1 and T6 are positioned in cranio-caudal plane (Lien). With the classical position, anesthesiologist and monitor were placed near to patient's head. Surgeons stand classically near to patient's body while patients are lying in prone position. Manipulation of thoracic pedicle screws on the left side is difficult for right-handed surgeons in classical position<sup>20</sup>. We recommend a new standing position to insert pedicle screws in upper thoracic segments. With the new standing position,



**Fig. 1.** The new standing position: Surgeons stand by the head of the patient and the anesthesia monitor placed laterally, under patient's belt level.

surgeons stand by the head of the patient and the anesthesia monitor is placed lateral side, under patient's belt level (Fig. 1).

In this study, we retrospectively evaluated the two different positions for right-handed surgeons during inserting pedicle screws into the upper thoracic spine. Our hypothesis is that the new position we recommended may maintain more comfortable position for the right-handed spine surgeons on the left side.

## MATERIALS AND METHODS

Patients who underwent upper thoracic spine pedicle screw placement between 2010 and 2016 were retrospectively evaluated. Patients' demographics were detailed in Table 1. Patients were divided into two groups named classical positioning group and new positioning group. Both groups divided into two subgroups named screw malposition group and pedicle wall violation group. Finally, pedicle wall violation group divided into four subgroups named medial, lateral, superior and inferior. Postoperative computed tomography (CT) scans of the thoracic spine were obtained for all patients. Pedicle screws were marked as "correct" if they were fully contained within the pedicle walls. Besides, pedicle wall violations were measured and graded according to Gertzbein classification at either : 1–2 mm penetration, 2–4 mm penetration, or greater than 4 mm penetration<sup>5</sup>. Right or left sides of the cortical

**Table 1.** Patient demographics and indications for surgery

	Value
Gender	
Male	21
Female	12
Total	33
Age (years)	
Age range	12–78
Mean age	42.1
Indications for surgery	
Deformity	9
Tumor	9
Infection	8
Thoracic disc herniation	4
Trauma	3

penetrations were marked. The screw malposition and pedicle wall violations were divided and evaluated separately.

### Standing positions

Patients were operated under general anesthesia by two right-handed spine surgeons. In the first group, anesthesiologist and monitor were placed near to patient’s head. Surgeons stood classically lateral sides of the patient’s body while patients were lying in prone position. In the second group, surgeons stood by the head of the patient and the anesthesia monitor was placed on the lateral side, under patient’s belt level (Fig. 1). For the both groups, the thoracic spinal level was confirmed under per-operative C-arm fluoroscopy with caution. The sagittal trajectory of the probe is based upon the external anatomy of the posterior thoracic spine, the lamina and spinous processes. Cranio-caudal angulation is based upon per-operative C-arm fluoroscopy. Free-hand technique<sup>10)</sup> was used when inserting the screws. 4.0–4.5 mm diameter pedicle screws were placed between T1–6 for spinal stabilization.

### Statistical evaluation

Statistical analyses were conducted using SPSS (IBM Corp., Armonk, NY, USA; IBM SPSS Statistics for Macintosh version 23.0, IBM Corp.). Chi-square test was utilized to check the proportion of significant medial, lateral, superior and inferior pedicle wall violations by both the standing positions for right and left sides. Results are expressed as the mean (range), with a *p* value of 0.05 considered as being statistically significant.

## RESULTS

We retrospectively reviewed 33 patients (21 males and 12 fe-

males) who underwent upper thoracic pedicle screw instrumentation due to various pathologies. Mean age was 42.1 years in range between 12 and 78 years. In 15 patients, a total of 110 thoracic pedicle screws were inserted to the upper thoracic spine (T1–6) with classical position. In 18 patients, a total of 88 screws were inserted to the upper thoracic spine with the new position (Fig. 1). Indications for thoracic spine surgery were spinal deformity (n=9, 27%), spinal trauma (n=9, 27%), metastatic or primary tumors (n=8, 25%), thoracic disc herniation (n=4, 12%) and spinal infections (n=3, 9%).

Total 198 screws were inserted to upper thoracic vertebrae of the patients. Of 198 screws 110 were in the classical positioning group and 88 were in the new positioning group.

Incorrect screw containments in medial, lateral, superior and inferior directions were assessed by CT scans and results were shown in Table 2. Total screw malposition rate was 16.6% (n=33) in both groups. Eighty-five screws (77.3%) were completely within the pedicle in the classical positioning group (Table 2). Twenty-five screws (22.7%) penetrated the pedicle walls according to Gertzbein classification. Six incorrect screws were on the right side, whereas 19 were on the left side. Seventeen screws penetrated in one direction and eight screw penetrated in two directions. In the axial CT images, total 33 pedicle wall violations were observed. Three of the pedicle wall violations were medially, 11 of the pedicle wall violations were laterally, 16 of the pedicle wall violations were superiorly, and three of the pedicle wall violations were inferiorly. Twenty-five of the pedicle wall violations were on the left side and 8 were on the right side (Table 2).

Malposition rate of the screws positioned via the new standing position was 9% (n=8). Three incorrect screws were on the right side, whereas five were on the left side (Table 1). Two screws penetrated in one direction and three screws penetrated in two directions. In the axial CT images, two pedicle wall

**Table 2.** Sides, directions numbers and degrees of the pedicle wall violations with the classical standing position and new standing position

	Medial	Lateral	Superior	Inferior	Total	Penetration grade		
						<2 mm	2–4 mm	>4 mm
Classical standing position								
Right	1	3	2	2	8	4	3	1
Left	2	8	14	1	25	18	6	1
New standing position								
Right	0	1	1	1	3	2	1	0
Left	2	3	2	1	8	4	3	1
Total	5	15	19	5	44	28	13	3

**Table 3.** *p*-values by chi-square test for violation in both standing positions by sides and directions

	Direction			
	Medial	Lateral	Superior	Inferior
Right side	0.381	0.454	0.727	0.727
Left side	0.858	0.196	0.004	0.9

violations were medially, four pedicle wall violations were laterally, three pedicle wall violations were superiorly, and two pedicle wall violations were inferiorly. Right and left side total pedicle wall violations were three and eight, respectively (Table 2).

The differences between the medial, lateral, and inferior pedicle walls violations by both standing positions were found to be statistically insignificant for the left side. The difference between the superior pedicle wall violations by both standing position was found to be statistically significant for the left side ( $p=0.004$ ) (Table 3).

The differences between the medial, lateral, superior, and inferior pedicle walls violations in both two groups were found to be statistically insignificant for the right side. The difference between total pedicle wall violations by both standing positions were found to be statistically significant ( $p=0.003$ ) (Table 4). Likewise, the difference between total screw malposition by both standing positions were found to be statistically significant ( $p=0.011$ ). The difference between the left side screw malpositions in the new positioning group ( $n=5$ ) and total right side screw malpositions ( $n=9$ ) in both groups were found to be statistically insignificant ( $p=0.827$ ).

Surgeon one and surgeon two inserted 18 of 102 screws incorrectly and 15 of 96 screws incorrectly, respectively. The difference between incorrect screw placements of both surgeons was statistically insignificant ( $p=0.703$ ).

## DISCUSSION

Inserting pedicle screws into upper thoracic spine needs talent and experience. Additionally, the positioning and insertion technique are very important for this challenging intervention. Changing the standing position of surgeons may decrease the malposition rate of right-handed spine surgeons on the left side when inserting pedicle screws into upper thoracic spine.

Thoracic pedicle screws biomechanically maintain stronger

**Table 4.** *p*-values by chi-square test for screw malposition and pedicle wall penetration in both standing positions by sides

	Screw malposition	Pedicle wall violation
Right side	0.532	0.258
Left side	0.005	0.003
Total	0.011	0.003

stabilization when compared to other fusion techniques. The pullout strength of the pedicle screws is much stronger and the fusion rates are higher due to larger bone-implant area<sup>7,11,14</sup>. Per-operative fluoroscopy has been the most commonly used method to guide the insertion of pedicle screws into thoracic spine. Nevertheless, up to 40% rate of pedicle wall violation has been noted in the literature<sup>19</sup>. The free-hand thoracic pedicle screw technique has been described by Kim and Lenke<sup>10</sup>. Pedicle screw insertion based on anatomical landmarks and the tactile feel of probing the pedicles. In this study, the free-hand technique was used to insert pedicle screws into thoracic spine. Suk et al.<sup>17</sup> described biplaner thoracic pedicle technique. Four thousand six hundred four pedicle screws were placed with their technique and 1.5% of the pedicles were violated medially. Of the 279 pedicles screws, only two screws penetrated spinal canal (medial wall) in Belmont series<sup>1</sup>. In our patients, five screws of 198 screws were placed medially (2.5%).

The rate of complications due to incorrect pedicle insertion is between 0% and 0.9% in the literature<sup>1,4,6</sup>. Medial pedicle wall violation can cause cord injury, neurological deficits and CSF leakage due to dural injury. Lateral wall violation can cause vascular injury and, pleural irritation and visceral injury<sup>3</sup>. Superior and inferior walls violation can cause dorsal pain, musculoskeletal pain and rib pain due to thoracic nerve root radiculopathy and CSF leakage<sup>1,3,4</sup>. Moreover, pedicle wall violation causes reduction of pull-out strength of the pedicle screws due to reduced bone-implant interface<sup>2</sup>. In our patients, 33 screws of the 198 thoracic screws were inserted incorrectly (16.6%). However, result of this study correlated with previous studies. Our patients did not have any neurological and vascular complications due to incorrect pedicle screw insertion.

In this study, 25 of the pedicle wall violations were on the left side, eight were on the right side in classical positioning group. Violations of the screws were more frequent on the left side, and the difference was statistically significant ( $p=0.001$ ).

In the new positioning group, eight of the pedicle wall violations were on the left side, three were on the right side. The difference between two sides was statistically insignificant ( $p=0.170$ ). The difference between total pedicle wall violations by both standing positions were found to be statistically significant ( $p=0.003$ ). Likewise, the difference between total screw malposition by both standing positions were found to be statistically significant ( $p=0.011$ ). The difference between the left side screw malpositions in the new positioning group ( $n=5$ ) and total right side screw malpositions ( $n=9$ ) in both groups were found to be statistically insignificant ( $p=0.827$ ). This result supports that new standing position is successful to eliminate the difference between both right and left sides.

Thoracic pedicles have special and specific properties. The pedicles of thoracic vertebra are placed in craniocaudal plane<sup>13</sup>). In their large series, Kim and colleagues recommended that the direction of the pedicle screw should be more caudal and lateral in the upper thoracic region<sup>9</sup>). With the classical standing position, it is difficult to direct the screws to medial and superior due to limitation of the patient's body on the operating table for the right-handed surgeon on the left side. The difference between the superior pedicle wall violations by both standing positions was found to be statistically significant for the left side ( $p=0.004$ ). Otherwise, the difference between medial wall violations by both standing positions was found to be statistically insignificant for the left side ( $p=0.858$ ). This can be explained by the fact that medial wall of thoracic pedicle is stronger than the lateral wall. The screws oriented medially usually don't penetrate medial wall because of the medial wall's plasticity and thickening<sup>10</sup>). In particular, the medial pedicle wall tends to keep in the pedicle due to its strong structure in free-hand technique. Moreover, the desire of the surgeon is usually to avoid potential injury to the spinal cord, thus the surgeons force to insert screw laterally uncomfortably.

In conclusion, the insertion of thoracic pedicle on the right side is easily for right-handed surgeons but insertion of the thoracic pedicle screw on the left side is difficult for right-handed surgeons because the pedicles of thoracic vertebra are placed in cranio-caudal plane. Instead of classical position, placing the anesthesia monitor lateral side of the patient in prone position (under belt level) and maintaining position of the surgeons close to the patient's head during inserting upper thoracic spine will provide a comfortable position for the right-handed surgeons and decrease the screw malpositioning

rate especially on the left side.

This study had some limitations. The number of patients was low. A more cases study should be performed. Secondly, this is a retrospective study in a single center; a multicenter prospective randomized controlled study between classical standing position and new standing position should be performed.

## CONCLUSION

Right-handedness is an important problem during the upper thoracic pedicle screw placement on the left side due to specific properties of the pedicles. Changing the surgeon's position, standing near to patient's head will provide a much comfortable position to orient during inserting pedicle screw in the upper thoracic spine.

## CONFLICTS OF INTEREST

No potential conflict of interest relevant to this article was reported.

## INFORMED CONSENT

This type of study does not require informed consent.

## References

1. Belmont PJ Jr, Klemme WR, Dhawan A, Polly DW Jr : In vivo accuracy of thoracic pedicle screws. **Spine (Phila Pa 1976)** **26** : 2340-2346, 2001
2. Costa F, Villa T, Anasetti F, Tomei M, Ortolina A, Cardia A, et al. : Primary stability of pedicle screws depends on the screw positioning and alignment. **Spine J** **13** : 1934-1939, 2013
3. Di Silvestre M, Parisini P, Lolli F, Bakaloudis G : Complications of thoracic pedicle screws in scoliosis treatment. **Spine (Phila Pa 1976)** **32** : 1655-1661, 2007
4. Fisher CG, Sahajpal V, Keynan O, Boyd M, Graeb D, Bailey C, et al. : Accuracy and safety of pedicle screw fixation in thoracic spine trauma. **J Neurosurg Spine** **5** : 520-526, 2006
5. Gertzbein SD, Robbins SE : Accuracy of pedicular screw placement in vivo. **Spine (Phila Pa 1976)** **15** : 11-14, 1990
6. Guzey FK, Emel E, Hakan Seyithanoglu M, Serdar Bas N, Ozkan N, Sel

- B, et al. : Accuracy of pedicle screw placement for upper and middle thoracic pathologies without coronal plane spinal deformity using conventional methods. **J Spinal Disord Tech** **19** : 436-441, 2006
7. Hackenberg L, Link T, Liljenqvist U : Axial and tangential fixation strength of pedicle screws versus hooks in the thoracic spine in relation to bone mineral density. **Spine (Phila Pa 1976)** **27** : 937-942, 2002
  8. Heini P, Schöll E, Wyler D, Egli S : Fatal cardiac tamponade associated with posterior spinal instrumentation. A case report. **Spine (Phila Pa 1976)** **23** : 2226-2230, 1998
  9. Kim YJ, Lenke LG, Bridwell KH, Cho YS, Riew KD : Free hand pedicle screw placement in the thoracic spine: is it safe? **Spine (Phila Pa 1976)** **29** : 333-342; discussion 342, 2004
  10. Kim YJ, Lenke LG : Thoracic pedicle screw placement: free-hand technique. **Neurol India** **53** : 512-519, 2005
  11. Lee CS, Kim MJ, Ahn YJ, Kim YT, Jeong KI, Lee DH : Thoracic pedicle screw insertion in scoliosis using posteroanterior C-arm rotation method. **J Spinal Disord Tech** **20** : 66-71, 2007
  12. Lehman RA Jr, Polly DW Jr, Kuklo TR, Cunningham B, Kirk KL, Belmont PJ Jr : Straight-forward versus anatomic trajectory technique of thoracic pedicle screw fixation: a biomechanical analysis. **Spine (Phila Pa 1976)** **28** : 2058-2065, 2003
  13. Lien SB, Liou NH, Wu SS : Analysis of anatomic morphometry of the pedicles and the safe zone for through-pedicle procedures in the thoracic and lumbar spine. **Eur Spine J** **16** : 1215-1222, 2007
  14. Liljenqvist U, Hackenberg L, Link T, Halm H : Pullout strength of pedicle screws versus pedicle and laminar hooks in the thoracic spine. **Acta Orthop Belg** **67** : 157-163, 2001
  15. Liljenqvist UR, Halm HF, Link TM : Pedicle screw instrumentation of the thoracic spine in idiopathic scoliosis. **Spine (Phila Pa 1976)** **22** : 2239-2245, 1997
  16. Minor ME, Morrissey NJ, Peress R, Carroccio A, Ellozy S, Agarwal G, et al. : Endovascular treatment of an iatrogenic thoracic aortic injury after spinal instrumentation: case report. **J Vasc Surg** **39** : 893-896, 2004
  17. Suk SI, Kim WJ, Lee SM, Kim JH, Chung ER : Thoracic pedicle screw fixation in spinal deformities: are they really safe? **Spine (Phila Pa 1976)** **26** : 2049-2057, 2001
  18. Vaccaro AR, Rizzolo SJ, Balderston RA, Allardyce TJ, Garfin SR, Dolinskas C, et al. : Placement of pedicle screws in the thoracic spine. Part II: an anatomical and radiographic assessment. **J Bone Joint Surg Am** **77** : 1200-1206, 1995
  19. Wang VY, Chin CT, Lu DC, Smith JS, Chou D : Free-hand thoracic pedicle screws placed by neurosurgery residents: a CT analysis. **Eur Spine J** **19** : 821-827, 2010
  20. Yaman O, Acaroğlu E : Role of surgeon handedness in transpedicular screw insertion. **Acta Orthop Traumatol Turc** **48** : 479-482, 2014