

Outcomes of Brugada Syndrome Patients with Coronary Artery Vasospasm

Shingo Kujime¹, Harumizu Sakurada², Naoki Saito¹, Yoshinari Enomoto³, Naoshi Ito³, Keijiro Nakamura³, Seiji Fukamizu⁴, Tamotsu Tejima⁵, Yuzuru Yambe¹, Mitsuhiro Nishizaki⁶, Mahito Noro³, Masayasu Hiraoka⁷ and Kaoru Sugi³

Abstract

Objective To evaluate the outcomes of patients with concomitant Brugada syndrome and coronary artery vasospasm.

Methods Patients diagnosed with Brugada syndrome with an implantable cardiac defibrillator were retrospectively investigated, and the coexistence of vasospasm was evaluated. The clinical features and outcomes were evaluated, especially in patients with coexistent vasospasm. A provocation test using acetylcholine was performed in patients confirmed to have no organic stenosis on percutaneous coronary angiography to confirm the presence of vasospasm. Implantable cardiac defibrillator shock status was checked every three months. Statistical comparisons of the groups with and without vasospasm were performed. A univariate analysis was also performed, and the odds ratio for the risk of implantable cardiac defibrillator shock was calculated.

Patients Thirty-five patients with Brugada syndrome, of whom six had coexistent vasospasm.

Results There were no significant differences in the laboratory data, echocardiogram findings, disease, or the history of taking any drugs between patients with and without vasospasm. There were significant differences in the clinical features of Brugada syndrome, i.e. cardiac events such as resuscitation from ventricular fibrillation or appropriate implantable cardiac defibrillator shock. Four patients with vasospasm had cardiac events such as resuscitation from ventricular fibrillation and/or appropriate defibrillator shock; three of them had no cardiac events with calcium channel blocker therapy to prevent vasospasm. The coexistence of vasospasm was a potential risk factor for an appropriate implantable cardiac defibrillator shock (odds ratio: 13.5, confidence interval: 1.572-115.940, p value: 0.035) on a univariate analysis.

Conclusion Coronary artery vasospasm could be a risk factor for cardiac events in patients with Brugada syndrome.

Key words: Brugada syndrome, coronary artery vasospasm, risk stratification

(Intern Med 56: 129-135, 2017)

(DOI: 10.2169/internalmedicine.56.7307)

Introduction

Brugada syndrome (BrS) is a primary disease that causes

sudden cardiac events, and the use of an implantable cardiac defibrillator (ICD) is recommended. Risk stratification for cardiac events has been a major problem. It is widely recognized that a previous history of resuscitation from ventricu-

¹Department of Cardiology, Yokohama General Hospital, Japan, ²Department of Cardiology, Tokyo Metropolitan Health and Medical Treatment Corporation Ohkubo Hospital, Japan, ³Division of Cardiovascular Medicine, Toho University Medical Center Ohashi Hospital, Japan, ⁴Department of Cardiology, Tokyo Metropolitan Hiroo Hospital, Japan, ⁵Department of Cardiology, Tokyo Metropolitan Tama Medical Center, Japan, ⁶Department of Cardiology, Yokohama Minami Kyosai Hospital, Japan and ⁷Department of Cardiology, Toride Kitasohma Medical Center Hospital, Japan

Received for publication February 22, 2016; Accepted for publication May 31, 2016

Correspondence to Dr. Shingo Kujime, shingo@oha.toho-u.ac.jp

lar fibrillation (VF) is a major risk factor. Other risk factors include male sex, spontaneous type-1 pattern on electrocardiogram (ECG), family history of BrS, previous history of VF induced by ventricular stimulation during electrophysiological study (EPS), late potential measured by signal-averaged electrocardiography, and atrial fibrillation, but no consensus has been reached with regard to these factors (1-6).

Attacks of BrS tend to occur during the period from night to early morning. Coronary artery vasospasm (spasm) has similar clinical features (7-11). Recently, several reports have described the coexistence of BrS and spasm (12-16). The coexistence of spasm may affect the outcomes of BrS patients. The outcomes of patients with concomitant BrS and spasm were evaluated.

Materials and Methods

Patients diagnosed with BrS in our hospital were retrospectively investigated. Patients with an ICD were selected, and the coexistence of spasm was evaluated. In patients with coexistent spasm in particular, the clinical features and outcomes were evaluated.

Definition of BrS

BrS was defined as follows: 1) BrS was diagnosed in patients with ST-segment elevation with type I morphology ≥ 2 mm in ≥ 1 lead among the right precordial leads V1 and V2 positioned in the 2nd, 3rd, or 4th intercostal space occurring either spontaneously or after a provocative drug test with intravenous administration of Class I (pilsicainide 1 mg/kg) antiarrhythmic drugs; 2) BrS was diagnosed in patients with type 2 or type 3 ST-segment elevation in ≥ 1 lead among the right precordial leads V1 and V2 positioned in the 2nd, 3rd, or 4th intercostal space when a provocative drug test with intravenous administration of Class I (pilsicainide 1 mg/kg) antiarrhythmic drugs induced a type I ECG morphology. The following components were considered: a history of resuscitation from VF, unexplained syncope, a family history of BrS, and VF induced by up to three premature ventricular stimulations at the right ventricular apex or right ventricular outflow tract during EPS (17-20).

Definition of spasm

A provocation test using acetylcholine (ACh) was performed in patients who had been confirmed to have no organic stenosis by percutaneous coronary angiography. A total of 20 μ g, 50 μ g, and 100 μ g ACh were administered in the left coronary artery (LCA), and 20 μ g and 50 μ g ACh were administered in the right coronary artery (RCA), sequentially, each over 20 seconds. Angiography was obtained one minute after the completion of administration (21). The TIMI classification was used to evaluate the coronary flow (22). Patients with TIMI flow 0 or 1 on angiography, ST change in the supplying territory of the abnormal coronary artery, and/or angina symptoms were diagnosed as

positive for spasm (23-26).

Evaluation methods for ICD shock

The status of ICD shock was checked every 3 months. When any shocks were noted, the intracardiac ECG recorded by ICD was thoroughly evaluated for signs of inappropriate shock, such as sinus tachycardia, atrial fibrillation, and T-wave oversensing.

In this investigation, informed consent was obtained from all of the patients, and the study protocol conformed to the ethical guidelines of the Declaration of Helsinki. This study was reviewed and approved by the Yokohama General Hospital Ethics Committee.

Statistical methods

Statistical comparisons of the two groups were performed using Student's *t*-test for continuous variables and the chi-squared test (Fisher's exact test) for non-continuous variables. A univariate analysis was performed, and the odds ratio was calculated for the risk of ICD shock. A *p* value of < 0.05 was considered significant in all tests.

Results

There were 35 patients with BrS; 6 had coexistent spasm. The patients' characteristics are shown in Table 1. There were no significant differences in laboratory data, echocardiogram findings, disease, and the history of taking any drugs between patients with and without spasm. There were, however, significant differences in the clinical features of BrS, i.e. cardiac event such as resuscitation from VF or appropriate ICD shock.

The details of the six patients with coexistent spasm are shown in Table 2. All six were men. Four patients had a defined cardiac event, and the same four patients had spasm in the RCA. All six patients were treated with a calcium channel blocker (CCB) to prevent spasm. Only Case 2 had a recurrent cardiac event (relapse of appropriate ICD shock after taking the CCB). The risk factors for an appropriate ICD shock were analyzed using a univariate analysis (Table 3). The coexistence of spasm was a potential risk factor (odds ratio [OR]: 13.5, 95% confidence interval [CI]: 1.572-115.940, *p* value: 0.035).

The precordial leads on ECG and the clinical information of five patients with coexistent spasm in the RCA (Cases 1-5) are presented.

Case 1 is illustrated in Fig. 1. A 29-year-old healthy man experienced VF during a morning conference. He had spontaneous type-1 ECG change, inducibility of VF during EPS, and spasm in the RCA. The marked type-1 pattern on ECG manifested during provocation with pilsicainide and when RCA spasm appeared. There was concern that BrS or spasm might have contributed to the VF, so an ICD was implanted, and a CCB was prescribed. The patient had no further episodes of VF or ICD shocks.

Case 2 is illustrated in Fig. 2. A 33-year-old healthy man

Table 1. Characteristics of All Patients.

	BrS with spasm (n=6)	BrS without spasm (n=29)	p
Age (y)	35.7±5.43	35.7±8.23	NS
Male	6 (100)	26 (89.7)	NS
Smoking	2 (33.3)	9 (31.0)	NS
Laboratory data			NS
Total cholesterol (mg/dL)	185.7±32.8	193.3±21.1	NS
High density cholesterol (mg/dL)	52.1±12.2	50.2±9.8	NS
Triglycerides (mg/dL)	125.3±54.3	129.5±32.7	NS
Hemoglobin A1c (%)	5.1±0.8	5.2±0.3	NS
Echocardiogram findings			NS
Ejection fraction (%)	71.1±28.7	67.8±8.9	NS
Left atrial dimension (mm)	36.9±4.5	35.9±5.3	NS
Left ventricular end-diastolic dimension (mm)	46.4±4.5	45.7±5.4	NS
Left ventricular end-systolic dimension (mm)	28.1±5.1	28.2±6.0	NS
Ventricular septal wall thickness (mm)	9.6±1.5	9.1±1.3	NS
Posterior wall thickness (mm)	9.4±1.4	9.7±1.3	NS
History of any disease			NS
Hypertension	0 (0)	1 (3.4)	NS
Dyslipidemia	0 (0)	1 (3.4)	NS
Diabetes mellitus	0 (0)	0 (0)	NS
Any drug			NS
Calcium channel blocker	0 (0)	0 (0)	NS
ACE-I/ARB	0 (0)	1 (3.4)	NS
Statin	0 (0)	1 (3.4)	NS
Clinical features			NS
Spontaneous type-1	3 (50)	14 (48.2)	NS
Family history of BrS	2 (33.3)	10 (34.5)	NS
Inducibility of VF during EPS	4 (66.7)	20 (69.0)	NS
Episode of cardiac event	4 (66.7)	4 (13.8)	<0.05
Resuscitation from VF	3 (50.0)	3 (10.3)	<0.05
Appropriate ICD shock	3 (50.0)	2 (6.9)	<0.05

ACEI: angiotensin converting enzyme inhibitor, ARB: aldosterone receptor blocker, BrS: Brugada syndrome, ICD: implantable cardioverter defibrillator, spasm: coronary artery vasospasm

Table 3. Univariate Analysis for Appropriate Implantable Cardioverter Defibrillator Shock.

	Odds ratio	95% CI	p
BrS with spasm	13.5	1.572-115.940	0.035

BrS: Brugada syndrome, spasm: coronary artery vasospasm

experienced VF during sleep. He had a normal ECG, no inducibility of VF during EPS, and spasm in the RCA. The marked type-1 pattern manifested only after provocation with pilsicainide. There was concern that BrS might have contributed to the occurrence of VF, so an ICD was implanted. He experienced an appropriate ICD shock for a relapse of VF after 10 months. There was concern about spasm, and a CCB was prescribed. However, he had an episode of ICD shock for a relapse of VF despite taking a CCB.

Case 3 is illustrated in Fig. 3. A 34-year-old healthy man experienced VF during sleep. He had BrS-like ECG change, no inducibility of VF during EPS, and spasm in the RCA. The marked type-1 pattern manifested after provocation with pilsicainide and when RCA spasm appeared. There was concern that BrS or spasm might have contributed to the VF, so an ICD was implanted, and a CCB was prescribed. However, the patient stopped taking the CCB after 14 months. After 18 months, he had an episode of ICD shock for a

Table 2. Characteristics of Patients with Concomitant Brugada Syndrome and Coronary Artery Vasospasm.

Case	Age (y) (sex)	Family history	Inducibility of VF during EPS	Type-1 pattern on ECG	About spasm		Cardiac event	
					Branch of spasm	Type-1 pattern on ECG with appearance of spasm?	Before CCB	After CCB
1	29 (M)	-	+	Spontaneously	RCA	Marked	Resuscitation from VF	None
2	33 (M)	-	-	Pharmacologically	RCA	None	Resuscitation from VF and ICD shock	ICD shock
3	34 (M)	-	-	Pharmacologically	RCA	Marked	Resuscitation from VF and ICD shock	None
4	35 (M)	-	+	Pharmacologically	RCA	None	Unknown syncope	None
5	38 (M)	+	+	Spontaneously	RCA	Marked	ICD shock	None
6	45 (M)	+	+	Spontaneously	LCX	None	None	None

CCB: calcium channel blocker, ECG: electrocardiogram, EPS: electrophysiological study, ICD: implantable cardioverter defibrillator, LCX: left circumflex artery, pharmacologically: after provocation with pilsicainide, RCA: right coronary artery, VF: ventricular fibrillation

lapse of VF. He is now taking the CCB regularly, and there have been no episodes of VF relapse or ICD shock.

Case 4 is illustrated in Fig. 4. A 35-year-old healthy man experienced 3 episodes of syncope of unknown origin. He had BrS-like ECG change, inducibility of VF during EPS, and spasm in the RCA. The marked type-1 pattern manifested only after provocation with pilsicainide. As requested, an ICD was implanted, and a CCB was prescribed. The patient has had no further episodes of syncope or VF or ICD shocks.

Case 5 is illustrated in Fig. 5. A 35-year-old healthy man had a family history of BrS; his father and brother were diagnosed with BrS. He also had inducibility of VF during

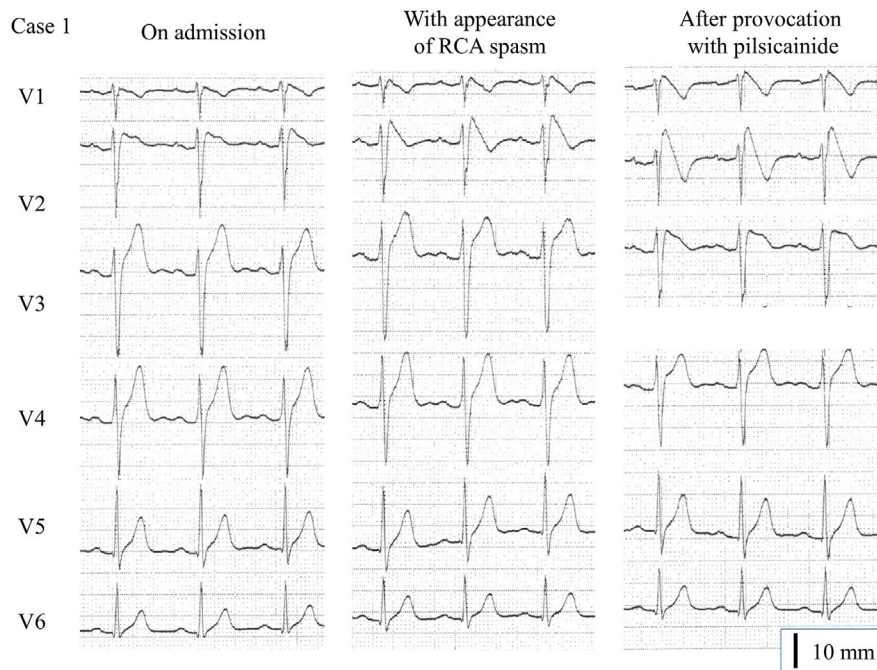


Figure 1. A 29-year-old healthy man. The electrocardiogram on admission shows the spontaneous type-1 pattern. The marked type-1 pattern manifests during provocation with pilsicainide and while right coronary artery spasm appears.

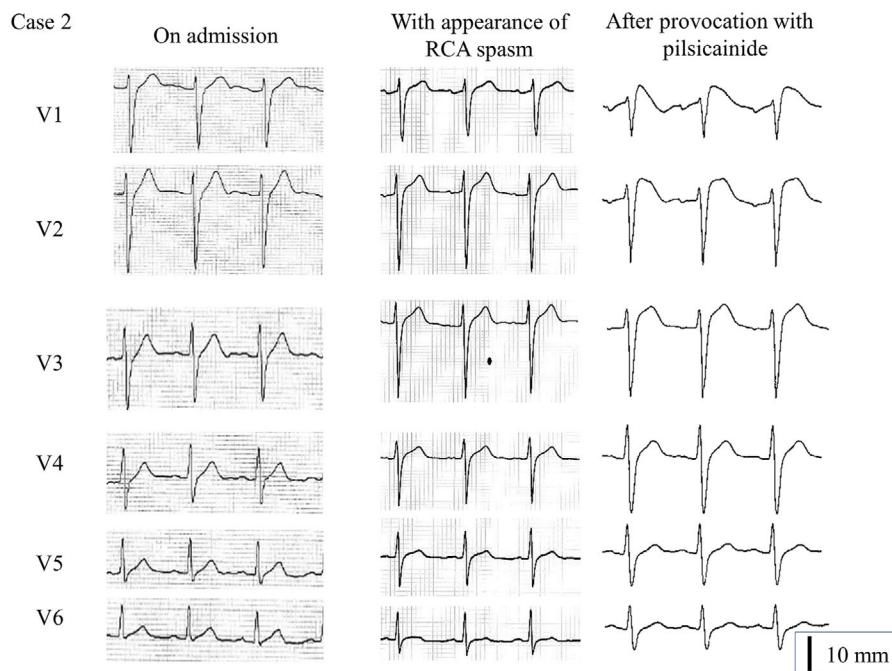


Figure 2. A 33-year-old healthy man. The electrocardiogram on admission is normal. The electrocardiogram during right coronary artery spasm is also normal. However, the marked type-1 pattern manifests only after provocation with pilsicainide.

EPS and spasm in the RCA. The marked type-1 pattern manifested after provocation with pilsicainide and when RCA spasm appeared. As requested, an ICD was implanted. After 38 months, he experienced an ICD shock for VF. There was concern that spasm might have contributed to the occurrence of VF, so a CCB was prescribed. The patient

then had no further episodes of VF or appropriate ICD shocks.

In addition, these five patients had no remarkable changes on ECG, such as marked type-1 pattern on ECG and bradycardia, after starting CCB treatment.

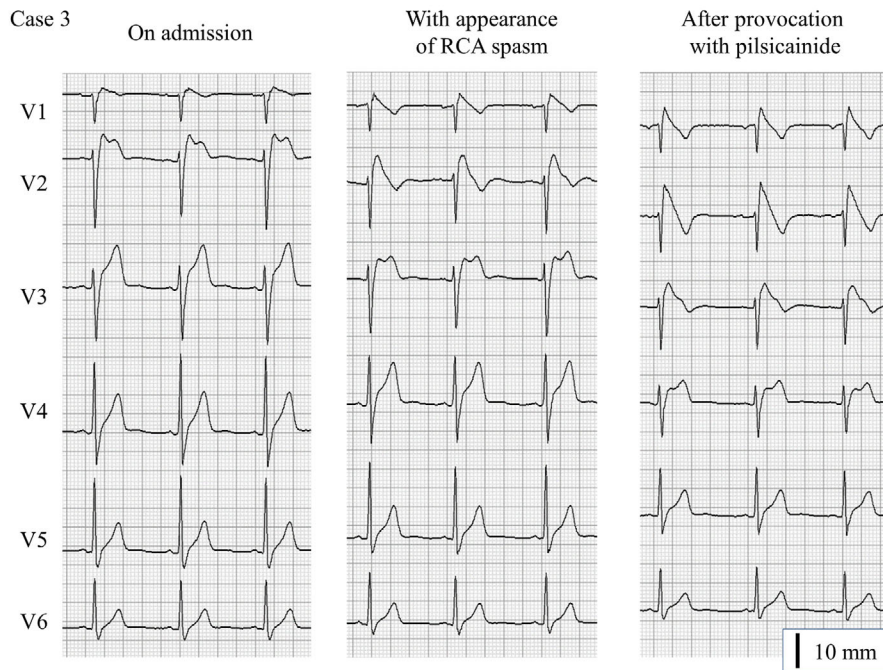


Figure 3. A 34-year-old healthy man. The electrocardiogram on admission shows Brugada syndrome-like change. The marked type-1 pattern manifests after provocation with pilosicainide and while right coronary artery spasm appears.

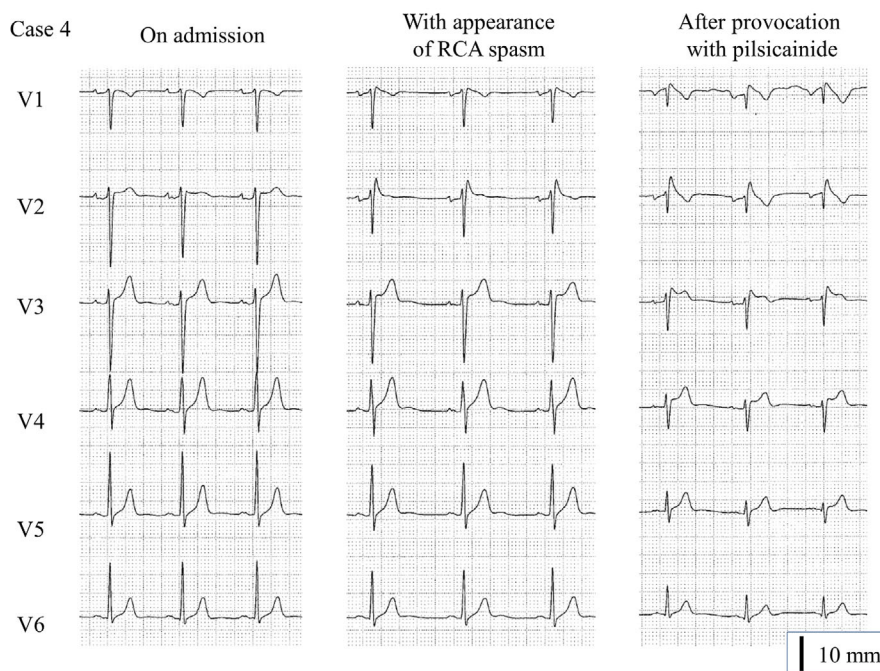


Figure 4. A 35-year-old healthy man. The electrocardiogram on admission and during right coronary artery spasm shows Brugada syndrome-like change but does not meet the criteria for Brugada syndrome. The marked type-1 pattern manifests only after provocation with pilosicainide.

Discussion

Many BrS patients with coexistent RCA spasm had cardiac events such as resuscitation from VF and/or appropriate ICD shock. Cases 1, 3, and 5 were very remarkable. These

three cases had the marked type-1 pattern on ECG not only after provocation with pilosicainide but also during spastic change, i.e. ischemic change in the RCA. These three cases also had no cardiac events after taking a CCB for spasm prevention.

The RCA is known to be a feeding vessel for the right

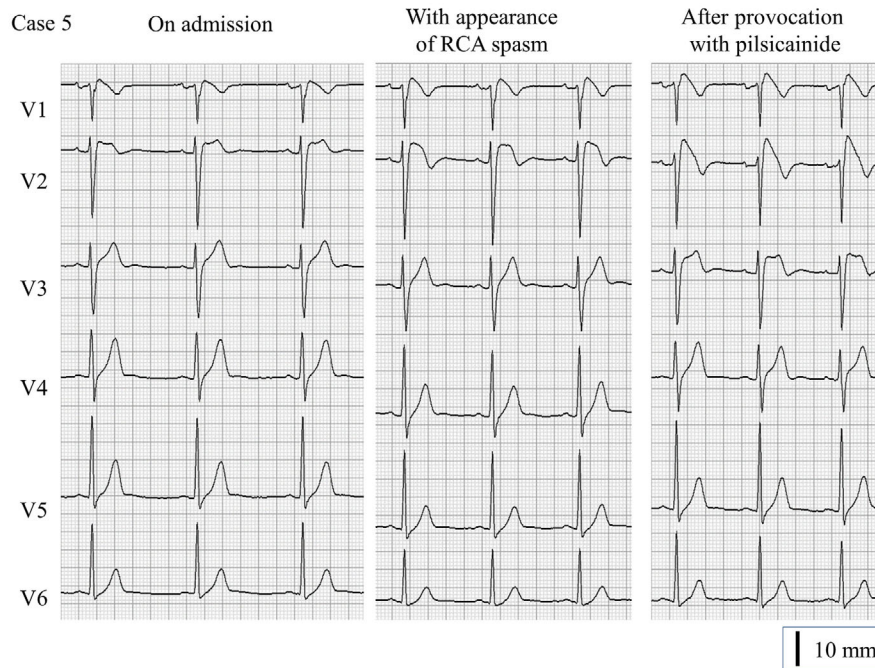


Figure 5. A 35-year-old healthy man. The electrocardiogram on admission shows Brugada syndrome-like change but does not meet the criteria for Brugada syndrome. The marked type-1 pattern manifests after provocation with pilsicainide and while right coronary artery spasm appears.

ventricular outflow tract (27). Ischemic change in the RCA will cause imbalance in the right ventricular outflow tract. It has been reported that the mechanism of formation of the type-1 pattern on ECG and initiation of VF are related to imbalanced endocardial and epicardial action potentials in the right ventricular outflow tract (28-30). RCA spasm can cause ischemic change and an imbalance of action potentials in the right ventricular outflow tract. Cases 1, 3, and 5 had the marked type-1 pattern on ECG during spastic change in the RCA, and this phenomenon evoked an imbalance in the right ventricular outflow tract. Once RCA spasm occurs in BrS patients, it may contribute to cardiac events.

We emphasize that the etiology of cardiac events is not only RCA spasm. One BrS patient developed a cardiac event despite taking a CCB for prevention of spasm, as shown in Case 2. There was also a BrS patient who developed a cardiac event without spasm. CCBs should not be prescribed to all BrS patients with spasm. It has been reported that currents related to calcium may be attenuated by CCBs, which may lead to worsening of the clinical condition of BrS patients (31). Accordingly, the usefulness of CCB therapy cannot be determined based on the results of the present investigation alone, and further investigations are warranted. We prescribed a CCB to patients in whom the involvement of spasm was strongly suspected. At present, the use of CCBs should be carefully decided on a case-by-case basis.

The rate of coexistence of BrS and spasm has been discussed previously, and it was found in 17% of the present cases. This rate does not seem markedly different from those in previous reports in Japan, but it might be higher than in

Caucasian populations (32); it is widely known that Japanese patients have a higher rate of coronary artery disease than Caucasian patients (33). Regardless of the presence or absence of BrS, the rate probably differs among ethnic groups.

Several limitations associated with the present study warrant mention. First, and most importantly, we were unable to distinguish whether the cause of the cardiac events was spasm or BrS. It is difficult to resolve this problem using the interrogated data of an ICD. Even if spasm is suspected as the cause of VF, it is difficult to remove the ICD from patients meeting the criteria for BrS. Spasm in the present study was not spontaneous, but artificially induced. The effect needs to be investigated over the long term. Second, BrS is not a common disease. The study population was very small, and the number of patients with coexistent spasm was much smaller. Only a univariate analysis could be performed. Finally, atrial fibrillation and late potentials, which are also reported as risk factors for sudden cardiac events, were not evaluated.

In our view, spasm is not the only etiology of cardiac events in BrS. It would therefore be rash to say that spasm is a risk factor for cardiac events in BrS. Further study is needed in order to draw hard conclusions about the relationship between BrS and spasm. However, we should at least recognize that spasm could be a potential risk factor for cardiac events in BrS.

The authors state that they have no Conflict of Interest (COI).

References

- Antzelevitch C, Brugada P, Borggrefe M, et al. Brugada syndrome: report of the second consensus conference: endorsed by the Heart Rhythm Society and the European Heart Rhythm Association. *Circulation* **111**: 659-670, 2005.
- Gehi AK, Duong TD, Metz LD, Gomes JA, Mehta D. Risk stratification of individuals with the Brugada electrocardiogram: a meta-analysis. *J Cardiovasc Electrophysiol* **17**: 577-583, 2006.
- Brugada J, Brugada R, Brugada P. Determinants of sudden cardiac death in individuals with the electrocardiographic pattern of Brugada syndrome and no previous cardiac arrest. *Circulation* **108**: 3092-3096, 2003.
- Brugada P, Brugada R, Mont L, Rivero M, Geelen P, Brugada J. Natural history of Brugada syndrome: the prognostic value of programmed electrical stimulation of the heart. *J Cardiovasc Electrophysiol* **14**: 455-457, 2003.
- Ikeda T, Sakurada H, Sakabe K, et al. Assessment of noninvasive markers in identifying patients at risk in the Brugada syndrome: insight into risk stratification. *J Am Coll Cardiol* **37**: 1628-1634, 2001.
- Kusano KF, Taniyama M, Nakamura K, et al. Atrial fibrillation in patients with Brugada syndrome relationships of gene mutation, electrophysiology, and clinical backgrounds. *J Am Coll Cardiol* **51**: 1169-1175, 2008.
- Matsuo K, Kurita T, Inagaki M, et al. The circadian pattern of the development of ventricular fibrillation in patients with Brugada syndrome. *Eur Heart J* **20**: 465-470, 1999.
- Yasue H, Kugiyama K. Coronary spasm: clinical features and pathogenesis. *Intern Med* **36**: 760-765, 1997.
- Yasue H, Touyama M, Shimamoto M, Kato H, Tanaka S. Role of autonomic nervous system in the pathogenesis of Prinzmetal's variant form of angina. *Circulation* **50**: 534-539, 1974.
- Yasue H, Takizawa A, Nagao M, et al. Long-term prognosis for patients with variant angina and influential factors. *Circulation* **78**: 1-9, 1988.
- Koyanagi S, Takeshita A, Nakamura M. Clinical characteristics of sudden cardiac death in patients with vasospastic angina. *Jpn Circ J* **53**: 1541-1545, 1989.
- Chinushi M, Kuroe Y, Ito E, Tagawa M, Aizawa Y. Vasospastic angina accompanied by Brugada-type electrocardiographic abnormalities. *J Cardiovasc Electrophysiol* **12**: 108-111, 2001.
- Noda T, Shimizu W, Taguchi A, et al. ST-segment elevation and ventricular fibrillation without coronary spasm by intracoronary injection of acetylcholine and/or ergonovine maleate in patients with Brugada syndrome. *J Am Coll Cardiol* **40**: 1841-1847, 2002.
- Chinushi M, Furushima H, Tanabe Y, Washizuka T, Aizawa Y. Similarities between Brugada syndrome and ischemia-induced ST-segment elevation. Clinical correlation and synergy. *J Electrocardiol* **38**: 18-21, 2005.
- Aizawa Y, Sato A. Brugada syndrome and vasospastic angina do coexist: potential clinical importance. *Intern Med* **45**: 43-44, 2006.
- Sasaki T, Niwano S, Kitano Y, Izumi T. Two cases of Brugada syndrome associated with spontaneous clinical episodes of coronary vasospasm. *Intern Med* **45**: 77-80, 2006.
- Wilde AA, Antzelevitch C, Borggrefe M, et al; Study Group on the Molecular Basis of Arrhythmias of the European Society of Cardiology. Proposed diagnostic criteria for the Brugada syndrome: consensus report. *Circulation* **5**: 2514-2519, 2002.
- Shimizu W, Matsuo K, Takagi M, et al. Body surface distribution and response to drugs of ST segment elevation in Brugada syndrome: clinical implication of eighty-seven-lead body surface potential mapping and its application to twelve-lead electrocardiograms. *J Cardiovasc Electrophysiol* **11**: 396-404, 2000.
- Miyamoto K, Yokokawa M, Tanaka K, et al. Diagnostic and prognostic value of a type 1 Brugada electrocardiogram at higher (third or second) V1 to V2 recording in men with Brugada syndrome. *Am J Cardiol* **99**: 53-57, 2007.
- Brugada P, Brugada R, Brugada J. Should patients with an asymptomatic Brugada electrocardiogram undergo pharmacological and electrophysiological testing? *Circulation* **112**: 279-292, 2005.
- Sueda S, Izoë Y, Kohno H, Fukuda H, Uraoka T. Need for documentation of guidelines for coronary artery spasm: An investigation by questionnaire in Japan. *Circ J* **69**: 1333-1337, 2005.
- TIMI Study Group. The Thrombolysis in Myocardial Infarction (TIMI) trial; Phase I findings. *N Engl J Med* **312**: 932-936, 1985.
- Yasue H, Horio Y, Nakamura N, et al. Induction of coronary artery spasm by acetylcholine in patients with variant angina: possible role of the parasympathetic nervous system in the pathogenesis of coronary artery spasm. *Circulation* **74**: 955-963, 1986.
- Okumura K, Yasue H, Matsuyama K, et al. Sensitivity and specificity of intracoronary injection of acetylcholine for the induction of coronary artery spasm. *J Am Coll Cardiol* **12**: 883-888, 1988.
- Okumura K, Yasue H, Horio Y, et al. Multivessel coronary spasm in patients with variant angina: a study with intracoronary injection of acetylcholine. *Circulation* **77**: 535-542, 1988.
- Sueda S, Ochi N, Kawada H, et al. Frequency of provoked coronary vasospasm in patients undergoing coronary arteriography with spasm provocation test of acetylcholine. *Am J Cardiol* **83**: 1186-1190, 1999.
- Ogano M, Iwasaki YK, Morita N, et al. Proarrhythmic ECG deterioration caused by myocardial ischemia of the conus branch artery in patients with a Brugada ECG pattern. *Pacing Clin Electrophysiol* **34**: e26-e29, 2011.
- Yan GX, Antzelevitch C. Cellular basis for the Brugada syndrome and other mechanisms of arrhythmogenesis associated with ST-segment elevation. *Circulation* **100**: 1660-1666, 1999.
- Antzelevitch C. The Brugada syndrome: ionic basis and arrhythmia mechanisms. *J Cardiovasc Electrophysiol* **12**: 268-272, 2001.
- Kurita T, Shimizu W, Inagaki M, et al. The electrophysiologic mechanism of ST-segment elevation in Brugada syndrome. *J Am Coll Cardiol* **40**: 330-334, 2002.
- Shimizu W. Acquired forms of Brugada Syndrome. In: *The Brugada Syndrome: From Bench to Bedside*. Antzelevitch C, Brugada P, Brugada J, et al, Eds. Blackwell Futura, UK, 2004: 166-177.
- Ong P, Bastiaenen R, Batchvarov VN, et al. Prevalence of the type 1 Brugada electrocardiogram in Caucasian patients with suspected coronary spasm. *Europace* **13**: 1625-1631, 2011.
- Pristipino C, Beltrame JF, Finocchiaro ML, et al. Major racial differences in coronary constrictor response between Japanese and Caucasians with recent myocardial infarction. *Circulation* **101**: 1102-1108, 2000.

The Internal Medicine is an Open Access article distributed under the Creative Commons Attribution-NonCommercial-NoDerivatives 4.0 International License. To view the details of this license, please visit (<https://creativecommons.org/licenses/by-nc-nd/4.0/>).