

## Original Article

**Cite this article:** Gartenberg AJ, White TJ, Dang K, Shah M, Paridon SM, and Elias MD (2021). Assessing the utility of screening electrocardiograms in paediatric patients following COVID-19. *Cardiology in the Young*, page 1 of 7. doi: [10.1017/S1047951121003012](https://doi.org/10.1017/S1047951121003012)

Received: 14 May 2021

Revised: 15 June 2021

Accepted: 27 June 2021


**Keywords:**

COVID-19; SARS-CoV-2; paediatric cardiology; myocarditis; electrocardiogram

**Author for correspondence:**

M.D. Elias, MD, The Children's Hospital of Philadelphia, Division of Cardiology, 3401 Civic Center Boulevard, Philadelphia, PA 19104, USA. Tel: +215-590-3180; Fax: 267-426-5324. E-mail: [eliasm1@chop.edu](mailto:eliasm1@chop.edu)

# Assessing the utility of screening electrocardiograms in paediatric patients following COVID-19

Ari J. Gartenberg<sup>1</sup>, Travus J. White<sup>1</sup>, Khoi Dang<sup>2</sup>, Maully Shah<sup>1</sup>, Stephen M. Paridon<sup>1</sup> and Matthew D. Elias<sup>1</sup> 

<sup>1</sup>Division of Cardiology, The Children's Hospital of Philadelphia, Philadelphia, PA, USA and <sup>2</sup>Division of General Pediatrics, The Children's Hospital of Philadelphia, Philadelphia, PA, USA

**Abstract**

**Objective:** To determine the utility of screening electrocardiograms after severe acute respiratory syndrome coronavirus 2 (SARS-CoV-2) infection among children in detecting myocarditis related to coronavirus disease 2019 (COVID-19). **Study Design:** A retrospective chart review was performed at a large paediatric academic institution to identify patients with prior SARS-CoV-2 infection who received a screening electrocardiogram by their primary care providers and were subsequently referred for outpatient cardiology consultation due to an abnormal electrocardiogram. The outcomes were the results from their cardiology evaluations, including testing and final diagnoses. **Results:** Among 46 patients, during their preceding COVID-19 illness, the majority had mild symptoms, 4 were asymptomatic, and 1 had moderate symptoms. The median length of time from positive SARS-CoV-2 test to screening electrocardiogram was 22 days, and many electrocardiogram findings that prompted cardiology consultation were normal variants in asymptomatic adolescent athletes. Patients underwent frequent additional testing at their cardiology appointments: repeat electrocardiogram (72%), echocardiogram (59%), Holter monitor (11%), exercise stress test (7%), and cardiac MRI (2%). Five patients were incidentally diagnosed with CHD or structural cardiac abnormalities, and three patients had conduction abnormalities (pre-mature atrial contractions, pre-mature ventricular contractions, borderline prolonged QTc), although potentially incidental to COVID-19. No patients were diagnosed with myocarditis or ventricular dysfunction. **Conclusion:** In a small cohort of children with prior COVID-19, who were primarily either asymptomatic or mildly symptomatic, subsequent screening electrocardiograms identified various potential abnormalities prompting cardiology consultation, but no patient was diagnosed with myocarditis. Larger multi-centre studies are necessary to confirm these results and to evaluate those with more severe disease.

Since the onset of the coronavirus disease 2019 (COVID-19) pandemic, there has been substantial evidence that cardiac injury is common in patients infected with the severe acute respiratory syndrome coronavirus 2 (SARS-CoV-2). Early reports focused on highlighting the alarming rates of acute myocardial injury in hospitalised adult patients with severe disease.<sup>1-5</sup>

More recent studies, however, have demonstrated that a portion of adults with prior COVID-19 continue to have evidence of myocarditis, even after recovery from their illness and even in adults who were never hospitalised.<sup>6-8</sup> Several studies have evaluated younger adults, including collegiate and professional athletes, and have identified myocarditis in a small subset of these patients as well, even in mild or asymptomatic cases.<sup>8-13</sup>

There is currently a paucity of published data regarding the cardiac manifestations in children with acute COVID-19. Most of the current paediatric literature focuses on the multisystem inflammatory syndrome in children, since there is frequently associated ventricular dysfunction, and less commonly, coronary artery aneurysms and arrhythmias.<sup>14-15</sup> Multisystem inflammatory syndrome in children, though, is felt to be a distinct entity due to a delayed immune response to SARS-CoV-2 rather than due to acute viral injury.<sup>16-18</sup>

Since myocarditis is a leading cause of sudden cardiac death in young competitive athletes, multiple guidelines have been developed to risk stratify patients prior to their return to competitive sports after COVID-19.<sup>19-25</sup> There are only a few published guidelines specifically for children, including statements from the American College of Cardiology and the American Academy of Pediatrics.<sup>21,26,27</sup> Most of these guidelines include recommendations for screening electrocardiograms in a subset of patients, followed by cardiology consultation for sports clearance among patients with abnormal electrocardiogram findings. There is no clear evidence, however, that screening electrocardiograms are helpful in the evaluation of myocarditis after COVID-19, especially in paediatrics.<sup>28</sup>

We therefore sought to assess the utility of screening electrocardiograms after COVID-19 in children by analysing the diagnostic and clinical evaluations of those patients who were referred to outpatient paediatric cardiology for abnormal screening electrocardiograms.

## Materials and methods

### Data source

Identification of subjects and patient data were obtained through a review of electronic medical records.

### Study population

This study was a retrospective chart review of children at a single institution, Children's Hospital of Philadelphia (CHOP), with a history of SARS-CoV-2 infection who were referred by their primary care providers for an outpatient cardiology consultation due to concerning findings on a screening electrocardiogram. Subjects were identified by querying the electronic medical record for patients whose primary care providers had ordered an electrocardiogram after 1 March, 2020 with an associated diagnosis containing the term "COVID," who then had an outpatient cardiology office evaluation either in person or via telemedicine that was completed prior to 25 March, 2021. The query was limited to electrocardiograms ordered by primary care providers within our large outpatient hospital network and limited to patients in whom both the ordered electrocardiogram and the cardiology office visit were completed, filtering out any cancelled or unattended visits. Patients with a diagnosis of multisystem inflammatory syndrome in children were excluded. Additionally, patients who had COVID-19 and were referred for cardiology evaluation due to cardiac symptoms alone, yet with a normal screening electrocardiogram, were similarly excluded.

### Study measures

The primary exposure for the study was the identification by a patient's primary care provider of a concerning finding on a post-COVID-19 screening electrocardiogram, which prompted an outpatient cardiology evaluation. All electrocardiograms performed at our institution are officially interpreted by a paediatric cardiologist. The outcomes of interest were the subsequent workup and testing the patients underwent as part of their cardiology evaluation as well as the final cardiology diagnosis. Each patient was evaluated by a paediatric cardiologist who determined the final diagnosis based on his/her clinical evaluation and any associated diagnostic testing that was ordered on the basis of the treating cardiologist's clinical concerns. The spectrum of cardiac testing included additional electrocardiograms, echocardiography, Holter monitoring, cardiac MRI, and exercise stress tests. No test was ordered for research purposes. Data about a range of potentially influential covariates were also collected, which included both demographic factors (i.e. gender, race, ethnicity) and clinical factors, such as the patients' past medical history, age at SARS-CoV-2 diagnosis, severity of illness, associated symptoms, and body mass index. For normally distributed data, mean and standard deviation were reported, and for non-normally distributed data, median and interquartile range were reported. Illness severity was graded according to the American Academy of Pediatrics classification in their published guidance for return to sports following COVID-19.<sup>27</sup> The final diagnosis was assigned

by the treating cardiologist and independently reviewed by the authors (M.E. and A.G.) of this manuscript. Patient clinical and procedural data were collected via the web-based application Research Electronic Data Capture (REDCap) hosted at our institution. The study protocol was approved by the institutional review board with exempt determination. Lastly, we provide an overview of the current paediatric cardiology guidelines after COVID-19, important in the context of the current study methodology, with the proposed guidelines from our academic institution.

## Results

The patient cohort consisted of 46 patients, of which 31 (67.4%) were male and 38 (86.4%) identified as Caucasian (Table 1). The mean age at the time of positive SARS-CoV-2 PCR testing was 15.6 years with a range of 12 to 18 years. Most patients (41, 89.1%) had mild symptoms, 4 (8.7%) were asymptomatic, and 1 (2.2%) had moderate symptoms, with none of the study patients experiencing severe disease or requiring hospitalisation. The most commonly reported symptoms were headache (47.6%), fever (40.5%), and fatigue (35.7%). With respect to cardiorespiratory symptoms, there were 4 (9.5%) reports of chest pain/tightness, 1 (2.4%) of shortness of breath, 1 (2.4%) of lightheadedness, and no instances of palpitations or syncope.

In the majority of patients, the date of a prior positive SARS-CoV-2 PCR was used to confirm evidence of a prior infection. There were, however, three instances of PCR results that were deemed false-negatives by the treating clinicians due to highly characteristic symptoms of COVID-19 and multiple affected family members with positive tests. There were also two patients who were presumed to have COVID-19 by their physicians without formal PCR testing, again due to highly characteristic symptoms. All five of these patients were included in the patient cohort given the high likelihood of clinical infection. The median length of time from the positive SARS-CoV-2 test to the electrocardiogram was 22 days (IQR 14–39), and the median length of time from the positive test to the date of the cardiology visit was 36 days (25–53). There was a range of electrocardiogram findings that prompted cardiology referral (Table 2), most commonly sinus bradycardia in 10 (21.7%), incomplete right bundle branch block or right ventricular conduction delay in 8 (17.4%), non-specific ST elevation in 7 (15.2%), and right atrial enlargement in 5 (13.0%).

Most patients (72%) received another electrocardiogram during the subsequent cardiology outpatient visit, and just over half of the patients (59%) received an echocardiogram, with fewer receiving additional testing (Fig 1). Table S3 provides a summary of the pertinent findings on subsequent testing, number of outpatient visits completed, and final outcomes for those patients with concerning electrocardiogram findings who were referred to cardiology. Most patients (38, 82.6%) were determined to have no cardiac disease, with the electrocardiogram findings that prompted referral either having normalised on repeat assessment, or more often, being characterised as normal variants. Pertinent final cardiac diagnoses included individual cases of gene-positive congenital long QT syndrome, persistently borderline prolonged QTc interval, cor triatriatum sinister, prominent left ventricular trabeculations not meeting criteria for left ventricular non-compaction cardiomyopathy, mild ascending aortic dilation, bicuspid aortic valve, pre-mature ventricular contractions, and pre-mature atrial contractions. There were no patients with evidence of inflammatory heart disease (i.e. myocarditis or pericarditis) or ventricular dysfunction suggestive of acute cardiac injury.

**Table 1.** Patient characteristics

<b>Gender</b>	
Male	31 (67.4)
Female	15 (32.6)
<b>Race</b>	
White	38 (86.4)
African-American	0 (0)
Other	6 (13.6)
<b>Ethnicity</b>	
Non-Hispanic/Latino	41 (93.2)
Hispanic/Latino	3 (6.8)
<b>Past medical history</b>	
None	17 (37)
Asthma	10 (21.7)
Allergic rhinitis	6 (13)
ADHD	5 (10.9)
Migraines	3 (6.5)
Anxiety	3 (6.5)
CHD	0 (0)
Other	12 (26.1)
<b>Age at diagnosis (years)</b>	15.63 ± 1.65
<b>COVID-19 severity</b>	
Asymptomatic	4 (8.7)
Mild	41 (89.1)
Moderate	1 (2.2)
Severe	0 (0)
<b>COVID-19 symptoms</b>	
<i>HEENT</i>	
Cough	10 (23.8)
Congestion/rhinorrhea	14 (33.3)
Sore throat	10 (23.8)
Headache	20 (47.6)
Loss of smell	15 (35.7)
Loss of taste	13 (31.0)
<i>GI</i>	
Nausea	1 (2.4)
Diarrhoea	2 (4.8)
<i>Cardiorespiratory</i>	
Chest pain/tightness	4 (9.5)
Shortness of breath	1 (2.4)
Lightheadedness	1 (2.4)
Palpitations	0 (0)
Syncope	0 (0)

(Continued)

**Table 1.** (Continued)

<i>Generalised</i>	
Myalgia/body aches	4 (9.5)
Chills	2 (4.8)
Fatigue	15 (35.7)
Fever	17 (40.5)
Rash	2 (4.8)
<b>Time from positive SARS-CoV-2 test to ECG (days)</b>	22 (14 – 39)
<b>Time from positive SARS-CoV-2 test to cardiology visit (days)</b>	36 (25 – 53)
<b>BMI (kg/m<sup>2</sup>)</b>	23.12 ± 4.38
<b>BMI percentile &gt;85%</b>	13 (28.3)

Data presented as count (% of total), mean ± SD, or median (interquartile range). “Other” category for past medical history includes small anomalous optic pit of the right optic nerve, depression, Crohn’s disease, patellofemoral pain syndrome, type 1 diabetes mellitus, Sever’s apophysitis, fragile X syndrome carrier, hypertriglyceridemia, jejunal atresia, minocycline-induced hepatitis and pancreatitis, mild scoliosis, and eczema. ADHD, attention-deficit hyperactivity disorder; HEENT, head, eyes, ears, nose, and throat; GI, gastrointestinal; BMI, body mass index.

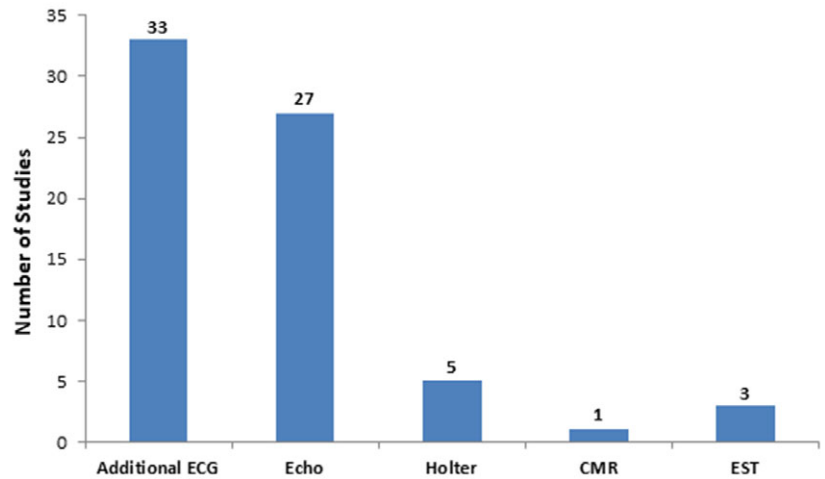
**Table 2.** Initial ECG findings prompting cardiology referral

ECG findings	n (%)
Sinus bradycardia	10 (21.7)
IRBBB/RVCD/RSR’ V1	8 (17.4)
ST elevation	7 (15.2)
Right atrial enlargement	6 (13.0)
Low right atrial rhythm	5 (10.9)
LVH	5 (10.9)
Non-specific T-wave abnormality	5 (10.9)
Rightward axis	4 (8.7)
Prolonged QTc	4 (8.7)
NSIVCD	3 (6.5)
Short PR interval	2 (4.3)
Sinus tachycardia	1 (2.2)
PVCs	1 (2.2)
Junctional escape rhythm	1 (2.2)
RBBB	1 (2.2)
RVH	1 (2.2)
Non-specific ST abnormality	1 (2.2)
Peaked T-waves	1 (2.2)

ECG = electrocardiogram; IRBBB = incomplete right bundle branch block; RVCD = right ventricular conduction delay; LVH = left ventricular hypertrophy; NSIVCD = non-specific intraventricular conduction delay; PVCs = pre-mature ventricular contractions; RBBB = right bundle branch block; RVH = right ventricular hypertrophy.

## Discussion

Current paediatric guidelines for cardiac evaluation after COVID-19 prior to returning to sports are extrapolated from adult



**Figure 1.** Additional cardiac testing performed following initial ECG.

Key: ECG, electrocardiogram; Echo, echocardiogram; CMR, cardiac MRI; EST, exercise stress test.

data and typically involve screening electrocardiograms. To the authors' knowledge, this current study is the first to review the utility of electrocardiograms in the assessment of children after COVID-19. A recent study of 170 collegiate athletes evaluated whether routine screening electrocardiograms were beneficial; six patients (3.5%) had an abnormal electrocardiogram that warranted cardiology evaluation, and only one electrocardiogram identified viral pericarditis, with no patients having myocarditis.<sup>28</sup>

In our study, the most common potentially abnormal electrocardiogram findings – sinus bradycardia, incomplete right bundle branch block, right ventricular conduction delay, non-specific ST elevation, and right atrial enlargement – have all been well recognised as normal variants in asymptomatic adolescent athletes,<sup>29</sup> which casts strong doubt that any of these findings were COVID-related. Among the patients referred to cardiology in this patient cohort, the majority (82.6%) were deemed to have no cardiac disease, and several were diagnosed with incidental findings unrelated to COVID-19. The electrocardiogram findings of pre-mature atrial contractions and pre-mature ventricular contractions that might potentially be COVID-related are also highly common incidental findings in general. Three patients were referred for a borderline QTc interval, of which two electrocardiograms were normal at the outpatient visit and one remained borderline. One additional patient had a persistently prolonged QTc leading to an incidental diagnosis of gene-positive congenital long QT syndrome. Although prolonged QTc intervals have been associated with COVID-19 in adults,<sup>30</sup> genetic long QT syndrome is unrelated to COVID-19.

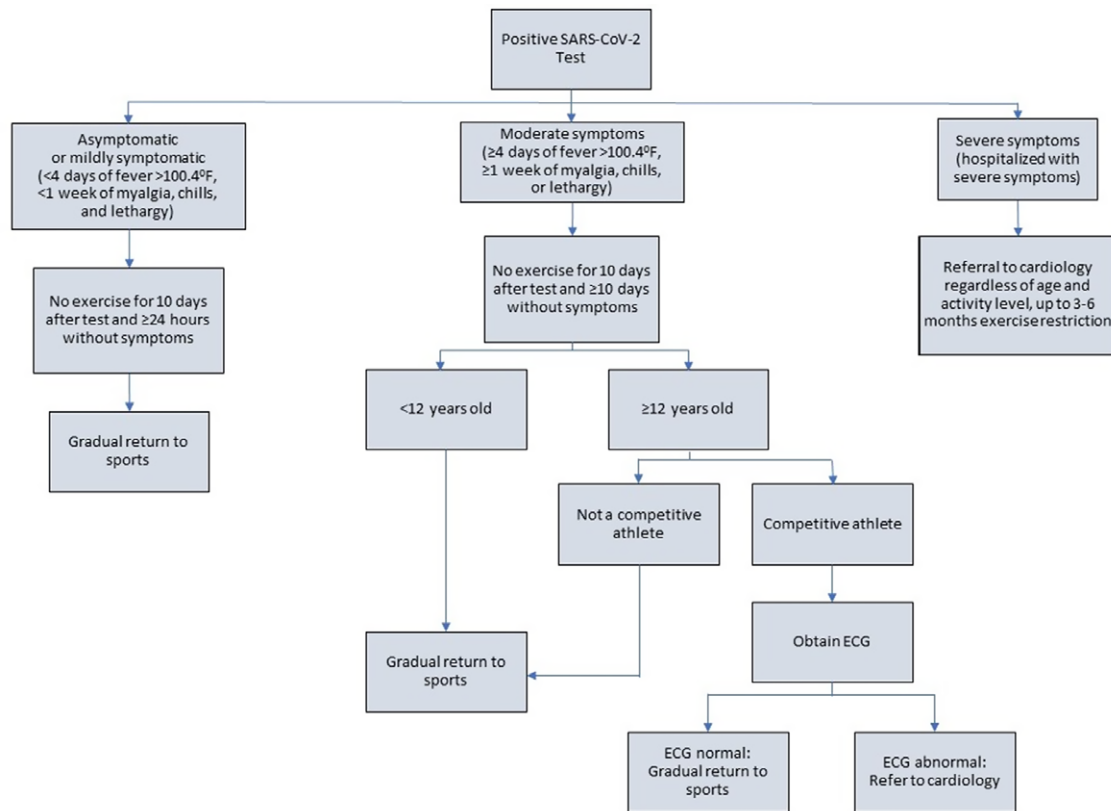
Most patients received a repeat electrocardiogram at their cardiology visit, and about half of the patients received an echocardiogram, with fewer undergoing additional testing consisting of Holter monitoring, cardiac MRI, and exercise stress test. Although these additional diagnostic modalities did reveal pertinent isolated cardiac diagnoses in several instances, there were importantly no patients with any evidence of myocarditis or ventricular dysfunction across this broad array of testing. While the presence of cardiac disease cannot be conclusively ruled out without additional testing often used in research studies, such as adjunct echocardiograms or cardiac MRIs, each patient was evaluated by a paediatric cardiologist at a large academic centre who determined the final diagnosis based on a comprehensive clinical evaluation with supplemental diagnostic testing as indicated.

The importance of identifying potential myocarditis stems from myocarditis being one of the most common causes of sudden

cardiac death in competitive adolescent athletes,<sup>31</sup> accounting for approximately 5–10% of cases. Given the potential risk of myocarditis after COVID-19, in May 2020, the American College of Cardiology Sports and Exercise Section generated recommendations to promote safe return-to-play for competitive adult athletes following COVID-19, which included 2 weeks of convalescence without exercise after symptom resolution, followed by “triad testing” consisting of a troponin, electrocardiogram, and echocardiogram.<sup>19</sup> These guidelines have been refined in light of emerging data on the rarity of myocardial involvement, especially in asymptomatic patients or those with only mild disease, to recommend cardiac diagnostic testing only in higher risk groups, such as those who had moderate or severe COVID-19 symptoms.<sup>21</sup>

A statement from the American College of Cardiology in July 2020 highlighted an important distinction in children with the introduction of an age cut-off for screening at 12 years old.<sup>26</sup> For younger children, the level of intensity of a sporting event may not be that much more strenuous than normal recreational activities and regular play. For older children and adolescents, who may be naturally pushed by their coaches and teammates beyond their normal comfort level in order to maximise their athletic performance, the risk of a sudden cardiac event may increase if they happen to have underlying myocarditis. Therefore, the authors recommended a screening electrocardiogram prior to return-to-play only in those older than 12 years who experienced moderate COVID-19 symptoms and participated in competitive sports. The American Academy of Pediatrics' guidelines have evolved over the past year and similarly recommend a screening electrocardiogram for moderately symptomatic patients ( $\geq 4$  days of fever,  $\geq 1$  week of myalgia, chills, or lethargy, or non-ICU admission), although without a specific age cut-off and regardless of activity level.<sup>27</sup>

Our institution has created additional paediatric guidelines, led by several authors of this current study, based on the latest literature, published guidelines, and local experience and consensus among divisions, including this current data. The initial guidelines were intentionally conservative and recommended a screening electrocardiogram prior to return-to-play in patients  $\geq 12$  years old who had either mild or moderate symptoms and were involved in competitive sports, along with an outpatient cardiology evaluation regardless of age or activity level for those with severe symptoms, with the possibility of up to 3–6 months of exercise restriction depending on clinical severity. These guidelines were recently updated in April 2021 to limit the



**Figure 2.** CHOP cardiology return-to-play algorithm.

recommendation for a screening electrocardiogram to those with at least moderate symptoms, eliminating many of the current study's patients who underwent electrocardiogram screening with only mild symptoms (Fig 2).<sup>32</sup>

As supported by the current data and reflected in the latest guidelines, electrocardiograms have a relatively low specificity for the detection of myocarditis after COVID-19, particularly in athletes,<sup>13</sup> and may not be beneficial as a screening tool in the absence of more significant baseline COVID-19 symptoms. Primary care providers, paediatric cardiologists, athletic trainers, schools, and others involved in the care of paediatric athletes must balance the risks of over-testing and exercise restriction with the small potential risk of myocarditis after COVID-19. To mitigate these risks, cardiologists must correctly identify well-recognised normal electrocardiogram variants in athletes, such as sinus bradycardia, incomplete right bundle branch block, right ventricular conduction delay, benign early repolarisation manifesting as diffuse non-specific ST segment elevation, and right atrial enlargement. Awareness of these normal findings is known to reduce workload and cost of screening significantly without compromising the ability to detect athletes with serious cardiac disease.<sup>29,33</sup>

### Study limitations

This study is retrospective and is subject to all of the biases inherent to this type of investigation. It was also conducted at a single centre and reflects the practices of our institution exclusively. Patients were identified through electronic medical record coding, which resulted in a small sample size and may not have produced an exhaustive list. Although our sample size was small, we posit that it is nevertheless representative of the general patient population

being referred for these indications with involvement from a primary care referral network comprised of urban, suburban, and rural populations. Importantly, there was only one patient in our study with moderate symptoms and none with severe symptoms, so our data cannot be extrapolated to this potentially higher risk population. The fewer number of patients in the study cohort with moderate symptoms likely reflects the majority of patients experiencing milder symptoms. Patients with moderate symptoms may have also been more likely to be referred to cardiology due to symptoms alone, rather than obtaining a screening electrocardiogram and referring only if the electrocardiogram was abnormal. There were notably no African-American patients in our study population; it is unclear whether this difference is due to the small sample size not adequately representing the heterogeneous population of athletes or if it is a reflection of broader disparities with respect to seeking and accessing the healthcare system. This observation is especially germane to our study, as racial and ethnic minorities have been shown to carry a higher burden of COVID-19 infection.<sup>34,35</sup> Finally, only one patient in our cohort underwent cardiac MRI, which has historically been considered the gold standard for the diagnosis of myocarditis. The true clinical significance, however, of an isolated abnormal cardiac MRI in the context of a prior COVID-19 infection and its impact on the risk of sudden cardiac death have not been well established.<sup>12</sup>

### Conclusion

In a small cohort of children with prior COVID-19, who were primarily either asymptomatic or mildly symptomatic at the time of illness, subsequent screening electrocardiograms identified

a variety of potential abnormalities prompting cardiology consultation. Many findings were well-recognised normal variants in adolescent athletes, and no patient was diagnosed with myocarditis following cardiology evaluation. The utility of screening electrocardiograms in this population prior to return-to-play remains unclear, although there is a definite risk of over-testing and likely low yield of informative data from electrocardiograms alone. Larger multi-centre studies are warranted to establish more comprehensive best practice guidelines, particularly with respect to patients with more severe disease.

**Supplementary material.** To view supplementary material for this article, please visit <https://doi.org/10.1017/S1047951121003012>

**Acknowledgements.** We are grateful for all healthcare workers providing care for COVID-19 patients during this pandemic and certainly all patients and their families.

**Financial support.** This research received no specific grant from any funding agency, commercial or not-for-profit sectors.

**Conflicts of interest.** None

## References

- Smilowitz NR, Jethani N, Chen J, et al. Myocardial injury in adults hospitalized with COVID-19. *Circulation* 2020; 142: 2393–2395.
- Ni W, Yang X, Liu J, et al. Acute myocardial injury at hospital admission is associated with all-cause mortality in COVID-19. *J Am Coll Cardiol* 2020; 76: 124–125.
- Clerkin KJ, Fried JA, Raikhelkar J, et al. COVID-19 and cardiovascular disease. *Circulation* 2020; 141: 1648–1655.
- Huang C, Wang Y, Li X, et al. Clinical features of patients infected with 2019 novel coronavirus in Wuhan, China. *Lancet* 2020; 395: 497–506.
- Driggin E, Madhavan MV, Bikdeli B, et al. Cardiovascular considerations for patients, health care workers, and health systems during the COVID-19 Pandemic. *J Am Coll Cardiol* 2020; 75: 2352–2371.
- Puntmann VO, Carerj ML, Wieters I, et al. outcomes of cardiovascular magnetic resonance imaging in patients recently recovered from coronavirus disease 2019 (COVID-19). *JAMA Cardiol* 2020; 5: 1265–1273.
- Li X, Wang H, Zhao R, et al. Elevated extracellular volume fraction and reduced global longitudinal strains in patients recovered from COVID-19 without Clinical Cardiac Findings. *Radiology* 2021; 299: E230–E240.
- Rajpal S, Tong MS, Borchers J, et al. Cardiovascular magnetic resonance findings in competitive athletes recovering from COVID-19 Infection. *JAMA Cardiol* 2021; 6: 116–118.
- Starekova J, Bluemke DA, Bradham WS, et al. Evaluation for myocarditis in competitive student athletes recovering from coronavirus disease 2019 with cardiac magnetic resonance imaging. *JAMA Cardiol*. Published online Jan 14 2021. doi: [10.1001/jamacardio.2020.7444](https://doi.org/10.1001/jamacardio.2020.7444)
- Clark DE, Parikh A, Dendy JM, et al. COVID-19 myocardial pathology evaluation in athletes with cardiac magnetic resonance (COMPETE CMR). *Circulation* 2021; 143: 609–612.
- Brito D, Meester S, Yanamala N, et al. high prevalence of pericardial involvement in college student athletes recovering from COVID-19. *JACC Cardiovasc Imaging* 2021; 14: 541–555.
- Moulson N, Petek BJ, Drezner JA, et al. SARS-CoV-2 cardiac involvement in young competitive athletes. *Circulation*. Published online Apr 17 2021. doi: [10.1161/CIRCULATIONAHA.121.054824](https://doi.org/10.1161/CIRCULATIONAHA.121.054824).
- Martinez MW, Tucker AM, Bloom OJ, et al. Prevalence of inflammatory heart disease among professional athletes with prior COVID-19 infection who received systematic return-to-play cardiac screening. *JAMA Cardiol*. Published online Mar 4 2021. doi: [10.1001/jamacardio.2021.0565](https://doi.org/10.1001/jamacardio.2021.0565)
- Valverde I, Singh Y, Sanchez-de-Toledo J, et al. Acute cardiovascular manifestations in 286 children with multisystem inflammatory syndrome associated with COVID-19 infection in Europe. *Circulation* 2021; 143: 21–32.
- Godfred-Cato S, Bryant B, Leung J, et al. COVID-19-associated multisystem inflammatory syndrome in children - United States, March-July 2020. *MMWR Morb Mortal Wkly Rep* 2020; 69: 1074–80.
- Diorio C, Henrickson SE, Vella LA, et al. Multisystem inflammatory syndrome in children and COVID-19 are distinct presentations of SARS-CoV-2. *J Clin Invest* 2020; 130: 5967–5975.
- Gruber CN, Patel RS, Trachtman R, et al. mapping systemic inflammation and antibody responses in multisystem inflammatory syndrome in children (MIS-C). *Cell* 2020; 183: 982–95 e14.
- Rostad CA, Chahroudi A, Mantus G, et al. Quantitative SARS-CoV-2 serology in children with multisystem inflammatory syndrome (MIS-C). *Pediatrics* 2020; 146: e2020018242.
- Phelan D, Kim JH, Chung EH. A game plan for the resumption of sport and exercise after coronavirus disease 2019 (COVID-19) infection. *JAMA Cardiol* 2020; 5: 1085–1086.
- Baggish A, Drezner JA, Kim J, Martinez M, Prutkin JM. Resurgence of sport in the wake of COVID-19: cardiac considerations in competitive athletes. *Br J Sports Med* 2020; 54: 1130–1131.
- Kim JH, Levine BD, Phelan D, et al. Coronavirus disease 2019 and the athletic heart: emerging perspectives on pathology, risks, and return to play. *JAMA Cardiol* 2021; 6: 219–227.
- Bhatia RT, Marwaha S, Malhotra A, et al. Exercise in the severe acute respiratory syndrome coronavirus-2 (SARS-CoV-2) era: a question and answer session with the experts endorsed by the section of sports cardiology & exercise of the European association of preventive cardiology (EAPC). *Eur J Prev Cardiol* 2020; 27: 1242–1251.
- Phelan D, Kim JH, Elliott MD, et al. Screening of potential cardiac involvement in competitive athletes recovering from COVID-19: an expert consensus statement. *JACC Cardiovasc Imaging* 2020; 13: 2635–52.
- Wilson MG, Hull JH, Rogers J, et al. Cardiorespiratory considerations for return-to-play in elite athletes after COVID-19 infection: a practical guide for sport and exercise medicine physicians. *Br J Sports Med* 2020; 54: 1157–1161.
- Drezner JA, Heinz WM, Asif IM, et al. Cardiopulmonary considerations for high school student-athletes during the COVID-19 pandemic: NFHS-AMSSM guidance statement. *Sports Health* 2020; 12: 459–461.
- Dean PN, Jackson LB, Paridon SM. Returning to Play After Coronavirus Infection: Pediatric Cardiologists' Perspective. *American College of Cardiology: Expert Analysis*. Available from: <https://www.acc.org/latest-in-cardiology/articles/2020/07/13/13/37/returning-to-play-after-coronavirus-infection>. Accessed April 21, 2021.
- COVID-19 Interim Guidance: Return to Sports and Physical Activity. *American Academy of Pediatrics*. Available from: <https://services.aap.org/en/pages/2019-novel-coronavirus-covid-19-infections/clinical-guidance/covid-19-interim-guidance-return-to-sports>. Accessed April 21, 2021.
- Erickson JL, Poterucha JT, Gende A, et al. The use of electrocardiogram screening to clear athletes for return to sport following COVID-19 infection. *Mayo Clin Proc Innov Qual Outcomes* 2021; 5: 368–376.
- Sharma S, Drezner JA, Baggish A, et al. International recommendations for electrocardiographic interpretation in athletes. *J Am Coll Cardiol* 2017; 69: 1057–1075.
- Akhtar Z, Gallagher MM, Yap YG, et al. Prolonged QT predicts prognosis in COVID-19. *Pacing Clin Electrophysiol* 2021; 44: 875–882.
- Maron BJ, Thompson PD, Ackerman MJ, et al. Recommendations and considerations related to preparticipation screening for cardiovascular abnormalities in competitive athletes: 2007 update: a scientific statement from the American Heart Association Council on Nutrition, Physical Activity, and Metabolism: endorsed by the American College of Cardiology Foundation. *Circulation* 2007; 115: 1643–1655.
- COVID-19 Return to Sports Participation for General Pediatricians and Recommendations for Cardiology Consultation after COVID-19.

- Children's Hospital of Philadelphia. Available from: <https://www.chop.edu/clinical-pathway/coronavirus-guidance-return-sports-general-pediatricians>. Accessed April 21, 2021.
33. Dhutia H, Malhotra A, Finocchiaro G, et al. Impact of the international recommendations for electrocardiographic interpretation on cardiovascular screening in young athletes. *J Am Coll Cardiol* 2017; 70: 805–807.
  34. Abedi V, Olulana O, Avula V, et al. Racial, economic, and health inequality and COVID-19 infection in the United States. *J Racial Ethn Health Disparities* 2021; 8: 732–742.
  35. Goyal MK, Simpson JN, Boyle MD, et al. Racial and/or ethnic and socioeconomic disparities of SARS-CoV-2 infection among children. *Pediatrics* 2020; 146: e2020009951.