



Case report

Mycetoma due to *Aspergillus flavus* in a diabetic patient: Case report and literature review

Hasti Kamali Sarvestani^a, Bahram Ahmadi^b, Mohsen Gerami Shoar^a, Muhammad Getso^{a,c}, Zahra Rafat^d, Shahram Mahmoudi^e, Mahmood Khansari^f, Faeze Salahshour^g, Ladan Fatahi^h, Mohammadreza Salehi^{i,1,*}, Saham Ansari^{j,1,*}

^a Department of Medical Parasitology and Mycology, School of Public Health, Tehran University of Medical Sciences, Tehran, Iran

^b Department of Medical Laboratory Sciences, School of Para-Medicine, Bushehr University of Medical Sciences, Bushehr, Iran

^c Department of Medical Microbiology and Parasitology, College of Health Sciences, Faculty of Clinical Sciences, Bayero University, Kano, Nigeria

^d Department of Medical Microbiology, School of Medicine, Guilan University of Medical Sciences, Rasht, Iran

^e Department of Parasitology and Mycology, School of Medicine, Iran University of Medical Sciences, Tehran, Iran

^f Department of Surgery, Sina Hospital, Tehran University of Medical Sciences, Tehran, Iran

^g Radiology Department, Imam Khomeini Hospital Complex, Tehran University of Medical Sciences, Tehran, Iran

^h Department of Pathology, School of Medicine, Ahvaz Jundishapur University of Medical Sciences, Ahvaz, Iran

ⁱ Department of Infectious Diseases and Tropical Medicine, Imam Khomeini Hospital Complex, Tehran University of Medical Sciences, Tehran, Iran

^j Department of Medical Parasitology and Mycology, School of Medicine, Shahid Beheshti University of Medical Sciences, Tehran, Iran

ARTICLE INFO

Keywords:

Aspergillus flavus

Mycetoma

Diabetes mellitus

Molecular identification

ABSTRACT

Diabetes mellitus patients are prone to cutaneous and subcutaneous fungal infections due to pathogenic fungi, including dermatophytes, Mucorales, *Candida*, *Aspergillus*, and *Fusarium* species. Here, we report a case of *A. flavus* mycetoma confirmed by isolation and molecular identification. The case was a 38-year-old male farmer with a seven-year history of type 2 diabetes mellitus, living in Khuzestan, southwest of Iran. The patient presented with a right foot swelling associated with a nodule and multiple discharging sinuses following trauma sustained on the foot while working barefoot on the rice farm, a year ago. The nodule appeared at the site of the trauma two months after the injury. The initial diagnosis was based on direct microscopic examination of lesions scraping using 20% potassium hydroxide and radiology. Molecular analysis confirmed the isolates to be *A. flavus*. *In vitro* susceptibility of the isolate to voriconazole, posaconazole, caspofungin, itraconazole, and amphotericin B was determined. Treatment with voriconazole (200 mg twice daily) stopped the purulent discharge, reduced the swelling, and improved the clinical condition within two months. The study emphasizes the importance of wearing footwear to prevent skin trauma as the main risk factor of patient involvement.

Introduction

Chronic subcutaneous infections such as mycetoma caused by *Aspergillus* species are considered to be rare [1]. Results of a systematic review and meta-analysis on the global burden of human mycetoma showed that among 2704 fungal isolates from patients with mycetoma, only 5 (0.0005%) were *Aspergillus* species [2]. Diabetes mellitus is a common chronic endocrine metabolic disorder associated with an increased risk of fungal infections [3,53]. Patients with diabetes have an immune system with a lower ability to respond to and deal with diseases of any type (fungal/bacterial/viral). This means they are more prone to

illnesses than the general population [11]. Diabetic patients are susceptible to cutaneous and subcutaneous fungal infections due to pathogenic fungi, including dermatophytes, Mucorales, *Candida*, *Aspergillus*, and *Fusarium* species [3–6]. In a study conducted by Kachi Udeani et al., of 120 diabetic patients analyzed, 63 (52.5%) had fungal infections [10].

Aspergillus flavus is a ubiquitous mold, found everywhere in the environment including air, water, soil, and plant materials. This fungus is one of the most frequently isolated *Aspergillus* species from human infections, especially in Asia [7,8,54]. Apart from keratitis, otitis, pulmonary and systemic infections in immunocompromised patients,

* Corresponding authors.

E-mail addresses: mr-salehi@sina.tums.ac.ir (M. Salehi), saham.ansari@sbm.ac.ir (S. Ansari).

¹ These authors have contributed equally to this work as correspondents.

A. flavus is commonly isolated from cutaneous lesions and onychomycosis in immunocompetent patients [9,55–57]. Here, we report a case of subcutaneous mycetoma infection caused by *A. flavus* in a diabetic patient from Iran.

Case

A 38-year-old male farmer from Khuzestan, southwest of Iran, with a seven-year history of type 2 diabetes mellitus was admitted at Imam Khomeini Hospital Complex, Tehran, Iran, in June 2020. The patient presented with a right foot swelling associated with a nodule and multiple discharging sinuses following trauma sustained on the foot while working on the rice farm, a year ago. The lesion started as a nodule that appeared at the site of the trauma two months after the injury. This was followed by a gradually progressing foot swelling, and after 6 months, secretory sinuses opened to the dorsal and lateral surfaces of the foot discharging purulent fluid (Fig. 1). The patient lost the ability of walking and his movement was performed only by a wheelchair. The patient stated a history of a penetrated wound due to barefoot walking on the rice farm. Also, he revealed a history of poor glycemic control despite using insulin injections, in addition to various regimens of oral hypoglycemic agents. Blood chemistry was obtained and the following results were found: fasting blood sugar (FBS): 160 mg/dL (normal range < 100 mg/dL), post-prandial blood sugar (PPBS): 230 mg/dL (normal range 110–140 mg/dL); and HbA_{1c}: 8.3% (normal <6%). It should be noted that in previous medical reports of the patient high values for FBS, PPBS, and HbA_{1c} in comparison with the normal ranges were found which were related to 6 months ago.

In the primary examination, the bone tumor was considered as one of the diagnostic possibilities, and with this diagnosis, other steps were taken for diagnosis and treatment. Also, even amputation of the patient's leg was considered as a treatment method for this reason. A technetium-99 m bone scan was suggestive of active infection of the left distal tibial head (osteomyelitis) as evidence by an increased flow (in angiographic phase) and mild hyperactivity (in delayed phase) at the left distal head of tibia bone (Fig. 2). With a suspicion of mycetoma, despite several examinations, grain was not observed in the purulent discharge. Thus, the lesions on the foot were scraped and a biopsy was taken from sinuses for further evaluation using potassium hydroxide and hematoxylin and eosin (H&E) stain, respectively. Microscopic examination of tissue sections revealed hyaline septate hyphae upon direct microscopy (Fig. 3a). Portions of the specimen were inoculated onto Sabouraud dextrose agar with and without chloramphenicol (Merck, Germany) at several locations on culture plates and incubated at 27 °C and 37 °C for two weeks. After five days of incubation, white, mold-colonies were seen at inoculation sites, which slowly became yellowish and finally light green (Fig. 3b); the fungus was identified as a member of the genus *Aspergillus* owing to macroscopic and microscopic features such as hyaline, septate hyphae with a few spherical conidia released from phialide cells (Fig. 3c). Since the initial treatment was based on

bone tumor, after the evidence mentioned above and diagnosis of mycetoma, the treatment was started with itraconazole 200 mg daily. Further, molecular identification was performed via PCR-sequencing analysis to confirm the morphological identification. Briefly, the genomic DNA was isolated from fresh colonies using a method described previously [12]. Then, PCR-Sequencing was carried out bilaterally to amplify the beta-tubulin gene using the primers Bt2 α : (5'-GGT AAC CAA ATC GGT GCT GCT TTC-3') and Bt2 β : (5'-ACC CTC AGT GTA GTG ACC CTT GGC-3') [13]. Analysis of the obtained sequences demonstrated high homology (99.81%) between the investigated amplicon and the reference strain of *A. flavus* presented in GenBank with accession number MG991316. The obtained sequence was deposited in Gene Bank with accession number MW147358. The treatment with itraconazole was continued for one month and unfortunately, no improvement was observed. Thereafter, *in vitro* susceptibility of the isolate to voriconazole, posaconazole, caspofungin, itraconazole, and amphotericin B was determined based on clinical and laboratory standards institute (CLSI) M38-A2 protocol [14]. The minimum inhibitory concentrations (MIC) of antifungal agents were 0.063, 0.125, 0.5, 0.125, and 1 mg/L for voriconazole, posaconazole, caspofungin, itraconazole, and amphotericin B, respectively. Based on these results, the treatment changed to voriconazole (200 mg twice daily) and, after two months, the purulent discharge stopped, the swelling remarkably subsided, and clinical as well as radiographic signs have significantly improved. Before the treatment with voriconazole, the patient had lost the ability to walk but after two months he can walk with the help of a cane, and the leg pain was severely reduced. Treatment was continued for two months (in total four months) and in one year follow up, the lesions were healed and the patient was in a healthy status (Fig. 4).

Discussion

Mycetoma is a subcutaneous chronic infection caused by fungi (mycetoma) or bacteria (actinomycetoma). Several fungal species are the causative agents of eumycetoma. *Madurella mycetomatis*, *Madurella grisea*, and *Scedosporium apiospermum* are the most common causative agents. Furthermore, other fungal strains including *Neotestudina rosatii*, *Scedosporium* spp., *Curvularia lunata*, *Falciformispora senegalensis*, *Biatrispora mackinnonii* (*P. mackinnonii*), *Pseudochaetosphaeronea larense* and *Aspergillus* spp. are uncommon agents of eumycetoma [15].

In the past decade, many species of fungi such as *Aspergillus*, *Candida*, *Fusarium*, *Cryptococcus*, etc. have appeared as a considerable cause of morbidity and mortality in human and animal infections worldwide [16–18,58,59]. *Aspergillus* species are opportunistic microorganisms, globally distributed in air, soil, and plants, and the majority of cases reported occurred in patients with predisposing conditions such as hematologic malignancies, steroid use, human immunodeficiency virus, diabetes mellitus, etc. [19–21,60]. In patients with immunodeficiency, a more severe disease that may eventually destroy tissues including bones may occur [22–24,61]. The case of *A. flavus* mycetoma infection

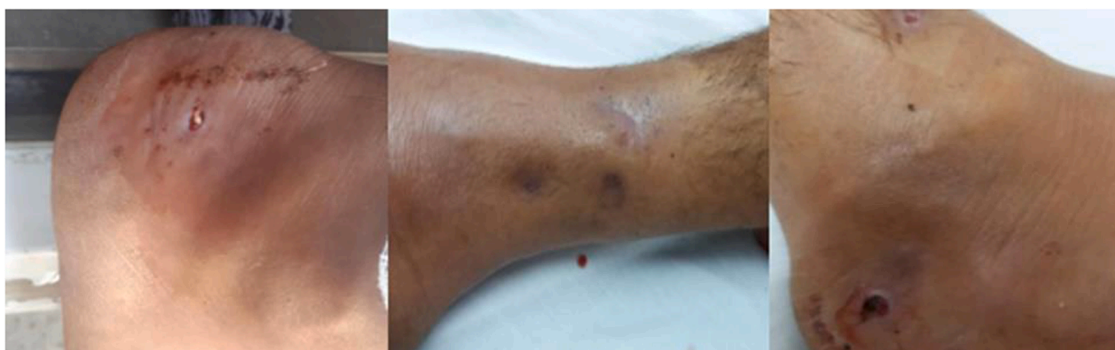

Fig. 1. Swollen and discharging lesions on the right foot of the patient at first visit.

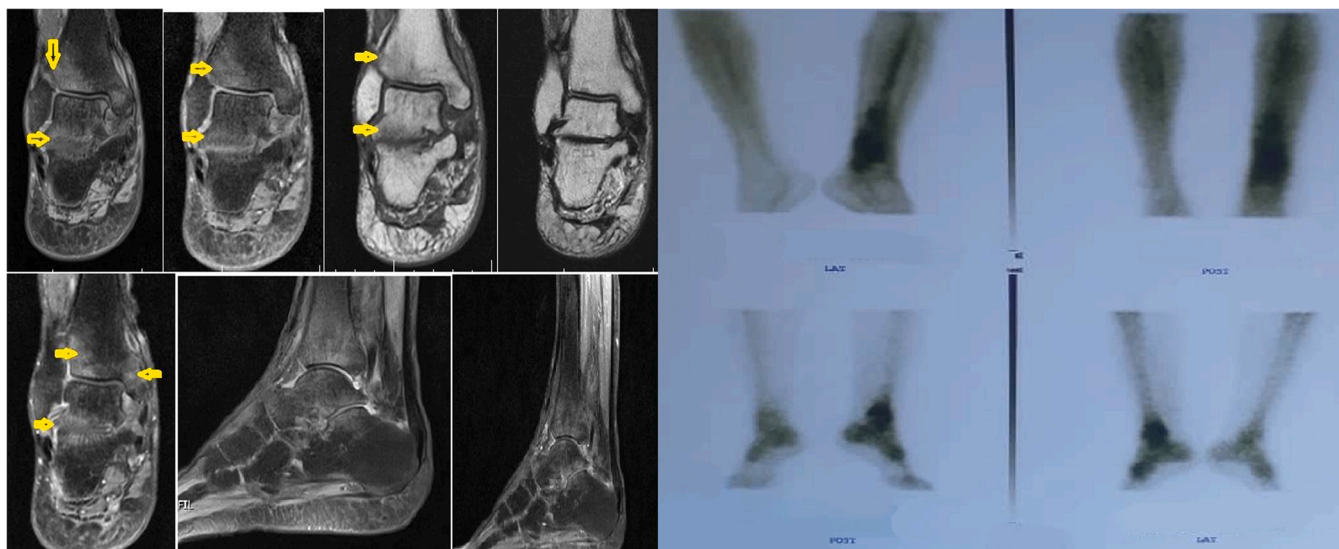


Fig. 2. Lateral sagittal contrast-enhanced T1 FS and axial TIRM T2 FS images of the ankle shows the abscess's disappearance around the calcaneus and the ankle.

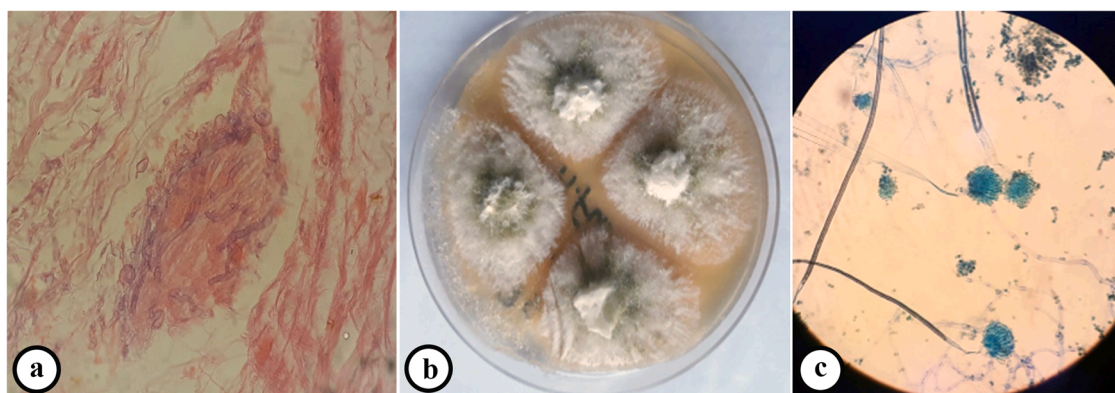


Fig. 3. Microscopic examination of biopsy sample stained by hematoxylin and eosin (H&E) demonstrating septate hyphae (a), macroscopic appearance of the isolate on sabouraud dextrose agar compatible with *Aspergillus* spp. (b), and microscopic features of the isolate (400 \times) compatible with *A. flavus* (c).

reported in this paper had type 2 diabetes mellitus as the main underlying illness. Hyperglycemia in diabetes is thought to cause dysfunction of the immune response, which fails to control the spread of invading pathogens in diabetic subjects [11].

To the best of our knowledge, to date, three cases of *A. flavus* eumycetoma have been reported in diabetic patients [25–27]. Skin involvement can be categorized as primary, following direct inoculation of *Aspergillus* at sites of skin injury or secondary, from the hematogenous spread [7]. In our presented case, the patient sustained a traumatic injury on his right foot while working barefoot on the rice farm. Studies reported that mycetoma typically presents in people who walk barefoot in dry, dusty conditions as was our case. Minor trauma causes the pathogens to enter the skin from the soil [1–3].

Nearly 50% of mycetoma are eumycetoma [29] and of over 30 species of *Aspergillus* linked to human infections, four were reported to cause eumycetoma, namely *A. nidulans*, *A. flavus*, *A. fumigatus*, and *A. terreus* [25,26,30]. The most prevalent *Aspergillus* species causing mycetoma is *A. nidulans*, while *A. flavus* is the second most common species associated with mycetoma cases [30]. Reportedly, cutaneous, mucocutaneous, and subcutaneous tissue infections are more often associated with *A. flavus* than other species of *Aspergillus* [31–33].

The clinical manifestation of cutaneous aspergillosis by *A. flavus* is described by the presence of macules, plaques, papules, nodules, ulcerations, pustules, or subcutaneous abscesses. In our case, nodule,

swelling, and secretory sinuses were the main presentation during hospitalization [7,34]. The progression of the infection is gradual but may affect deep structures such as muscles, joints, tendons, and bones [2]. Computed tomography (CT), X-rays, ultrasound, and magnetic resonance imaging (MRI) scans can only help to detect the extent of disease [29]. The bone scan in the presented case showed increased blood flow and mild hyperactivity at the left distal head of the tibia bone, suggestive of osteomyelitis.

Some occupational groups in rural areas such as agricultural workers, gardeners, poultry farmers, etc. [35–37], who work barefoot on land seem to be at a higher risk of ingress of causative agent into the subcutaneous tissue through direct implantation; this occurs commonly in young men aged between 20 and 40 years [38,39]. In the present case, a 38-year-old man who was also a farmer presented with secretory sinus and swelling on his right foot. As clinical presentations are not always pathognomonic, detection of species by laboratory examination is essential [9]. Conidia of saprophytic fungal species represent one of the most common airborne laboratory contaminants [40]. There for, directly detection of the fungus in clinical specimens remains the way to corroborate the *Aspergillus* infection in such cases [41]. In this case, samples were inoculated on multiple points on several culture media, and the same colonies of *Aspergillus* species were isolated from the inoculation points. Besides, the direct microscopic examination confirmed the presence of fungi in the sample. However, because of the

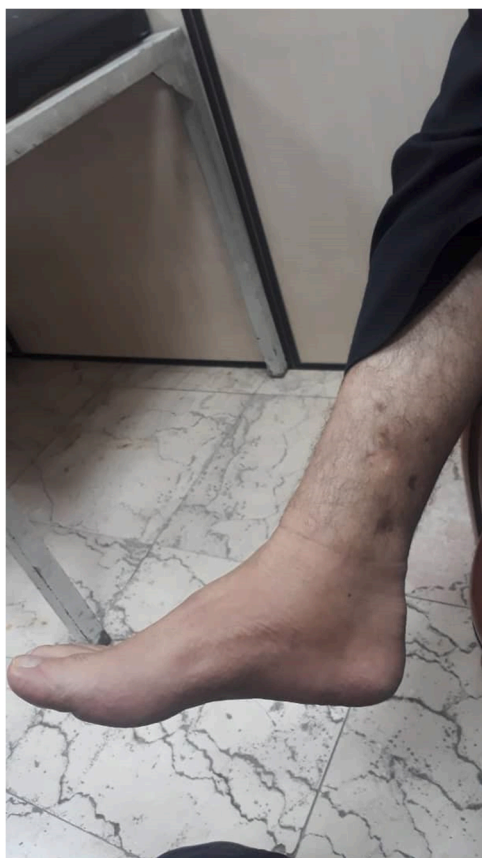

Fig. 4. Improved lesions of the patient in one year follow.

disintegration of the growth and sporulation pattern of the isolated strain, the morphological identification could not be specifically definite to the species level thus, further molecular evaluation became paramount for precise identification of the fungus [1]. DNA sequencing data unambiguously showed that the strain was *A. flavus*. Table 1 summarized all cases of mycetoma due to *A. flavus* reported across the world.

Although clinical manifestations of mycetoma caused by different etiological agents remain similar, therapy may be entirely different [42]. One core characteristic of mycetoma is poor response to treatment [43].

Table 1
All cases of mycetoma due to *A. flavus* reported across the world.

Reference	Case No	Country	Sex/Age (year)	Infection site	Occupation	Underlying condition	Diagnosis method	Treatment
Mahgoub et al. [25]/1973	1	Sudan	F/50	Ankle	NA	None	Culture, histopathological examination, immunodiffusion tests	Multiple incisions to relieve pressure + antibiotic
Padhi et al. [28]/2009	1	India	36/F	Anterior abdomen	Housewife	Diabetes Mellitus, end-stage renal disease	Culture, histopathological examination	Ketoconazole + Itraconazole + Voriconazole
Witzig et al. [27]/1996	1	USA	36/F	Back	Laundry	Diabetes Mellitus, nephrotic syndrome	KOH wet mount examination, Culture, histopathological examination	Decompressive laminectomy + Itraconazole
Hashemi et al. [51]/2001	1	Iran	25/F	Ankle	NA	NA	KOH wet mount examination, Culture, histopathological examination	NA
Ahmed et al. [1]/2015	1	Sudan	55/M	Foot	NA	Diabetes Mellitus	PCR-sequencing, immunohistochemical analysis, MALDI-TOF MS	Operation+ ketoconazole +itraconazole + voriconazole
Baishya et al. [52]/2017	1		9 months/M	Lower limb	-	NA	KOH wet mount examination, Culture, histopathological examination	Itraconazole
Present case/ 2021	1	Iran	38/Male	Foot	Farmer	Diabetes Mellitus	KOH wet mount examination, Culture, PCR-sequencing	Voriconazole

Abbreviations: M: male; F: Female; NA: not available; KOH: potassium hydroxide.

Also, the undesirable effects of antifungal drugs and multidrug-resistant microorganisms could be other contributing factors to treatment failure; susceptibility tests on isolated species may be of value in choosing suitable treatment [9,47]. The newer drugs of azole antifungal agents show a broader spectrum of activity and are at lower levels of toxicity [29]. Recently, Lionakis et al. reported that 11% of the *A. flavus* isolates in their study were resistant to itraconazole [45]. Voriconazole, posaconazole, and caspofungin have been approved for the treatment of aspergillosis [7]. Voriconazole has good *in vitro* activity against a range of *Aspergillus* species, including *A. flavus* with better clinical outcomes [46–48]. Based on the results of *in vitro* studies, *A. flavus* is more susceptible to echinocandins than *A. fumigatus* [49,50] thus, a species-specific difference in susceptibility to echinocandins may exist. Given that, our reported mycetoma case showed a remarkable response to treatment by voriconazole therapy in a way, the purulent discharge stopped and the swelling reduced.

In conclusion, our report highlights that *A. flavus* is an important mycotic pathogen that should be considered as a potential pathogenic agent in mycetoma. Although conventional mycologic techniques are powerful diagnostic tools, molecular studies substantiate identification and can lead to a better favorable clinical outcome along with appropriate treatment, especially in immunocompromised individuals such as diabetic patients.

Funding

No fund was received for this research.

Ethical approval

This study was approved by the ethics committee of Tehran University of Medical Sciences, Tehran, Iran.

Consent

Informed consent was obtained from the patient for publication of his data.

CRedit authorship contribution statement

Study design: HKS, MS, SA, ZR, MKH. Data collection: HKS, BA, MGS, MG, SM, FS, LF. Writing: BA, MG, SM. Critical review: MS, SA.

Conflict of interest

The authors declare that there are no conflicts of interest.

References

- Ahmed SA, Abbas MA, Jouvion G, et al. Seventeen years of subcutaneous infection by *Aspergillus flavus*; eumycetoma confirmed by immunohistochemistry. *Mycoses* 2015;58(12):728–34. <https://doi.org/10.1111/myc.12422>.
- van de Sande WW. Global burden of human mycetoma: a systematic review and meta-analysis. *PLoS Negl Trop Dis* 2013;7(11):e2550. <https://doi.org/10.1371/journal.pntd.0002550>.
- Mehra BK, Singh AK, Gupta D, et al. A clinicomicrobiological study on incidence of mycotic infections in diabetic foot ulcers. *Int J Sci Study* 2017;4(12):50–4.
- Raiesi O, Siavash M, Mohammadi F, et al. Frequency of cutaneous fungal infections and azole resistance of the isolates in patients with diabetes mellitus. *Adv Biomed Res* 2017;6:71–7. <https://doi.org/10.4103/2277-9175.191003>.
- Dutta P, Premkumar A, Chakrabarti A, et al. *Fusarium* faliforme infection of foot in a patient with type 2 diabetes mellitus: a case report and review of the literature. *Mycopathologia* 2013;176(3–4):225–32. <https://doi.org/10.1007/s11046-013-9646-z>.
- Dahiya D L, et al. Eumycetoma of the foot due to *Fusarium solani* in a person with diabetes mellitus: report of a case and review of literature. *Mycopathologia* 2021; 186(2):277–88. <https://doi.org/10.1007/s11046-020-00524-y>.
- Hedayati M, Pasqualotto A, Warn P, et al. *Aspergillus flavus*: human pathogen, allergen, and mycotoxin producer. *Microbiology* 2007;153(6):1677–92. <https://doi.org/10.1099/mic.0.2007/007641-0>.
- Taghizadeh-Armaki M, Hedayati MT, Ansari S, et al. Genetic diversity and in vitro antifungal susceptibility of 200 clinical and environmental *Aspergillus flavus* isolates. *Antimicrob Agents Chemother* 2017;61(5). <https://doi.org/10.1128/AAC.00004-17>.
- Pal M, Dave P, Manna AK. Emerging role of *Aspergillus flavus* in human and animal disorders. *J Mycopathol Res* 2014;52(2):211–6.
- Udeani TK, Asogwa VN, Ezenwaka U. Assessment of systemic fungal infections among diabetic patients in Enugu, Nigeria. *J Infect Dis Epidemiol*, 4(2); 2018. p. 051. (DOI: 10.23937/2474-3658/1510051).
- Rafat Z, Hashemi SJ, Ashrafi K, et al. Fungal isolates of the respiratory tract in symptomatic patients hospitalized in pulmonary units: a mycological and molecular epidemiologic study. *J Multidiscip Health* 2020;13:661–7. <https://doi.org/10.2147/JMDH.S252371>.
- Makimura K, Tamura Y, Mochizuki T, et al. Phylogenetic classification and species identification of dermatophyte strains based on DNA sequences of nuclear ribosomal internal transcribed spacer 1 regions. 920–424 *J Clin Microbiol* 1999;37(4). <https://doi.org/10.1128/JCM.37.4.920-924.1999>.
- Glass NL, Donaldson GC. Development of primer sets designed for use with the PCR to amplify conserved genes from filamentous ascomycetes. *Appl Environ Microbiol* 1995;61(4):1323–30.
- Wayne P. *Clinical and Laboratory Standards Institute (CLSI): reference method for broth dilution antifungal susceptibility testing of filamentous fungi*. Carol Stream, IL, USA: Allured Publishing Corporation; 2008.
- Emery D, Denning DW. The global distribution of actinomycetoma and eumycetoma. *PLoS Negl Trop Dis* 2020 24;14(9):e0008397. <https://doi.org/10.1371/journal.pntd.0008397>.
- Pal M. *Cryptococcus gattii*: An emerging global mycotic pathogen of humans and animals. *J Mycopathol Res* 2014;52:1–7. <https://doi.org/10.1016/j.micinf.2011.05.009>.
- Pal M, Sisay T, Asfaw Y. Growing significance of fungi in human and animal health. *J Nat Hist* 2011;7(2):82–6. <https://doi.org/10.1101/cshperspect.a019273>.
- Nucci M, Marr KA. Emerging fungal diseases. *Clin Infect Dis* 2005;41(4):521–6. <https://doi.org/10.1086/432060>.
- Bennett JW. An overview of the genus *Aspergillus*. *Aspergillus Mol Biol Genom* 2010:1–17.
- Tsai WC, Lee CH, Wu WM, et al. Cutaneous manifestations of subcutaneous and systemic fungal infections in tropical regions: a retrospective study from a referral center in southern Taiwan. *Int J Dermatol* 2017;56(6):623–9. <https://doi.org/10.1111/ijd.13497>.
- Epstein MD, Segalman KA, Mulholland JH, et al. Successful treatment of primary cutaneous *Aspergillus flavus* infection of the hand with oral itraconazole. *J Hand Surg* 1996;21(6):1106–8. [https://doi.org/10.1016/S0363-5023\(96\)80327-3](https://doi.org/10.1016/S0363-5023(96)80327-3).
- Nenoff P, Van De Sande W, Fahal A, et al. Eumycetoma and actinomycetoma—an update on causative agents, epidemiology, pathogenesis, diagnostics, and therapy. *J Eur Acad Dermatol Venereol* 2015;29(10):1873–83. <https://doi.org/10.1111/jdv.13008>.
- Lazarides M, Venkatswami S, Sankarasubramanian A, et al. The Madura foot: looking deep. *Int J Low Extrem Wounds* 2012;11(1):31–42. <https://doi.org/10.1177/1534734612438549>.
- Zein HA, Fahal AH, Mahgoub ES, et al. Predictors of cure, amputation, and follow-up dropout among patients with mycetoma seen at the Mycetoma Research Centre, University of Khartoum, Sudan. *Trans R Soc Trop Med Hyg* 2012;106(11):639–44. <https://doi.org/10.1016/j.trstmh.2012.07.003>.
- Mahgoub ES. Can *Aspergillus flavus* cause maduromycetoma? *Bull Soc Pathol Exot* 1973;66(3):390–5.
- Bassiri-Jahromi S. Mycetoma in Iran: causative agents and geographic distribution. *Indian J Dermatol* 2014;59(5):529. <https://doi.org/10.4103/0019-5154>.
- Witzig R, Greer D, Hyslop Jr N. *Aspergillus flavus* mycetoma and epidural abscess successfully treated with itraconazole. *J Med Vet Mycol* 1996;34(2):133–7. <https://doi.org/10.1080/02681219680000201>.
- Padhi S, Uppin SG, Uppin MS, et al. Mycetoma in South India: retrospective analysis of 13 cases and description of two cases caused by unusual pathogens: *Neoscytalidium dimidiatum* and *Aspergillus flavus*. *Int J Dermatol* 2010;49(11):1289–96. <https://doi.org/10.1111/j.1365-4632.2010.04610.x>.
- Reis CMS, Reis-Filho EGD. Mycetomas: an epidemiological, etiological, clinical, laboratory and therapeutic review. *Bras Dermatol* 2018;93(1):8–18. <https://doi.org/10.1590/abd1806-4841.20187075>.
- Verma R, Vasudevan B, Sahni AK, et al. First reported case of *Aspergillus nidulans* eumycetoma in a sporotrichoid distribution. *Int J Dermatol* 2015;54(1):74–7. <https://doi.org/10.1111/ijd.12571>.
- Myoken Y, Sugata T, Fujita Y, et al. Molecular epidemiology of invasive stomatitis due to *Aspergillus flavus* in patients with acute leukemia. *J Oral Pathol Med* 2003; 32(4):215–8. <https://doi.org/10.1034/j.1600-0714.2003.00080.x>.
- Heinemann S, Symoens F, Gordts B, et al. Environmental investigations and molecular typing of *Aspergillus flavus* during an outbreak of postoperative infections. *J Hosp Infect* 2004;57(2):149–55. <https://doi.org/10.1016/j.jhin.2004.02.007>.
- Pasqualotto A, Denning D. Post-operative aspergillosis. *Clin Microbiol Infect* 2006; 12(11):1060–76. <https://doi.org/10.1111/j.1469-0691.2006.01512.x>.
- Pal M. Public health concern due to emerging and re-emerging zoonoses. *Int J Livest Res* 2013;3(1):56–62. <https://doi.org/10.5455/ijlr>.
- Lichon V, Khachemoune A. Mycetoma. *Am J Clin Dermatol* 2006;7(5):315–21. <https://doi.org/10.2165/00128071-200607050-00005>.
- Mattioni S, Develoux M, Brun S, et al. Management of mycetomas in France. *Med Mal Infect* 2013;43(7):286–94. <https://doi.org/10.1016/j.medmal.2013.06.004>.
- Tomczyk S, Deribe K, Brooker SJ, et al. Association between footwear use and neglected tropical diseases: a systematic review and meta-analysis. *PLoS Negl Trop Dis* 2014;8(11):e3285. <https://doi.org/10.1371/journal.pntd.0003285>.
- Zijlstra EE, Van De Sande WW, Welsh O, et al. Mycetoma: a unique neglected tropical disease. *Lancet Infect Dis* 2016;16(1):100–12. [https://doi.org/10.1016/S1473-3099\(15\)00359-X](https://doi.org/10.1016/S1473-3099(15)00359-X).
- Bonifaz A, Tirado-Sánchez A, Calderón L, et al. Mycetoma: experience of 482 cases in a single center in Mexico. *PLoS Negl Trop Dis* 2014;8(8):e3102. <https://doi.org/10.1371/journal.pntd.0003102>.
- de Hoog GS, Guarro J, Gené J, et al. Atlas of clinical fungi: Centraalbureau voor Schimmelfcultures (CBS); 2000.
- Hanazawa R, Murayama SY, Yamaguchi H. In-situ detection of *Aspergillus fumigatus*. *J Med Microbiol* 2000;49(3):285–90. <https://doi.org/10.1099/0022-1317-49-3-285>.
- Mhmoud NA, Ahmed SA, Fahal AH, et al. Pleurostomophora ochracea, a novel agent of human eumycetoma with yellow grains. *J Clin Microbiol* 2012;50(9): 2987–94. <https://doi.org/10.1128/JCM.01470-12>.
- Castro LM, Piquero-Casals J. Clinical and mycologic findings and therapeutic outcome of 27 mycetoma patients from São Paulo, Brazil. *Int J Dermatol* 2008;47(2):160–3. <https://doi.org/10.1111/j.1365-4632.2008.03447.x>.
- Lionakis MS, Lewis RE, Torres HA, et al. Increased frequency of non-fumigatus *Aspergillus* species in amphotericin B-or triazole-pre-exposed cancer patients with positive cultures for aspergilli. *Diagn Microbiol Infect Dis* 2005;52(1):15–20. <https://doi.org/10.1016/j.diagmicrobio.2005.01.001>.
- Pfaller M, Messer S, Hollis R, et al. Antifungal activities of posaconazole, ravuconazole, and voriconazole compared to those of itraconazole and amphotericin B against 239 clinical isolates of *Aspergillus* spp. and other filamentous fungi: report from SENTRY Antimicrobial Surveillance Program, 2000. *Antimicrob Agents Chemother* 2002;46(4):1032–7. <https://doi.org/10.1128/AAC.46.4.1032-1037.2002>.
- Diekema D, Messer S, Hollis R, et al. Activities of caspofungin, itraconazole, posaconazole, ravuconazole, voriconazole, and amphotericin B against 448 recent clinical isolates of filamentous fungi. *J Clin Microbiol* 2003;41(8):3623–6. <https://doi.org/10.1128/JCM.41.8.3623-3626.2003>.
- Lass-Flörl C, Nagl M, Speth C, et al. Studies of in vitro activities of voriconazole and itraconazole against *Aspergillus* hyphae using viability staining. *Antimicrob Agents Chemother* 2001;45(1):124–8. <https://doi.org/10.1128/AAC.45.1.124-128.2001>.
- Oakley KL, Moore CB, Denning DW. In vitro activity of the echinocandin antifungal agent LY303, 366 in comparison with itraconazole and amphotericin B against *Aspergillus* spp. *Antimicrob Agents Chemother* 1998;42(10):2726–30. PMID: PMC105927, PMID: 9756785.
- Espinel-Ingroff A. Evaluation of broth microdilution testing parameters and agar diffusion Etest procedure for testing susceptibilities of *Aspergillus* spp. to caspofungin acetate (MK-0991). *J Clin Microbiol* 2003;41(1):403–9. <https://doi.org/10.1128/JCM.41.1.403-409.2003>.
- Hashmi SJ, Geramishar M. The case report of the first Mycetoma Caused by *Aspergillus flavus* in Iran. *J Inflamm Dis* 2001;5(3):64–7.
- Baishya L, Kalita M, Sharma A, et al. White grain eumycetoma due to *Aspergillus flavus* in infancy: a rare case report from Assam. *J Pure Appl Microbiol* 2017;11(2): 969–73. <https://doi.org/10.22207/JPAM.11.2.38>.
- Kamali Sarvestani Hasti, et al., Daie Ghazvini R, Hashemi SJ. Molecular Characterization of Fungal Colonization on the Provox™ Tracheoesophageal Voice Prosthesis in Post Laryngectomy Patients. *Iranian Journal of Public Health* 2022;51(1):151. <https://doi.org/10.18502/ijph.v51i1.8306>.
- Kamali Sarvestani Zahra, et al. Evaluation of fungal air contamination in selected wards of two tertiary hospitals in Tehran, Iran. *Tehran University Medical Journal TUMS Publications* 2017;75(4):299–306.

- [55] Kamali Sarvestani Zahra, et al. Species identification and in vitro antifungal susceptibility testing of *Aspergillus* section *Nigri* strains isolated from otomycosis patients. *Journal de Mycologie Medicale* 2018;28(2):279–84. <https://doi.org/10.1016/j.mycmed.2018.02.003>.
- [56] Kamali Sarvestani Hasti, et al. Investigation of etiologic agents and clinical presentations of otomycosis at a tertiary referral center in Tehran, Iran. *Iranian Journal of Public Health* 2019;48(2):331.
- [57] Ardi Pegah, et al. Study on invasive aspergillosis using galactomannan enzyme immunoassay and determining antifungal drug susceptibility among hospitalized patients with hematologic malignancies or candidates for organ transplantation. *Microbial pathogenesis* 2020;147:104382. <https://doi.org/10.1016/j.micpath.2020.104382>.
- [58] Halvae Samaneh. A Mycological and Molecular Epidemiologic Study on Onychomycosis and Determination *In Vitro* Susceptibilities of Isolated Fungal Strains to Conventional and New Antifungals. *Frontiers in Cellular and Infection Microbiology* 2021;11:693522. <https://doi.org/10.3389/fcimb.2021.693522>.
- [59] Kamali Sarvestani Hasti. Fatal invasive aspergillosis in a child with chronic granulomatous disease. *Journal of Wound Care* 2022;31(5):427–31. <https://doi.org/10.12968/jowc.2022.31.5.427>.
- [60] Kamali Sarvestani Hasti. Black aspergilli as causes of otomycosis in the era of molecular diagnostics, a mini-review. *Journal of Medical Mycology* 2022;32(2):101240. <https://doi.org/10.1016/j.mycmed.2021.101240>.
- [61] Rafat Zahra, et al. Fungal and bacterial co-infections of the respiratory tract among patients with COVID-19 hospitalized in intensive care units. *Gene Reports* 2022;27:101588. <https://doi.org/10.1016/j.genrep.2022.101588>.