



Intracerebral Hemorrhage Secondary to Scorpion Toxin in the Northwest of Argentina; A Case Report

Lucas Bordón¹, Walter Paredes¹, Romina Pacheco¹, Noé Graneros¹, Carina Tolosa¹, Gustavo Galarza², Daniel Agustín Godoy¹

¹Intensive Care Unit, Hospital San Juan Bautista, Catamarca, Argentina

²Department of Neurosurgery, Hospital San Juan Bautista, Catamarca, Argentina

*Corresponding author: Daniel Agustín Godoy

Address: Intensive Care Unit, Hospital San Juan Bautista, Avenida Moreno e Illia, 4700. Catamarca, Argentina.

Tel: +54-3834-432005 Interno 199

e-mail: dagodoytorres@yahoo.com.ar

Received: March 12, 2018

Revised: May 19, 2018

Accepted: May 19, 2018

▶ ABSTRACT

Scorpionism is the clinical picture resulting from the inoculation of scorpion venom. It is considered a major public health problem, especially in countries with low resources and tropical or subtropical climate. Poisoning can be fatal especially in the first hours due to respiratory and / or cardiovascular collapse. The compromise of the central nervous system (CNS) is infrequent but varied and complex, being able to be triggered due to multiple and different neurotoxic properties of the toxin. We report here a severe case of poisoning with cardiovascular and neurological compromise in an endemic region of Argentina. After cardiorespiratory stabilization, neurological deterioration is detected secondary to intracerebral hemorrhage that required surgery and multimodal neuromonitoring. The outcome was fatal due to multiple neurological and systemic complications. Scorpion sting poisoning is a true neurologic and neurosurgical life-threatening emergency.

Keywords: Scorpionism; Scorpion toxin; Sympathetic hyperactivity; Intracerebral hemorrhage.

Please cite this paper as:

Bordón L, Paredes W, Pacheco R, Graneros N, Tolosa C, Galarza G, Godoy DA. Intracerebral Hemorrhage Secondary to Scorpion Toxin in the Northwest of Argentina; A Case Report. *Bull Emerg Trauma*. 2018;6(3):253-256. doi: 10.29252/beat-060312.

Introduction

The scorpion sting is a life-threatening and endemic medical toxicological emergency in certain regions of third world such as Africa, India and Latin America [1, 2]. In the province of Catamarca, Argentina, seven species have been recorded, two of the genus *Tityus* (*trivittatus* and *confluens*) whose venom is potentially lethal to humans [3]. (Figure 1).

The toxin released by the arachnid mainly stimulates the autonomic nervous system (sympathetic and parasympathetic) causing a variety of clinical presentations including myocarditis, cardiogenic and / or distributive shock, acute respiratory distress syndrome (ARDS), disseminated intravascular coagulation (DIC), acute renal dysfunction and compromise of the central nervous system (CNS) between which include seizures, subarachnoid



Fig. 1. Scorpion of the genus *Tityus* (*trivittatus*).

hemorrhage and ischemic stroke [4-6]. Intracerebral hemorrhage (ICH) is a rare clinical form of scorpion poisoning, so, this reason motivates us to present this clinical case.

Case Report

A 69-year-old woman without medical history was bitten on the back of the left foot by a scorpion of the genus *Tityus trivittatus* (Figure 1) Initially, she present mild local pain and erythematous reaction and was treated with dexamethasone, diphenhydramine and then she was transferred to our hospital. At emergency admission she was tachycardic (HR 157 bpm) in sinus rhythm, tachypneic (RR 42 bpm), hypertensive (187/97 mmHg), hypothermic (35.5°C rectal temperature), sweaty, with increased respiratory secretions and excessive tearing and salivation. She showed progressive deterioration of consciousness state to coma (Glasgow 7 points: O1, V1, M5), localizing nociceptive stimuli in both arms and legs. Pupils remained equal and reactive. No meningeal irritation was detected. She was intubated, ventilated, oxygenated and resuscitated with isotonic fluids, corticosteroids and anti-scorpion polyvalent serum (4 units). Deep sedoanalgesia was started with remifentanyl and propofol (RASS – 4) [7]. EKG showed sinus tachycardia with isolated monofocal ventricular extra systoles. X-ray of the chest was normal.

Laboratory at admission was as follow: pH 7,41; paCO₂: 16,8 mmHg; paO₂:105 mmHg (FiO₂ 0.5/ PEEP 5 cmH₂O); BE-11,7; lactate 6,5 mmol/L, glycaemia 296 mg/dL, Sodium (Na⁺) 135 mEq/L, potassium (K⁺) 2,3 mEq/L; white blood cells (WBC) 22060/mm³; 81% neutrophils; hemoglobin (Hgb) 11,6 g/dL; Platelets 274000 mm³; AST 8 UI/L, ALT 20 UI/L, ALP 47 UI/L, Total Bilirubin 0,14 mg/dl; blood urea 40 mg/dl, creatinine 0,75 mg/dL, CK 99 U/L, CK-MB 29%, T-troponin 58,64 pg/ml. CRP 23 mg/L. Coagulation profile: prothrombin concentration: 74%; aPTT 25 seconds; INR: 1.08; platelets 274.000/mm³; fibrinogen levels: 278 mg/dL; D-dimer: 0.4 µg/mL; FDP <10 µg/ml. Two hours after admission, she suddenly developed arterial hypotension (76/36 mmHg), accompanied by cholinergic symptoms such as bradycardia (40 bpm),

excessive sweating and increased lacrimal, salivary and bronchial secretions. Shape, size and pupillary symmetry remained unchanged. Hypotension non response to fluids, so norepinephrine was started. Transthoracic echocardiography showed normal ventricular motility and geometry. Ejection fraction was 58%. Mild left ventricular diastolic dysfunction, without valves and pericardial involvement.

48 hs after admission, she was clinical stable, so wake up test was performed. One hour after stopped sedation and analgesia, there was no ocular opening (O1). Pupils remained intermediate, symmetrical and reactive, but marked conjugate deviation of the gaze to the left was detected, while motor response was inadequate to nociceptive stimulus (M4). GCS was 6 points. She was transferred to the radiology department where non-contrast cerebral tomography (CT) revealed an extensive cortical and subcortical left temporo parieto occipital hematoma with extension to the subarachnoid space and in caudal direction to the basal ganglia and internal capsule.

The volume of hematoma was 140 cc (ABC/2 method) [8], with midline shift >10 mm and subfalcial and left uncal herniation (Figure 2). Neurosurgery decided to evacuate urgently the lesion. After hematoma evacuation, intracranial pressure (ICP); cerebral perfusion pressure (CPP) and jugular bulb saturation (SvjO₂) on the side of the hematoma were monitored. Postoperative, intracranial hemodynamic and global oxygenation parameters remained stable for 3 days, so, after this period the monitoring systems were removed. Simultaneously, continuous EEG recording was obtained, reflecting only global slowness according to sedation level without seizure

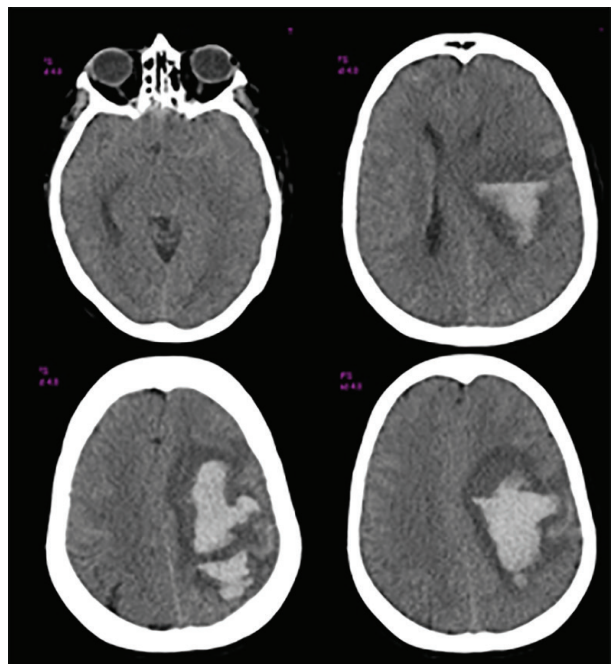


Fig. 2. Cerebral non-contrast CT scan on admission revealing an extensive cortical and subcortical left temporo parieto occipital hematoma with extension to the subarachnoid space and in caudal direction to the basal ganglia and internal capsule; midline shift >10 mm and subfalcial and left uncal herniation.

activity. Despite CT scan improvement, the patient remained in a minimal state of consciousness, with severe spastic hemiplegia of right side, and dependent on the mechanical ventilator for irregular ventilatory patterns (Figure 3). Tracheostomy was performed on day 10. Subsequently she presented multiple complications, including non-convulsive epilepticus status, paroxysmal sympathetic hyperactivity syndrome and multiple infections. She died on day 33 of admission due to sepsis and multiorgan dysfunction.

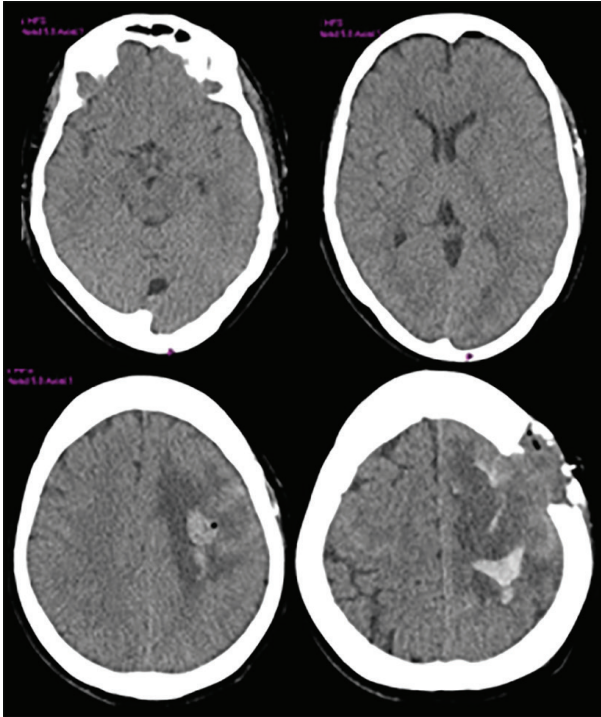


Fig. 3. Control CT Scan that showed craniotomy and residual hemorrhage with perihematomal edema. Midline shift was rectified and uncal and subfalcial herniation were resolved.

Discussion

Scorpion poisoning is a potentially lethal entity [1-15]. The clinical manifestations are varied and can be life-threatening by severe compromise of cardiac, pulmonary, renal, coagulation and CNS

function [1-15]. Cerebrovascular involvement occurs in approximately 8% of cases⁵. Previous analysis of the literature until 2013 (Pubmed) detected 23 cases; two thirds of which corresponded to ischemic stroke, while the remaining third was due to intracerebral hemorrhage⁵. Within the latter group (n=8), the half of them (n=4) were due to hemorrhages of the basal ganglia; while 2 corresponded to cortical and subcortical hematomas as the reported clinical case; 1 to intraventricular bleeding and 1 due to subarachnoid hemorrhage [5]. In Table 1, we summarized ICH reported cases.

The venom of the scorpion is produced in glands located in the distal portion of the tail. It is composed of various low molecular weights, water soluble polypeptides with enzymatic and pro-inflammatory properties, capable of activating coagulation cascade at different levels, whereby, the compound acquires toxic characteristics fundamentally for the myocardium, kidney, lung and CNS [3, 4, 14]. Its lethality lies in the fact that the poison binds to specific sites that modify ionic movements essential for the normal maintenance of cellular physiology [4, 15].

Toxins affect the ion permeability of excitable cells and four families of toxins have been described, all of that interact with voltage channels dependent, principally sodium, potassium, chloride and calcium [4, 14]. By acting on sodium (excitation) and potassium (blocking) channels, depolarization is prolonged, resulting in neuronal excitation, mainly the postsynaptic, postganglionic nerve terminals of the autonomic nervous system, causing the massive release of sympathetic (catecholamine) and parasympathetic (acetylcholine) mediators [4, 14]. Additionally, the toxin stimulates the release of cytokines, endothelin, neuropeptide Y, while activating the coagulation and complement cascade, which closes the vicious circle of neuronal damage [4, 14] (Figure 4). The mechanisms indicated, explain the reported case. Early recognition together with the therapy directed to advanced cardiorespiratory support, and neutralization of the toxin can contribute to reduce the mortality associated with scorpion poisoning.

Table 1. Summary of reported intracerebral hemorrhage (ICH) cases following scorpion sting.

Author	Year	Country	Age	Sex (M ^a /F ^b)	Scorpion	ABP ^d (mmHg)	GCS ^c	ICH ^d Localization	Surgery	Outcome
Kishore ^e	2008	India	18	M	Mesobuthus tamlus (Indian red scorpion)	128/74	15	Lobar multiple	No	Survive
Dube [10]	2011	India	-	-	-	-	-	-	-	Died
Eze [12]	2014	Nigeria	83	F	NR ^e	110/80	11	Lobar	No	Survive
Kumar [13]	2014	India	25	M	Mesobuthus tamlus (Indian red scorpion)	90/60	3	Thalamic/ Cerebellar	No	Died
Godoy	2018	Argentina	69	F	Tityus trivittatus	187/97	7	Lobar/ Putaminal	Yes	Died

^aM: male; ^bF: female; ^cGCS: Glasgow coma scale at admission; ^dICH: intracerebral hemorrhage; ^eNR: not reported; ^fABP: arterial blood pressure at hospital presentation; ^g http://www.japi.org/april_2009/article_12.html

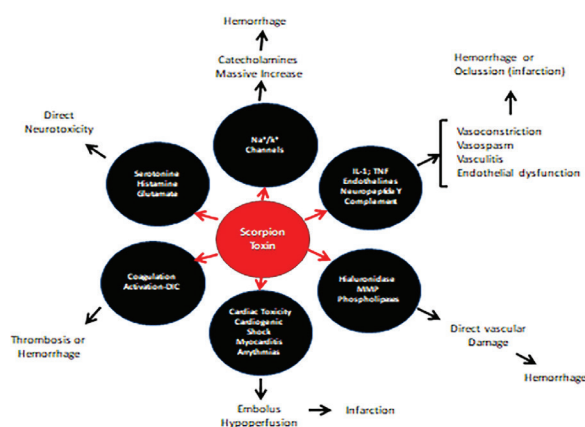


Fig. 4. Potential mechanisms of central nervous system damage of scorpion toxin.

In conclusion, in endemic regions for toxic scorpion species always consider the possibility of central nervous system compromise, due to the neurotoxic characteristics of the toxin which can induce severe forms of hemorrhagic stroke.

Declaration of patient consent: The authors certify that they have obtained all appropriate patient consent forms. In the form the patient(s) has/have given his/her/their consent for his/her/their images and other clinical information to be reported in the journal. The patients understand that their names and initials will not be published and due efforts will be made to conceal their identity, but anonymity cannot be guaranteed.

Conflicts of Interest: None declared.

References

1. Chippaux JP, Goyffon M. Epidemiology of scorpionism: a global appraisal. *Acta Trop*. 2008;**107**(2):71-9.
2. Santos MS, Silva CG, Neto BS, Grangeiro Junior CR, Lopes VH, Teixeira Junior AG, et al. Clinical and Epidemiological Aspects of Scorpionism in the World: A Systematic Review. *Wilderness Environ Med*. 2016;**27**(4):504-18.
3. Alvarez E, Lopez R; Godoy DA. Envenenamiento por animales ponzoñosos en cuidados criticos. Accidentes por arácnidos. En Green Book de Cuidados Intensivos. Editorial Distribuna. Bogota, Colombia 2014. Cap 96, pág 934-939.
4. Cupo P. Clinical update on scorpion envenoming. *Rev Soc Bras Med Trop*. 2015;**48**(6):642-9.
5. Del Brutto OH, Del Brutto VJ. Scorpion stings: focus on cerebrovascular complications of envenoming. *Int J Stroke*. 2013;**8**(4):E8.
6. Sarkar S, Bhattacharya P, Paswan A. Cerebrovascular manifestations and alteration of coagulation profile in scorpion sting: a case series. *Indian J Crit Care Med*. 2008;**12**(1):15-7.
7. Assessler C, Gosnelli M, Grap MJ. A new agitation sedation scale (RASS) for critically ill patients. Developing and testing for validity and inter-rater reliability. *Am J Resp Crit Care Med*. 2000;**161**:A506.
8. Kothari RU, Brott T, Broderick JP, Barsan WG, Sauerbeck LR, Zuccarello M, et al. The ABCs of measuring intracerebral hemorrhage volumes. *Stroke*. 1996;**27**(8):1304-5.
9. Mathur S, Jain S, Dubey T, Kulshrestha M, Mathur S, Jangid R, Ram Ch. Scorpion Sting presenting as subarachnoid hemorrhage in an elderly male. *J Indian Academy of Geriatrics*. 2010;**6**:171-2.
10. Dube S, Sharma VK, Dubey TN, Gouda NB, Shrivastava V. Fatal intracerebral haemorrhage following scorpion sting. *J Indian Med Assoc*. 2011;**109**(3):194-5.
11. Rai M, Shukla RC, Varma DN, Bajpai HS, Gupta SK. Intracerebral hemorrhage following scorpion bite. *Neurology*. 1990;**40**(11):1801.
12. Kumar TP, Reddy VU, Narayan PD, Agrawal A. Symmetrical thalamic and cerebellar hemorrhages following scorpion envenomation. *International Journal of Students' Research*. 2014;**4**(1):15.
13. Eze CO, Onwuekwe I, Ekenze O. Stroke as a rare consequence of scorpion sting and scorpion ingestion: A case report from South East Nigeria. *Annals of Tropical Medicine and Public Health*. 2014;**7**(4):202.
14. de Roodt AR. Veneno de escorpiones (alacranes) y envenenamiento. *Acta bioquímica clínica latinoamericana*. 2015;**49**(1):55-71.
15. Isbister GK, Bawaskar HS. Scorpion envenomation. *N Engl J Med*. 2014;**371**(5):457-63.

Open Access License

All articles published by Bulletin of Emergency And Trauma are fully open access: immediately freely available to read, download and share. Bulletin of Emergency And Trauma articles are published under a Creative Commons license. Mandated authors will be offered CC-BY; all other authors will choose between CC-BY, CC-BY-NC and CC-BY-NC-ND.