



Original Article

Evaluation of the results and complications of the Latarjet procedure for recurrent anterior dislocation of the shoulder



Luciana Andrade da Silva^{a,*}, Álvaro Gonçalves da Costa Lima^b, Raul Meyer Kautsky^b, Pedro Doneux Santos^a, Guilherme do Val Sella^a, Sergio Luiz Checchia^{a,c}

^a Shoulder and Elbow Group, Santa Casa de São Paulo, São Paulo, SP, Brazil

^b Department of Orthopedics and Traumatology, Santa Casa de São Paulo, São Paulo, SP, Brazil

^c Department of Orthopedics and Traumatology, Faculdade de Ciências Médicas da Santa Casa de São Paulo (FCMSCSP), São Paulo, SP, Brazil

ARTICLE INFO

Article history:

Received 7 August 2014

Accepted 22 September 2014

Available online 11 November 2015

Keywords:

Joint instability

Shoulder dislocation

Shoulder

ABSTRACT

Objective: Evaluate the results and complications of Latarjet procedure in patients with anterior recurrent dislocation of the shoulder.

Methods: Fifty-one patients (52 shoulders) with anterior recurrent dislocation, surgically treated by Latarjet procedure, were analyzed retrospectively. The average follow-up time was 22 months, range 12–66 months; The age range was 15–59 years with a mean of 31; regarding sex, 42 (82.4%) patients were male and nine (17.6%) were female. The dominant side was affected in 29 (55.8%) shoulders. Regarding the etiology, 48 (92.3%) reported trauma and four (7.6%) had the first episode after a convulsion.

Results: The average elevation, lateral rotation and medial rotation of the operated shoulder were, respectively, 146° (60–80°), 59° (0–85°) and T8 (T5 gluteus), with statistical significance for decreased range of motion in all planes, compared with the other side. The scores of Rowe and UCLA were 90.6 and 31.4, respectively, in the postoperative period. Eleven shoulders (21.2%) had poor results: signs of instability (13.4%), non-union (11.5%) and early loosening of the synthesis material (1.9%). There was a correlation between poor results and convulsive patients ($p = 0.026$).

Conclusion: We conclude that the Latarjet procedure for correction of anterior recurrent dislocation leads to good and excellent results in 82.7% of cases. Complications are related to errors in technique.

© 2014 Sociedade Brasileira de Ortopedia e Traumatologia. Published by Elsevier Editora Ltda. All rights reserved.

* Corresponding author.

E-mails: lucalu@terra.com.br, ombro@ombro.med.br (L.A. da Silva).

<http://dx.doi.org/10.1016/j.rboe.2015.09.009>

2255-4971/© 2014 Sociedade Brasileira de Ortopedia e Traumatologia. Published by Elsevier Editora Ltda. All rights reserved.

Avaliação dos resultados e das complicações em pacientes com instabilidade anterior de ombro tratados pela técnica de Latarjet

R E S U M O

Palavras-chave:

Instabilidade articular/cirurgia

Luxação glenoumeral

Ombro

Objetivo: Avaliar os resultados e as complicações da cirurgia de Latarjet em pacientes acometidos pela instabilidade recorrente anterior de ombro.

Métodos: Foram analisados, retrospectivamente, 51 pacientes (52 ombros) com diagnóstico de luxação recidivante anterior, operados pela técnica de Latarjet. O tempo médio de seguimento foi de 22 meses, variação de 12 a 66 meses; a faixa etária variou de 15 a 59 anos, com média de 31; em relação ao sexo, 42 (82,4%) pacientes eram do masculino e nove (17,6%) do feminino. O lado dominante foi acometido em 29 (55,8%) ombros. Quanto à etiologia, 48 (92,3%) referiram trauma e quatro (7,6%) tiveram o primeiro episódio após um quadro de convulsão.

Resultados: As médias de elevação, rotação lateral e rotação medial ativas do membro operado foram, respectivamente, de 146° (60° a 180°), 59° (0° a 85°) e T8 (T5 a glúteo), houve significância estatística quanto à diminuição da amplitude de movimento em todos os planos, quando comparado com o lado contralateral (não operado). As médias de pontuação de Rowe e UCLA foram de 90,6 e 31,4, respectivamente, no período pós-operatório. Onze ombros (21,2%) apresentaram maus resultados: sinais de instabilidade (13,4%), pseudoartrose (11,5%) e soltura precoce do material de síntese (1,9%). Houve correlação entre maus resultados e pacientes convulsivos ($p = 0,026$).

Conclusão: O procedimento de Latarjet para correção da luxação anterior recidivante leva a bons e excelentes resultados em 82,7% dos casos.

© 2014 Sociedade Brasileira de Ortopedia e Traumatologia. Publicado por Elsevier Editora Ltda. Todos os direitos reservados.

Introduction

Different surgical procedures have been described for treating recurrent anterior shoulder dislocation.¹ The capsulolabral repair described by Bankart² and modified by Rowe et al.³ is one of the main techniques used to treat this condition and it can be done arthroscopically or as an open procedure, with good results from most patients.¹ In cases in which the dislocation occurs in more than one direction and/or there is an increase in capsule volume, capsuloplasty can be chosen. This technique was described by Neer and Foster⁴ and was subsequently revised by Bigliani.⁵

However, soft-tissue repair alone does not seem to be an effective procedure in all cases.⁶ Attempts to define some parameters that could be used to guide the type of procedure to be performed are now being made.⁶ From studying cadavers, Itoi et al.⁷ concluded that bone defects of the glenoid cavity greater than 21% provide the conditions for the force needed for shoulder dislocation to be considerably lower. Application of a bone graft to such defects increases the stability of the joint.⁷

Balg and Boileau⁶ created an instability score (ISIS) for determining the preoperative risk factors among patients with recurrent instability, with the aim of assisting surgeons in indicating arthroscopic or open surgery. According to these authors, for patients with high risk of recurrent dislocation, transposition of the coracoid process to the anteroinferior border of the glenoid cavity is an effective option.⁶ This procedure was first described by Latarjet⁸ in 1954 and by Helfet⁹ (the author who named the technique the Bristow procedure) in

1958. In 1982, Patte and Debeyre¹⁰ added further stability to the original technique through using the coracoacromial ligament, which overlaps the joint capsule after fixation of the bone graft.

The first Brazilian authors to publish their experience of treating recurrent anterior shoulder dislocation using the technique of bone grafting from the coracoid in association with ligament stabilization were Godinho and Monteiro,¹¹ in 1993. These authors did not have any cases of recurrence of the dislocation, and 90% of the patients returned to their previous sports activities. Bessière et al.¹² conducted a retrospective study on 186 patients who presented recurrent post-traumatic anterior instability. They compared the patients treated by means of Bankart's arthroscopic repair of the injury versus Latarjet's operation,⁸ with a mean follow-up of six years, and concluded that the second group presented better Rowe scores³ and lower rates of recurrent instability.¹²

The objective of this study was to evaluate the results from patients with recurrent anterior shoulder dislocation who were treated using the Latarjet technique,⁸ highlight their complications and attempt to correlate these with their possible causes.

Sample and methods

Between July 2007 and December 2012, 69 patients with diagnoses of recurrent anterior shoulder dislocation were treated surgically using the Latarjet technique,⁸ by the Shoulder

Surgery Group of our service. Out of this total, 51 patients (52 shoulders) were analyzed retrospectively.

The inclusion criteria that we used were that the patients needed to have never undergone any surgery previously and to have been followed up postoperatively for a minimum of one year. Patients who had undergone some previous shoulder surgery were excluded, along with those whose outpatient follow-up had lasted for less than one year after the operation.

The mean length of follow-up was 22 months, with a range from 12 to 66. With regard to sex, 42 (82.4%) were male and nine (17.6%) were female. The age range was from 15 to 59 years, with a mean of 31. The dominant side was affected in 29 cases (55.8%). Regarding etiology, 48 (92.3%) reported that there had been some type of trauma and in four cases, the first episode had occurred after a condition of convulsion (7.6%).

In relation to the surgical indication, 43 shoulders (82.7%) underwent the procedure because of the presence of bone erosion, five (9.6%) because these patients played contact sports and four (7.7%) because these patients suffered from convulsions. In this last group, three cases (5.8%) also presented bone erosion. Among the 51 patients evaluated, 38 (74.4%) practiced physical activities. Of these, eight (15.6%) were professional sport players. The mean length of time between the initial dislocation and the surgery was six years, with a range from four months to 40 years. The number of episodes of dislocation before the surgery ranged from two to more than 100, with a median of 15.

All the patients underwent simple radiography of the shoulder and the radiographic views used in the preoperative evaluation were: frontal, corrected to neutral rotation; apical-oblique¹³; axillary lateral; and West Point.¹⁴ Axial computed tomography and/or magnetic resonance imaging were also performed.

In relation to the surgical technique used, all the patients underwent their operations in the deckchair position and the access route used was above the coracoid process, extending to the deltopectoral space by around 5 cm. The coracoid process was osteotomized 1.5–2 cm from its tip, at the origin of the conjoined tendon. A graft was prepared such that its convexity was planed down and bloodied for adaptation to the glenoid border. This was then transferred by means of the subscapular muscle (opened longitudinally between its upper two thirds and the lower third) and the joint capsule (opened vertically). In this manner, the graft was supported along its major axis, at the anteroinferior border of the glenoid, which was previously prepared through resection of the labrum (or what was left of it) and decortication of the glenoid border and neck. The graft was fixed using two screws that were parallel to the

joint surface and anchored in the posterior cortical bone of the scapular neck, thus promoting compression between the fragments.¹⁵ The coracoacromial ligament was preserved at the coracoid and was sutured at the medial band of the joint capsule.¹⁰ A suction drain was left in place for 48 h after the operation. Regarding the type of implant used, the graft was fixed using small-fragment screws.

After the surgery, the patients were immobilized by means of a cushioned sling in order to keep the limb in a position of neutral rotation for six weeks or until bone consolidation had been verified. During this period, the patients were instructed to perform passive lateral rotation exercises, which began on the first postoperative day.

The patients underwent postoperative evaluations by means of simple radiographs produced one, three and six weeks after the operation. If there were any doubts regarding the consolidation or the position of the graft, computed tomography was performed.

Shoulder range of motion was measured bilaterally in accordance with the criteria of the American Academy of Orthopedic Surgeons (AAOS).¹⁶ The functional results were evaluated clinically by means of Rowe's criteria³ and the modified version of the scoring system proposed by the University of California at Los Angeles (UCLA).¹⁷ The patients were asked about their return to sports, in the case of practitioners.

The data were organized and descriptive analysis was performed by means of constructing frequency tables and graphs and calculating central trend and variability measurements.

In the statistical analysis, we used 95% confidence intervals and the significance level of 0.05 ($p < 0.05$). When necessary, we used Student's *t* test for paired data (to test the differences in measurements between the operated and contralateral sides) and the nonparametric Mann-Whitney test (to compare the mean results between the groups with good and poor results). To test whether there was independence between pairs of variables, Fisher's exact test was used.

This study was approved by the hospital's ethics committee under CAAE number 22949213.3.0000.5479.

Results

In relation to shoulder mobility, we observed that the mean active elevation, lateral rotation and medial rotation of the operated limb were less than those of the contralateral limb (which had not been operated) and that the reduction in range of motion was statistically significant in all planes. These values can be seen in Table 1.

Table 1 – Range of motion of the operated and contralateral shoulders.

Movement	Mean		Standard deviation		Minimum		Maximum		Significance (<i>p</i>)
	A	B	A	B	A	B	A	B	
Elevation	146	151	18.91	11.95	60	110	180	180	0.019
Medial rotation	8	7	2.41	1.83	Gluteus	T12	T5	T5	0.001
Lateral rotation	59	63	18.49	10.49	0	30	85	85	0.048

Source: the hospital's medical and statistical files.

A, operated shoulder; B, contralateral shoulder; *p*, corresponds to the descriptive level for the differences in the paired measurements.

Table 2 – Results from Rowe and UCLA scores.

	Rowe	n	UCLA	n	Result
Excellent	78.8%	41	75%	39	Satisfactory
Good	3.8%	2	7.7%	4	
Fair	11.5%	6	7.7%	4	Unsatisfactory
Poor	5.8%	3	9.6%	5	

Source: the hospital's medical and statistical files.
n, absolute number of shoulders.

Table 3 – Detailing of the findings from patients with poor results.

Finding from physical or radiographic examination	Percentage (%)	n
Limitation on lateral rotation	7.69	4
Pain	17.31	9
Positive apprehension test	11.54	6
Pseudarthrosis	11.54	6
Recurrence	3.85	2
Total	21.15	11

Source: the hospital's medical and statistical files.
n, absolute number of shoulders that presented complications.

The mean postoperative scores from the Rowe³ and UCLA¹⁷ functional evaluations were 90.6 (range: 30–100) and 31.4 (range: 8–35), respectively. Both through the UCLA score¹⁷ and through the Rowe score,³ nine shoulders (17.3%) were classified as presenting unsatisfactory results (fair and poor) and 43 (82.7%) as satisfactory (good and excellent). However, in comparing the four possible outcomes (excellent, good, fair and poor) using these two methods, there was variation in the number of shoulders classified in the excellent and good subgroups, and likewise in the fair and poor subgroups (Table 2).

Among the patients presenting convulsions, there was a statistically significant correlation between convulsion and poor results/complications ($p = 0.026$).

We did not find any statistically significant correlation for the variance in the time that elapsed between the first episode

of dislocation and the surgery in relation to poor results ($p = 0.729$), or for the number of episodes of dislocation in relation to poor results ($p = 0.663$). The patients who were sports participants whose results were satisfactory and unsatisfactory did not show any correlation with the patients who did not practice sports ($p = 0.180$). Sex, age and dominance did not show any correlation with the outcomes from the cases.

Among the 38 patients who practiced sports (73.1% of the total), six did not return to their previous sports practice, among whom one was a professional sports player.

Eleven shoulders (21.2%) presented poor results. Among these, seven (13.4%) remained unstable: two (3.8%) had new episodes of dislocation and five (9.6%) presented positive apprehension tests, among whom three evolved with associated pseudarthrosis of the coracoid process. There were four cases of complications (7.7%): three presenting pseudarthrosis without instability (5.8%) and one with early loosening of the synthesis material (1.9%), 15 days after the operation (Tables 3 and 4).

Discussion

In our sample, limitation of the range of motion occurred in all: 5° of elevation, 4° of lateral rotation and one vertebra of medial rotation. Despite presenting statistical significance, the decrease in mobility was very slight. Ikemoto et al.¹⁸ evaluated 26 patients with a mean length of follow-up of 38 months and also observed that there was limitation of mobility in the operated shoulder in all planes, but more markedly so in

Table 4 – Correlation between the clinical and radiographic findings from the patients with poor results.

Case	Clinical findings				Radiographic findings		
	Pain	Limitation on LR	Apprehension +	Recurrence	Pseudarthrosis	Graft position	Screw
1	X				X	C	S+L
2	X	X			X	M	S
3	X		X			C	C
4	X	X	X		X	I	C
5	X				X	M	S+L
6	X		X		X	M	S+L
7		X				M+I	C
8	X	X	X		X	I	S+B
9	X		X	X		C	C
10	X		X			C	C
11				X		C	B

Source: the hospital's medical and statistical files.

Case, patient who presented complication; LR, lateral rotation; Apprehension +, positive apprehension test; M, medialized graft; I, graft in excessively inferior position; C, correct positioning; S, short screw (reaching only one cortical layer); B, screw breakage; L, loosening of synthesis.

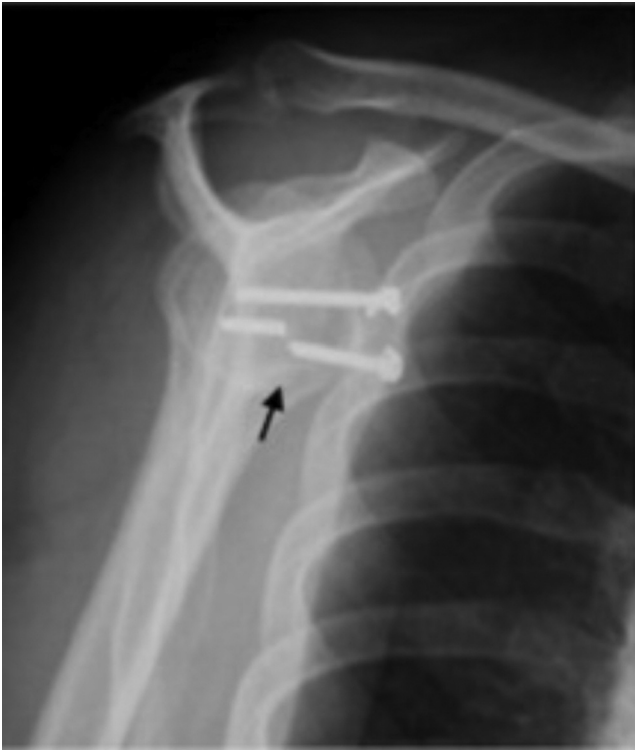

Fig. 1 – Radiograph of a shoulder in lateral scapular view showing breakage of synthesis material (arrow).

relation to movements of lateral rotation. Godinho and Monteiro¹¹ had a larger number of patients with loss of medial rotation (13 out of 40), while lateral rotation was limited in only 11 patients, with a mean of 14.1°. On the other hand, Hovelius et al.¹⁹ observed in a prospective study on 112 patients that there was a loss of lateral rotation over a follow-up period of two to five years, with losses of 19° in adduction and 21° in abduction.¹⁹

Schroder et al.²⁰ reported good and excellent functional and stability results from their retrospective study on the Latarjet procedure⁸ based on the Rowe score.³ The mean was 81.8 among 52 patients, among whom 36 were considered to be excellent, five fair and 11 poor,²⁰ i.e. 30.7% of the results were unsatisfactory. In our study, we found that nine patients (17.3%) had results that were considered to be unsatisfactory (fair/poor), based on the Rowe score³ and UCLA score¹⁷ (Table 2).

We followed up four patients with epilepsy (7.7% of the total number of shoulders) in our study and observed that there was a statistically significant correlation between presence of convulsions and poor results/complications ($p=0.026$). The only patient whose convulsive condition was well controlled had an excellent result. There was one case of surgical revision, nine months after the operation, in a patient who suffered fracturing of the graft and breakage of the synthesis material (Fig. 1), after a new convulsive episode. These data are in line with what we found in the literature. Raiss et al.²¹ published a study in which 14 shoulders in 12 patients with epilepsy who had undergone the Latarjet procedure⁸ were retrospectively evaluated. They observed that dislocation recurred in 43% of

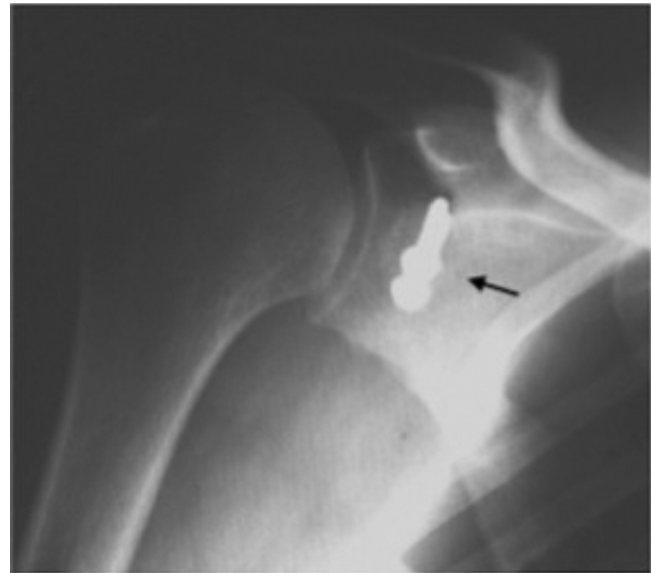


Fig. 2 – Anteroposterior radiograph of a right shoulder showing medialized graft (arrow).

the cases, as did Checchia et al.,²² who found a recurrence rate of 42% when studying techniques for treating recurrent anterior shoulder dislocation in epileptic patients. The latter authors attributed the poor result to poor clinical control over the convulsive crises. Raiss et al.²¹ considered that only patients presenting good control from a neurological point of view who suffer recurrent dislocation during day-to-day activities should undergo the Latarjet procedure,⁸ and we agree with this view.

We found a recurrence rate for episodes of dislocation of 3.8% (two cases). One of these cases involved a patient with poorly controlled epilepsy who had nine episodes of dislocation and the other was a patient who suffered a car accident (rollover) in the fourth month after the surgery and evolved with a condition of instability after the incident.

In a systematic review on 1904 shoulders, Griesser et al.²³ found a recurrence rate of 2.9%.²³ Lädermann et al.²⁴ reported a recurrent dislocation rate of 1.7% in their sample of 117 shoulders and found that 3.4% persisted with a positive apprehension test.²⁴ In our study, five patients (9.6%) evolved with a positive apprehension test. In one of these cases, there were no objective findings that would explain this result and we believe that this was a case motivated toward secondary gains (time off work or financial benefits). Another case involved a patient with severe psychiatric problems and difficult subjective interpretation of the clinical examination. In the other three patients, the positive apprehension tests were associated with pseudarthrosis, and the results were unsatisfactory. We attributed these failures to poor graft positioning (Figs. 2–4), since the grafts were below their ideal position. In two patients and in the third case, the graft was medialized and the screws were not reaching both cortical layers of the glenoid bone. These patients underwent surgical revision.

Hovelius et al.²⁵ reevaluated 319 shoulders and found a recurrence rate of 5% and a positive correlation between recurrence and medialized graft positioning.

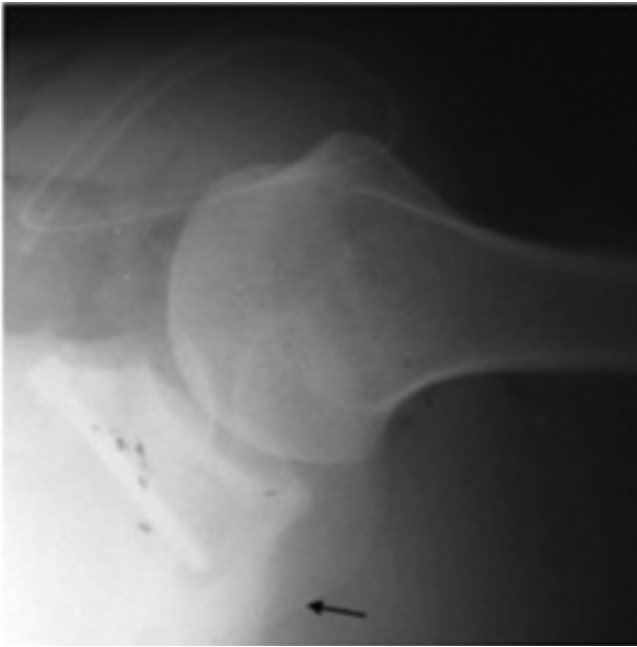


Fig. 3 – Radiograph of a shoulder in axillary view during the immediate postoperative period, showing screws that did not reach the second cortical layer (arrow).

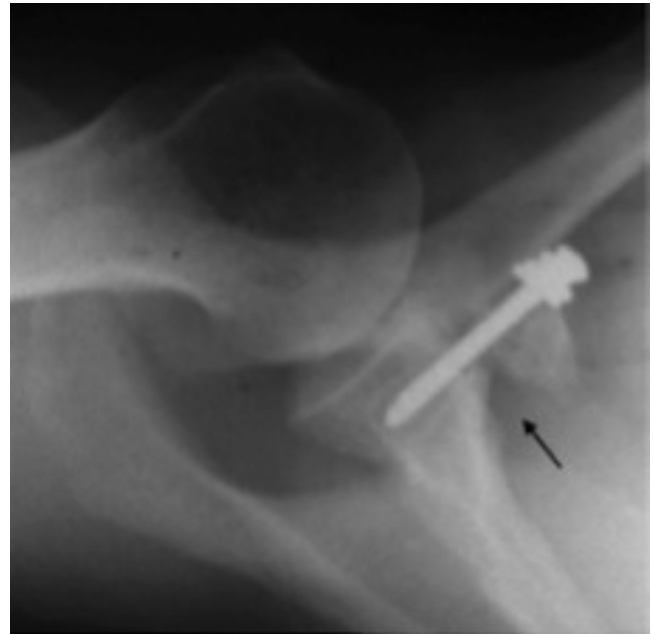


Fig. 4 – Radiograph of a shoulder in axillary view showing pseudarthrosis of the graft (arrow).

The total pseudarthrosis rate observed among the cases evaluated in our study was 11.5%, corresponding to six shoulders. Three of these cases also presented positive apprehension test and were discussed earlier. Among the other three patients with pseudarthrosis (5.8%), there was one case in which although non-consolidation of the graft was evident, this did not influence the patient's daily activities. This patient refused to undergo the revision procedure. His results from the UCLA¹⁷ and Rowe³ functional evaluations were 24 and 80, respectively. The other two cases were due to technical failure: one evolved with UCLA¹⁷ and Rowe³ of 12 and 65, respectively, with major limitations on daily activities. On reviewing

this patient's radiographic examinations, we observed medialization of the graft and screws only passing through one of the cortical bone layers. One of these screws broke and the other became loose 28 months after the operation, and this patient underwent surgical revision. The other patient, who did not present any episodes of recurrent shoulder dislocation, was not reviewed because he died due to external causes.

In a retrospective study, Walch and Boileau¹⁵ found a pseudarthrosis rate of 2.4% and correlated the cause of this complication to the positioning of the screws, which only passed through one cortical layer. However, they did not find that this complication influenced the final evaluation. In this same study, in which the technique was described, the

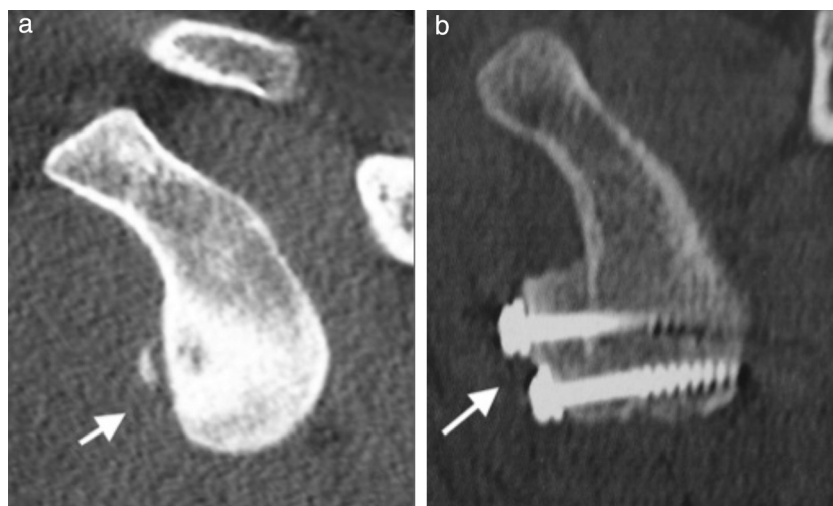


Fig. 5 – Sagittal slice from computed tomography on a shoulder showing (a) bone erosion at the anteroinferior border of the glenoid (arrow) and (b) correction of the lesion using a coracoid graft, fixed in the ideal position (arrow).

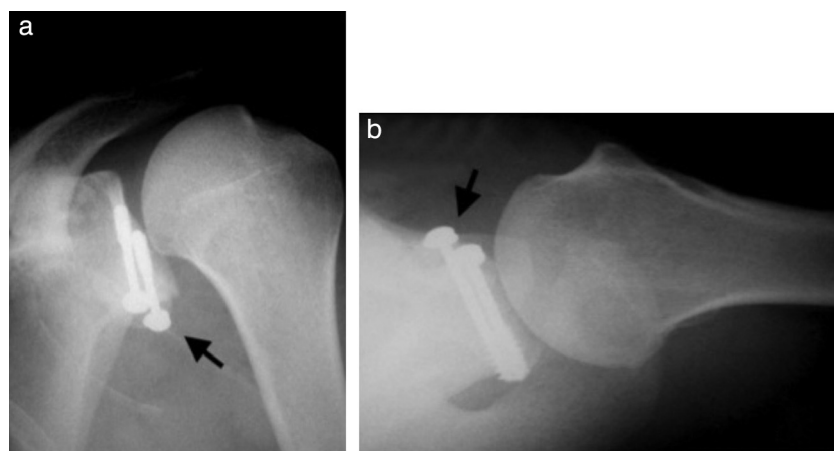


Fig. 6 – Radiographs of a left shoulder in (a) anteroposterior view and (b) axillary view, showing good positioning of the graft (arrows).

authors recommended that the screws should pass through both cortical layers and that the graft should be positioned very cautiously, with the limb rotated internally so as to accept slightly medial positioning of a maximum of a few millimeters and avoid the lateral border of the glenoid. These authors stated that drilling should be performed in a plane parallel to the joint surface.¹⁵ We agree that this is the best position for the graft and screws (Figs. 5 and 6) and highlight that the glenoid cavity presents anteversion of around 30–40° and that the graft should not advance into the joint but, rather, should form a continuation of the joint surface.

One of the cases evolved with early loosening of the synthesis material during the first two weeks after the operation, and this patient underwent a new surgical procedure in order to fix the coracoid again. The hypothesis of an infectious process was ruled out. From analysis on the radiographic images, we concluded that there had been a technical failure, since the graft had remained in a low and medialized position, which was the probable cause of this loosening.

Griesser et al.²³ reported a complication rate of 30%, caused by recurrences, neurovascular lesions, hematomas, infections, pseudarthrosis of the graft and movement limitations.²³ We did not have any cases of neurovascular lesion, hematoma or infection.

This study has some limitations such as its retrospective nature and its minimum follow-up of only one year. Alterations like arthrosis (which has been described as one of the complications of the Latarjet procedure)⁵ need longer postoperative periods for them to become visible on radiographs. In order to reach a conclusion of greater precision regarding the evolution of epileptic patients, we believe that a larger sample would be needed, despite the very suggestive results obtained regarding the relationship between convulsions and poor results. On the other hand, the positive points of our study are that its sample was very suitable, with enough patients with very uniform epidemiological characteristics who underwent operations in exactly the same manner, thereby eliminating variables that could have altered our results.

Conclusions

The Latarjet procedure for correcting recurrent anterior shoulder dislocation led to good and excellent results in 82.7% of the cases. The complications observed were related to technical errors.

Conflicts of interest

The authors declare no conflicts of interest.

REFERENCES

1. Emami MJ, Solooki S, Meshksari Z, Vosoughi AR. The effect of open Bristow-Latarjet procedure for anterior shoulder instability: a 10-year study. *Musculoskelet Surg.* 2011;95(3):231–5.
2. Bankart AS. The pathology and treatment of recurrent dislocation of the shoulder joint. *Br J Surg.* 1938;26:23–9.
3. Rowe CR, Patel D, Southmayd WW. The Bankart procedure: a long-term end-result study. *J Bone Joint Surg Am.* 1978;60(1):1–16.
4. Neer CS, Foster CR. Inferior capsular shift for involuntary inferior and multidirectional instability of the shoulder: a preliminary report. *J Bone Joint Surg Am.* 1980;62(6):897–908.
5. Bigliani LU. Anterior and posterior capsular shift for multidirectional instability. *Tech Orthop.* 1989;3:36–45.
6. Balg F, Boileau P. The instability severity index score. A simple pre-operative score to select patients for arthroscopic or open shoulder stabilization. *J Bone Joint Surg Br.* 2007;89(11):1470–7.
7. Itoi E, Lee SB, Berglund LJ, Berge LL, An KN. The effect of a glenoid defect on antero-inferior stability of the shoulder after Bankart repair: a cadaveric study. *J Bone Joint Surg Am.* 2000;82(1):35–46.
8. Latarjet M. Treatment of recurrent dislocation of the shoulder. *Lyon Chir.* 1954;49(8):994–7.
9. Helfet AJ. Coracoid transplantation for recurring dislocation of the shoulder. *J Bone Joint Surg Br.* 1958;40(2):198–202.
10. Patte D, Debeyre J. Luxations recivates de l'épaule. *Eneyel Med Chir Techn Chirug Orthop.* 1982;44:265.

11. Godinho GG, Monteiro PC. Tratamento cirúrgico da instabilidade anterior do ombro pela técnica de Didier-Patte. *Rev Bras Ortop.* 1993;28(9):640-4.
12. Bessière C, Trojani C, Carles M, Mehta SS, Boileau P. The open Latarjet procedure is more reliable in terms of shoulder stability than arthroscopic Bankart repair. *Clin Orthop Relat Res.* 2014;472(8):2345-51.
13. Garth WP, Slappey CE, Ochs CW. Roentgenographic demonstration of instability of the shoulder: the apical oblique projection. *J Bone Joint Surg Am.* 1984;66(9):1450-3.
14. Rokous JR, Feagin JA, Abbott HG. Modified axillary roentgenogram. *Clin Orthop.* 1972;82:84-6.
15. Walch G, Boileau P. Latarjet-Bristow procedure for recurrent anterior instability techniques. *Tech Shoulder Elbow Surg.* 2000;1(4):256-61.
16. Hawkins RJ, Bokos DJ. Clinical evaluation of shoulder problems. In: Rockwood CA Jr, Matsen FA 3rd, Hiraki A, editors. *The shoulder.* 2nd ed. Philadelphia: Saunders; 1998. p. 175-80.
17. Ellman H, Kay SP. Arthroscopic subacromial decompression for chronic impingement. Two-to five-year results. *J Bone Joint Surg Br.* 1991;73(3):395-8.
18. Ikemoto RY, Murachovisky J, Nascimento LP, Bueno RS, Almeida LO, Strose E, et al. Resultados da cirurgia de Latarjet no tratamento da instabilidade anterior traumática do ombro associada à erosão óssea da cavidade glenoidal - Seguimento mínimo de um ano. *Rev Bras Ortop.* 2011;46(5):553-60.
19. Hovelius L, Akermark C, Albrektsson B, Berg E, Körner L, Lundberg B, et al. Bristow-Latarjet procedure for recurrent anterior dislocation of the shoulder. A 2-5 year follow-up study on the results of 112 cases. *Acta Orthop Scand.* 1983;54(2):284-90.
20. Schroder DT, Provencher MT, Mologne TS, Muldoon MP, Cox JS. The modified Bristow procedure for anterior shoulder instability: 26-year outcomes in Naval Academy midshipmen. *Am J Sports Med.* 2006;34(5):778-86.
21. Raiss P, Lin A, Mizuno N, Melis B, Walch G. Results of the Latarjet procedure for recurrent anterior dislocation of the shoulder in patients with epilepsy. *J Bone Joint Surg Br.* 2012;94(9):1260-4.
22. Checchia SL, Doneux PS, Miyazaki AN, Leite AFM, Simmer Filho J, Menezes MVC. Tratamento cirúrgico da luxação recidivante anterior do ombro em pacientes convulsivos. *Rev Bras Ortop.* 2000;35(9):340-6.
23. Griesser MJ, Harris JD, McCoy BW, Hussain WM, Jones MH, Bishop JY, et al. Complications and re-operations after Bristow-Latarjet shoulder stabilization: a systematic review. *J Shoulder Elbow Surg.* 2013;22(2):286-92.
24. Lädermann A, Lubbeke A, Stern R, Cunningham G, Bellotti V, Gazielly DF. Risk factors for dislocation arthropathy after Latarjet procedure: a long-term study. *Int Orthop.* 2013;37(6):1093-8.
25. Hovelius L, Sandström B, Olofsson A, Svensson O, Rahme H. The effect of capsular repair, bone block healing, and position on the results of the Bristow-Latarjet procedure (study III): long-term follow-up in 319 shoulders. *J Shoulder Elbow Surg.* 2012;21(5):647-60.