

This is an Open Access article licensed under the terms of the Creative Commons Attribution-NonCommercial 3.0 Unported license (CC BY-NC) (www.karger.com/OA-license), applicable to the online version of the article only. Distribution permitted for non-commercial purposes only.

Incomplete Vitreomacular Traction Release Using Intravitreal Ocriplasmin

Eric K. Chin David R.P. Almeida Elliott H. Sohn H. Culver Boldt
Vinit B. Mahajan Karen M. Gehrs Stephen R. Russell James C. Folk

Department of Ophthalmology, University of Iowa Hospitals and Clinics,
Iowa City, Iowa, USA

Key Words

Vitreomacular traction · Vitreomacular adhesion · Macular hole · Vitreolysis · Ocriplasmin · Jetrea® · Vitrectomy

Abstract

Purpose: To report the clinical course of our first 7 consecutive patients treated with intravitreal ocriplasmin (Jetrea®). **Methods:** Retrospective case series of the first 7 patients treated with ocriplasmin between January and December 2013 at an academic tertiary care center. **Results:** The average age was 78.4 years (range: 63–92). Five patients were pseudophakic and 2 patients were phakic in the injected eye. The median baseline visual acuity (VA) was 20/60 (range: 20/25 to 20/200). The median 1-month postinjection VA was 20/70, with a mean loss of 2 lines of VA among all patients. None of the patients had complete resolution of their vitreomacular traction or macular hole at 1 month of follow-up. Three patients had subsequent pars plana vitrectomy and membrane peeling surgery. The mean follow-up period for those who did not undergo vitrectomy was 9 months (range: 1–13). One patient with known ocular hypertension had an increase in intraocular pressure requiring topical pressure-lowering eyedrops. There were no cases of postinjection uveitis, endophthalmitis, retinal tears, or retinal detachment. **Conclusions:** While ocriplasmin may be a viable pharmacological agent for vitreolysis, we present a series of patients that all had incomplete resolution of vitreomacular traction with and without full-thickness macular hole. There was an associated reduction in VA after ocriplasmin treatment at 1 month of follow-up. Careful analysis of the vitreoretinal interface and comorbid eye conditions is required to optimize outcome success with ocriplasmin.

© 2014 S. Karger AG, Basel

Eric K. Chin, MD
Department of Ophthalmology, University of Iowa
200 Hawkins Dr.
Iowa City, IA 52242 (USA)
E-Mail chin.eric@gmail.com

Introduction

The vitreoretinal interface has recently been studied extensively due to the advent of noninvasive high-resolution optical coherence tomography (OCT) imaging. The treatment of vitreomacular interface disorders, including vitreomacular adhesion (VMA), vitreomacular traction (VMT), and evolving or early full-thickness macular hole (FTMH), has traditionally been limited to either surgical or observational management. Until recently, pars plana vitrectomy (PPV) was the only treatment for VMT and FTMH. Because surgery poses certain risks, it is usually withheld until the loss of vision is clinically significant or progressive.

Ocriplasmin (Jetrea®; ThromboGenics, Iselin, N.J., USA) is a recombinant 2-kDa protease subunit derived from human plasmin that can hydrolyze laminin and fibronectin, which normally connects the collagen fibrils at the vitreoretinal interface. Intravitreally, ocriplasmin induces vitreous liquefaction and separation of vitreoretinal adhesions at the macula and peripapillary retina [1]. Ocriplasmin was approved by the US Food and Drug Administration (FDA) in October 2012, the European Commission of the European Union in March 2013, and Health Canada in August 2013 for the treatment of patients with symptomatic VMT with and without FTMH [2]. In the current study, we report our clinical experience of the first 7 patients treated with intravitreal ocriplasmin for VMT. The goals of this paper are to evaluate our treatment outcomes using ocriplasmin and to analyze which patients may be better candidates for this treatment.

Methods

In a retrospective observational consecutive case series, the first 7 patients who were treated with intravitreal ocriplasmin at the University of Iowa between January 1, 2013 and December 1, 2013 were evaluated. The study received institutional review board/ethics committee approval at the University of Iowa and adhered to the tenets of the Declaration of Helsinki. All patients who had a billing code for an intravitreal injection procedure using ocriplasmin were reviewed. All patients received ocriplasmin in a similar sterile fashion with the patient sitting upright and with application of subconjunctival lidocaine and povidone iodine 5% on the conjunctiva prior to injection.

The primary outcome measure was the incidence of release of the VMT at 1 month following injection as evaluated by the Spectralis OCT (Heidelberg Engineering, Heidelberg, Germany). Secondary outcome measures included visual acuity (VA), intraocular pressure, lens status, and ocular adverse events, e.g. progression of VMT to FTMH, retinal tear or detachment, development of submacular fluid or serous retinal detachment, or subjective dyschromatopsia.

Results

A total of 7 consecutive patients with a spectrum of VMT were treated with a one-time injection of intravitreal ocriplasmin by 4 different retina specialists. Two of the treated patients had concurrent FTMH. There were no cases of postinjection uveitis, endophthalmitis, retinal tears, or retinal detachment throughout the follow-up period. None of our patients had visually significant epiretinal membranes. Only the affected eye with significant VMT was included in our analysis. A summary of all patients' demographics, lens status, pre-

and postinjection VA, and postinjection disposition are listed in [table 1](#). OCT features and patient symptoms before and 1 month after intravitreal ocriplasmin are listed in [table 2](#).

None of the patients had release of the VMT or closure of the macular hole at 1 month of follow-up. The mean follow-up period for those who did not undergo vitrectomy was 9 months (range: 1–13 months). Patient No. 1 was seen locally by an outside eye provider after his 1-month postinjection follow-up. Patient No. 2 had spontaneous resolution of her broad VMA and persistent scant subretinal fluid at the fovea center during the year following ocriplasmin injection. Her VA remained stable 20/250 at the most recent follow-up. Patient No. 3 was seen 3.5 months after ocriplasmin and had unchanged 20/70 vision and OCT findings. Patient No. 4 was seen 3 months following ocriplasmin and had resolution of the subretinal fluid that was seen at 1 month. At both 3 and 10 months of follow-up, there was persistent VMT, and vision had returned to his 20/60 baseline. Three patients (patients No. 5–7) underwent PPV and membrane peeling surgery after at least 1 month following ocriplasmin injection.

Discussion

Intravitreal injection of ocriplasmin represents a novel treatment option supplementing observation and PPV in the management of patients with symptomatic vitreomacular interface disorders. In this study, we evaluated our first 7 consecutive cases of incomplete VMT resolution following intravitreal ocriplasmin. We present an array of patients who responded inadequately to pharmacologic vitreolysis despite prior published reports of success rates as high as 42–47% [3, 4]. The confounding variables that may limit the success of ocriplasmin seen in our series can be summarized by the following:

(1) *Lens Status*. Pseudophakic patients may do poorly compared to those who are phakic. We know from Stalmans et al. [2] that the success rate is much lower in those who have had prior cataract surgery (i.e. 34.2 vs. 13.4% in phakic vs. pseudophakic patients, respectively). In a small retrospective series by Singh et al. [4], resolution of VMT was found in 2 out of 5 patients (40%) who were pseudophakic, in comparison to 6 out of 12 (50%) patients who were phakic. In their retrospective series, Kim et al. [3] included 4 patients who were pseudophakic, none of which had success with ocriplasmin and all subsequently underwent surgical repair. Our study included 2 patients who were phakic, but neither had resolution of the VMT.

(2) *Broad versus Focal Vitreomacular Attachments*. We observed 2 patients with broad vitreoretinal adhesions (patient No. 2, [fig. 1c, d](#); patient No. 3, [fig. 2b, d](#)) which did not change significantly following intravitreal ocriplasmin. Both these patients went on to develop new trace subretinal fluid and slight worsening of their vision. Interestingly, even those with focal adhesions tended to do poorly in this series. In some cases, the adhesion may have been so strong that the vitreolysis caused increased intraretinal or subretinal fluid, as well as transient subjective and objective blurring in the interim prior to their 1-month follow-up. In a majority of cases, the trace subretinal fluid and/or intraretinal cysts at the fovea center at 1 month of follow-up eventually resolved; however, the VMT or VMA persisted.

(3) *Multiple Vitreomacular Attachments*. To our knowledge, this is the first published report of a patient who had 2 areas of focal VMT/VMA that was treated with ocriplasmin (patient No. 4, [fig. 3](#)). There was little change to the width of attachment in either location; however, there was new subretinal fluid and 2 lines of vision loss showing that there were some changes, perhaps partially or inadequately, following ocriplasmin injection. The subretinal fluid eventually resolved at 3 months of follow-up; however, the VMT persisted

and the vision returned to baseline (20/60). We hypothesize that such a ‘satellite’ (or ancillary adhesion site) will foster a poor likelihood of VMT resolution and vision improvement.

(4) *Age.* The average age of our cohort was 78.4 years. It has been hypothesized that patients younger than 65 years may have greater success rates. Kim et al. [3] reported a 42% success rate and an average age in their cohort of 71 years. Similarly, Singh et al. [4] reported a success rate of 47% and an average age of 68.8 years.

The most useful data for ocriplasmin usage is derived from the Microplasmin for Intravitreal Injection Traction Release without Surgical Treatment (MIVI-TRUST) group that provided combined analysis of 2 large, randomized, double-blind controlled clinical trials (i.e. MIVI-006, MIVI-007) [2]. Patients with symptomatic VMA were eligible, including those with macular hole and VMT, with a VA in the range of 20/25 to 20/800. The treatment group received a single intravitreal injection of 125 µg of ocriplasmin, and the control group received an intravitreal injection of drug vehicle/saline. The primary endpoint was resolution of VMA at day 28. Among 464 eyes treated with ocriplasmin, 26.5% had release of VMA at day 28 compared with 10.1% of 188 control eyes ($p < 0.001$) [2]. There was also a greater chance of macular hole closure, posterior vitreous detachment, and 3-line VA gain comparing the study eyes with the controls.

The purpose of this paper is to show the variability of outcomes following ocriplasmin injections, and the possibility of slight worsening of vision at 1 month of follow-up. In all 7 patients in this series, vision had decreased by an average of 2 Snellen acuity lines at 1 month postinjection. This may be a result of worsening intra- or subretinal fluid that was seen in 5 of 7 of our patients. Similar outer retinal changes at the inner/outer segment junction (i.e. ellipsoid layer) were seen in the study by Singh et al. [4]; however, their findings were present approximately 1–2 weeks after injection, with eventual resolution at 1 month. Alternatively, this could be the result of changes to the vitreous that cannot be visualized in the limited area seen with OCT, or perhaps changes to the photoreceptor layer that can be detected with electroretinogram [5]. A decrease of 3 or more lines of VA was experienced by 5.6% of the patients in the ocriplasmin group and 3.2% of those in the placebo group. This was not thought to be due to any manifest toxicity, but rather the US FDA concluded that a majority of these were because of progression of the underlying traction. Three of the patients presented in our series eventually went forward with definitive PPV surgery. Of the remaining 4 who elected for observation, many returned to their baseline vision with similar preoperative OCT findings.

This study is an initial look at the real-world clinical outcomes of ocriplasmin at our institution. It is limited by its retrospective nature and small number of subjects. No major adverse effects were encountered following intravitreal injection of ocriplasmin (i.e. no retinal tears, retinal detachment, or postinjection inflammation). One patient with known ocular hypertension had an abrupt and persistent increase in intraocular pressure by 5 mm Hg following her injection, which was adequately controlled with topical therapy. The results suggest that careful patient selection should be taken into consideration as vision may temporarily worsen related to anatomic changes at the vitreoretinal interface as well as within and underneath the neurosensory retina. Finally, patients should be counseled regarding the realistically modest rates of anatomic and functional success with intravitreal ocriplasmin, along with the non-negligible risks of treatment and intravitreal injection.

Disclosure Statement

The authors have no commercial or financial interests associated with the article.

References

- 1 Kuppermann BD: Ocriplasmin for pharmacologic vitreolysis. *Retina* 2012;32:S225–S228.
- 2 Stalmans P, Benz MS, Gandorfer A, et al: Enzymatic vitreolysis with ocriplasmin for vitreomacular traction and macular holes. *N Engl J Med* 2012;367:606–615.
- 3 Kim BT, Schwartz SG, Smiddy WE, et al: Initial outcomes following intravitreal ocriplasmin for treatment of symptomatic vitreomacular adhesion. *Ophthalm Surg Lasers Imaging Retin* 2013;44:334–343.
- 4 Singh RP, Li A, Bedi R, et al: Anatomical and visual outcomes following ocriplasmin for symptomatic vitreomacular traction syndrome. *Br J Ophthalmol* 2014;98:356–360.
- 5 Freund KB, Shah SA, Shah VP: Correlation of transient vision loss with outer retinal disruption following intravitreal ocriplasmin. *Eye (Lond)* 2013;27:773–774.

Table 1. Patient demographics, pre-/postinjection VA, and disposition

Patient/gender/eye	Age, years	Lens status/past ocular history of the injected eye	Preinjection BCVA	One-month postinjection BCVA	Disposition
1/F/OS	92.7	PCIOL/dry ARMD	20/80	20/100	Observe
2/F/OS	74.3	2+ NS/dry ARMD	20/200	20/300	Observe
3/F/OS	84.4	ACIOL/dropped lens	20/60	20/70	Observe
4/M/OD	80.4	PCIOL/none	20/60	20/80	Observe
5/F/OS	64.2	PCIOL/OHTN	20/40	20/60	Surgery
6/M/OS	77.0	PCIOL/dry ARMD	20/25	20/60	Surgery
7/F/OD	75.9	2+ NS/none	20/25	20/30	Surgery
Median	77.0		20/60	20/70	

M = Male; F = female; PCIOL = posterior chamber intraocular lens; ACIOL = anterior chamber intraocular lens; NS = nuclear sclerosis lens; BCVA = best corrected visual acuity; ARMD = age-related macular degeneration; OHTN = ocular hypertension.

Table 2. Pre- and postinjection qualitative OCT features with postinjection symptoms

Patient	Preoperative OCT	Postoperative OCT	Postinjection ocular symptoms at 1 month
1	FTMH with focal VMA	FTMH with focal VMA	Blurred vision
2	Broad VMA; intraretinal hyperreflectivity	New subretinal fluid ; broad VMA; intraretinal hyperreflectivity	None
3	Broad VMA; inner intraretinal cysts	Broad VMA; new subretinal fluid ; resolution of cystoid macular edema	Blurred vision; dysphotopsias
4	Intraretinal cystoid macular edema; secondary paracentral VMA	New subretinal fluid ; persistent secondary paracentral VMA; resolution of cystoid macular edema	None
5	FTMH; trace intraretinal cysts	FTMH; mild intraretinal cysts with broader base of FTMH	None
6	Focal VMA; drusen	Focal VMA; new intraretinal cystoid macular edema ; drusen	Blurred vision
7	Focal VMA with large inner retinal cysts	Focal VMA with smaller inner retinal cysts	Dysphotopsias

Pertinent positive findings are highlighted in bold.

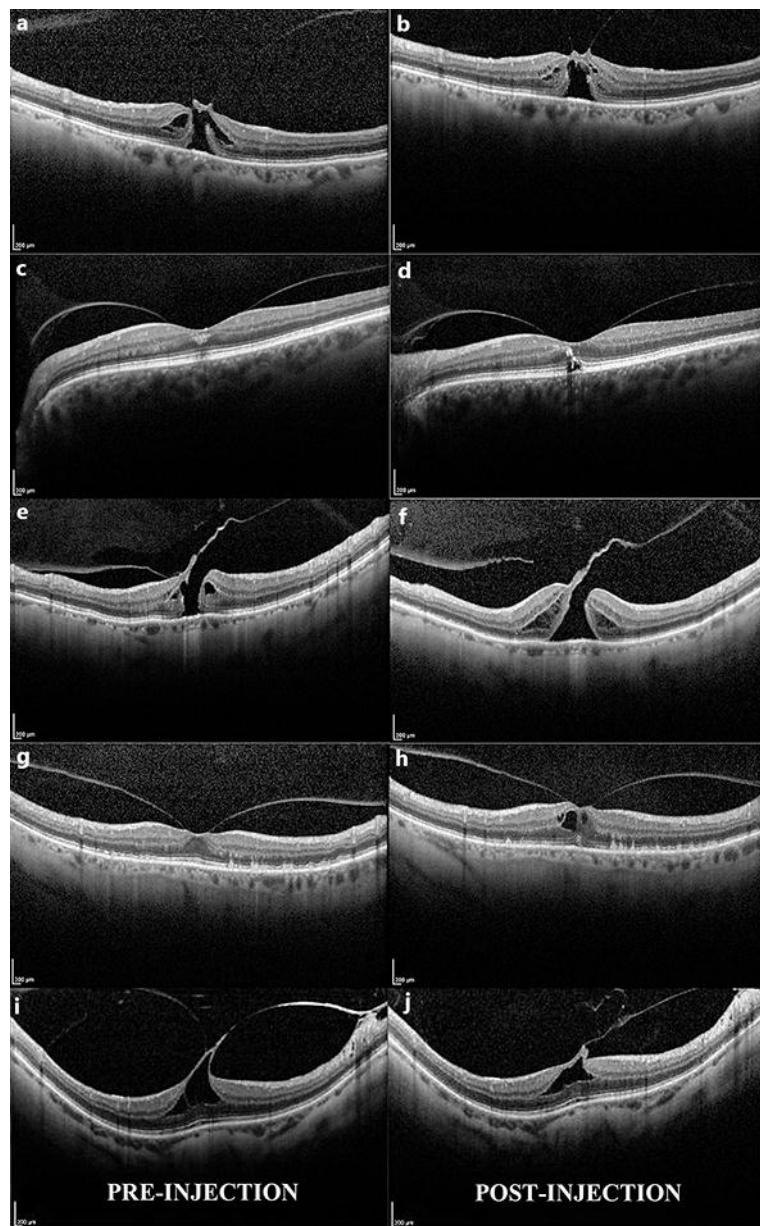


Fig. 1. **a, b** Patient No. 1. **a** FTMH with a focal VMT, mild retinal schisis and intraretinal cysts. **b** One month after ocriplasmin: persistent FTMH and VMT. The schisis and intraretinal cystoid changes appear less pronounced. **c, d** Patient No. 2. **c** A very broad VMA with ill-defined intraretinal hyperreflective spots at the fovea center. **d** One month after ocriplasmin: persistent broad VMA, intraretinal hyperreflective spots, and new small amount of subretinal fluid at the fovea center. **e, f** Patient No. 5. **e** FTMH with focal VMT and small intraretinal cysts. **f** One month after ocriplasmin: slightly larger FTMH, persistent focal VMT and larger intraretinal cysts. **g, h** Patient No. 6. **g** Focal VMA with several small drusen. **h** One month after ocriplasmin: persistent focal VMA and drusen with new intraretinal cystoid changes. **i, j** Patient No. 7. **i** Focal VMT with inner intraretinal cystoid changes. **j** Persistent thin thread of vitreous remains attached to the foveal retinal interface and with smaller intraretinal cystoid changes.

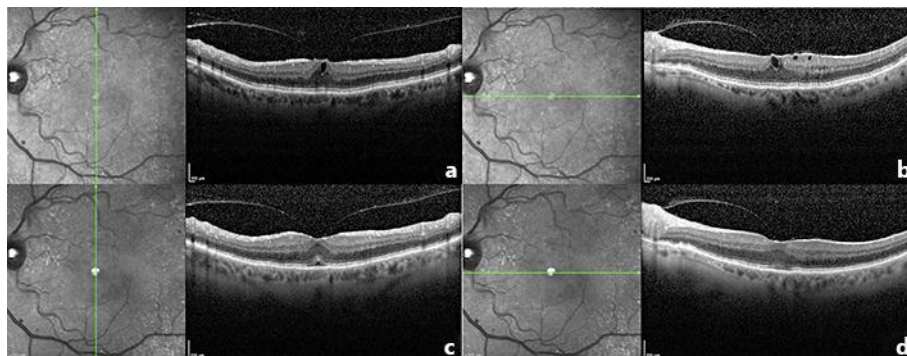


Fig. 2. a–d Patient No. 3. **a** Focal VMA with a few small intraretinal cysts. **b** Broad VMA that can only be seen in horizontal scans. Superficial cysts are present just below the internal limiting membrane. **c** Focal VMA with a new small amount of subretinal fluid 1 month after ocriplasmin. **d** Unchanged broad VMA temporarily, but resolution of the intraretinal superficial cysts 1 month after ocriplasmin.

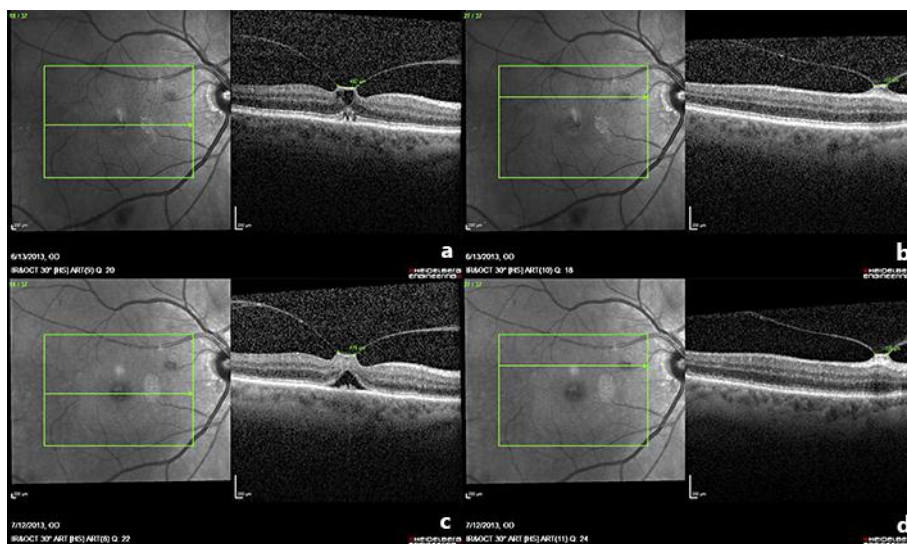


Fig. 3. a–d Patient No. 4. **a** Focal VMA overlying a few large intraretinal cysts. **b** A secondary point of VMA just temporal to the optic nerve without any intraretinal cystoid changes. **c** Persistent focal VMA with new subretinal fluid, but resolution of the previously seen intraretinal cysts 1 month after ocriplasmin. **d** Unchanged focal VMA just temporal to the optic nerve at 1 month of follow-up.