

Carotid Endarterectomy: experience in 8743 cases

R. Chiesa¹, G. Melissano¹, R. Castellano¹, Y. Tshomba¹, E.M. Marone¹, E. Civilini¹, D. Astore¹, F. Calliari¹, B. Catenaccio¹, G. Coppi¹, A. Carozzo², R. Mennella²

¹Department of Vascular Surgery; ²Anesthesia and Intensive Care, San Raffaele Scientific Institute, Università Vita-Salute, Milan, Italy

ABSTRACT

Introduction: Recently published case series of patients undergoing carotid endarterectomy suggested a reduction in the rate of perioperative neurologic events when compared to those reported in the large randomized trials performed in the 1990s, without great differences between high and low risk patients.

Methods: As a major center of Vascular Surgery we prospectively collected data on 8743 carotid endarterectomy procedures (eversion technique 75%, patch closure 17.5%) performed in the period 1992-2009.

Results: Perioperative mortality was 0.32% (27/8743) with myocardial infarction being the most frequent cause (9 patients). Perioperative neurological morbidity was 1.04% (91/8743) with 51 major and 40 minor strokes. In 201 cases (2.3%) a cervical hematoma (suture-line bleeding in 41 cases and or diffuse oozing in 160 cases) in the early postoperative period necessitated urgent wound revision. In 262 (3.0%) cases we observed permanent or transient lesions of cranial nerves in the postoperative period. There was no significant difference in the combined ipsilateral stroke and perioperative death rate in octogenarian patients (2.1% in octogenarians and 1.2% in younger patients, $p > 0.05$), even though an increasing trend was evident.

Conclusions: Carotid endarterectomy has a reduced rate of perioperative complications when compared to those previously reported in literature. The low complication rate is related to improved preoperative patients evaluation, surgeons' increasing experience and to surgical and anesthesiological techniques. Carotid angioplasty and stenting should have their results compared to these real world results of carotid endarterectomy in order to assess their reliability when treating extracranial cerebrovascular disease.

Keywords: vascular surgery, carotid endarterectomy, stroke survival anesthesia.

INTRODUCTION

In the early 1990's several well designed randomized studies clearly demonstrated the effectiveness of carotid endarterectomy (CE) over best medical therapy alone for symptomatic and asymptomatic patients with a significant stenosis of the internal carotid artery (ICA) (1-6).

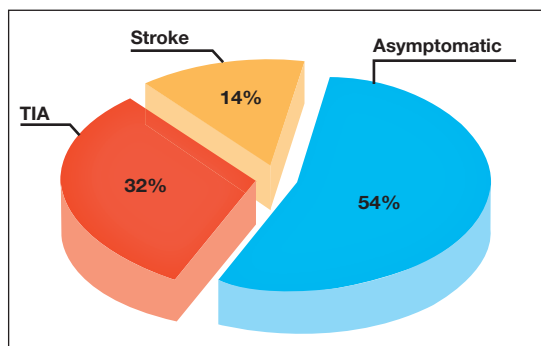
More recently, published case series of patients undergoing CE (7-10) assessed a more conclusive reduction in rate of perioperative complications (neurologic events) compared to risk/benefit ratio reported in the former trials (1-6), without great differences between high- and low- risk selected patients.

In this article we report our experience as a major center of Vascular Surgery, performing 8743 CE procedures in the period 1992-2009, and we show our results analysis with evaluation of perioperative complication rates.

Corresponding author:
 Roberto Chiesa, M.D.
 Professor of Vascular Surgery,
 San Raffaele Scientific Institute, Università Vita-Salute
 Via Olgettina 60 - 20132 Milan, Italy
 e.mail: chiesa.roberto@hsr.it

Table 1 - Clinical characteristics of 6468 patients who underwent 8743 carotid endarterectomy procedures in the period 1992-2009 in our centre.

Clinical Features	N
Male sex, n (%)	5764 (69 %)
Age, mean (years)	69
Symptoms	
Stroke	1176 (14 %)
TIA	2689 (32 %)
Asymptomatic	4538 (54 %)
Risk Factors	
Hypertension	5579 (66 %)
Dislipidemia	3966 (47 %)
Diabetes	1664 (20 %)
Smoke	3975 (47 %)
Positive TC	5151 (61 %)



Graph 2

Neurologic medical history of 6468 patients who underwent 8743 carotid endarterectomy procedures in the period 1992-2009 in our centre.

METHODS

From 1992 to 2009, we performed a total of 8743 CE, on 6468 patients, with a mean age of 69.3 years (range 32-92).

Clinical characteristics and age distribution are presented in *table 1* and *Graph 1*.

Neurological history was positive for stroke in 1224 (14%) and for transient ischemic attack (TIA) in 2798 patients (32%).

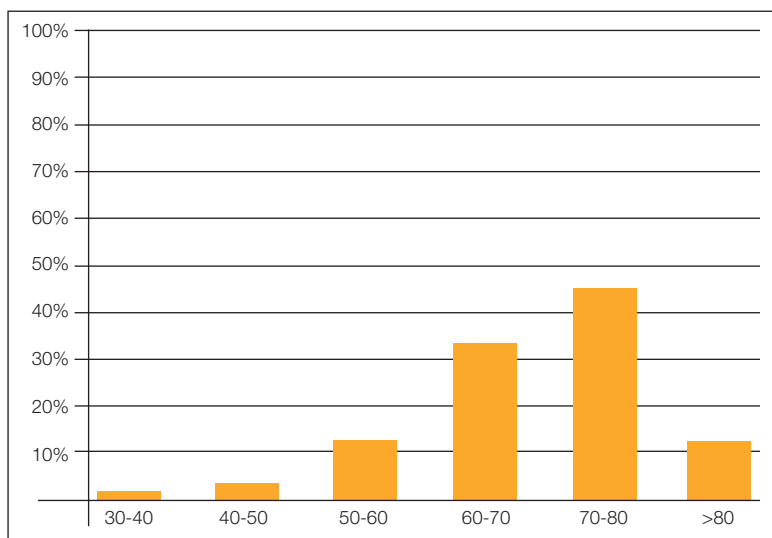
In 4721 cases (54%) patients were neuro-

logically asymptomatic or presented non specific symptoms (*Graph 2*).

Our current clinical protocol and the percentage of adherence to it in this case series are described below.

Indications

According to well-defined guidelines, established in 1998 during the Consensus Conference of the American Heart Association (11, 12) and endorsed by the Italian Society



Graph 1

Age distribution of 6468 patients who underwent 8743 carotid endarterectomy procedures in the period 1992-2009 in our centre.

of Vascular Surgery (13), symptomatic and asymptomatic patients with carotid stenosis >60% are judged eligible for CE, depending on life expectancy, comorbidities, general condition and surgical risk (which must be less than 3% for asymptomatic patients and less than 6% for symptomatic patients).

Elderly patients are not excluded from surgical treatment on the basis of age alone (10.1% of octogenarians in our series), as, even in this subgroup of patients, CE may be a safe mean of stroke prevention, provided that patients receive adequate selection (14-16).

Indication and timing of urgent carotid revascularization in presence of acute neurological symptoms still represent a much debated issue, even though some investigators advocate good results with emergent surgery in highly selected patient (17-19). In our series we had 157/8743 cases (1.8%) of urgent carotid revascularization, performed for two specific conditions: patients with crescendo TIAs and a single TIA with ulcerated plaque (136 cases); patients developing post-operative cerebral ischemia (21 cases), respectively.

Preoperative hospital stay and diagnostic work-up

Although patients could be ideally admitted to hospital the same day of surgery (20), we usually prefer to admit the patient 1 day before surgery.

Duplex Scanning: duplex scanning (i.e. an ultrasonography study characterized by the combination of B-scan imaging and Doppler imaging) performed at a validated laboratory has almost completely replaced angiography (21-24). When the results of a duplex scan are uncertain, magnetic resonance angiography (MRA)/computed tomography angiography (CTA) represent our second choice while contrast angiography with arterial catheterization (stroke rate of 1.2%

in ACAS trial) (6) is our last choice.

Cerebral Parenchymal Study/Neurological Auditing: as far as cerebral parenchymal imaging is concerned, preoperative computed tomography (CT) scan is useful to show previous ischemic cerebral lesions with prognostic significance for new strokes after CE (25). CT may also reveal the presence of aneurysms, vascular malformations, and brain tumors.

In the last 2 years, preoperative cerebral CT was performed in 87% of our patients, especially those showing high risk features (neurologic symptoms, bilateral stenosis, high risk plaque). Magnetic resonance imaging (MRI) is performed only in *selected cases* (5.8%).

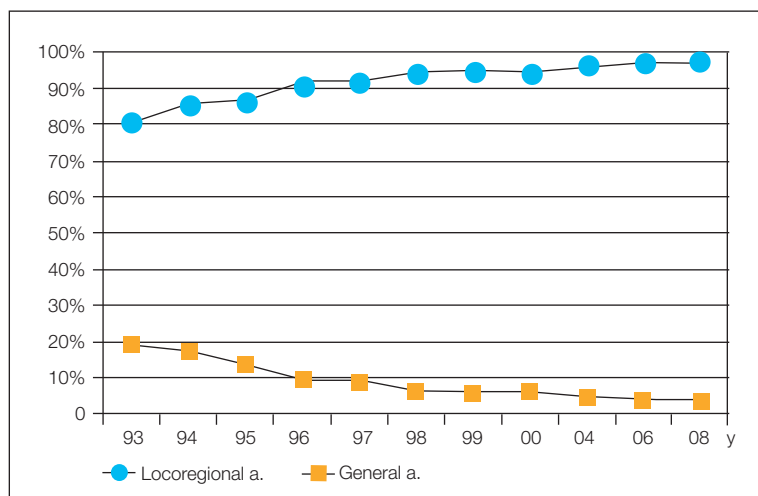
Cardiac Status: the most important non-neurologic area to explore preoperatively is cardiac status. As a matter of fact, most of perioperative complications and deaths are cardiac in origin (26). There is no consensus on optimal cardiovascular preoperative evaluation before CE. Some studies suggest that routine scintigraphic or ultrasonographic tests are useful in detecting patients at high risk (27, 28), but there is no evidence of cost-effectiveness of this approach.

According to our current protocol, echocardiography with dobutamine test is performed in patients with a history of cardiac disease or with a pathologic electrocardiogram (EKG) (16%).

Preoperative Medication: given the benefit of antiplatelet therapy in patient undergoing CE without a substantial higher risk of bleeding (29) we discontinue acetylsalicylic acid/ticlopidine only the day of operation, while low molecular weight heparin at low doses is administered overnight.

Surgical procedure

Anesthesia: the choice of the anesthetic management for carotid surgery is still controversial. A recent large randomized trial

**Graph 3**

The increase in the use of Loco Regional Anesthesia in our centre in the study period to perform 8743 carotid endarterectomy procedures.

showed no differences between general and locoregional anesthesia (30) in clinically relevant endpoints.

Nevertheless, minor advantages of locoregional anesthesia (LRA) are well recognized. It can be performed outside the operating room with adequate patient monitoring, and allows a less cumbersome neurological monitoring during clamping. Some authors also described better hemodynamic stability during surgery and improved post-operative pain control with the use of LRA (31).

Performing LRA in recovery room before entering the operating room helped us to save at least 30 min on the use of the operating room, compared to general anesthesia. Currently LRA is used in most cases of our series (96.3%) (*Graph 3*).

The choice between superficial or deep cervical plexus block is performed by the attending anesthesiologist, taking into account his/her experience in the technique and patients' characteristics (e.g. double antiplatelet therapy). Superficial cervical plexus blocks is performed by a 20 G needle, introduced into the skin at the midpoint of the posterior border of the sternocleidomastoid muscle in a slightly caudal direction, and 0.75% ropivacaine (≈ 5 ml) is injected along

the posterior border in cranial and caudal directions subcutaneously, superficial and deep to the fascia of the muscle. An injection in a fan-like fashion is also performed subcutaneously from the posterior border of sternocleidomastoid toward the midline of the neck. Deep cervical plexus block is performed at C2-C3-C4 level. A 20 G needle is inserted in the skin until it reaches the transverse process of the corresponding vertebra and then anesthetic is injected after an accurate suction-test. We generally administer 5 ml of 0.75% ropivacaine for each injection. The total amount of ropivacaine used is 1.5 mg/kg (considering both the superficial and the deep cervical block). The last step of the procedure is the infiltration of the incision line with 10 to 15 ml of lidocaine 1%. Subsequent sensory loss to a pinprick in the C2-4 dermatome distribution is recorded. Additional lidocaine (1%) is administered intraoperatively by surgeons in 1 ml aliquots (either superficially into skin and subcutaneous tissues or deep into and around the carotid sheath), as required when the patient reported discomfort. It should be useful to add a mild intravenous injection of opiates (Fentanyl 1 μ g/kg or Remifentanyl 0.025-0.05 μ g/kg/min), to reduce discomfort associated to the forced posture during

surgery. We feel very comfortable with use of lidocaine and ropivacaine, as the former ensues a rapid onset of pain control while the latter, with its long lasting nerve block (5-8 hours), guarantees good analgesia in the early postoperative period.

Heparinization: systemic heparinization is routinely used (a dose of 70 IU/kg was used until '04 when we reduced the dose to 50 IU/kg in order to minimize the risk of cerebral haemorrhage). Activated Clotting Time (ACT) is measured before and after heparin administration, with a target ACT greater than 200". Protamine is administered in half the dose required to antagonize all heparin.

Surgery

Exposure of the carotid bifurcation: exposure starts with incision of the skin right on the anterior border of the sternocleidomastoid muscle. Depending on the characteristic of the neck, our standard incision usually was 10-15 cm long. Recently we have started to reduce the length of the skin incision by mapping the location of the carotid bifurcation at the time duplex is performed (32) (*Figure 1*). Once the bifurcation is freed from the surrounding structures, we progress to mobilization of the arteries. Special care is mandatory to avoid damage to the vagus nerve. The internal carotid artery (ICA) is then mobilized to a point distal to the visible atheromatous lesion. The ICA is dissected along its edge, starting at the upper end of the bulb. During dissection is important to avoid the X and XII cranial nerves. As we use eversion as our routine technique, we routinely dissect the ICA distally in order to have a secure end-point. The surgical technique used in each single case is chosen according to carotid anatomy and cerebral tolerance to cross-clamping.

Standard endarterectomy: once the component of the carotid bifurcation are dissected and heparin administered, the arteries are

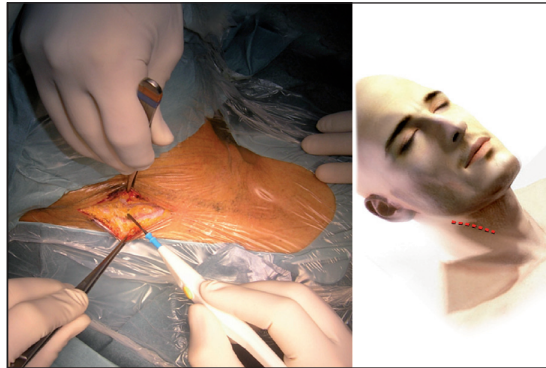


Figure 1

Our currently used shorter incision (5-7 cm long).

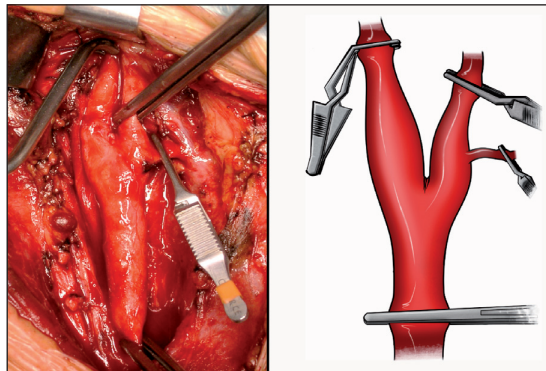


Figure 2

Complete clamping of the carotid bifurcation.

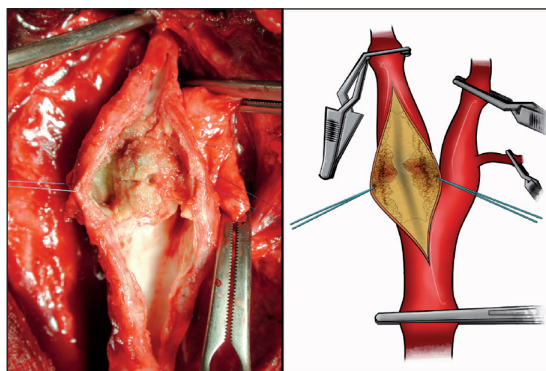


Figure 3

Arteriotomy of the bifurcation (two suture lines are placed to help maintaining the bifurcation open)..

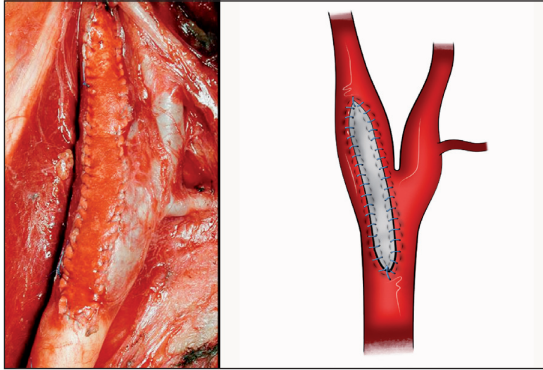


Figure 4
Polyurethane carotid patch.

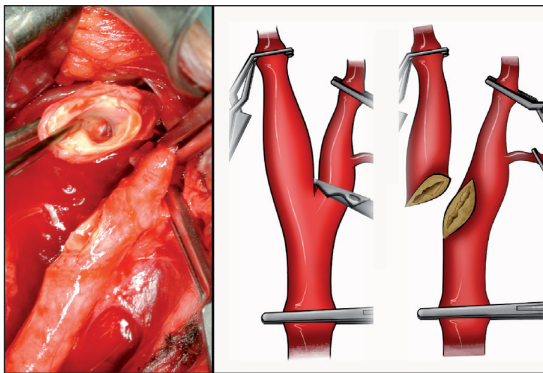


Figure 5
Transverse arteriotomy during eversion andarterectomy.

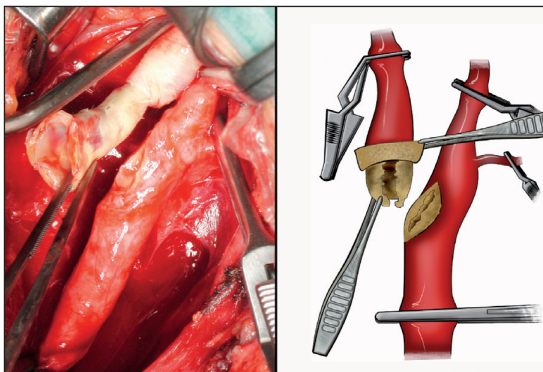


Figure 6
Eversion: the plaque is firmly hold with forceps while the outer wall is everted. Pulling the plaque should be avoided by any means.

clamped with microsurgical clamps. We usually clamp the ICA first, then the CCA and finally the ECA. If the superior thyroid artery has to be clamped, we usually deal with it using a mini-bulldog clamp (*Figure 2*). We always perform a tolerance test of 1 minute before starting with the CE. Arteriotomy extends over the last 2 centimeters of CCA and into the ICA to a point beyond the termination of the plaque (*Figure 3*). The plane for endarterectomy is sought at the level of the bulb, where the plaque is usually most developed. The proximal end-point of the plaque, at the level of the CCA, is usually obtained by direct cutting. The ICA endarterectomy is the most important part. The plaque is therefore pulled along its axis, paying attention not to stay close to the artery wall, while the ICA is pushed the opposite way. The remaining surface is then accurately debrided using forceps. Finally we proceed to closure of the arteriotomy with a synthetic patch (*Figure 4*). We have currently abandoned direct closure, as a recent metanalysis has shown a higher rate of restenosis, compared to patch closure or eversion (33).

Eversion technique: eversion allows optimal correction of elongated ICAs either by shortening the ICA after endarterectomy or by reimplanting the ICA a little further down into the CCA (34). The suture line is basically an end to side anastomosis that does not produce diameter reduction. This technique is expeditious and straightforward and it is the most used in our series (75 % of cases). One drawback is that occasionally it does not allow a clear-cut view of the distal end-point of the endarterectomy, thus requiring systematic intraoperative arteriography as a quality check. Once clamping of the ICA, CCA and ECA is established and the patient responds well to neurologic evaluation (of at least 1 minute), the ICA is transected at its origin (*Figure 5*). ICA endarterectomy is carried out by eversion in

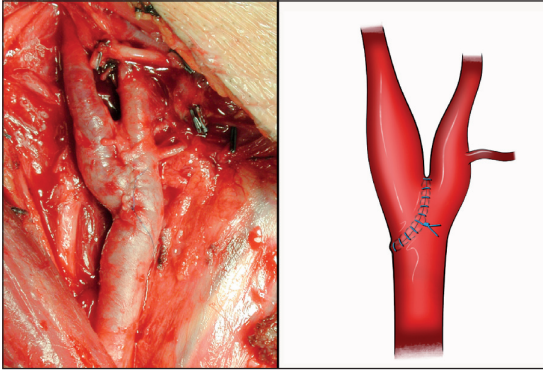


Figure 7
Final reconstruction of carotid bifurcation after eversion.

cranial direction (*Figure 6*). Careful flushing of the ICA and the CCA is performed before reimplanting of the ICA (*Figure 7*). At the end of the reimplantation an intraoperative arteriography is performed in order to exclude a distal intimal flap in the ICA which could lead to dissection or thrombosis (*Figure 8*).

Shunting: we are used to perform selective shunting with a Javid shunt (10.7%). On declamping we perform the Imparato ma-

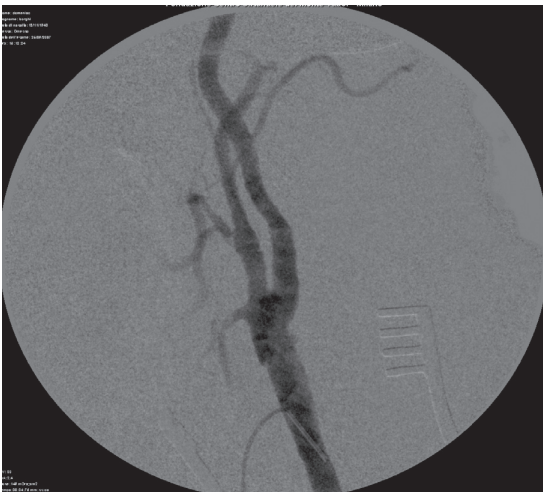

Figure 8
Intraoperative arteriography showing optimal final result of the endarterectomy.

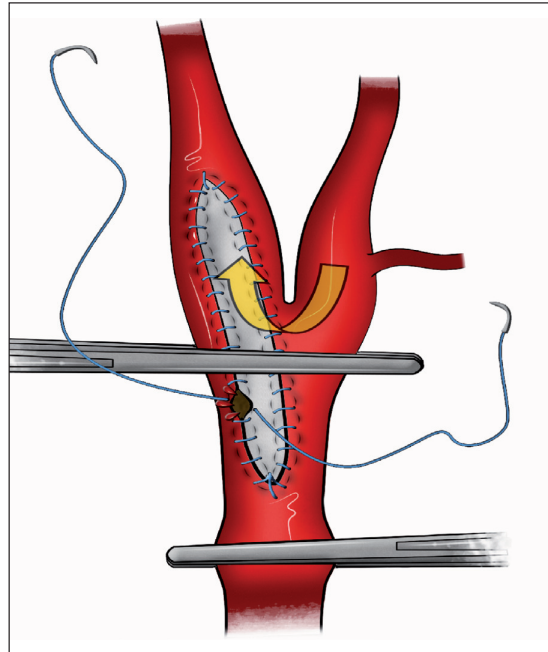


Figure 9
Imparato maneuver.

neuver in order to minimize the ischemic time (*Figure 9*).

Intraoperative quality check: to reduce the incidence of complications related to technical defects after CE, several types of quality control tests have been employed by different authors (35,36). Angiography through direct puncture of the CCA is probably the simplest and most direct way to show technical defects in the endarterectomized ICA. In our series, intraoperative completion arteriography is used routinely for eversion endarterectomy and only in dubious cases for other techniques. Selective carotid arteriography is performed through direct puncture of the CCA. If angiography shows a substantial defect of the distal end-point, the surgical options include resection and bypass grafting or a longitudinal incision on the internal carotid artery, with fixation of the intimal flap with tacking sutures and patch closure. Intraoperative carotid artery stenting (CAS) has emerged as a valuable

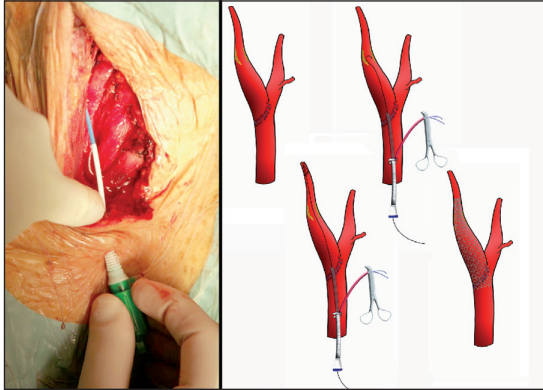


Figure 10
Intraoperative view of the transcervical approach for ICA stenting.

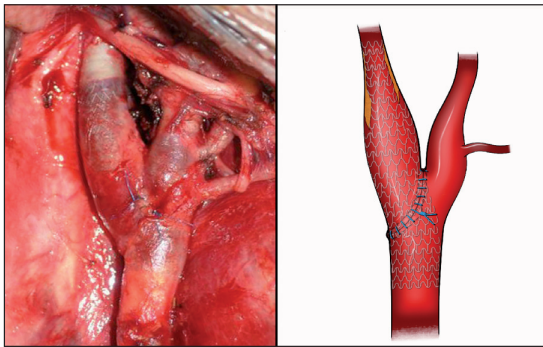


Figure 11
Stenting of the ICA for a distal end point defect.

alternative in the management of perioperative technical complications following CE (Figure 10). Currently stenting of the distal flap through direct cannulation of the CCA is often performed in case of a technical defect detected intraoperatively (Figure 11).

Post-operative management

In our experience selective postoperative ICU stay was necessary only in 1.5% of cases. This result is related to the high-quality nursing in the surgical ward, to the presence of a surgeon on call 24 hr/day, and to the availability of accurate, noninvasive monitoring at the patient's bedside.

Bleeding: in spite of meticulous hemostasis and cautious administration of heparin, postoperative bleeding is relatively frequent, particularly for patients on double antiplatelet therapy (37-39). The amount of tolerable bleeding in the neck is reduced by anatomic limitations related to the fasciae and the risk of airways' compression makes cervical hematoma a surgical emergency. When orotracheal intubation is required, it is important to remember that this may be extremely difficult to carry out because of the hematoma and swelling of the soft tissues that may limit the view of the larynx and the passage of the tube. Therefore intubation should be performed with a fibroscope. If the patient is breathing well, we perform hemostasis under local anesthesia. If the patient is intubated and there is large swelling of the soft tissues, we prefer to leave the tube in for at least 24 hr, along with steroid administration and head elevation.

Discharge: because the surgical procedure has a rather low local invasivity, safe discharge from the hospital may be as early as the first postoperative day (40). On the first postoperative morning, the surgeon inspects the wound and remove the drain. An independent neurologist rechecks the neurological status. If the patient is stable from a cardiovascular and neurologic standpoint, the EKG is unchanged, and the patient has no fever, has a dry wound without any neck swelling, and can eat, void, and ambulate spontaneously, discharge from the hospital can be scheduled for the same day. In our series patients are discharged at a mean of 2.5 ± 0.8 postoperative days.

Follow-up/Restenosis

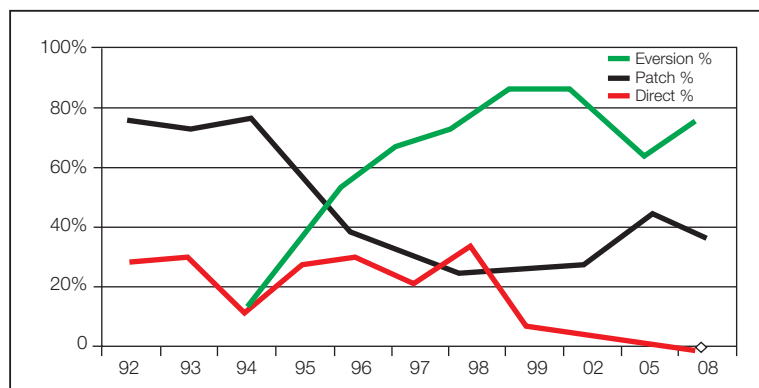
The patient is seen at the outpatient clinic on postoperative day 10 to remove the skin staples. If the patient is living far from the Hospital, he/she spends 1 more day in hospital and is asked to stay in town for a few days after the procedure. Follow-up duplex

scan is scheduled after 3,6 and 12 months and then on a yearly basis. Patients living in Lombardia have a 93 % clinical and duplex scan follow-up. For patients not living in Lombardia follow-up rate is lower but still acceptable (62 %).

RESULTS

The eversion technique was used in 6558 cases (75 %). CE with patch closure (we used Dacron patches until 2001 then we turned to polyurethane patches) was used in 1530 cases (17.5 %) and direct suture, now abandoned, in 655 cases (7.5 %) (*Graph 4*). A Javid shunt was selectively used in 935 cases (10.7 %) because of the presence of clinical and instrumental (modification of the EEG pattern) signs of cerebral ischemia. Shunting was twice as common in case of contralateral occlusion. Mean use of the operating room was 74 min. Through systematic use of locoregional anesthesia (LRA), our use of the operating room is at least 30 min less than that that we have during general anesthesia. Mean clamping time accounted for 14 minutes in case of patch closure and for 10 minutes in case of eversion endarterectomy. Perioperative mortality was 0.32 % (27/8743), with myocardial infarction being the most frequent cause (9 patients). Other causes of

death were: ischemic stroke (7 patients), hemorrhagic stroke (7 patients), respiratory failure caused by cervical hematoma (1 patient), wound infection (1 patient) and suture failure with massive bleeding (2 patients). Perioperative neurological morbidity was 1.04 % (91/8743). Of these 91 cases 51 (56 %) were major strokes and 40 (44 %) minor strokes, with complete or near complete resolution of all symptoms. A total of 201 cases (2.3 %) developed cervical hematoma in the early postoperative period, which necessitated urgent wound revision. Of these, 8 patients had the wound emergently reopened in the surgical ward because of progressive airway compression, which was fatal in one case. The cause of hematoma was either suture-line bleeding (41 cases) or diffuse oozing (160 cases). In 262 (3.0 %) cases we observed permanent or transient lesions of cranial nerves in the postoperative period, with the recurrent laryngeal nerve involved in 135 cases (51.7 %), the hypoglossal in 67 (25.8 %), the facial in 27 (10.3 %), the glossopharyngeal in 21 (7.5 %) and the accessory in 12 cases (4.7 %). We registered 25 cases of wound infection. All were readmitted to hospital and treated with surgical drainage. In case of patch closure (13 patients), the patch was removed and replaced with a saphenous vein one. In all cases except one, who suffered fatal stroke, recovery was unevent-



Graph 4

Trends in use of different endarterectomy techniques in our serie.

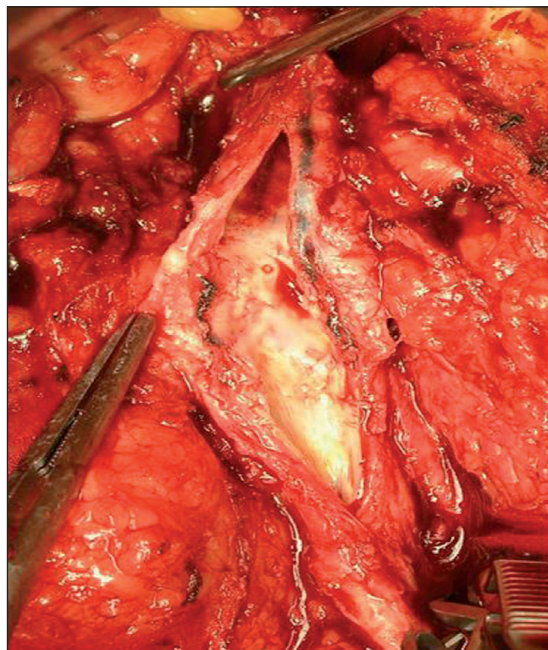

Figure 12

Reoperation for restenosis after a previous patch closure (Dacron).

ful. Elderly patients (i.e., octogenarians) face an increased operative risk (41). Since 1995 we performed 883 CE in octogenarians. The 1-year mortality was significantly higher among the octogenarians (1.37% vs. 0.32%, chi-square test, $p < 0.05$), however, there was no significant difference in the combined ipsilateral stroke and perioperative death rate (2.1% in the octogenarians and 1.2% in younger patients, $p > 0.05$), even though an increasing trend was evident. At the time of first admission 21.3% of patients presented with bilateral carotid stenosis greater than 70% and underwent staged bilateral CE. After the first intervention we experienced a rate of combined ipsilateral stroke and perioperative death rate of 1.4%, comparable to those experienced in normal patients. Similarly, the rate of combined ipsilateral stroke and perioperative death after the second operation was 1.3%. It is noteworthy that there was a sig-

nificantly greater need for shunting if the second operation was performed early, especially within 30 days from the first one (42). Contralateral occlusion was present in 18.2% of the patients. The rate of combined ipsilateral stroke and perioperative death rate was 1.37% in this subgroup. Complication rate did not differ from that of other patients, the only difference being a double rate of shunt insertion in patients with contralateral occlusion (43). In 431 cases (5%) we observed a $> 50\%$ restenosis that was treated only if symptomatic or critical $\geq 80\%$ (44), either with PTA-Stenting (71 cases; 0.8%) or surgically (32 cases; 0.3%). In 32 cases we performed redo open procedures (Figure 12) with 6 cases (18.7%) of cranial nerve injuries, and a combined ipsilateral stroke and perioperative death rate of 6%.

DISCUSSION

Carotid endarterectomy is safe and effective for stroke prevention in significant symptomatic and asymptomatic carotid stenosis. Writing the word "carotid endarterectomy" on the browser of any service that include English citations from MEDLINE and other life science journals for biomedical articles, each one of us can easily notice that over 9000 papers on CE have been published in peer-reviewed journals from 1953, and, incredibly, until nowadays, the surgical indications, the choice of neurological monitoring, the anesthetic management, and the surgical technique are still controversial. Moreover, in the last decade, carotid artery angioplasty and stenting (CAS) gained popularity as an alternative to carotid endarterectomy (CE), particularly in high risk patients, being less invasive and potentially minimizing the risks of wound complications and cranial nerve injury, which may translate into shorter length of hospitaliza-

tion and less resource utilization. Waiting for future developments, CAS is at present an effective treatment, particularly appealing in high-risk patients with significant carotid artery stenosis, however, there is no real evidence that CAS provides better results in the prevention of stroke compared to CE. We currently limit its use in cases of restenosis, in patients unfit for surgery, and for the perioperative correction of distal flaps after CE that may be difficult to treat surgically.

Our results of 8743 CEs demonstrate a progressive reduction in the incidence of complications, which can be compared to that reported by the major international studies of the last few years. This reduction is related to improved preoperative patients evaluation, surgeons' increasing experience, and to surgical and anesthesiological technique developments.

In terms of surgical technique, good results have been reported for all commonly used surgical techniques. We prefer to adopt a flexible approach choosing surgical technique on the basis of intraoperative findings and the need for shunt insertion. Shunt use has become less frequent, reflecting better neurologic monitoring and shorter clamp-times.

Limitations

Our study entails some limits. First of all the intrinsic limit of being a retrospective study, with all the bias due to its design. Moreover, in the first years, only major adverse cerebrovascular events were recorded, whereas TIA or non fatal myocardial infarction were not labeled as complications. This has led without any doubt to an under-estimation of the total rate of complication of CEA, even if it is still a topic of discussion what the real importance of this minor complications might be.

One second major limit is the fact that the short in-hospital stay of these patients (2.5

days) might make a discrete amount of post-operative complications, in particular those cardiac in origin, to go unnoticed. It is in fact well documented in literature that, on average, cardiac complications happen 2 to 4 days after the surgical stress has occurred. This might then lead to underestimate the total incidence of MI in the postoperative period, as many of our patients come from areas outside of our district.

The authors certify that there is no conflict of interest with any financial organization regarding the material discussed in the manuscript.

REFERENCES

1. Beneficial effect of carotid endarterectomy in symptomatic patients with high-grade carotid stenosis. North American Symptomatic Carotid Endarterectomy Trial Collaborators. *N Engl J Med* 1991; 325: 445-453.
2. Barnett HJ, Taylor DW, Eliasziw M, et al. Benefit of carotid endarterectomy in patients with symptomatic moderate or severe stenosis. North American Symptomatic Carotid Endarterectomy Trial Collaborators. *N Engl J Med* 1998; 339: 1415-1425.
3. MRC European Carotid Surgery Trial: interim results for symptomatic patients with severe (70-99%) or with mild (0-29%) carotid stenosis. European Carotid Surgery Trialists' Collaborative Group. *Lancet* 1991; 337: 1235-1243.
4. Mayberg MR, Wilson SE, Yatsu F, et al. Carotid endarterectomy and prevention of cerebral ischemia in symptomatic carotid stenosis. Veterans Affairs Cooperative Studies Program 309 Trialist Group *Jama* 1991;266:3289-3294.
5. Hobson RW 2nd, Weiss DG, Fields WS, et al. Efficacy of carotid endarterectomy for asymptomatic carotid stenosis. The Veterans Affairs Cooperative Study Group. *N Engl J Med* 1993; 328: 221-227.
6. Endarterectomy for asymptomatic carotid artery stenosis. Executive Committee for the Asymptomatic Carotid Atherosclerosis Study. *Jama* 1995; 273: 1421-1428.
7. LaMuraglia GM, Brewster DC, Moncure AC, et

- al. Carotid endarterectomy at the millennium: what interventional therapy must match. *Ann Surg* 2004; 240: 535-544; discussion 544-546.
8. Feasby TE, Kennedy J, Quan H, et al. Real-world replication of randomized controlled trial results for carotid endarterectomy. *Arch Neurol* 2007; 64: 1496-1500.
9. Long GW, Nuthakki V, Bove PG, et al. Contemporary outcomes for carotid endarterectomy at a large community-based academic health center. *Ann Vasc Surg* 2007; 21: 321-327.
10. Crawford RS, Chung TK, Hodgman T, et al. Restenosis after eversion vs patch closure carotid endarterectomy. *J Vasc Surg* 2007; 46: 41-48.
11. Moore WS, Barnett HJ, Beebe HG, et al. Guidelines for carotid endarterectomy. A multidisciplinary consensus statement from the Ad Hoc Committee, American Heart Association. *Circulation* 1995; 91: 566-579.
12. Biller J, Feinberg WM, Castaldo JE, et al. Guidelines for carotid endarterectomy: a statement for healthcare professionals from a Special Writing Group of the Stroke Council, American Heart Association. *Circulation* 1998; 97: 501-509.
13. Linee Guida SICVE: patologia carotidea e dei tronchi sopra-aortici. *G. Ital. Chir. Vasc.* 2000; 14: 14-21.
14. Pruner G, Castellano R, Jannello AM, et al. Carotid endarterectomy in the octogenarian: outcomes of 345 procedures performed from 1995-2000. *Cardiovasc Surg* 2003; 11: 105-112.
15. Kazmers A, Perkins AJ, Huber TS, Jacobs LA. Carotid surgery in octogenarians in Veterans Affairs medical centers. *J Surg Res* 1999; 81: 87-90.
16. Manton KG, Vaupel JW. Survival after the age of 80 in the United States, Sweden, France, England, and Japan. *N Engl J Med* 1995; 333: 1232-1235.
17. Van der Mieren G, Duchateau J, De Vleeschauer P, De Leersnijder J. The case for urgent carotid endarterectomy. *Acta Chir Belg* 2005; 105: 403-406.
18. Peiper C, Nowack J, Ktenidis K, et al. Prophylactic urgent revascularization of the internal carotid artery in the symptomatic patient. *Vasa* 2001; 30: 247-251.
19. Huber R, Muller BT, Seitz RJ, et al. Carotid surgery in acute symptomatic patients. *Eur J Vasc Endovasc Surg* 2003; 25: 60-67.
20. Musser DJ, Calligaro KD, Dougherty MJ, et al. Safety and cost-efficiency of 24-hour hospitalization for carotid endarterectomy. *Ann Vasc Surg* 1996; 10: 143-146.
21. Maldonado TS. What are current preprocedure imaging requirements for carotid artery stenting and carotid endarterectomy: have magnetic resonance angiography and computed tomographic angiography made a difference? *Semin Vasc Surg* 2007; 20: 205-215.
22. Ballotta E, Da Giau G, Abbruzzese E, et al. Carotid endarterectomy without angiography: can clinical evaluation and duplex ultrasonographic scanning alone replace traditional arteriography for carotid surgery workup? A prospective study. *Surgery* 1999; 126: 20-27.
23. Loftus IM, McCarthy MJ, Pau H, et al. Carotid endarterectomy without angiography does not compromise operative outcome. *Eur J Vasc Endovasc Surg* 1998; 16: 489-493.
24. Wain RA, Lyon RT, Veith FJ, et al. Accuracy of duplex ultrasound in evaluating carotid artery anatomy before endarterectomy. *J Vasc Surg* 1998; 27: 235-242; discussion 242-4
25. Ricotta JJ, Ouriel K, Green RM, DeWeese JA. Use of computerized cerebral tomography in selection of patients for elective and urgent carotid endarterectomy. *Ann Surg* 1985; 202: 783-787.
26. Feringa HH, Karagiannis SE, Vidakovic R, et al. The prevalence and prognosis of unrecognized myocardial infarction and silent myocardial ischemia in patients undergoing major vascular surgery. *Coron Artery Dis* 2007; 18: 571-576.
27. Landesberg G, Wolf Y, Schechter D, et al. Preoperative thallium scanning, selective coronary revascularization, and long-term survival after carotid endarterectomy. *Stroke* 1998; 29: 2541-2548.
28. Klonaris CN, Bastounis EA, Xiromeritis NC, Balas PE. The predictive value of dipyridamole-thallium scintigraphy for cardiac risk assessment before major vascular surgery. *Int Angiol* 1998; 17: 171-178.
29. Comerota AJ, Thakur S. Antiplatelet therapy for vascular interventions. *Perspect Vasc Surg Endovasc Ther* 2008; 20: 28-35.
30. Gough MJ, Bodenham A, Horrocks M, et al. GALA: an international multicentre randomised trial comparing general anaesthesia

- versus local anaesthesia for carotid surgery. *Trials* 2008; 9: 28.
31. Guay J. Regional anesthesia for carotid surgery. *Curr Opin Anaesthesiol* 2008; 21: 638-644.
 32. Ascher E, Hingorani A, Marks N, et al. Mini skin incision for carotid endarterectomy (CEA): a new and safe alternative to the standard approach. *J Vasc Surg* 2005; 42: 1089-1093.
 33. Byrne J, Feustel P, Darling RC 3rd. Primary closure, routine patching, and eversion endarterectomy: what is the current state of the literature supporting use of these techniques? *Semin Vasc Surg* 2007; 20: 226-235.
 34. Cao P, De Rango P, Cieri E, Giordano G. Eversion versus conventional endarterectomy. *Semin Vasc Surg* 2004; 17: 236-242.
 35. Lennard N, Smith JL, Gaunt ME, et al. A policy of quality control assessment helps to reduce the risk of intraoperative stroke during carotid endarterectomy. *Eur J Vasc Endovasc Surg* 1999; 17: 234-240.
 36. Westerband A, Mills JL, Berman SS, Hunter GC. The influence of routine completion arteriography on outcome following carotid endarterectomy. *Ann Vasc Surg* 1997; 11: 14-19.
 37. Groudine SB, Sakawi Y, Patel MK, et al. Low-dose heparin appears safe and can eliminate protamine use for carotid endarterectomy. *J Cardiothorac Vasc Anesth* 1998; 12: 295-298.
 38. Self DD, Bryson GL, Sullivan PJ. Risk factors for post-carotid endarterectomy hematoma formation. *Can J Anaesth* 1999; 46: 635-640.
 39. Fearn SJ, Parry AD, Picton AJ, et al. Should heparin be reversed after carotid endarterectomy? A randomised prospective trial. *Eur J Vasc Endovasc Surg* 1997; 13: 394-397.
 40. Sheehan MK, Baker WH, Littooy FN, et al. Timing of postcarotid complications: a guide to safe discharge planning. *J Vasc Surg* 2001; 34: 13-16.
 41. Perler BA, Dardik A, Burleyson GP, et al. Influence of age and hospital volume on the results of carotid endarterectomy: a statewide analysis of 9918 cases. *J Vasc Surg* 1998; 27: 25-31; discussion 31-3.
 42. Marrocco-Trischitta MM, Melissano G, Kahlberg A, et al. Increased incidence of cerebral clamping ischemia during early contralateral carotid endarterectomy. *J Vasc Surg* 2006; 43: 1155-1161.
 43. Dalainas I, Nano G, Bianchi P, et al. Carotid endarterectomy in patients with contralateral carotid artery occlusion. *Ann Vasc Surg* 2007; 21: 16-22.
 44. Lal BK. Recurrent carotid stenosis after CEA and CAS: diagnosis and management. *Semin Vasc Surg* 2007; 20: 259-266.