

## Case Report

# Homozygous delta-beta Thalassemia in a Child: a Rare Cause of Elevated Fetal Hemoglobin

Verma S MD<sup>1</sup>, Bhargava M MD<sup>2</sup>, Mittal SK MD<sup>3</sup>, Gupta R MD<sup>4</sup>

1. Senior Resident, Department of Pathology, Chacha Nehru Bal Chikitsalaya, Delhi, India.

2. Consultant Pathologist, Department of Pathology, Pushpanjali Crosslay Hospital, India.

3. Director & Senior Consultant, Department of Pediatrics, Pushpanjali Crosslay Hospital, India.

4. Assistant Professor and Head, Departments of Pathology, Chacha Nehru Bal Chikitsalaya, Delhi, India.

Received: 15 November 2012

Accepted: 26 January 2013

### Abstract

#### Background

Delta beta ( $\delta\beta$ ) thalassemia is an unusual variant of thalassemia with elevated level of fetal hemoglobin (HbF). Homozygous patients of this disorder, unlike  $\beta$ -thalassemia, show mild anemia. Only few cases of  $\delta\beta$ -thalassemia have been reported from India in the available indexed English literature.

#### Case presentation

A four-year old male child was evaluated for recent-onset jaundice. Hematological investigations showed mild anemia with microcytic hypochromic red cells. A comprehensive analysis of hemoglobin by high-performance liquid chromatography (HPLC) showed

complete absence of HbA and HbA<sub>2</sub> with HbF constituting 100% of the hemoglobin. Hemoglobin analysis of both parents showed elevated level of HbF with normal HbA<sub>2</sub>. A final diagnosis of  $\delta\beta$ -thalassemia in the child with both parents being carriers was rendered.

#### Conclusion

Delta beta-thalassemia is an uncommon cause of markedly elevated fetal hemoglobin beyond fetal period. Clinical and haematological parameters should be evaluated to render an accurate diagnosis.

#### Key Words

Delta-Beta Thalassemia ;Homozygote; Chromatography, High Pressure Liquid

### Corresponding Author

Ruchika Gupta, Department of Pathology, Chacha Nehru Bal Chikitsalaya (Associate Hospital of Maulana Azad Medical College), Geeta Colony, Delhi (India), E-mail: ruchika257@yahoo.com

### Introduction

Delta beta ( $\delta\beta$ ) thalassemia is an infrequent cause of elevated fetal hemoglobin (HbF) beyond infancy. This disorder is characterized by reduction in production of both  $\delta$  and  $\beta$ -globin chains, usually due to deletions of  $\delta$  and  $\beta$  structural genes (1). Delta beta ( $\delta\beta$ ) thalassemia mutations have been reported in various ethnic groups, like Turkish, German, Japanese, Sicilian and Spanish (2). Non-deletional  $\delta\beta$ -thalassemia has also been described recently (3). Unlike classical  $\beta$ -thalassemia, the clinical presentation of  $\delta\beta$ -thalassemia is mild in both heterozygotes and rare homozygote patients. However, the thalassemic red cell indices in combination with hemoglobin analysis (electrophoresis or HPLC) showing elevated HbF with normal HbA<sub>2</sub> in heterozygotes and absence of HbA and HbA<sub>2</sub> in homozygotes help in suggesting

the diagnosis (4). Mutation analysis is the confirmatory test for diagnosis of this rare disorder (4). The main differential diagnosis of homozygous  $\delta\beta$ -thalassemia includes homozygous hereditary persistence of fetal hemoglobin (HPFH), since both these disorders show 100% HbF (5). The clinical findings of mild anemia with haemolytic features (reticulocytosis, indirect hyperbilirubinemia, and reduced haptoglobin) rules in favour of  $\delta\beta$ -thalassemia rather than HPFH (6). Family studies of both parents also show thalassemic red cell indices, with or without anemia and elevation in HbF up to 30% in heterozygotes for  $\delta\beta$ -thalassemia (6). Other diagnostic possibilities of 100% HbF include variants of homozygous  $\beta$ -thalassemia and double heterozygosity for  $\delta\beta$ -thalassemia and classical  $\beta$ -thalassemia (5,6).

We describe the clinical and haematological features of a young male child with this rare disorder and discuss the relevant literature.

### Case Presentation

A 4-year male child was referred for further evaluation of acute onset jaundice of 7-8 days duration. There was a history of intermittent diarrhoea since the last four months. However, no other associated urinary complaint was present. There was no history of prior blood transfusion.

On general examination, the child was thinly built. He was pale and had icterus. Liver was palpable 1cm below right costal margin soft and non-tender, and spleen 3 cm below left costal margin. There was no peripheral lymphadenopathy or ascites. Other systemic examinations were unremarkable.

Liver function tests were normal except for an elevated total serum bilirubin (3.5mg/dl) and indirect bilirubin (2.8mg/dl). Hepatitis markers were negative. Serum ceruloplasmin was 28 mg/dl. Hematological investigations revealed mild anemia (hemoglobin 9.8 g/dl) with normal leukocyte and platelet count. Peripheral smear examination showed microcytic hypochromic red cells with target cells and polychromasia (Fig. 1a,b). Few nucleated red cells (4/100 WBC) and basophilic stippling were also

noted. Reticulocyte count was high (6%). No microspherocytes or acanthocytes were seen in the blood smear. Further work-up for haemolytic anemia was undertaken. G-6-PD screening test, direct Coombs' test and sickling tests were negative. An HPLC analysis was carried out, which revealed 100% HbF with absence of HbA and HbA<sub>2</sub> (Fig. 1c). The salient investigations are given in Table I.

Subsequently, HPLC of parents was also performed. Both parents had elevated level of HbF (19.2% and 16.0%) with normal HbA<sub>2</sub> levels. The smear of both parents also showed hypochromia and target cells (Fig. 2a-d). A history of first-degree consanguineous marriage was elicited.

In view of the peripheral blood findings of haemolytic anemia with 100% HbF, a diagnosis of homozygous delta-beta thalassemia was rendered and genetic analysis was advised. The genetic analysis could not be performed due to financial constraints.

Table I: Hematological parameters of patient with delta-beta thalassemia

Parameters	Patient	Father	Mother
Hemoglobin (g/dl)	9.8	15.0	12.2
RBC count (million/mm <sup>3</sup> )	4.61	5.84	5.27
MCV (fl)	76.4	85.0	74.2
MCHC (pg)	27.7	30.1	31.2
RDW-CV (%)	17.3	15.4	17.0
G6PD screening test	NEGATIVE	-	-
HPLC	HbF 100%	F 19.2%	F 16.0%
	HbA 0%	A <sub>2</sub> 2.7%	A <sub>2</sub> 2.9%
	HbA <sub>2</sub> 0%		
SGOT (IU/L)	35	-	-
SGPT (IU/L)	48		
Alkaline phosphatase (IU/L)	144	-	-
S. bilirubin total (mg/dl)	5.6	-	-
Direct bilirubin (mg/dl)	0.6		
Indirect bilirubin (mg/dl)	5.0		

MCV: mean corpuscular volume; MCHC: mean corpuscular hemoglobin concentration; RDW-CV: red cell distribution width- coefficient of variation; G6PD: glucose-6-phosphate dehydrogenase; HPLC: high performance liquid chromatography; SGOT: serum glutamate oxaloacetate dehydrogenase; SGPT: serum glutamate pyruvate dehydrogenase; HbF: hemoglobin F (fetal); HbA: adult hemoglobin

## Discussion

Delta-beta thalassemia ( $\delta\beta$ -thalassemia), a relatively rare form of thalassemia, is characterized by lack of  $\beta$  and  $\delta$ -globin chain production (1,4). This reduction in production is usually caused by deletion of  $\delta$  and  $\beta$  structural genes(7). Non-deletional  $\delta\beta$ -thalassemia has also been described, which results from presence in cis of 2 different nucleotide substitutions in promoter of  $A\gamma$  and  $\beta$ -globin gene(7). Studies of globin chain synthesis have shown that  $\alpha$ /non- $\alpha$  chain imbalance in  $\delta\beta$ -thalassemia is less pronounced than in  $\beta$ -thalassemia(8). Mutations responsible for  $\delta\beta$ -

thalassemia have been observed in different ethnic groups, including Turkish, German, Japanese, Black,

Sicilian and Spanish type deletion mutations(2). Heterozygotes for  $\delta\beta$ -thalassemia are found to have thalassemic red cell indices (high RBC count, low MCV and MCH), normal or reduced HbA<sub>2</sub> levels and increased amounts of fetal hemoglobin. The HbF is heterogeneously distributed among red blood cells (heterocellular distribution of HbF).<sup>3</sup> Rare homozygous patients present clinically as either thalassemia intermedia or silent phenotype. Regardless of the clinical presentation, there is

thalassemic red cell morphology (microcytic hypochromic anemia with erythrocytosis, high reticulocyte count) along with biochemical evidence of hemolytic anemia (indirect hyperbilirubinemia and reduced serum haptoglobin). This syndrome has also been termed variously as F-thalassemia,  $\beta$ -thalassemia type 2 and normal  $A_2$   $\beta$ -thalassemia (9). Earlier authors have described families with homozygous  $\delta\beta$ -thalassemic siblings presenting either with mild anemia and hepatosplenomegaly or as clinically normal without anemia or splenomegaly (9,10). The child in the current study was homozygous for  $\delta\beta$ -thalassemic and did not have any siblings. However, both of his parents were heterozygous for  $\delta\beta$ -thalassemia. Although the exact diagnosis of  $\delta\beta$ -thalassemia requires genetic analysis for mutations, hemoglobin electrophoresis or HPLC finding of markedly elevated HbF may be suggestive. Complete absence of HbA with presence of HbF as the single or main hemoglobin component beyond fetal period occurs in four genetic disorders: some variants of homozygous  $\beta$ -thalassemia, some cases of double heterozygosity for  $\delta\beta$ -thalassemia and classical  $\beta$ -thalassemia, homozygous patients of hereditary persistence of fetal hemoglobin (HPFH) and homozygous  $\delta\beta$ -thalassemia (4,5,11,12). These conditions can be differentiated on the basis of clinical and hematological features.

Homozygous  $\beta$ -thalassemia usually presents with severe anemia while  $\delta\beta$ -thalassemia, even in homozygous patients, shows mild anemia or are in compensated hemolytic process. Homozygotes of HPFH are clinically normal. The normal HbA<sub>2</sub> levels in both parents exclude the possibility of homozygous  $\beta$ -thalassemia or double heterozygosity for  $\beta$ -thalassemia and  $\delta\beta$ -thalassemia in the present case. Hence, the differential diagnosis lies between homozygous  $\delta\beta$ -thalassemia and HPFH.

The red cell morphology in the present case (microcytic hypochromic with target cells, polychromasia and reticulocytosis) is suggestive of  $\delta\beta$ -thalassemia, since homozygous HPFH shows only a few target cells with normocytic normochromic picture (5). The presence of haemolytic picture in the present case rules out homozygous HPFH. Hemoglobin HPLC of parents, heterozygous for the disorder, showed HbF of 16% and 19%, which are low for heterozygotes of African type HPFH (usually 20-40%) (5). In addition, the red cell indices were of thallemic type in both parents, again favouring heterozygosity for  $\delta\beta$ -thalassemia.

An extensive PubMed search yielded only few reports of  $\delta\beta$ -thalassemia in Indian families, especially from eastern and western India (13,15). Since hemoglobin HPLC is increasingly becoming

available at more institutions across the country, this rare disorder should be kept in mind in cases with elevated HbF.

### Conclusion

This case highlights the importance of considering  $\delta\beta$ -thalassemia in presence of elevated HbF and normal or reduced HbA<sub>2</sub>. Careful review of clinical and haematological features assists in differentiation of this rare disorder from HPFH.

### Acknowledgment

The authors are grateful to Mr. Dinesh for technical assistance in HPLC analysis.

### Conflict of interest

The authors have no conflict of interest.

### References

1. Comings DE, Motulsky AG. Absence of cis delta chain synthesis in (sigma beta) thalassemia (F-thalassemia). *Blood* 1966;28:54-69.
2. Carrocini GC, Ondeï LS, Zamaro PJ, Bonini-Domingos CR. Evaluation of HPFH and delta beta thalassemia mutations in a Brazilian group with high HbF levels. *Genet Mol Res* 2011;10:3213-9.
3. Pirastu M, Kan YW, Galanello R, Cao A. Multiple mutations produce delta beta 0 thalassemia in Sardinia. *Science* 1984;223:929-30.
4. Cao A, Melis MA, Galanello R, Angius A, Furbetta M, Giordano P, et al. Delta beta (F)-thalassaemia in Sardinia. *J Med Genet* 1982;19:184-92.
5. Wolff JA, Ignatov VG. Heterogeneity of thalassemia major. *Am J Dis Child* 1963;105:234-42.
6. Conley CL, Weatherall DJ, Richardson SN, Shepard MK, Charache S. Hereditary persistence of fetal hemoglobin: a study of 79 affected persons in 15 Negro families in Baltimore. *Blood* 1963;21:261-81.
7. Ottolenghi S, Comi P, Giglioni B, Tolstoshev P, Lanyon WG, Mitchell GJ, et al. Delta-beta-thalassemia is due to a gene deletion. *Cell* 1976;9:71-80.
8. Kinney TR, Friedman S, Cifuentes E, Kim HC, Schwartz E. Variations in globin synthesis in delta-beta-thalassaemia. *Br J Haematol* 1978;38:15-22.
9. Ramot B, Ben-Bassat I, Gafni D, Zanoon R. A family with three beta-delta-thalassemia homozygotes. *Blood* 1970;35:158-65.
10. Silvestroni E, Bianco I, Reitano G. Three cases of homozygous beta, delta-thalassemia (or microcythaemia) with high haemoglobin F in a Sicilian family. *Acta Haematol* 1968;40:220-9.
11. Conconi F, Bargellesi A, Pontremoli S, Vigi V, Volpato S, Gaburro D. Absence of beta-globin synthesis and excess of gamma-globin synthesis in homozygous beta-thalassaemic subjects from the Ferrara region. *Nature* 1968;217:259-60.

12. Brancati C, Baglioni C. Homozygous beta-delta thalassaemia (beta-delta microcythaemia). *Nature* 1966;212:262-4.
13. Patel DK, Patel M, Mashon RS, Patel S, Dash PM, Das BS. Clinical and molecular characterization of  $\beta(S)$  and  $(G)\gamma((A)\gamma\delta\beta)^0$ -thalassemia in eastern India. *Hemoglobin* 2010;34:604-9.
14. Nadkarni A, Wadia M, Gorakshakar A, Kiyama R, Colah RB, Mohanty D. Molecular characterization of delta beta-thalassemia and hereditary persistence of fetal hemoglobin in the Indian population. *Hemoglobin* 2008;32:425-33.
15. Agarwal MB, Mehta BC. Delta-beta thalassemia in 36 cases from 14 families. *Indian J Med Res* 1981;73:251-4.

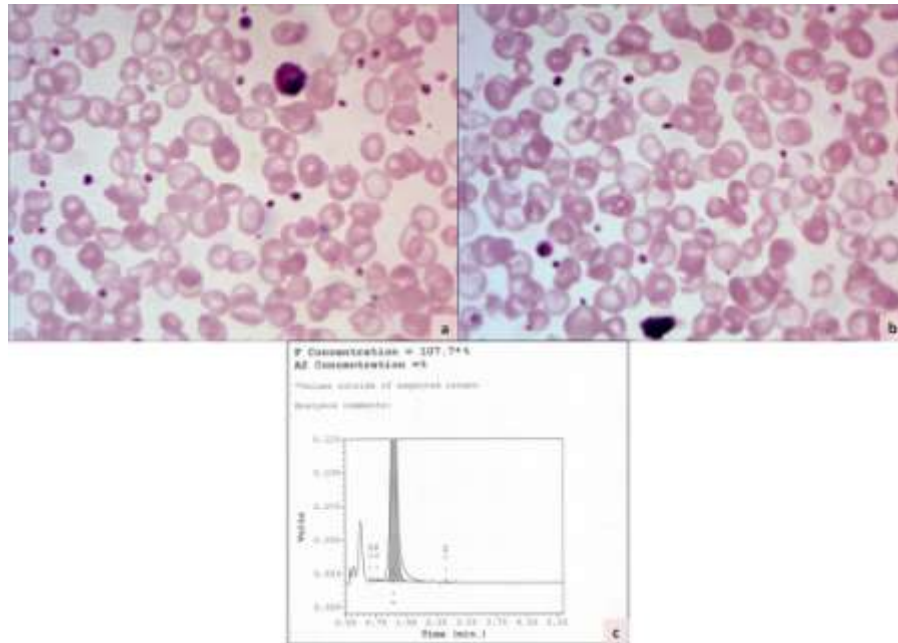


Figure 1. Photomicrographs of peripheral smears of the patient showing microcytic hypochromic red cells with target cells, basophilic stippling and moderate anisopoikilocytosis (a & b, Giemsa x400). HPLC graph demonstrated 100% HbF in the child with absent HbA and HbA<sub>2</sub> (c).

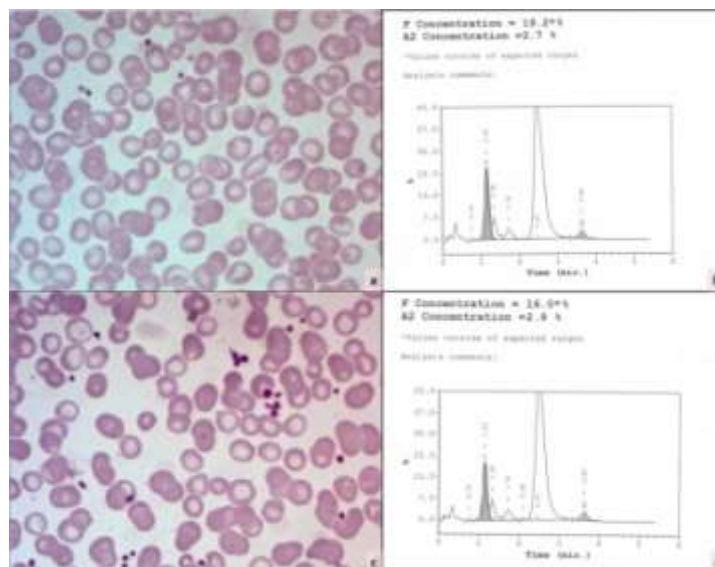


Figure 2. Peripheral blood smear of the father shows few microcytic hypochromic red cells (a, Giemsa x400) while HPLC shows elevated HbF (b). Peripheral blood smear of mother showing microcytic hypochromic red cells and occasional target cells (c, Giemsa x400) and HPLC graph with HbF of 16.0% (d).