

# Segmental left atrial appendage electrical isolation to avoid left phrenic nerve damage



Jorge Romero, MD, FHRS, Nicola Tarantino, MD, Roberto Cerrud-Rodriguez, MD, Isabella Alviz, MD, Vito Gruppisso, RT, Luigi Di Biase, MD, PhD, FHRS

*From the Montefiore-Einstein Center for Heart and Vascular Care, Montefiore Medical Center, Albert Einstein College of Medicine, Bronx, New York.*

## Introduction

The initiation of atrial fibrillation (AF) is triggered by focal circuits localized in the pulmonary veins (PVs) and sometimes outside the PVs.<sup>1</sup> The left atrial appendage (LAA) plays a considerable role in the arrhythmogenesis of persistent and long-standing persistent AF (LSPAF), and its isolation confers significant clinical benefits, as evidenced by a series of studies.<sup>2-4</sup> However, the anatomical proximity to the left phrenic nerve (LPN) might induce the electrophysiologists to refrain from isolating the LAA using standard technique at the ostial level.<sup>5</sup> Herein, we describe a successful case of recurrent paroxysmal AF in which the LPN was localized at the LAA ostial level and compartmental electrical isolation of the LAA using radiofrequency ablation (RFA) was performed sparing the LPN thanks to identification of the anatomical path with pace-mapping.

## Case report

The case involves an 87-year-old woman with a history of hypertension and LSPAF over the past 7 years. The patient had initially been treated with Tikosyn (dofetilide) but she was admitted to our institution with severe palpitations and heart rate oscillating between 150 and 170 beats/min. She underwent a total of 10 electrical cardioversions, but she persisted in AF with rapid ventricular response despite being partially loaded with amiodarone (5 g). She subsequently underwent isolation of all 4 PVs and posterior wall (PW) with RFA. She presented to our clinic complaining of several episodes of palpitations and presyncope, which were confirmed by event monitor. Amiodarone was stopped owing to severe skin allergy. Her left ventricular ejection fraction was preserved. Baseline electrocardiogram showed sinus rhythm with sporadic premature atrial complexes. Her

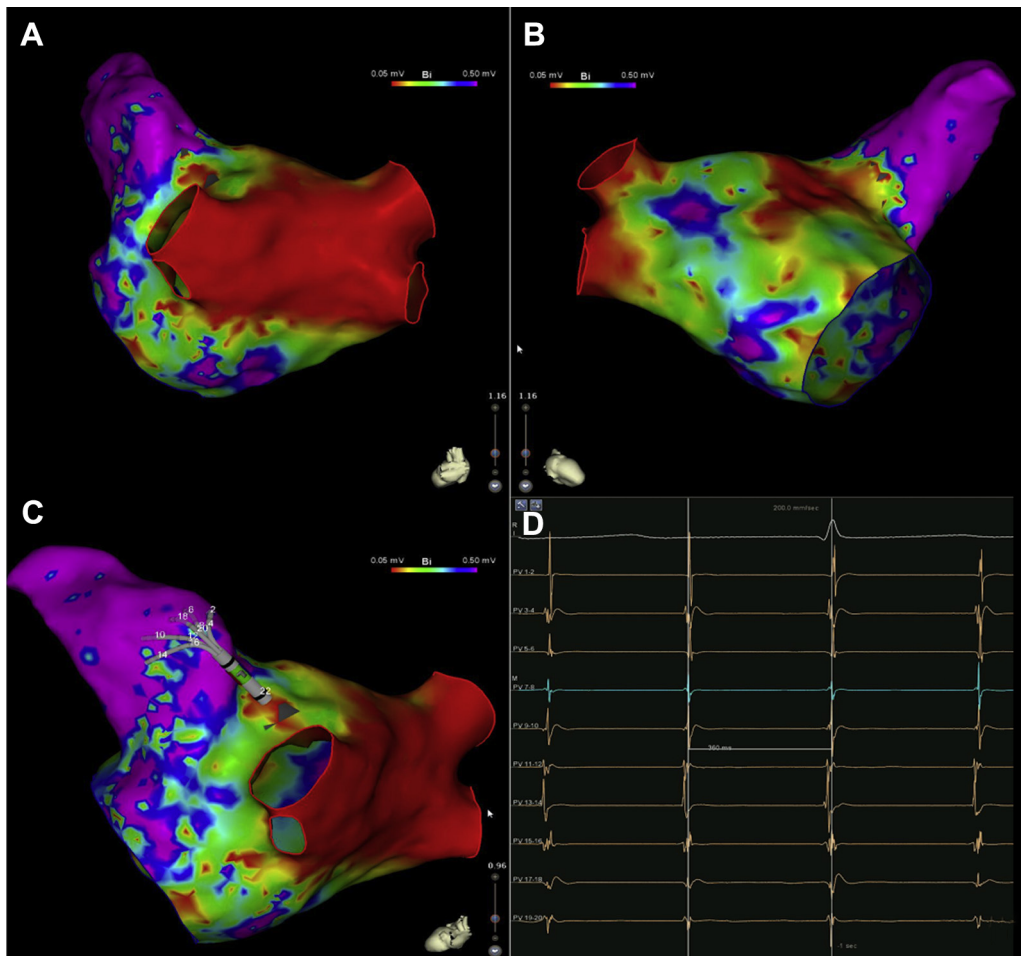
## KEY TEACHING POINTS

- In some cases, the left phrenic nerve (LPN) is in the vicinity of the left atrial appendage (LAA) ostium, which renders the circumferential electrical isolation of the LAA with radiofrequency particularly challenging.
- Routine localization of LPN with high-output pacing should be performed during LAA electrical isolation.
- If the LPN is located in the vicinity of the LAA ostium, segmental LAA electrical isolation is feasible and safe.

CHA<sub>2</sub>DS<sub>2</sub>VASC score was 5, indicating a 7.2% annual risk of stroke. She was on thromboembolic prophylaxis with warfarin. She was thus started on dofetilide 250 mg daily as an antiarrhythmic, without improvement of her symptoms. For this reason, the patient was brought to the electrophysiology laboratory for a second procedure. An 8F duodecapolar (Abbott-St. Jude, Medical, St. Paul, MN) catheter was looped in the right atrium along the crista terminalis and in the coronary sinus (CS) for pacing and recording, while a 10F SoundStar catheter of 10 MHz (Biosense Webster, Irvine, CA) was placed in the right atrium through the left femoral vein for intracardiac echography guidance. A fluoroless transseptal access was obtained using an Agilis sheath (Abbott-St. Jude Medical, St. Paul, MN) and a SafeSept transseptal guidewire. Through the Agilis sheath, an 8F multielectrode catheter (PentaRay, Biosense Webster, Irvine, CA) was advanced in the left atrium (LA) and a 3-dimensional shell representing the LA and PVs was constructed using the CartoSound mapping system. A preprocedure cardiac computed tomography (CT) scan was merged with the electroanatomic shell created by ultrasound reconstruction and catheter manipulation in the LA. Esophageal position was monitored using intracardiac ultrasound guidance and temperature probe. Voltage mapping of the LA revealed diffuse scar tissue over the anterior, inferior, septal,

**KEYWORDS** Atrial fibrillation; Complications; Left atrial appendage; Pace-mapping; Phrenic nerve  
(Heart Rhythm Case Reports 2019;5:269-273)

**Address reprint requests and correspondence:** Dr Jorge Romero, Montefiore-Einstein Center for Heart and Vascular Care, Montefiore Medical Center, Albert Einstein College of Medicine, 2814 Middletown Rd, Bronx, NY 10461. E-mail address: [drromero28@hotmail.com](mailto:drromero28@hotmail.com).



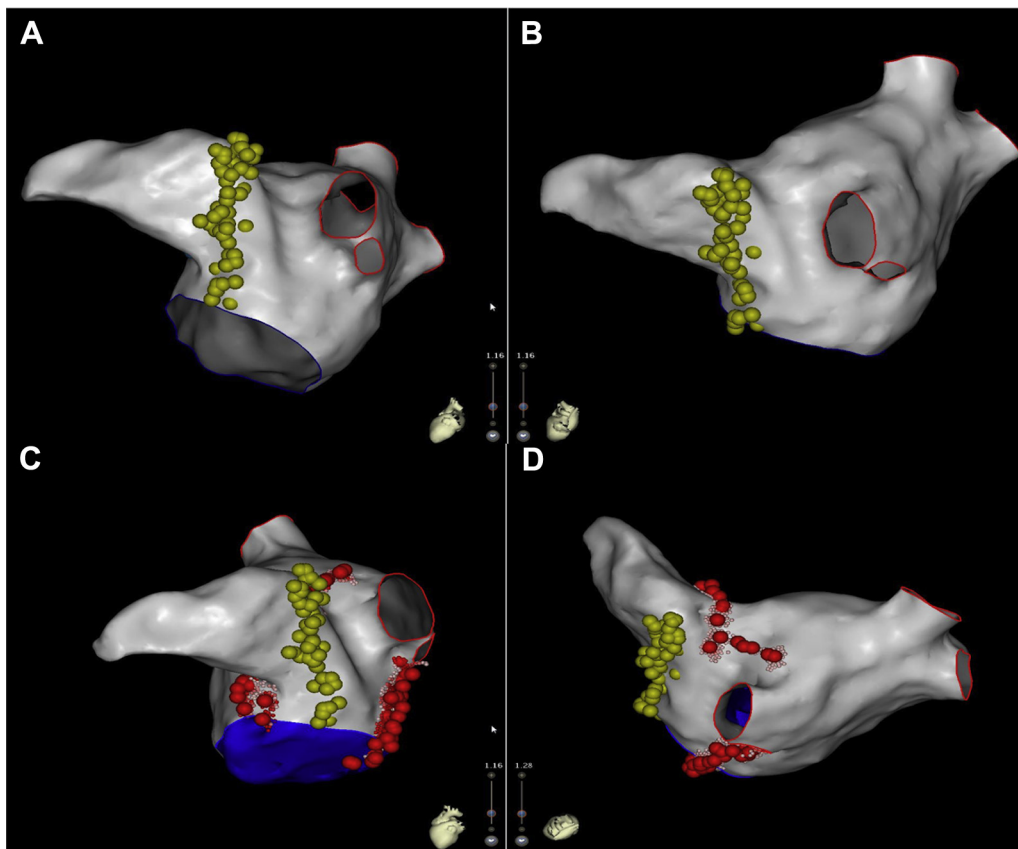
**Figure 1** Electroanatomical mapping of the left atrium. **A:** Posteroanterior view; **B:** anteroposterior view; and **C:** left lateral view showing complete isolation of all 4 pulmonary veins and electrical isolation of the posterior wall from initial ablation procedure. However, patchy areas of low voltage were detected all around the ostial region of the left atrial appendage, from which atrial tachycardia was easily inducible while manipulating the catheters (**D**). Likewise, areas of low voltage were also seen in the anterior, inferior, septal, and lateral left atrial walls.

and lateral LA walls. All 4 PVs and PW were silent from prior procedures, as demonstrated by voltage mapping showing bidirectional conduction block in these areas (Figure 1A–C). The superior vena cava was silent. Several arrhythmogenic potentials were noted to be originating from a large LAA (Figure 1D), from which several atrial tachycardias and episodes of AF were also induced with catheter manipulation. The LAA had a chicken wing morphology and measured 1.8 cm × 2.75 cm as per the preprocedural CT scan. A ThermoCool SmartTouch DF SF BiDir (Biosense Webster, Irvine, CA) was used to identify the LPN trajectory using high-output pacing (20 mA at 2 ms). Figure 2A and B shows the close anatomical relationship of the LPN to the posterobasal LAA wall. The LPN actually crosses the ostium of this structure, rendering delivering of radiofrequency energy at the ostial level unfeasible. Therefore, in order to avoid areas of LPN capture owing to the high risk of unilateral phrenic nerve paralysis, the decision was made to isolate the LAA by creating posterolateral and anterior mitral isthmus lines, instead of performing a full circumferential ostial isolation, thus sparing the posterobasal segment of the LAA ostium (Figure 2C and D). Radiofrequency energy

was applied with a target temperature of less than 42°C and target power of 30–40 W until obtaining >80% reduction of electrical potentials amplitude and at least 10 ohms in impedance drop. Up to 30 seconds was spent for each single lesion. Further radiofrequency focal lesions within the CS were required. The initial 20 W of radiofrequency delivery in the distal CS appeared unsuccessful; therefore we increased the power up to 30 W, achieving satisfactory potential defragmentation. A total of 77 lesions (45 minutes) were delivered. After the ablation, no AF was inducible with atrial stimulation with and without isoproterenol infusion. No LAA acute reconnection was evident after 30 minutes of observation and LAA appeared completely silent at the voltage map (Figure 3). No complications were encountered. At 6-month follow-up, the patient remains symptom free and in normal sinus rhythm on a low dose of Tikosyn (125 mg twice a day) and warfarin for stroke prevention.

## Discussion

To the best of our knowledge, this is the first case report of a successful segmental LAA electrical isolation (LAAEI)



**Figure 2** A, B: High-output pace-mapping (20 mA @ 2 ms) identified an extensive area of anatomical contact between the left phrenic nerve (LPN) and the whole posterior and superior aspects of the left atrial appendage (LAA) ostium (yellow dots in A and B). Notice that LAA electrical isolation at the ostial level is not feasible in this case, given the fact the left phrenic nerve crosses the inferior ostial margin of the LAA. (A: Left lateral view. B: Modified posterior view of the left atrium.) C, D: Segmental isolation of the LAA was performed by delivering radiofrequency ablation along the posterolateral (left inferior pulmonary vein) and anterior (left superior pulmonary vein) mitral isthmus lines (red dots in C and D). (C: Left lateral view. D: Modified posterior view of the left atrium.)

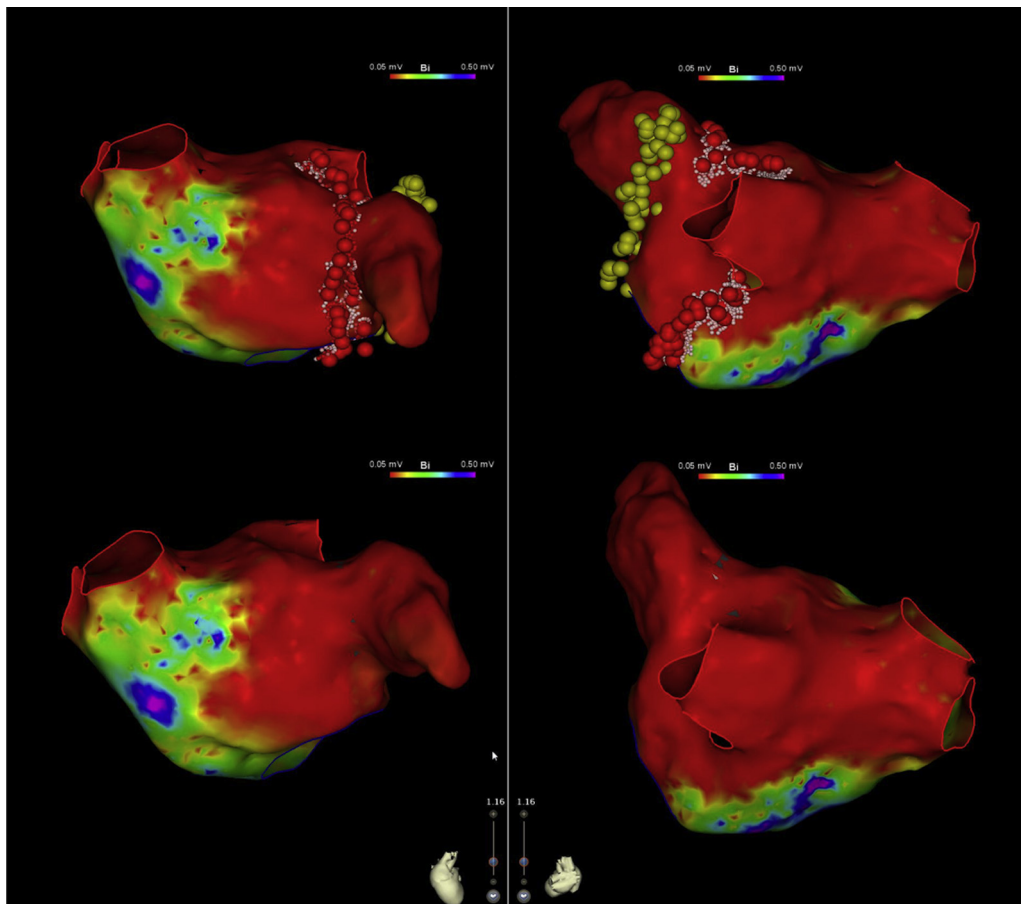
intentionally performed to prevent LPN damage. The involvement of the LAA in the triggering and perpetuation of persistent AF is of relatively recent awareness, when Di Biase and colleagues<sup>2</sup> (2010) reported the prevalence of AF triggers in the LAA, enrolling a cohort of 987 consecutive patients for redo catheter ablation of AF.

These encouraging findings were subsequently confirmed with an open-label randomized trial, the BELIEF trial (2016), which sought to assess if empirical LAAEI along with extensive ablation could improve freedom from AF in patients with LSPAF when compared with extensive ablation alone. The results showed that after a first procedure, as well as after a redo procedure, there was a statistically significant benefit of the empirical LAAEI in long-term freedom from atrial arrhythmias, without an increase in complications.<sup>3</sup> Likewise, cryotherapy for empiric LAAEI was able to provide significant benefit in freedom from atrial tachyarrhythmias at 12-month follow-up, when compared to PV isolation alone (86% vs 67%,  $P < .001$ ).<sup>6</sup> A meta-analysis by Romero and colleagues<sup>4</sup> (2018), including 7 papers that enrolled a total of 930 patients, showed findings consistent with the previous studies. The overall freedom from recurrence of all arrhythmias at 12-month follow-up was 75.5% in the LAAEI group vs 43.9% in the standard ablation-only cohort, with

an absolute and relative reduction of 31% and 56%, respectively (risk ratio 0.44, 95% confidence interval 0.31–0.64;  $P < .001$ ). Although in this meta-analysis the incidence of LPN injury was extremely low and only seen during cryoballoon ablation, it is well known that the LPN runs very close to the LAA PW. The LPN typically descends on the fibrous pericardium, taking different courses over the LAA, as demonstrated by Randhawa and associates<sup>7</sup> using cadaveric human hearts from donors: in this study, the LPN crossed the LAA anteriorly in 30% of cases, laterally in 67%, and posteriorly only in 3%.

Regarding the technical aspects, it is considered safer to perform the isolation at the level of the LAA ostium, which is thicker.<sup>8</sup> Although no phrenic nerve palsy was seen in the series by Di Biase and colleagues<sup>2</sup> utilizing a dragging approach to achieve LAA isolation, we believe the current case report is clinically relevant because it highlights how to prevent LPN damage.

In our case, given the anatomical close relationship with the LPN, a segmental strategy was considered to be the safest approach. The LPN is a sensory-motor nerve originating from the cervical plexus (C3–C5), running epicardially in the pericardiophrenic bundle along with vein and artery, supplying motor fibers only to the diaphragm.



**Figure 3** After left atrial appendage electrical isolation was performed, a new voltage map was obtained, showing complete isolation of the left atrial appendage, posterior wall, and all 4 pulmonary veins.

The most recently estimated risk of phrenic nerve injury during ablation of AF (in the Fire and Ice trial of 2016) is between 0 and 2.7%; the highest risk is seen with cryoballoon therapy, whereas the lowest risk is seen in the RFA group.<sup>9</sup>

We must keep in mind that, regardless of the source of energy adopted, there are several possible anatomical variations. Therefore, it is of the utmost importance to determine the spatial relationship between the LPN and the LAA before performing LAAEI. Multidetector CT can be used for preprocedural assessment of cardiac anatomy, with the caveat that it will be unable to identify the LPN in up to 26% of patients, especially in elderly women.<sup>10</sup> It is also plausible to consider that advanced imaging modalities are not available in every center and that given the great variability of nerve course, a real-time identification of the LPN using the pace-mapping technique might be more reliable, given also the fact that the phrenic nerve may actually move. According to a study by Huemer and colleagues<sup>11</sup> (2014), LPN capture by pacing in the LAA showed remarkable individual variations in nerve course. In this study 55% of patients showed phrenic nerve capture in the LAA, with a total phrenic nerve mapping time of  $6 \pm 2$  minutes per patient, using a 10 V/2.9 ms protocol. No cases of phrenic nerve palsy were reported in this study, possibly highlighting the safety and reliability of the LPN pace-mapping.

## Conclusion

Segmented LAAEI along the posterolateral mitral isthmus and anterior lines seems to be an effective technique in case of unfavorable anatomical relationship between LAA and LPN. To date, it is unknown if this approach carries an increased risk of acute and long-term reconnection because no head-to-head comparison between ostial and segmental LAAEI has been conducted. Furthermore, periprocedural pace-mapping appears to be a reliable and safe strategy to identify LPN course and decrease the risk of nerve injury during the ablation procedure.

## References

1. Haïssaguerre M, Jaïs P, Shah DC, et al. Spontaneous initiation of atrial fibrillation by ectopic beats originating in the pulmonary veins. *N Engl J Med* 1998; 339:659–666.
2. Di Biase L, Burkhardt JD, Mohanty P, et al. Left atrial appendage: an underrecognized trigger site of atrial fibrillation. *Circulation* 2010;122:109–118.
3. Di Biase L, Burkhardt JD, Mohanty P, et al. Left atrial appendage isolation in patients with longstanding persistent AF undergoing catheter ablation: BELIEF Trial. *J Am Coll Cardiol* 2016;68:1929–1940.
4. Romero J, Michaud GF, Avendano R, et al. Benefit of left atrial appendage electrical isolation for persistent and long-standing persistent atrial fibrillation: a systematic review and meta-analysis. *Europace* 2018;20:1268–1278.
5. Romero J, Natale A, Di Biase L. How to perform left atrial appendage electrical isolation using radiofrequency ablation. *Heart Rhythm* 2018;15:1577–1582.
6. Yorgun H, Canpolat U, Kocyigit D, Çöteli C, Evranos B, Aytemir K. Left atrial appendage isolation in addition to pulmonary vein isolation in persistent atrial

- fibrillation: one-year clinical outcome after cryoballoon-based ablation. *Europace* 2017;19:758–768.
7. Randhawa A, Sahni D, Aggarwal A, Rohit MK, Sehgal S, Reddy YM. Study of spatial relationship of phrenic nerves with cardiac structures relevant to electrophysiologic interventions. *Pacing Clin Electrophysiol* 2014;37:1477–1484.
  8. Panikker S, Jarman JW, Virmani R, et al. Left atrial appendage electrical isolation and concomitant device occlusion to treat persistent atrial fibrillation: a first-in-human safety, feasibility, and efficacy study. *Circ Arrhythm Electrophysiol* 2016;9:e003710.
  9. Kuck KH, Brugada J, Furnkranz A, et al. Cryoballoon or radiofrequency ablation for paroxysmal atrial fibrillation. *N Engl J Med* 2016;374:2235–2245.
  10. Matsumoto Y, Krishnan S, Fowler SJ, et al. Detection of phrenic nerves and their relation to cardiac anatomy using 64-slice multidetector computed tomography. *Am J Cardiol* 2007;100:133–137.
  11. Huemer M, Wutzler A, Parwani AS, Attanasio P, Haverkamp W, Boldt LH. Mapping of the left-sided phrenic nerve course in patients undergoing left atrial catheter ablations. *Pacing Clin Electrophysiol* 2014; 37:1141–1148.