

## Review Article

### Male reproductive health and infertility

pISSN: 2287-4208 / eISSN: 2287-4690  
World J Mens Health 2022 Apr 40(2): 191-207  
<https://doi.org/10.5534/wjmh.210063>



# Relevance of Leukocytospermia and Semen Culture and Its True Place in Diagnosing and Treating Male Infertility

Rakesh Sharma<sup>1</sup>, Sajal Gupta<sup>1</sup>, Ashok Agarwal<sup>1</sup>, Ralf Henkel<sup>1,2,3</sup>, Renata Finelli<sup>1</sup>, Neel Parekh<sup>4</sup>, Ramadan Saleh<sup>5</sup>, Mohamed Arafa<sup>1,6,12</sup>, Edmund Ko<sup>7</sup>, Armand Zini<sup>8</sup>, Nicholas Tadros<sup>9</sup>, Rupin Shah<sup>10</sup>, Rafael F. Ambar<sup>11</sup>, Haitham Elbardisi<sup>6,12</sup>, Pallav Sengupta<sup>13</sup>, Marlon Martinez<sup>14</sup>, Florence Boitrelle<sup>15,16</sup>, Mara Simopoulou<sup>17</sup>, Paraskevi Vogiatzi<sup>18</sup>, Jaime Gosalvez<sup>19</sup>, Parviz Kavoussi<sup>20</sup>, Hussein Kandil<sup>21</sup>, Ayad Palani<sup>22</sup>, Marcelo Rodriguez Peña<sup>23</sup>, Osvaldo Rajmil<sup>24</sup>, Gian Maria Busetto<sup>25</sup>, Christina Anagnostopoulou<sup>26</sup>, Sava Micic<sup>27</sup>, Marco G. Alves<sup>28</sup>, Lucia Rocco<sup>29</sup>, Taymour Mostafa<sup>30</sup>, Juan G. Alvarez<sup>31,32</sup>, Sunil Jindal<sup>33</sup>, Hassan N. Sallam<sup>34</sup>, Israel Maldonado Rosas<sup>35</sup>, Sheena E.M. Lewis<sup>36</sup>, Sami AlSaid<sup>6</sup>, Mesut Altan<sup>37</sup>, Hyun Jun Park<sup>38,39</sup>, Jonathan Ramsay<sup>40</sup>, Sijo Parekattil<sup>41</sup>, Marjan Sabbaghian<sup>42</sup>, Kelton Tremellen<sup>43</sup>, Kareim Khalafalla<sup>6</sup>, Damayanthi Durairajanayagam<sup>44</sup>, Giovanni M. Colpi<sup>45</sup>

<sup>1</sup>American Center for Reproductive Medicine, Cleveland Clinic, Cleveland, OH, USA, <sup>2</sup>Department of Metabolism, Digestion and Reproduction, Imperial College London, London, UK, <sup>3</sup>Department of Medical Bioscience, University of the Western Cape, Bellville, South Africa, <sup>4</sup>Department of Urology, Cleveland Clinic, Cleveland, OH, USA, <sup>5</sup>Department of Dermatology, Venereology and Andrology, Faculty of Medicine, Sohag University, Sohag, Egypt, <sup>6</sup>Department of Urology, Hamad Medical Corporation, Doha, Qatar, <sup>7</sup>Department of Urology, Loma Linda University Health, Loma Linda, CA, USA, <sup>8</sup>Department of Surgery, McGill University, Montreal, Canada, <sup>9</sup>Division of Urology, Southern Illinois University School of Medicine, Springfield, IL, USA, <sup>10</sup>Department of Urology, Lilavati Hospital and Research Centre, Mumbai, India, <sup>11</sup>Department of Urology, Centro Universitario em Saude do ABC/Andrology Group at Ideia Fertil Institute of Human Reproduction, Santo André, Brazil, <sup>12</sup>Department of Urology, Weill Cornell Medical-Qatar, Doha, Qatar, <sup>13</sup>Department of Physiology, Faculty of Medicine, Bioscience and Nursing, MAHSA University, Jenjarom, Selangor, Malaysia, <sup>14</sup>Section of Urology, University of Santo Tomas Hospital, Manila, Philippines, <sup>15</sup>Reproductive Biology, Fertility Preservation, Andrology, CECOS, Poissy Hospital, Poissy, <sup>16</sup>Paris Saclay University, UVSQ, INRAE, BREED, Jouy-en-Josas, France, <sup>17</sup>Department of Physiology, School of Medicine, National & Kapodistrian University of Athens, Maroussi, Athens, Greece, <sup>18</sup>Andromed Health & Reproduction, Fertility Diagnostics Laboratory, Maroussi, Greece, <sup>19</sup>Departamento de Biología, Universidad Autónoma de Madrid, Madrid, Spain, <sup>20</sup>Austin Fertility and Reproductive Medicine/Westlake IVF, Department of Urology, University of Texas Health Science Center at San Antonio, San Antonio, TX, USA, <sup>21</sup>Fakih IVF Fertility Center, Abu Dhabi, UAE, <sup>22</sup>Department of Biochemistry, College of Medicine, University of Garmian, Kalar, Iraq, <sup>23</sup>Departamento Docencia e Investigación, Hospital Militar Campo de Mayo, Universidad Barcelo, Buenos Aires, Argentina, <sup>24</sup>Clinical and training Centre of the European Academy of Andrology, Hospital de la Santa Creu i Sant Pau, Barcelona, Spain, <sup>25</sup>Department of Urology and Renal Transplantation, University of Foggia Policlinico Riuniti of Foggia, Foggia, Italy, <sup>26</sup>IVF Clinic "Akeso-Embryo ART", Athens, Greece, <sup>27</sup>Department of Andrology, Uromedica Polyclinic, Belgrade, Serbia, <sup>28</sup>Department of Anatomy & Unit for Multidisciplinary Research in Biomedicine (UMIB), Institute of Biomedical Sciences Abel Salazar (ICBAS), University of Porto, Porto, Portugal, <sup>29</sup>Department of Environmental, Biological and Pharmaceutical Sciences and Technologies (DiSTABiF), University of Campania Luigi Vanvitelli, Caserta, Italy, <sup>30</sup>Department of Andrology, Sexology & STIs, Faculty of Medicine, Cairo University, Cairo, Egypt, <sup>31</sup>Centro ANDROGEN, La Coruña, Spain, <sup>32</sup>Department of Obstetrics, Gynecology, and Reproductive Biology, Harvard Medical School, Boston, MA, USA, <sup>33</sup>Department of Andrology and Reproductive Medicine, Jindal Hospital, Meerut, India, <sup>34</sup>Department of Obstetrics and Gynaecology, Alexandria University Faculty of Medicine, Alexandria, Egypt, <sup>35</sup>Centerf Technological Innovation, and Reproductive Medicine (CITMER), Mexico City, Mexico, <sup>36</sup>Examenlab Ltd., Weavers Court Business Park, Linfield Road, Belfast, Northern Ireland, UK, <sup>37</sup>Department of Urology, Haccpetete

Received: Mar 31, 2021 Revised: Apr 17, 2021 Accepted: Apr 21, 2021 Published online Jun 9, 2021

Correspondence to: Ashok Agarwal <https://orcid.org/0000-0003-0585-1026>

Andrology Center and American Center for Reproductive Medicine, Cleveland Clinic, Mail Code X-11, 10681 Carnegie Avenue, Cleveland, OH 44195, USA.

Tel: +1-216-444-9485, Fax: +1-216-445-6049, E-mail: [agarwaa@ccf.org](mailto:agarwaa@ccf.org), Website: [www.Clevelandclinic.org/ReproductiveResearchCenter](http://www.Clevelandclinic.org/ReproductiveResearchCenter)

University, Ankara, Turkey, <sup>38</sup>Department of Urology, Pusan National University School of Medicine, <sup>39</sup>Medical Research Institute of Pusan National University Hospital, Busan, Korea, <sup>40</sup>Department of Andrology, Hammersmith Hospital, London, UK, <sup>41</sup>Avant Concierge Urology & University of Central Florida, Winter Garden, FL, USA, <sup>42</sup>Department of Andrology, Reproductive Biomedicine Research Center, Royan Institute for Reproductive Biomedicine, ACECR, Tehran, Iran, <sup>43</sup>Department of Obstetrics Gynaecology and Reproductive Medicine, Flinders University, Adelaide, South Australia, <sup>44</sup>Department of Physiology, Faculty of Medicine, Universiti Teknologi MARA, Sungai Buloh Campus, Selangor, Malaysia, <sup>45</sup>Andrology and IVF Unit, Procrea Institute, Lugano, Switzerland

The current WHO 2010 manual for human semen analysis defines leukocytospermia as the presence of peroxidase-positive leukocytes at a concentration  $>1 \times 10^6/\text{mL}$  of semen. Granular leukocytes when activated are capable of generating high levels of reactive oxygen species in semen resulting in oxidative stress. Oxidative stress has been correlated with poor sperm quality, increased level of sperm DNA fragmentation and low fertility potential. The presence of leukocytes and pathogens in the semen may be a sign of infection and/or localized inflammatory response in the male genital tract and the accessory glands. Common uro-pathogens including *Chlamydia trachomatis*, *Ureaplasma urealyticum*, *Neisseria gonorrhoeae*, *Mycoplasma hominis*, and *Escherichia coli* can cause epididymitis, epididymo-orchitis, or prostatitis. The relationship between leukocytospermia and infection is unclear. Therefore, we describe the pathogens responsible for male genital tract infections and their association with leukocytospermia. The review also examines the diagnostic tests available to identify seminal leukocytes. The role of leukocytospermia in male infertility and its management is also discussed.

**Keywords:** Culture; Endtz; Infections; Inflammation; Leukocytes; Spermatozoa

This is an Open Access article distributed under the terms of the Creative Commons Attribution Non-Commercial License (<http://creativecommons.org/licenses/by-nc/4.0>) which permits unrestricted non-commercial use, distribution, and reproduction in any medium, provided the original work is properly cited.

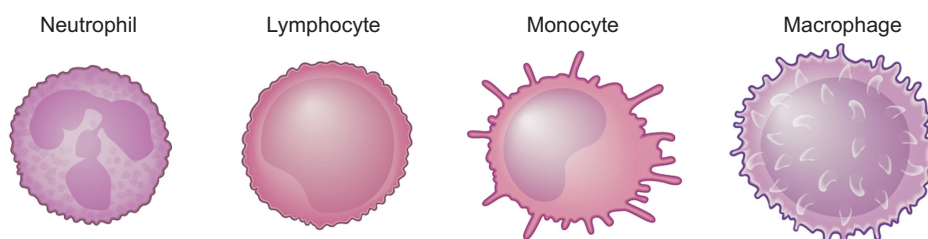
## INTRODUCTION

Leukocytes represent an important percentage of non-sperm cells in semen of both fertile and infertile men [1]. Around 50% to 60% of leukocytes are polymorphonuclear (PMN) granulocytes originating from the prostate and/or seminal vesicles (Fig. 1) [2,3], while a lower percentage are macrophages (20%–30%) and T-lymphocytes (2%–5%) [2].

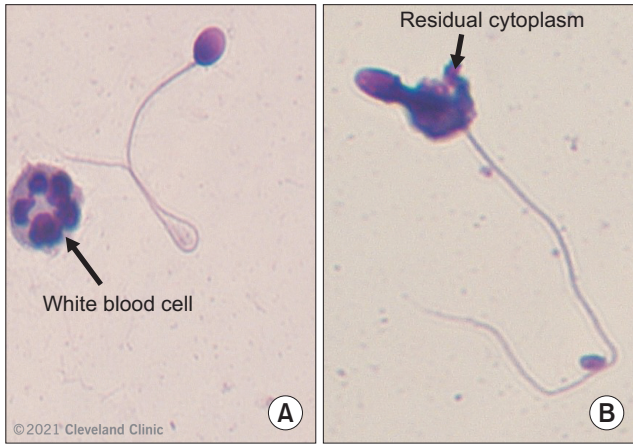
In semen, leukocytes are involved in the orchestration of an inflammatory response through the synthesis of cytokines, and other leukocyte-derived pro-inflammatory mediators like nitric oxide, prostaglandins and chemokines [4,5]. The inflammatory response results in the elimination of the pathogens and apoptosis of immature or abnormal spermatozoa by phagocytosis and production of reactive oxygen species (ROS) (Fig.

2, 3) [1,6-9]. The activation of leukocytes results in the generation of a 1,000-times more ROS than the amount released by spermatozoa [10].

The World Health Organization (WHO) 2010 laboratory manual [11] defines a seminal leukocyte concentration of greater than  $1 \times 10^6$  cells/mL as “leukocytospermia”. It is assumed that a leukocyte concentration higher than this cut-off value is a possible indication of male genital infection with possible infertility; however, this value is one that is suggestive as there is a broad “grey zone”. Some studies have linked leukocytospermia to male infertility [7,12,13] while others could not find an association [14,15]. Nevertheless, the presence of elevated seminal leukocytes is a very useful clinical parameter in the andrological assessment of male fertility potential. This article aims to review the evidence supporting an association of leukocytospermia

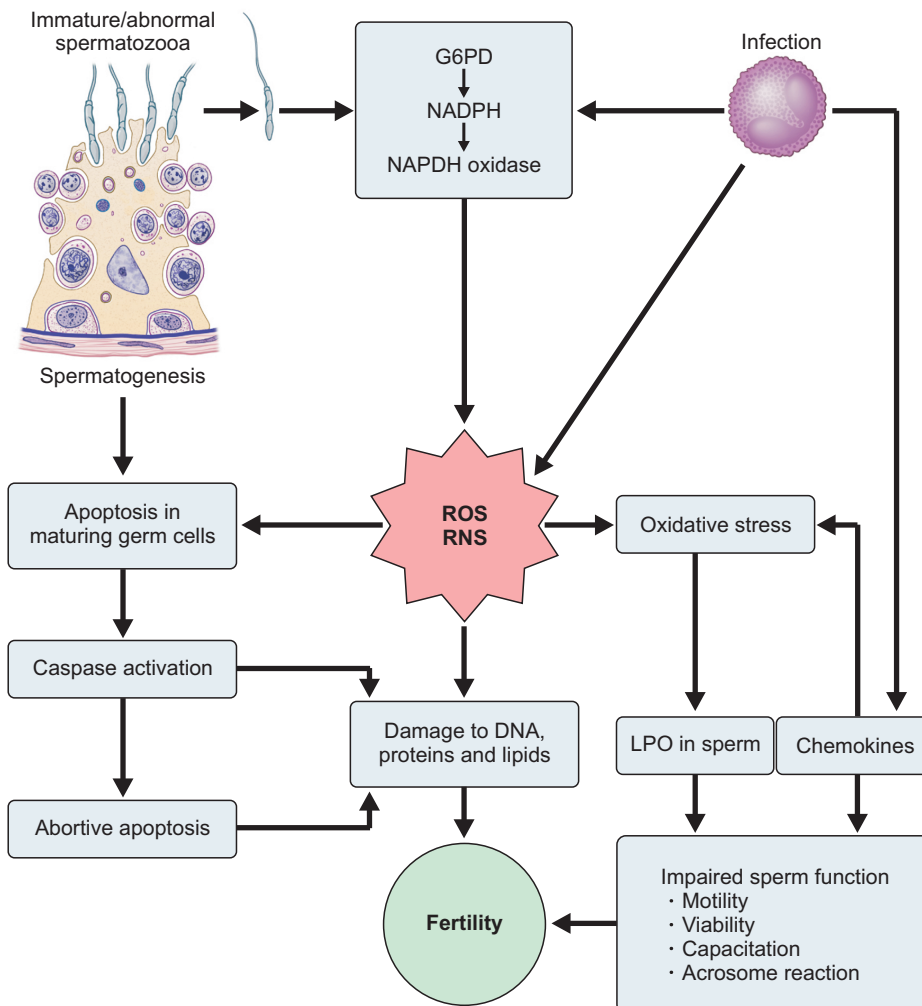


**Fig. 1.** Common leukocytes found in the semen.



**Fig. 2.** Sources of reactive oxygen species (ROS) in semen (A) leukocytes and (B) abnormal spermatozoa with residual cytoplasm. Diff-Quik stain was used and observed under bright field at 1,000× magnification using 100× objective and 10× eye-piece.

with male accessory gland infection (MAGI) and male genital tract infection (MGTI). The focus is to provide clear indications for the laboratory assessment of leukocytes, step-by-step protocols, troubleshooting, and the importance of quality control, quality assurance and competency assessment. Furthermore, the clinical relevance of leukocytospermia in male infertility along with the management of these patients are reviewed through clinical scenarios. Competency assessment is performed to evaluate the laboratory staff's knowledge and skills to perform the Endtz test correctly. The assessment is done annually using competency checklist for Endtz test.



**Fig. 3.** Mechanism of reactive oxygen species (ROS) production in semen. RNS: reactive nitrogen species, LPO: lipid peroxidation.

## MALE GENITAL TRACT INFECTIONS

### 1. Prevalence

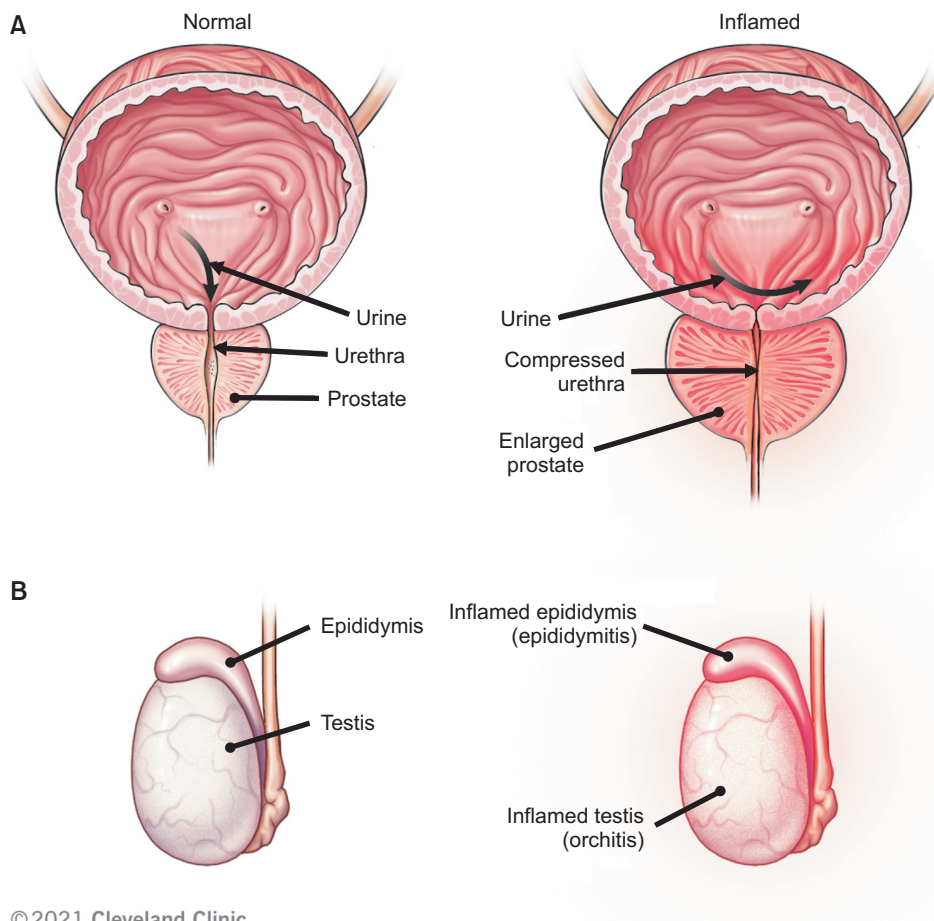
The term MAGI or male accessory gland infections indicates infection/inflammation of accessory glands such as the prostate, seminal vesicles and Cowper's glands [16]. This needs to be differentiated from the more general MGTI, which refers to the involvement of the entire male genital tract. Generally, the presence of an elevated number of leukocytes and/or pathogens in semen as well as inflammatory signs in the male genital tract are indicators of the presence of MGTI. Inflammation of the excurrent duct system that are neither anatomical parts of the male reproductive system nor are considered accessory glands are not included in the original definition of MAGI. Since a clear distinction cannot be made between specific localized infections [17], the term MGTI was introduced, which encompasses the entire reproductive tract [18]. While the presence of leukocytes appears to have only a weak discriminating power, elevated levels of seminal PMN granulocyte elastase ( $\geq 230$  ng/mL) and pro-inflam-

matory cytokines such as interleukin (IL)-6 and IL-8 are more helpful in the diagnosis and management of MAGI [1,19-21].

About 15% of the male infertility cases are linked to MGTIs, which would cause an abnormal increase in leukocyte counts in the ejaculate [22,23]. MGTIs are the third most common cause of male infertility after idiopathic infertility (28.4%) and varicocele (18.1%), although a prevalence of up to 36.7% has been previously reported [1,24,25]. *Chlamydia trachomatis*, *Escherichia coli*, and *Neisseria gonorrhoeae* are the most common causes of infection, resulting in an excessive accumulation of leukocytes within the male genital tract. These pathogens as well as their mediators can result in variable degree of damage to the testis and epididymis [26].

### 2. Pathogenesis of inflammation of the genital tract

Inflammation of the genital tract can affect semen quality and lead to deterioration of spermatogenesis, impairment of sperm function and obstruction of the seminal tract [27]. Secretory functions of the accessory



**Fig. 4.** Schematic showing normal and inflamed prostate, epididymis and the testis. (A) Normal and inflamed prostate with compressed urethra. (B) Normal and inflamed testis and epididymis.



glands can be adversely altered by inflammatory conditions [1,27,28].

Although still under debate, a strong association has been reported between infected semen and the presence of leukocytes in semen and male infertility [28-31]. Dysregulation of spermatogenesis due to the presence of microorganisms and activation of seminal leukocytes can impair semen quality [28,31]. Pro-inflammatory cytokines such as tumor necrosis factor- $\alpha$  (TNF- $\alpha$ ), IL-1 $\alpha$ , IL-6 or IL-8 released by leukocytes can lead to an inflammatory response [28,32,33] consequently affecting semen quality [27].

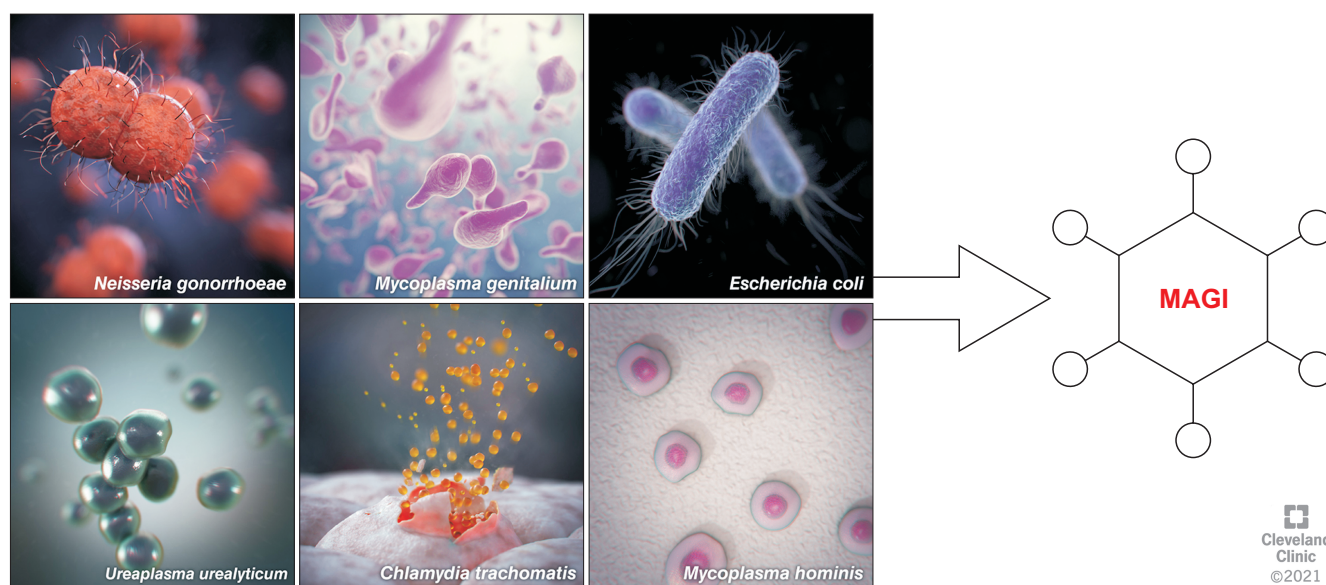
Prostatitis is the most common urological disorder in younger and middle-aged men with a prevalence of 4% to 11% (Fig. 4A) [34]. Epididymitis either acute or subacute can present with unilateral or bilateral swelling of the scrotum. Chronic epididymitis is more common (Fig. 4B). Prostatitis and epididymitis can lead to seminal tract obstruction secondary to scarring of the epididymis, vas or ejaculatory duct resulting in oligozoospermia or azoospermia [26]. The inflammation can spread to the testis as 'epididymo-orchitis' and can be associated with high rates of infertility and in extreme cases can be a cause of testicular atrophy and spermatogenic impairment or even arrest [35]. Urethritis can be caused by both sexually transmitted and non-sexually transmitted pathogens [1,36-38].

### 3. Infection due to pathogenic bacteria

The most prevalent pathogens in the male reproductive tract, including *Chlamydia trachomatis*, *Ureaplasma urealyticum*, *Neisseria gonorrhoeae*, *Mycoplasma hominis*, and *Mycoplasma genitalium*, are sexually transmitted (Fig. 5) [22]. *Escherichia coli* is another common pathogen particularly responsible for epididymo-orchitis and prostatitis in 65% to 80% of the cases [22]. These pathogens can affect the sperm fertilizing capacity and cause asymptomatic inflammation in the urogenital tract [39]. They can also cause an acute inflammatory response with a flow of leukocytes into the genital tract leading to deterioration of spermatogenesis, impairment of sperm function [40], and increase in production of ROS [41].

Another important aspect of MGIT is that these infections often present asymptotically [22,42-44] in about 50% of men [45] and this percentage may be higher in young, sexually active men [46]. Such silent infections may remain undetected and untreated and can lead to severe complications and/or infertility and can be transmitted to their sexual partner(s) [47-51]. However, there are reports of elevated ROS and reduced total antioxidant levels in men with asymptomatic urogenital infections. These patients may benefit from antibiotic therapy and thereby improve their semen parameters [49].

Pathogens including Chlamydia, Ureaplasma, Mycoplasma, Enterobacteriaceae as well as Gram-positive



**Fig. 5.** Examples of the most prevalent sexually transmitted pathogens in the male reproductive tract. Among these, *Neisseria gonorrhoeae*, *Chlamydia trachomatis*, and *Escherichia coli* are the most common causes of male accessory gland infection (MAGI).

cocci have been detected by either polymerase chain reaction (PCR) or cultures and their effect on sperm have been examined [52]. Cultures of Chlamydia, Ureaplasma, Mycoplasma, Enterobacteriaceae have low sensitivity and hence are detected using PCR, whereas Enterobacteriaceae as well as Gram positive cocci can be detected using specific culture methods [52]. *Escherichia coli*, *Staphylococcus aureus*, *Ureaplasma urealyticum*, or *Mycoplasma hominis* have been shown to negatively affect various semen parameters and sperm function such as sperm count, motility, or mitochondrial membrane potential [39,53-58]. Sperm concentration and motility have been found to differ between Ureaplasma-positive and negative patients [59]. In infertile men, those with seminal infections with Ureaplasma had significantly lower mean sperm concentration and vitality compared to those who were negative. However, these differences were not clinically significant [59]. Lower sperm vitality was reported in cases of Chlamydia infection, but there was no significant difference in the prevalence of Chlamydia between fertile and infertile men [59,60]. Mycoplasma, Enterobacteriaceae and Gram-positive cocci did not significantly affect semen parameters. Sperm concentration was significantly lower in the bacteria positive group but higher than the WHO reference range ( $15 \times 10^6$ /mL) [52,61]. There is a reported lack of association of Ureaplasma and Mycoplasma with poor semen quality [62-64].

## LEUKOCYTOSPERMIA AND SEMINAL OXIDATIVE STRESS

Leukocytospermia is found in 10% to 20% of infertile men [3]. There are numerous reports indicating that leukocytospermia has a negative impact on male fertility [7,12,13,29]. MGTI and leukocytospermia have been reported to be associated with high levels of ROS which in turn may cause a decline in sperm parameters including sperm concentration and motility [65]. A study (n=472) examined 3 different groups of men: men with no seminal leukocytes, men with low-level seminal leukocytes (range  $0.1 - <1.0 \times 10^6$  WBC/mL), and men with leukocytospermia ( $>1.0 \times 10^6$  WBC/mL). The latter study reported that the presence of even low levels of leukocytospermia is associated with semen OS, with no significant differences in the ROS levels between men with low leukocyte counts (range  $0.1 - <1.0 \times 10^6$  WBC/

mL) and those with leukocytospermia [66].

A study from our group has reported higher incidence of leukocytospermia in men with ROS levels above the cut-off level of  $250 \text{ RLU}/10^6 \text{ sperm/mL}$  [67]. A higher prevalence of leukocytospermia in men with high ROS levels also results in compromised sperm function. Elevated ROS levels negatively impact sperm functions such as sperm DNA integrity with an increase in DNA fragmentation rates [67]. A 25% increase in ROS level was associated with a 10% increase in DNA fragmentation [67]. Moreover, the study reported a positive association between leukocytospermia, ROS, and sperm DNA fragmentation levels. A similar positive correlation between total ROS levels, sperm DNA fragmentation by TUNEL assay and leukocytospermia has also been reported [65].

## ASSESSMENT OF ROUND CELLS IN THE EJACULATE

Initial semen analysis is conducted for the estimation of round cells on the wet preparation. The semen sample is examined using a phase-contrast microscope with a green filter. It is necessary to have a  $10 \times 10$  ocular grid in the microscope eyepiece. A  $6 \mu\text{L}$  of well-mixed semen sample is loaded onto the fixed cell chamber. Round cells in the semen can be either leukocytes, immature germ cells, large anucleate residual cytoplasm, epithelial cells, or *Trichomonas vaginalis*. The number of round cells in all 100 squares of the grid using  $20 \times$  objective (high power field) are counted and recorded in multiple fields. The round cell concentration is calculated as the average number of round cells per field and multiplied with the microscope factor. This calculation will give the concentration of round cells in  $10^6$ /mL [68]. If more than 5 round cells/high power field or a round cell concentration of  $\geq 1.0 \times 10^6$ /mL is found, a test for leukocytes (white blood cells; WBCs) is indicated.

## QUANTIFICATION OF WHITE BLOOD CELL IN SEMEN

### 1. Immunocytochemistry - the gold standard

Monoclonal antibodies against the common leukocyte antigen CD45 or CD53 can detect granulocytes, lymphocytes, and macrophages concurrently [69-72]. Ricci et al [73] compared a flow cytometric immunocy-

tological method using CD45 and CD53 with the simple peroxidase test and found positive correlations. Immunocytology is highly specific and recognized as the gold standard for diagnoses of leukocytospermia. However, it is impractical for daily use and if used with a flow cytometer it is relatively expensive. Major drawbacks include the lack of standardization of the exact immunohistological staining method and the exact monoclonal antibodies to be used, and are time-consuming if performed manually [23,73,74]. Both American Society for Reproductive Medicine (ASRM) and American Urological Association (AUA) recommend immunohistochemistry as a confirmatory diagnostic test for leukocytospermia [75].

## 2. Seminal granulocyte elastase test

Elastase is a protease released by PMN leukocytes during the inflammatory process [76,77]. It is measured by immunoassay in seminal plasma, Ela/ $\alpha$ 1-PI at a cut-off level of greater or equal to 230  $\mu$ g/L, which is useful in the detection of genital tract inflammation. The prevalence of increased seminal Ela/ $\alpha$ 1-PI in infertile men is significantly higher than that observed in fertile men [78]. Seminal granulocyte elastase measurement by an enzyme-linked immunosorbent assay (ELISA) allows discrimination between inflammatory *versus* non-inflammatory processes. Since PMN-elastase is liberated during phagocytosis or disintegration of granulocytes, there is a strong correlation of leukocytes with elastase [77,79]. Elastase concentrations have been shown to negatively correlate with sperm motility ( $p < 0.05$ ), progressive motility ( $p < 0.05$ ) as well as sperm morphology ( $p < 0.05$ ) [79]. Granulocyte elastase is a reli-

able screening test for silent genital tract inflammation [80]. The age-related prevalence of male genital tract inflammation (as defined by PMN-elastase  $> 250$  ng/mL) has been reported by Henkel et al [25]. The measurement of granulocyte elastase in semen provides information on the number of granulocytes and their inflammatory activation. However, commercial granulocyte elastase enzyme immunoassays are expensive [81]. The value of routine determination of PMN elastase in semen and/or serum samples is limited when used as a single parameter to screen for subclinical infection/inflammation in males undergoing infertility investigation [82].

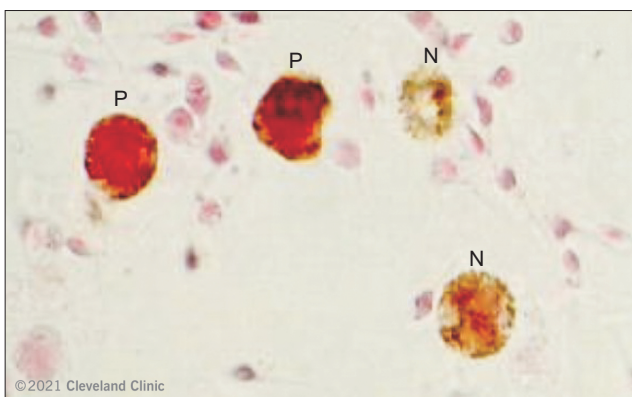
## 3. Peroxidase tests

### 1) Ortho-toluidine test

Peroxidase in granulocytes catalyzes the reaction of ortho-toluidine (o-toluidine) and hydrogen peroxide ( $H_2O_2$ ) [11]. Granulocytes stain brown as peroxidase-positive cells, while peroxidase-negative cells are unstained (Fig. 6). Both WHO and European Association of Urology (EAU) recommend performing peroxidase test for confirming wet mount microscopy findings [11,75]. Briefly, the working solution consisting of 10 mL 0.25% o-toluidine in phosphate buffer, pH 6.0, is mixed with 10  $\mu$ L 30%  $H_2O_2$ . The semen sample is diluted with physiological saline solution in a ratio of 1:10 and 100  $\mu$ L of diluted semen sample mixed with 100  $\mu$ L of the working solution. The mixture is incubated for 20 minutes at 37°C. Peroxidase-positive leukocytes are counted using an improved Neubauer chamber under 400 $\times$  magnification.

### 2) Endtz test

Peroxidase-positive granulocytes (neutrophils and macrophages) can also be detected by the Endtz test [83]. Peroxidase present in the granulocytes oxidizes benzidine derivative which precipitates to give a brown color. This test recognizes granulocytes present in the semen. However, it cannot identify non-peroxidase-rich WBCs. The inflammatory process induces the release of myeloperoxidase. This results in loss of peroxidase enzyme activity in granulocytes making them undetectable [72]. The Endtz test is a simple, quick and most commonly used test in diagnostic Andrology laboratories.



**Fig. 6.** O-Toluidine stained cells showing positive (P) and unstained negative (N). 400 $\times$  magnification using 40 $\times$  objective and 10 $\times$  eyepiece.

## ASSESSMENT OF WHITE BLOOD CELLS BY ENDTZ TEST

### 1. Principle and procedure of Endtz test

Round cells present in the ejaculate contain granulocytes such as neutrophils, PMN leukocytes, macrophages, and germinal cells. Granulocytes are the primary sources of ROS which can lead to male infertility [84]. WBCs cannot be differentiated from germinal cells in a wet unstained preparation. This is done using the Endtz or the peroxidase stain [68].

### 2. Reagents - preparation of stock and working solutions

#### 1) Preparation of stock solution (stable for 6 months)

- (1) Ethanol - 50 mL of 96%
- (2) Benzidine - 0.125 g
- (3) Sterile water - 50 mL

Mix these chemicals in a clean 100-mL bottle. The solution should be clear and yellow. Cover the bottle with aluminum foil and store it in the dark. If the solution gets dark in color or forms a cloudy precipitate, discard and prepare a fresh stock solution.

Benzidine is carcinogenic and should be handled carefully. Gloves and a face mask must be worn to avoid accidental inhalation when handling. The solu-

tion should be prepared in a biological safety cabinet. Any expired Endtz test solution should be discarded in concentrated Clorox solution.

#### 2) Preparation of working solution

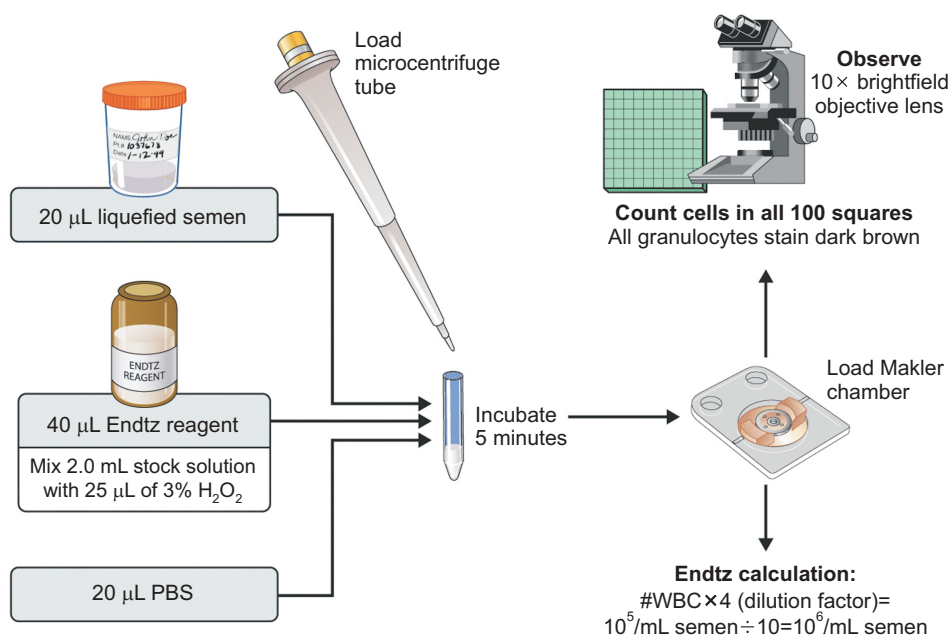
- (1) Mix 2.0 mL of stock solution and 25  $\mu$ L of 3%  $H_2O_2$  in a 6 mL polystyrene tube (use 3%  $H_2O_2$  or dilute 30% stock  $H_2O_2$  1:10).
- (2) Cover the tube with aluminum foil.
- (3) Prepare a fresh working solution from the stock solution every week.

#### 3) Requirements and procedure (Fig. 7)

- (1) Phosphate buffered saline (PBS)
- (2) Makler counting chamber
- (3) Microcentrifuge tubes
- (4) Eppendorf pipette (5  $\mu$ L, 20  $\mu$ L, 40  $\mu$ L) tips

#### 4) Use of Makler chamber

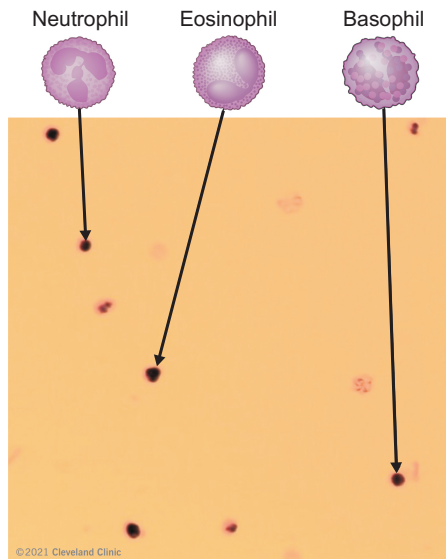
- (1) Load a Makler counting chamber with 5  $\mu$ L of the above mixture and observe under a 10 $\times$  bright-field objective lens.
- (2) All granulocytes will stain dark brown and retain their round shape.
- (3) Count the cells in all 100 squares of the Makler grid.



©2021 Cleveland Clinic

Fig. 7. Steps in performing the Endtz test. WBC: white blood cell.





**Fig. 8.** Cells stained positive for Endtz test are indicated and are mainly granulocytes. 100× magnification using 10× objective and 10× eye-piece.

### 5) Steps in performing the Endtz test

- (1) Take 20  $\mu\text{L}$  of liquefied semen specimen in a dark-colored microcentrifuge tube.
- (2) Add 20  $\mu\text{L}$  of PBS solution and 40  $\mu\text{L}$  of working Endtz solution.
- (3) Vortex and incubate at room temperature for 5 minutes.

### 6) Observing the stained cells

The stained cells can be observed using a bright field microscope and a 10× objective (Fig. 8).

### 7) Calculations and quantitation of white blood cells

The number of WBCs can be calculated by multiplying the total number of cells by 4 to correct for the dilution factor. The total WBCs number will be  $10^5/\text{mL}$  semen. This number should be corrected to  $10^6/\text{mL}$  by dividing by 10.

### 8) Endtz calculation

WBCs $\times$ 4 (dilution factor)= $10^5/\text{mL}$  semen  
 $10^5/\text{mL}$  semen divided by 10 to give result in  $10^6/\text{mL}$  semen (million/mL)

Example:

- (1) Seven WBC's are counted in 100 squares on the Makler grid
- (2) Endtz positive cells=WBCs $\times$ 4/10= $7\times 0.40=2.8\times 10^6/\text{mL}$

### 9) Reference values and urgent values

- (1) Report results as  $\times 10^6/\text{mL}$ .
- (2) We have reported that the presence of an even lower concentration of WBCs in the ejaculate can generate high ROS levels [84]. Therefore, WBC concentrations  $>0.10\times 10^6/\text{mL}$  will be considered as significant.

Any Endtz-positive test should be communicated to the gynecologist before performing the intrauterine insemination (IUI).

## QUALITY CONTROL, QUALITY ASSURANCE AND COMPETENCY ASSESSMENT IN LEUKOCYTOSPERMIA

In order to maintain the high quality of the laboratory testing, a weekly positive control is used to compare the results with the old and new Endtz solution. If the results are negative, the new reagent has to be mixed well and the control re-tested. If the test is still negative, a new control specimen needs to be run. In case a semen specimen is not available, an EDTA-anti-coagulated blood specimen may be used. For this, blood specimen is centrifuged to obtain the buffy coat. The buffy coat is removed using a transfer pipette, diluted with 2 mL of PBS buffer, and aliquoted (0.1 mL). These aliquots may be used for one month for quality control tests [68].

## LABORATORY SCENARIOS

Some lab issues may be encountered with respect to the Endtz test. These are described here as scenarios with recommendations for troubleshooting.

### 1. Case A

#### 1) Scenario

A 31-year-old patient provided a semen sample for laboratory evaluation. Upon examination, the parameters were volume: 2.0 mL; sperm concentration:  $35\times 10^6/\text{mL}$ ; motility: 45% and round cell concentration is  $20\times 10^6/\text{mL}$ . The working Endtz solution upon examination was found to have expired and was cloudy in appearance instead of the light straw color. How would you proceed?

## 2) Solution

Prepare fresh Endtz solution and perform quality control with a known positive semen sample. If the Endtz test is positive, the solution passes quality control. Perform the Endtz test for the patient sample and record the results.

## 2. Case B

### 1) Scenario

No positive Endtz semen sample is available. How do we perform the quality control for a fresh Endtz working solution?

### 2) Solution

The new lot of Endtz working solution should be compared with the old lot of Endtz solution that is expiring but has not expired. In case an Endtz positive semen sample is not available, blood can be used to separate the WBCs. The sample is centrifuged and the top buffy coat that is high in granulocytes can be used. If the sample tests positive with both new and old Endtz solution, the new Endtz solution passes quality control. Place a label with the lot number and the expiration date and the new Endtz solution can be used to perform the Endtz test.

## RELEVANCE OF LEUKOCYTOSPERMIA IN MALE INFERTILITY

### 1. Clinical indications for semen cultures

Infections are associated with inflammation, but it is unclear if infertile patients would benefit from obtaining a semen culture. *Ureaplasma urealyticum* and *Chlamydia trachomatis* are the two most common pathogenic microorganisms in the genital tract. Both can induce urethritis [85], whereas *Chlamydia trachomatis* can induce prostatitis [86] and epididymitis in young men [87]. *Chlamydia* and *Mycoplasma* are difficult to culture and are diagnosed with nucleic acid amplification testing (NAAT) such as PCR assay [52].

Peroxidase testing along with reflex semen cultures is a better clinical tool than the peroxidase test alone [88]. Men with subclinical asymptomatic infections and leukocytospermia may benefit from performing semen culture [89].

However, there are no clear guidelines on the in-

dications for semen culture [52]. There have been no differences reported in the incidence of positive semen culture between fertile and infertile men [52] and the clinical significance of positive semen cultures is unclear [52,61,90]. In cases of suspected MAGI or a patient with a positive semen culture, prostatic massage may be performed in order to examine the expressed prostatic secretion (EPS). The cytological examination of EPS is often diagnostic and is followed by EPS culture [91,92]. EPS examination is an easy procedure for urologists or andrologists and may be a "second line" diagnostic tool in suspected cases of MAGI or MGTL. However EPS is a discomforting and expensive procedure [14,93].

Some reports recommend treatment only in patients with leukocytospermia and a positive semen culture [52,94]. There are also no WHO guidelines on the indications for semen culture. Although leukocytospermia has detrimental effects on semen quality, it is not a predictor of positive semen cultures [95].

The EAU and AUA guidelines recommend performing a semen culture when the WBC is  $\geq 1 \times 10^6/\text{mL}$  in the ejaculate as this may be an indicator of active infection [96]. These recommendations are based on the concept that a bacterial infection can trigger an inflammatory response as documented by an increase in seminal leukocyte concentration [52]. The prevalence of both leukocytospermia (25%) and positive semen culture (10%) was reported in a homogeneous large cohort of white European men presenting with primary infertility [97].

Ventimiglia et al [97], conducted a study on 523 men with no symptoms of genital infections. All these men underwent semen culture. A positive semen culture was found in 54 men (10%) whereas 131 (25%) men had leukocytospermia at semen analysis. However, the majority of the positive semen cultures (43 out of 54 or 80%) did not have associated leukocytospermia and, moreover, by applying the EAU guidelines, positive semen cultures would be missed, resulting in 120/131 (92%) useless examinations. The majority of the false positive cultures are mainly due to contamination during the sample collection. Therefore, the strict aseptic conditions during sample collection should be followed according to the WHO to avoid such dilemma [11,97]. Hence, leukocytospermia alone has little diagnostic value in the detection of bacteriospermia and impaired semen quality [95] and is not a predictive factor of positive semen culture [97]. Overall, these studies suggest

that it is not possible to identify men at risk of semen infection. Infertile men with leukocytospermia and a positive semen culture should be treated with a course of antibiotics [98].

## 2. Leukocytospermia in varicocele patients

Varicocele can result in a high degree of leukocytes in the semen [75]. An increased number of semen lymphocytes is more frequent in subfertile men and males with varicocele compared to fertile males [99]. Although the Endtz test measures only granulocytes, measurement using flow cytometry has shown the presence of a significantly higher number of CD4+ helper T-lymphocytes in the varicocele group compared to the control group [100]. This may explain why patients with varicocele have increased cytokine levels in the seminal fluid even when sperm concentration is normal.

## 3. Leukocytospermia in smokers

The association between cigarette smoking and leukocytospermia is well established [101,102]. This positive correlation increases with the degree of smoking *i.e.* mild ( $p=0.241$ ); moderate ( $p=0.025$ ); and heavy smokers ( $p=0.001$ ) [103]. Activated leukocytes can result in elevated seminal levels of ROS which can overpower the antioxidant defenses and result in oxidative stress [104,105]. Metabolites in tobacco can trigger the inflammatory response and activate the infiltration of leukocytes into the seminal plasma [106]. A study comparing non-smokers, ex-smokers and smokers, reported that smokers were significantly ( $p<0.001$ ) younger and had higher levels of round cells in their ejaculates ( $p=0.003$ ). Moreover, the percentage of leukocytospermic ejaculates was higher in smokers ( $p<0.001$ ) [107]. A significant negative correlation between the number of leukocytes and total and progressive motility has also been reported among smokers [93].

## 4. Leukocytospermia in spinal cord injury

Increased numbers of leukocytes, especially granulocytes have been reported in retrograde ejaculates collected from men with spinal cord injury (SCI), likely secondary to urinary tract infections [108,109]. This is reflected by a significant positive correlation between leukocyte concentration and levels of ROS in these men [110]. Leukocyte concentrations higher than  $5 \times 10^6/\text{mL}$  were positively correlated with high levels

of ROS ( $p=0.02$ ). Antegrade specimens showed higher concentrations of leukocytes than retrograde specimens ( $p<0.03$ ) [110]. It is estimated that 60% to 70% of men with SCI have abnormal levels of leukocytes in the ejaculate with a direct negative impact on sperm motility, sperm viability, sperm morphology and an increase in the level of sperm DNA damage [109,111]. In some men with SCI, the average level of sperm DNA fragmentation is even higher than the control cohort, reaching values close to 100% [111]. Additionally, when urinary tract infections are diagnosed in SCI patients, the presence of macrophages and neutrophils is significantly increased [109].

## CLINICAL MANAGEMENT OF LEUKOCYTOPERMA

A number of clinical scenarios may be encountered in the management of infertile men with leukocytospermia, infection and high levels of ROS. Two common scenarios are described below.

### 1. Case A

#### 1) Scenario

A patient being evaluated for infertility has a semen analysis and semen culture done. The report shows a positive semen culture, but the semen analysis is negative for leukocytospermia.

#### 2) Management strategy

(1) WHO recommends strict hygiene and urinating before providing a semen sample to prevent bacterial contamination. It has been reported that false positive semen cultures results will turn out negative when the semen was collected using proper aseptic precautions.

(2) Skin flora contamination may be unavoidable. This is because up to 71% of bacterial strains colonizing the coronal sulcus can also be found in the distal urethra [112].

(3) Controversial - no significant difference in the presence or absence of bacteriospermia seen in patients and their ability to establish pregnancy [52].

(4) A positive semen culture and leukocytospermia should be treated.

## 2. Case B

### 1) Scenario

A patient's semen analysis demonstrates the following: sperm concentration:  $12 \times 10^6$ /mL; total motility: 30%; Endtz test value:  $4.5 \times 10^6$  WBCs/mL and a negative semen culture. Will this patient benefit from a course of antibiotics?

### 2) Management strategy

(1) If it is a case of oligoasthenozoospermia and leukocytospermia, then:

(2) Obtain history

(3) Perform physical exam

(4) Obtain social history - Leukocytospermia has also been attributed to factors such as cigarette smoking and heavy alcohol use.

The patient with negative semen culture and leukocytospermia should undergo urine PCR to assess for genital tract infections (*i.e.* chlamydia, ureaplasma). If the culture of a semen sample collected avoiding any external bacterial contamination, then the patient should be treated with the appropriate course of antibiotics [52].

Although a number of studies investigating the best treatment for leukocytospermia have been conducted, the best management strategy is still lacking. Leukocytospermia may indicate infection or inflammation of the male sex glands and urogenital tract [23,113]. Broad-spectrum antibiotics with good penetration into the prostate have been used in the treatment of leukocytospermia for male infertility [40]. In addition, antioxidants that can reduce ROS produced by semen leukocytes have also been used in patients with leukocytospermia [42,75]. However, there is no clear consensus on the effects of each treatment or whether leukocytospermia needs to be treated or not. Furthermore, only one systematic review of the antibiotic and antioxidant use in the treatment of leukocytospermia is available [94]. Despite some conflicting reports, a recent systematic review concluded that antibiotics might improve sperm parameters, the rate of resolution of leukocytospermia, the bacteriologic cure rate, and even the pregnancy rate [94]. However, the data is insufficient to conclude whether antibiotic and antioxidants for the treatment of infertile men with leukocytospermia are effective [94]. Branigan and Muller [42] reported that frequent ejaculation (at least every

3 days) with antibiotics was more efficient than antibiotics alone. Although an assessment of leukocytes is part of the standard semen analysis as outlined by the WHO laboratory manual [11], there is no consensus on the guidelines for its diagnosis, clinical implications, or treatment recommendations [75].

Definitive characterization of leukocytospermia as an infectious or inflammatory marker and a re-evaluation of the leukocyte concentration threshold is necessary to provide greater levels of evidence for the management of leukocytospermia. Several lines of evidence suggest that the presence of ROS and leukocytes in semen impair sperm count, motility, and morphology. The duration of treatment and the definition of leukocytospermia may also impact the success of antibiotic therapy in improving rates of natural conception [75]. A significant improvement in the resolution of leukocytospermia appears to be the result of a combination of antibiotic therapy and frequent ejaculation for at least one month [42,114].

## RELEVANCE OF LEUKOCYTOPSPERMIA IN ASSISTED REPRODUCTIVE TECHNOLOGY

Leukocytospermia may not be critical in an *in vitro* fertilization (IVF) setting due to the sperm processing step prior to the use of the sample in assisted reproductive technology (ART) [75,115]. A recent meta-analysis of twenty-eight case-controlled retrospective studies was conducted to examine the relationship between leukocytospermia and the outcome of ART. The meta-analysis concluded that leukocytospermia had no impact on fertility outcomes in cases of men having altered semen parameters and asymptomatic genital tract infection [116]. In another study, using flow cytometry for leukocyte detection, it was shown that leukocytospermia does not influence IVF/intracytoplasmic sperm injection (ICSI) outcome [117]. The authors concluded that the rates of fertilization and clinical pregnancy were not significantly different in men with or without leukocytospermia following ART.

## CONCLUSIONS

Leukocytospermia is a significant factor associated with high ROS levels, resulting in DNA damage and poor sperm quality. Quantification of leukocytes in the



semen is important as they may indicate an underlying inflammation and infection of the male genitourinary tract. This article clearly emphasizes the added value of investigating leukocytospermia to diagnose an underlying cause of male infertility, and treating it as part of optimal male infertility management. The peroxidase staining by Endtz test, while not the gold standard, is simple, practical, and provides reliable results. Although leukocytospermia is not a stand-alone good predictor of a positive semen culture, resolution of leukocytospermia would certainly be helpful in the management of infertile men.

## ACKNOWLEDGEMENTS

Authors are thankful to the artists from the Cleveland Clinic's Center for Medical Art & Photography for their help with the illustrations. The study was supported by the American Center for Reproductive Medicine.

## Conflict of Interest

The authors have nothing to disclose.

## Author Contribution

Conceptualization: AA, R Sharma, SG, RH. Writing – original draft: all the authors. Writing – review & editing: all the authors.

## REFERENCES

- Henkel R, Offor U, Fisher D. The role of infections and leukocytes in male infertility. *Andrologia* 2021;53:e13743.
- Johanisson E, Campana A, Luthi R, de Agostini A. Evaluation of 'round cells' in semen analysis: a comparative study. *Hum Reprod Update* 2000;6:404-12.
- Wolff H. The biologic significance of white blood cells in semen. *Fertil Steril* 1995;63:1143-57.
- Martínez-Prado E, Camejo Bermúdez MI. Expression of IL-6, IL-8, TNF-alpha, IL-10, HSP-60, anti-HSP-60 antibodies, and anti-sperm antibodies, in semen of men with leukocytes and/or bacteria. *Am J Reprod Immunol* 2010;63:233-43.
- Eggert-Kruse W, Boit R, Rohr G, Aufenanger J, Hund M, Strowitzki T. Relationship of seminal plasma interleukin (IL) -8 and IL-6 with semen quality. *Hum Reprod* 2001;16:517-28.
- Aitken RJ, Baker MA. Oxidative stress, spermatozoa and leukocytic infiltration: relationships forged by the opposing forces of microbial invasion and the search for perfection. *J Reprod Immunol* 2013;100:11-9.
- Saleh RA, Agarwal A, Kandirali E, Sharma RK, Thomas AJ, Nada EA, et al. Leukocytospermia is associated with increased reactive oxygen species production by human spermatozoa. *Fertil Steril* 2002;78:1215-24.
- Henkel R, Kierspel E, Stalf T, Mehnert C, Menkveld R, Tinneberg HR, et al. Effect of reactive oxygen species produced by spermatozoa and leukocytes on sperm functions in non-leukocytospermic patients. *Fertil Steril* 2005;83:635-42.
- Fraczek M, Sanocka D, Kamieniczna M, Kurpisz M. Proinflammatory cytokines as an intermediate factor enhancing lipid sperm membrane peroxidation in in vitro conditions. *J Androl* 2008;29:85-92.
- Plante M, de Lamirande E, Gagnon C. Reactive oxygen species released by activated neutrophils, but not by deficient spermatozoa, are sufficient to affect normal sperm motility. *Fertil Steril* 1994;62:387-93.
- World Health Organization (WHO). WHO laboratory manual for the examination and processing of human semen. 5th ed. Geneva: WHO; 2010.
- Aziz N, Agarwal A, Lewis-Jones I, Sharma RK, Thomas AJ Jr. Novel associations between specific sperm morphological defects and leukocytospermia. *Fertil Steril* 2004;82:621-7.
- Moubasher A, Sayed H, Mosaad E, Mahmoud A, Farag F, Taha EA. Impact of leukocytospermia on sperm dynamic motility parameters, DNA and chromosomal integrity. *Cent European J Urol* 2018;71:470-5.
- Trum JW, Mol BW, Pannekoek Y, Spanjaard L, Wertheim P, Bleker OP, et al. Value of detecting leukocytospermia in the diagnosis of genital tract infection in subfertile men. *Fertil Steril* 1998;70:315-9.
- Kaleli S, Oçer F, Irez T, Budak E, Aksu MF. Does leukocytospermia associate with poor semen parameters and sperm functions in male infertility? The role of different seminal leukocyte concentrations. *Eur J Obstet Gynecol Reprod Biol* 2000;89:185-91.
- Comhaire F, Verschraegen G, Vermeulen L. Diagnosis of accessory gland infection and its possible role in male infertility. *Int J Androl* 1980;3:32-45.
- Krause W. Male accessory gland infection. *Andrologia* 2008;40:113-6.
- Haidl G, Haidl F, Allam JP, Schuppe HC. Therapeutic options in male genital tract inflammation. *Andrologia* 2019;51:e13207.
- Depuydt CE, Bosmans E, Zalata A, Schoonjans F, Comhaire FH. The relation between reactive oxygen species and cyto-

- kines in andrological patients with or without male accessory gland infection. *J Androl* 1996;17:699-707.
20. Grande G, Milardi D, Baroni S, Luca G, Pontecorvi A. Identification of seminal markers of male accessory gland inflammation: from molecules to proteome. *Am J Reprod Immunol* 2018;80:e12992.
  21. Schiefer HG, von Graevenitz A. Clinical microbiology. In: Schill WB, Comhaire FH, Hargreave TB, editors. *Andrology for the clinician*. Heidelberg: Springer-Verlag Berlin Heidelberg; 2006;401-7.
  22. Pellati D, Mylonakis I, Bertoloni G, Fiore C, Andrisani A, Ambrosini G, et al. Genital tract infections and infertility. *Eur J Obstet Gynecol Reprod Biol* 2008;140:3-11.
  23. Sandoval JS, Raburn D, Muasher S. Leukocytospermia: overview of diagnosis, implications, and management of a controversial finding. *Middle East Fertil Soc J* 2013;18:129-34.
  24. Bayasgalan G, Naranbat D, Tsedmaa B, Tsogmaa B, Sukhee D, Amarjargal O, et al. Clinical patterns and major causes of infertility in Mongolia. *J Obstet Gynaecol Res* 2004;30:386-93.
  25. Henkel R, Maass G, Jung A, Haidl G, Schill WB, Schuppe HC. Age-related changes in seminal polymorphonuclear elastase in men with asymptomatic inflammation of the genital tract. *Asian J Androl* 2007;9:299-304.
  26. Schuppe HC, Bergmann M. Inflammatory conditions of the testis. In: Ježek D, editor. *Atlas on the human testis: normal morphology and pathology*. London: Springer; 2013;593-600.
  27. Azenabor A, Ekun AO, Akinloye O. Impact of inflammation on male reproductive tract. *J Reprod Infertil* 2015;16:123-9.
  28. Comhaire FH, Mahmoud AM, Depuydt CE, Zalata AA, Christophe AB. Mechanisms and effects of male genital tract infection on sperm quality and fertilizing potential: the andrologist's viewpoint. *Hum Reprod Update* 1999;5:393-8.
  29. Derbel R, Sellami H, Sakka R, Ben Slima A, Mkaddem I, Gdoura R, et al. Relationship between nuclear DNA fragmentation, mitochondrial DNA damage and standard sperm parameters in spermatozoa of infertile patients with leukocytospermia. *J Gynecol Obstet Hum Reprod* 2021;50:102101.
  30. Wolff H, Politch JA, Martinez A, Haimovici F, Hill JA, Anderson DJ. Leukocytospermia is associated with poor semen quality. *Fertil Steril* 1990;53:528-36.
  31. La Vignera S, Condorelli RA, Vicari E, Tumino D, Morgia G, Favilla V, et al. Markers of semen inflammation: supplementary semen analysis? *J Reprod Immunol* 2013;100:2-10.
  32. Koçak I, Yenisey C, Dündar M, Okyay P, Serter M. Relationship between seminal plasma interleukin-6 and tumor necrosis factor alpha levels with semen parameters in fertile and infertile men. *Urol Res* 2002;30:263-7.
  33. Haidl F, Haidl G, Oltermann I, Allam JP. Seminal parameters of chronic male genital inflammation are associated with disturbed sperm DNA integrity. *Andrologia* 2015;47:464-9.
  34. Nickel JC, Downey J, Hunter D, Clark J. Prevalence of prostatitis-like symptoms in a population based study using the National Institutes of Health chronic prostatitis symptom index. *J Urol* 2001;165:842-5.
  35. Choi HI, Yang DM, Kim HC, Kim SW, Jeong HS, Moon SK, et al. Testicular atrophy after mumps orchitis: ultrasonographic findings. *Ultrasonography* 2020;39:266-71.
  36. Ness RB, Markovic N, Carlson CL, Coughlin MT. Do men become infertile after having sexually transmitted urethritis? An epidemiologic examination. *Fertil Steril* 1997;68:205-13.
  37. Brill JR. Diagnosis and treatment of urethritis in men. *Am Fam Physician* 2010;81:873-8.
  38. Ochsendorf FR. Urethritis, sexually transmitted diseases (STD), acquired immunodeficiency syndrome (AIDS). In: Schill WB, Comhaire FH, Hargreave TB, editors. *Andrology for the clinician*. Heidelberg: Springer-Verlag Berlin Heidelberg; 2006;327-38.
  39. Sanocka-Maciejewska D, Ciupińska M, Kurpisz M. Bacterial infection and semen quality. *J Reprod Immunol* 2005;67:51-6.
  40. Skau PA, Folstad I. Do bacterial infections cause reduced ejaculate quality? A meta-analysis of antibiotic treatment of male infertility. *Behav Ecol* 2003;14:40-7.
  41. Villegas J, Schulz M, Soto L, Iglesias T, Miska W, Sánchez R. Influence of reactive oxygen species produced by activated leukocytes at the level of apoptosis in mature human spermatozoa. *Fertil Steril* 2005;83:808-10.
  42. Branigan EF, Muller CH. Efficacy of treatment and recurrence rate of leukocytospermia in infertile men with prostatitis. *Fertil Steril* 1994;62:580-4.
  43. Senior K. Chlamydia: a much underestimated STI. *Lancet Infect Dis* 2012;12:517-8.
  44. Samplaski MK, Domes T, Jarvi KA. Chlamydial infection and its role in male infertility. *Adv Androl* 2014;2014:307950.
  45. Gonzales GF, Muñoz G, Sánchez R, Henkel R, Gallegos-Avila G, Díaz-Gutierrez O, et al. Update on the impact of Chlamydia trachomatis infection on male fertility. *Andrologia* 2004;36:1-23.
  46. Chen MY, Rohrsheim R, Donovan B. The differing profiles of symptomatic and asymptomatic Chlamydia trachomatis-infected men in a clinical setting. *Int J STD AIDS* 2007;18:384-8.
  47. Ahmadi MH, Mirsalehian A, Bahador A. Association of Chlamydia trachomatis with infertility and clinical manifestations: a systematic review and meta-analysis of case-control studies. *Infect Dis (Lond)* 2016;48:517-23.
  48. Eley A, Pacey AA, Galdiero M, Galdiero M, Galdiero F. Can

- Chlamydia trachomatis directly damage your sperm? *Lancet Infect Dis* 2005;5:53-7.
49. Gallegos G, Ramos B, Santiso R, Goyanes V, Gosálvez J, Fernández JL. Sperm DNA fragmentation in infertile men with genitourinary infection by Chlamydia trachomatis and mycoplasma. *Fertil Steril* 2008;90:328-34.
  50. Gdoura R, Keskes-Ammar L, Bouzid F, Eb F, Hammami A, Orfila J. Chlamydia trachomatis and male infertility in Tunisia. *Eur J Contracept Reprod Health Care* 2001;6:102-7.
  51. Ouzounova-Raykova V, Ouzounova I, Mitov I. Chlamydia trachomatis infection as a problem among male partners of infertile couples. *Andrologia* 2009;41:14-9.
  52. Jue JS, Ramasamy R. Significance of positive semen culture in relation to male infertility and the assisted reproductive technology process. *Transl Androl Urol* 2017;6:916-22.
  53. Fraczek M, Piasecka M, Gaczarzewicz D, Szumala-Kakol A, Kazienko A, Lenart S, et al. Membrane stability and mitochondrial activity of human-ejaculated spermatozoa during in vitro experimental infection with Escherichia coli, Staphylococcus haemolyticus and Bacteroides ureolyticus. *Andrologia* 2012;44:315-29.
  54. Isaiah IN, Nche BT, Nwagu IG, Nnanna II. Current studies on bacterospermia the leading cause of male infertility: a protégé and potential threat towards mans extinction. *N Am J Med Sci* 2011;3:562-4.
  55. Köhn FM, Erdmann I, Oeda T, el Mulla KF, Schiefer HG, Schill WB. Influence of urogenital infections on sperm functions. *Andrologia* 1998;30 Suppl 1:73-80.
  56. Mazzoli S, Cai T, Addonisio P, Bechi A, Mondaini N, Bartoletti R. Chlamydia trachomatis infection is related to poor semen quality in young prostatitis patients. *Eur Urol* 2010;57:708-14.
  57. Mehta RH, Sridhar H, Vijay Kumar BR, Anand Kumar TC. High incidence of oligozoospermia and teratozoospermia in human semen infected with the aerobic bacterium Streptococcus faecalis. *Reprod Biomed Online* 2002;5:17-21.
  58. Rybar R, Prinosilova P, Kopecka V, Hlavicova J, Veznik Z, Zajicova A, et al. The effect of bacterial contamination of semen on sperm chromatin integrity and standard semen parameters in men from infertile couples. *Andrologia* 2012;44 Suppl 1:410-8.
  59. Liu J, Wang Q, Ji X, Guo S, Dai Y, Zhang Z, et al. Prevalence of Ureaplasma urealyticum, Mycoplasma hominis, Chlamydia trachomatis infections, and semen quality in infertile and fertile men in China. *Urology* 2014;83:795-9.
  60. Al-Sweih NA, Al-Fadli AH, Omu AE, Rotimi VO. Prevalence of Chlamydia trachomatis, Mycoplasma hominis, Mycoplasma genitalium, and Ureaplasma urealyticum infections and seminal quality in infertile and fertile men in Kuwait. *J Androl* 2012;33:1323-9.
  61. Moretti E, Capitani S, Figura N, Pammolli A, Federico MG, Giannerini V, et al. The presence of bacteria species in semen and sperm quality. *J Assist Reprod Genet* 2009;26:47-56.
  62. Andrade-Rocha FT. Ureaplasma urealyticum and Mycoplasma hominis in men attending for routine semen analysis. Prevalence, incidence by age and clinical settings, influence on sperm characteristics, relationship with the leukocyte count and clinical value. *Urol Int* 2003;71:377-81.
  63. Günyeli I, Abike F, Dünder I, Aslan C, Tapisız OL, Temizkan O, et al. Chlamydia, mycoplasma and ureaplasma infections in infertile couples and effects of these infections on fertility. *Arch Gynecol Obstet* 2011;283:379-85.
  64. La Vignera S, Vicari E, Condorelli RA, D'Agata R, Calogero AE. Male accessory gland infection and sperm parameters (review). *Int J Androl* 2011;34(5 Pt 2):e330-47.
  65. Lobascio AM, De Felici M, Anibaldi M, Greco P, Minasi MG, Greco E. Involvement of seminal leukocytes, reactive oxygen species, and sperm mitochondrial membrane potential in the DNA damage of the human spermatozoa. *Andrology* 2015;3:265-70.
  66. Agarwal A, Mulgund A, Alshahrani S, Assidi M, Abuzenadah AM, Sharma R, et al. Reactive oxygen species and sperm DNA damage in infertile men presenting with low level leukocytospermia. *Reprod Biol Endocrinol* 2014;12:126.
  67. Mahfouz R, Sharma R, Thiyagarajan A, Kale V, Gupta S, Sabanegh E, et al. Semen characteristics and sperm DNA fragmentation in infertile men with low and high levels of seminal reactive oxygen species. *Fertil Steril* 2010;94:2141-6.
  68. Agarwal A, Gupta S, Sharma R. Leukocytospermia quantitation (ENDTZ) test. In: Agarwal A, Gupta S, Sharma R, editors. *Andrological evaluation of male infertility*. Cham: Springer; 2016:69-72.
  69. Wolff H, Anderson DJ. Immunohistologic characterization and quantitation of leukocyte subpopulations in human semen. *Fertil Steril* 1988;49:497-504.
  70. Schöbel WA, Schieferstein G, Uchanska-Ziegler B. Immunocytochemical characterization of round cells in human semen using monoclonal antibodies and the APAAP-technique. *Andrologia* 1989;21:370-6.
  71. Eggert-Kruse W, Bellmann A, Rohr G, Tilgen W, Runnebaum B. Differentiation of round cells in semen by means of monoclonal antibodies and relationship with male fertility. *Fertil Steril* 1992;58:1046-55.
  72. Villegas J, Schulz M, Vallejos V, Henkel R, Miska W, Sánchez R. Indirect immunofluorescence using monoclonal antibodies for the detection of leukocytospermia: comparison with

- peroxidase staining. *Andrologia* 2002;34:69-73.
73. Ricci G, Presani G, Guaschino S, Simeone R, Perticarari S. Leukocyte detection in human semen using flow cytometry. *Hum Reprod* 2000;15:1329-37.
  74. Khodamoradi K, Kuchakulla M, Narasimman M, Khosravizadeh Z, Ali A, Brackett N, et al. Laboratory and clinical management of leukocytospermia and hematospermia: a review. *Ther Adv Reprod Health* 2020;14:2633494120922511.
  75. Brunner RJ, Demeter JH, Sindhwani P. Review of guidelines for the evaluation and treatment of leukocytospermia in male infertility. *World J Mens Health* 2019;37:128-37.
  76. Fritz H, Jochum M, Geiger R, Duswald KH, Dittmer H, Kortmann H, et al. Granulocyte proteinases as mediators of unspecific proteolysis in inflammation: a review. *Folia Histochem Cytobiol* 1986;24:99-115.
  77. Jochum M, Pabst W, Schill WB. Granulocyte elastase as a sensitive diagnostic parameter of silent male genital tract inflammation. *Andrologia* 1986;18:413-9.
  78. Zorn B, Sesek-Briski A, Osredkar J, Meden-Vrtovec H. Semen polymorphonuclear neutrophil leukocyte elastase as a diagnostic and prognostic marker of genital tract inflammation--a review. *Clin Chem Lab Med* 2003;41:2-12.
  79. Kopa Z, Wenzel J, Papp GK, Haidl G. Role of granulocyte elastase and interleukin-6 in the diagnosis of male genital tract inflammation. *Andrologia* 2005;37:188-94.
  80. Zorn B, Virant-Klun I, Meden-Vrtovec H. Semen granulocyte elastase: its relevance for the diagnosis and prognosis of silent genital tract inflammation. *Hum Reprod* 2000;15:1978-84.
  81. Wolff H. Methods for the detection of male genital tract inflammation. *Andrologia* 1998;30 Suppl 1:35-9.
  82. Eggert-Kruse W, Zimmermann K, Geissler W, Ehrmann A, Boit R, Strowitzki T. Clinical relevance of polymorphonuclear (PMN-) elastase determination in semen and serum during infertility investigation. *Int J Androl* 2009;32:317-29.
  83. Endtz AW. [A direct staining method for moist urinary sediment and moist human sperm]. *Ned Tijdschr Geneesk* 1972;116:681-5. Dutch.
  84. Sharma RK, Pasqualotto AE, Nelson DR, Thomas AJ Jr, Agarwal A. Relationship between seminal white blood cell counts and oxidative stress in men treated at an infertility clinic. *J Androl* 2001;22:575-83.
  85. Bowie W. Urethritis in males. In: Holmes KK, Sparling PF, Stamm WE, Wiesner PJ, Piot P, Wasserheit JN, editors. *Sexually transmitted diseases*. 4th ed. New York: McGraw-Hill; 2008;638-50.
  86. Bruce AW, Reid G. Prostatitis associated with *Chlamydia trachomatis* in 6 patients. *J Urol* 1989;142:1006-7.
  87. Berger RE, Alexander ER, Monda GD, Ansell J, McCormick G, Holmes KK. *Chlamydia trachomatis* as a cause of acute "idiopathic" epididymitis. *N Engl J Med* 1978;298:301-4.
  88. Cumming JA, Carrell DT. Utility of reflexive semen cultures for detecting bacterial infections in patients with infertility and leukocytospermia. *Fertil Steril* 2009;91(4 Suppl):1486-8.
  89. Esfandiari N, Saleh RA, Abdoos M, Rouzrokh A, Nazemian Z. Positive bacterial culture of semen from infertile men with asymptomatic leukocytospermia. *Int J Fertil Womens Med* 2002;47:265-70.
  90. Shalika S, Dugan K, Smith RD, Padilla SL. The effect of positive semen bacterial and *Ureaplasma* cultures on in-vitro fertilization success. *Hum Reprod* 1996;11:2789-92.
  91. Meares EM Jr. Bacterial prostatitis vs "prostatosis". A clinical and bacteriological study. *JAMA* 1973;224:1372-5.
  92. Colpi GM, Zanollo A, Roveda ML, Tommasini-Degna A, Beretta G. Anaerobic and aerobic bacteria in secretions of prostate and seminal vesicles of infertile men. *Arch Androl* 1982;9:175-81.
  93. Pajovic B, Pajovic L, Vukovic M. Effectiveness of antibiotic treatment in infertile patients with sterile leukocytospermia induced by tobacco use. *Syst Biol Reprod Med* 2017;63:391-6.
  94. Jung JH, Kim MH, Kim J, Baik SK, Koh SB, Park HJ, et al. Treatment of leukocytospermia in male infertility: a systematic review. *World J Mens Health* 2016;34:165-72.
  95. Lackner J, Schatzl G, Horvath S, Kratzik C, Marberger M. Value of counting white blood cells (WBC) in semen samples to predict the presence of bacteria. *Eur Urol* 2006;49:148-52; discussion 152-3.
  96. Jungwirth A, Diemer T, Kopa Z, Krausz C, Minhas S, Tournaye H. EAU guidelines on male infertility. *Arnhem: European Association of Urology*; 2018.
  97. Ventimiglia E, Capogrosso P, Boeri L, Cazzaniga W, Matloob R, Pozzi E, et al. Leukocytospermia is not an informative predictor of positive semen culture in infertile men: results from a validation study of available guidelines. *Hum Reprod Open* 2020;2020:hoaa039.
  98. Schlegel PN, Sigman M, Collura B, De Jonge CJ, Eisenberg ML, Lamb DJ, et al. Diagnosis and treatment of infertility in men: AUA/ASRM guideline part I. *J Urol* 2021;205:36-43.
  99. Tortolero I, Duarte Ojeda JM, Pamplona Casamayor M, Alvarez González E, Arata-Bellarbarba G, Regadera J, et al. [The effect of seminal leukocytes on semen quality in subfertile males with and without varicocele]. *Arch Esp Urol* 2004;57:921-8. Spanish.
  100. Mongioi LM, Alamo A, Calogero AE, Compagnone M, Giaccone F, Cannarella R, et al. Evaluation of seminal fluid leukocyte subpopulations in patients with varicocele. *Int J Immunopathol Pharmacol* 2020;34:2058738420925719.



101. Saleh RA, Agarwal A, Sharma RK, Nelson DR, Thomas AJ Jr. Effect of cigarette smoking on levels of seminal oxidative stress in infertile men: a prospective study. *Fertil Steril* 2002;78:491-9.
102. Close CE, Roberts PL, Berger RE. Cigarettes, alcohol and marijuana are related to pyospermia in infertile men. *J Urol* 1990;144:900-3.
103. Zhang ZH, Zhu HB, Li LL, Yu Y, Zhang HG, Liu RZ. Decline of semen quality and increase of leukocytes with cigarette smoking in infertile men. *Iran J Reprod Med* 2013;11:589-96.
104. Aitken RJ, Buckingham DW, Brindle J, Gomez E, Baker HW, Irvine DS. Analysis of sperm movement in relation to the oxidative stress created by leukocytes in washed sperm preparations and seminal plasma. *Hum Reprod* 1995;10:2061-71.
105. Harlev A, Agarwal A, Gunes SO, Shetty A, du Plessis SS. Smoking and male infertility: an evidence-based review. *World J Mens Health* 2015;33:143-60.
106. Agarwal A, Rana M, Qiu E, AlBunni H, Bui AD, Henkel R. Role of oxidative stress, infection and inflammation in male infertility. *Andrologia* 2018;50:e13126.
107. Trummer H, Habermann H, Haas J, Pummer K. The impact of cigarette smoking on human semen parameters and hormones. *Hum Reprod* 2002;17:1554-9.
108. Aird IA, Vince GS, Bates MD, Johnson PM, Lewis-Jones ID. Leukocytes in semen from men with spinal cord injuries. *Fertil Steril* 1999;72:97-103.
109. Trabulsi EJ, Shupp-Byrne D, Sedor J, Hirsch IH. Leukocyte subtypes in electroejaculates of spinal cord injured men. *Arch Phys Med Rehabil* 2002;83:31-4.
110. Padron OF, Brackett NL, Sharma RK, Lynne CM, Thomas AJ Jr, Agarwal A. Seminal reactive oxygen species and sperm motility and morphology in men with spinal cord injury. *Fertil Steril* 1997;67:1115-20.
111. Vargas-Baquero E, Johnston S, Sánchez-Ramos A, Arévalo-Martín A, Wilson R, Gosálvez J. The incidence and etiology of sperm DNA fragmentation in the ejaculates of males with spinal cord injuries. *Spinal Cord* 2020;58:803-10.
112. Willén M, Holst E, Myhre EB, Olsson AM. The bacterial flora of the genitourinary tract in healthy fertile men. *Scand J Urol Nephrol* 1996;30:387-93.
113. Pentylala S, Lee J, Annam S, Alvarez J, Veerraju A, Yadlapalli N, et al. Current perspectives on pyospermia: a review. *Asian J Androl* 2007;9:593-600.
114. Yamamoto M, Hibi H, Katsuno S, Miyake K. Antibiotic and ejaculation treatments improve resolution rate of leukocytospermia in infertile men with prostatitis. *Nagoya J Med Sci* 1995;58:41-5.
115. Lackner JE, Märk I, Sator K, Huber J, Sator M. Effect of leukocytospermia on fertilization and pregnancy rates of artificial reproductive technologies. *Fertil Steril* 2008;90:869-71.
116. Castellini C, D'Andrea S, Martorella A, Minaldi E, Necozone S, Francavilla F, et al. Relationship between leukocytospermia, reproductive potential after assisted reproductive technology, and sperm parameters: a systematic review and meta-analysis of case-control studies. *Andrology* 2020;8:125-35.
117. Ricci G, Granzotto M, Luppi S, Giolo E, Martinelli M, Zito G, et al. Effect of seminal leukocytes on in vitro fertilization and intracytoplasmic sperm injection outcomes. *Fertil Steril* 2015;104:87-93.