

## Case report

## Unusual presentation of CREST retinal vasculitis

Effie Z. Rahman\*, Kinley D. Beck, Corey W. Waldman, Jeong-Hyeon Sohn

University of Texas Health San Antonio, 7703 Floyd Curl Dr, San Antonio, TX, 78229, USA



## ARTICLE INFO

## Keywords:

CREST vasculitis  
Retinal vasculitis  
Autoimmune vasculitis

## ABSTRACT

**Purpose:** To report a case of CREST (calcinosis, Raynaud's phenomenon, esophageal dysmotility, sclerodactyly, telangiectasias) syndrome-induced retinal vasculitis in the setting of ocular inflammation soon after recent micropulse cyclophotocoagulation (mTS-CPC).

**Observations:** Our patient developed CREST associated retinal vasculitis in both eyes (right > left) eight days after receiving mTS-CPC in her left eye. There was initial concern for sympathetic ophthalmia due to the resulting bilateral inflammation. The patient was treated with prednisone with resolution of her symptoms.

**Conclusions:** This is the first case of CREST retinal vasculitis that appears to be directly triggered by inflammation caused by mTS-CPC.

## 1. Introduction

CREST syndrome (calcinosis, Raynaud's phenomenon, esophageal dysmotility, sclerodactyly, telangiectasias) is a limited form of scleroderma, primarily affecting specific organ systems rather than the entire body.<sup>1</sup> Most ocular symptoms of CREST are limited to the anterior segment and include keratoconjunctivitis sicca and eyelid telangiectasias. Posterior pole findings typically mimic those of hypertensive retinopathy and include vascular tortuosity, cotton wool spots (CWS), and mild retinal microvascular abnormalities. Additional posterior pole findings are quite rare – to date only two cases of CREST vasculitis have ever been published.<sup>2</sup> Other rare ocular CREST presentations include two cases of juxtafoveal telangiectasias,<sup>3–5</sup> one central retinal artery occlusion (CRAO),<sup>6</sup> two branch retinal artery occlusions (BRAO),<sup>2,3</sup> and three cases of granulomatous uveitis.<sup>7,8</sup>

We describe a novel case of CREST vasculitis in which our patient presented with concern for sympathetic ophthalmia due to the resulting bilateral inflammation that ensued following a transscleral micropulse cyclophotocoagulation (mTS-CPC) treatment for end-stage glaucoma in her left eye eight days prior. To date, this is the first reported case of CREST vasculitis that may have been triggered by intraocular inflammation following mTS-CPC. This is also the first case report in which sympathetic ophthalmia was a differential diagnosis for CREST vasculitis.

## 1.1. Case report

A 65-year-old female presented with sudden onset of painless, decreased vision in both eyes. The patient had been feeling weak at the time of presentation. She had a history of difficulty with swallowing which had flared over the past few days. The patient also reported chest tightness and pain radiating down her left arm with exertion. Eight days prior to the above presentation, the patient had received mTS-CPC for refractory glaucoma in her left eye. Her past medical history included CREST syndrome with known Raynaud's phenomenon, diabetes mellitus type 2, asthma, chronic kidney disease stage 3, osteoporosis, anemia, hearing loss, pancreatitis and pulmonary hypertension. Surgical history included hemorrhoidectomy, adenoidectomy and hysterectomy. Her ocular history was significant for cataract surgery, chronic angle closure glaucoma, laser peripheral iridotomy (LPI) and trabeculectomy OU. She was currently taking timolol OU, latanoprost OD, prednisolone acetate OS, moxifloxacin OS, and oral ranitidine, nystatin, pantoprazole, KCl, atorvastatin, amlodipine, prednisone, cetirizine, metformin, aspirin and sertraline. She had drug allergies to clindamycin and sulfa drugs. She denied alcohol, tobacco or drug use. Her family history was significant for primary open angle glaucoma, Parkinson's disease and coronary artery disease (CAD) in her father and CAD in her mother. Review of systems was positive for dyspnea on exertion and difficulty swallowing. On examination best corrected Snellen visual acuity (BCVA) was 20/30 OD and 20/100 OS. Her visual field was constricted in all four quadrants OS. Pupils measured 4 mm in dark and 3 mm in light, and no relative

\* Corresponding author.

E-mail addresses: [effie.rahman@gmail.com](mailto:effie.rahman@gmail.com), [rahmane@uthscsa.edu](mailto:rahmane@uthscsa.edu) (E.Z. Rahman), [kinleybeck@gmail.com](mailto:kinleybeck@gmail.com) (K.D. Beck), [waldmanc@uthscsa.edu](mailto:waldmanc@uthscsa.edu) (C.W. Waldman), [sohnj@uthscsa.edu](mailto:sohnj@uthscsa.edu) (J.-H. Sohn).

<https://doi.org/10.1016/j.ajoc.2021.101172>

Received 14 July 2019; Received in revised form 18 April 2021; Accepted 19 July 2021

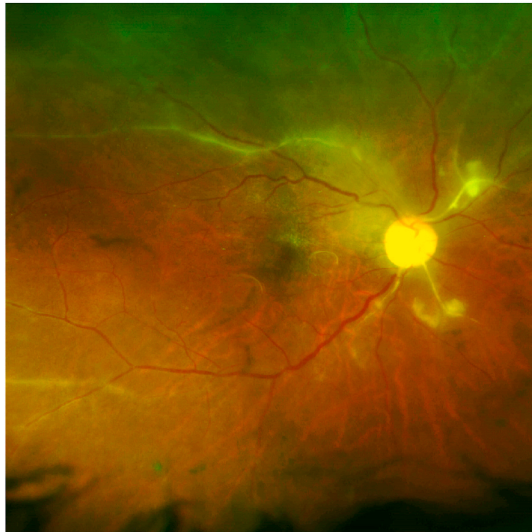Available online 22 July 2021

2451-9936/© 2021 Published by Elsevier Inc. This is an open access article under the CC BY-NC-ND license (<http://creativecommons.org/licenses/by-nc-nd/4.0/>).

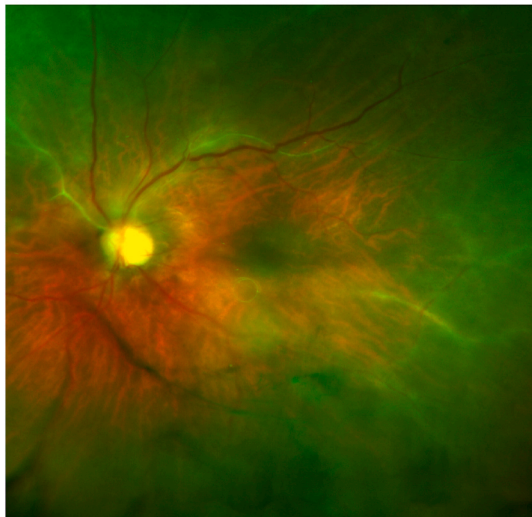
afferent pupillary defect (RAPD) was noted. Intraocular pressure measured 9 mm Hg and 15 mm Hg respectively. On anterior segment exam a cystic bleb was noted superiorly in both eyes and endopigment was noted across her posterior lens capsule OS. There was 1+ anterior chamber cell in the right eye and no inflammation noted in her left eye. The patient had patient LPs in both eyes and scatter iris-corneal touch and lens-iris touch in the left eye. A posterior chamber intraocular lens was present OD and sulcus lens was present OS. On dilated exam, a mild vitritis with a mix of white blood cells and pigment was noted in the right eye. She had a 0.8 and 0.9 cup to disk ratio respectively with inferior thinning OU. Retinal pigment epithelial (RPE) mottling was noted in both eyes. In the right eye, CWS were visible and white membranes were noted to emanate from the disc. Vessels were sclerotic with mild perivascular sheathing OU. In her left eye, CWS were noted along the nasal arcade.

Our patient was started on prednisone 40 mg by mouth and prednisolone acetate 1 % ophthalmic suspension was started six times a day OD. She returned for follow-up a day later and was found to have CWS

A)



B)



**Fig. 1.** Optos photos of the right (A) and left (B) eye. Images demonstrate (A) white membranes extending from the nasal disc. Vasculitis superiorly, nasally and temporally, and mild retinal pigment epithelial (RPE) mottling. (B) Vasculitis nasally and temporally.

and vasculitis in all four quadrants OU. At this time optos photos (Fig. 1: A-B) were taken. White membranes extended from the disc nasally, and vasculitis was noted superiorly, nasally and temporally OD. Vasculitis was observed nasally and temporally OS. Fluorescein angiogram (FA) (Fig. 2: A-B) was taken and demonstrated significant hypofluorescence from nonperfusion during the arteriovenous phase and perivascular hyperfluorescence with leakage during the late recirculation phase OU. Optical coherence tomography (OCT) macula demonstrated retinal thickening OD > OS. Uveitis and infectious work-up was negative, including antineutrophil cytoplasmic antibodies (ANCA), rheumatoid factor (RF), human leukocyte antigen-B27 (HLA-B27), angiotensin converting enzyme (ACE), lysozyme, interferon gamma releasing assay, bilirubin, Bartonella antibodies, rapid plasma reagin (RPR), reticulocyte count and pancreatic elastase-1. However, antinuclear antibody (ANA) with reflex titer was positive > 1:640.

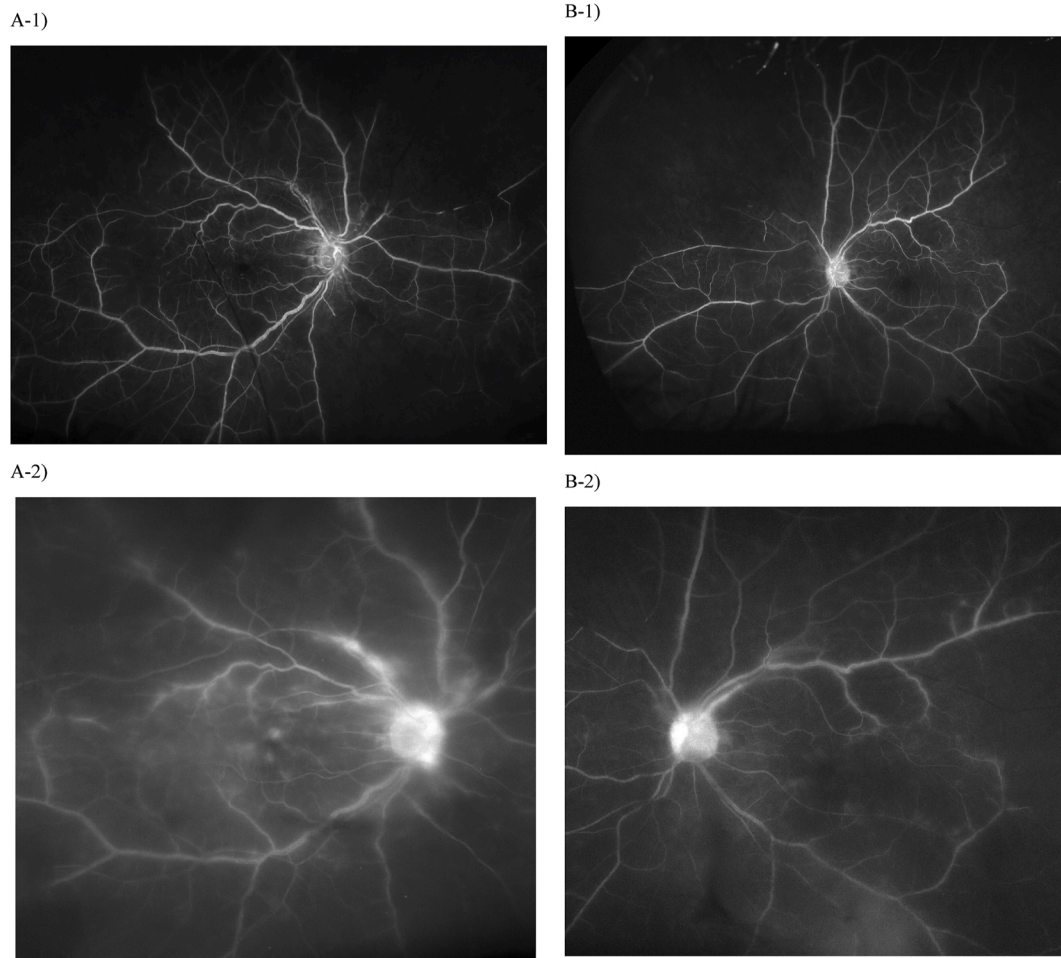
The patient had a history of hypertension that was well controlled at the time of presentation (120/80). She was evaluated by cardiology and underwent a nuclear stress test and a transthoracic echocardiogram, both of which were unremarkable for decompensated pulmonary hypertension. Her echocardiogram indicated sinus bradycardia with non-specific T-wave abnormalities. Her transthoracic echocardiogram was stable showing a left ventricular (LV) ejection fraction of 60 %, normal wall motion and normal LV dimension without hypertrophy. Normal right ventricular size and function were noted. She had mild right atrial enlargement and no pericardial effusions. CCP and SCL-70 were negative and anti-centromere antibodies were positive at >1:640. On follow-up the patient's BCVA was 20/40 OD and 20/60 OS. She had 2+ cell/flare OD but demonstrated resolving CWS and decreased white membranes emanating from the disc OU. Her vasculitis was stable and a few sclerotic vessels were noted OU. On follow-up one month later her BCVA was 20/30 OU and she was found to have residual cuffing and sheathing OD, and rare cell OS. Her OCT macula remained stable and she was gradually tapered off topical steroids. The patient was started on a monthly prednisone taper consisting of 30 mg, 20 mg, 15 mg, 10 mg and 5 mg before stopping completely. She was also started on mycophenolate 1000 mg BID. Three months later her BCVA was 20/30 OU. Her retinal vasculitis remained stable OU without perivascular thickening over the next seven months.

## 2. Discussion

Infectious and autoimmune causes are commonly the source for vasculitis; however, CREST induced vasculitis is exceedingly rare. Only two cases have ever been reported in the literature.<sup>2</sup> To our knowledge we present the first case of CREST vasculitis likely triggered by recent mTS-CPC. Our patient did not have a history of retinal vasculitis, yet developed it soon after receiving mTS-CPC in her left eye, which may have created an inciting inflammatory event. This case represents the first report of CREST vasculitis masquerading as possible sympathetic ophthalmia given her recent mTS-CPC treatment and acute, bilateral inflammatory onset. CREST ophthalmic presentations are rare, and those involving the retina are limited. Prior cases published on CREST vasculitis did not appear to have been triggered by an inciting event.<sup>2-8</sup> Our case is the second case ever reported of CREST vasculitis occurring without a concurrent arteriolar occlusive event. Although the development of CREST vasculitis may have occurred incidentally, the inflammation resulting from mTS-CPC may have triggered an inflammatory cascade.

## 3. Conclusions

Our case report is the first to present a case of CREST vasculitis masquerading as possible early sympathetic ophthalmia following mTS-CPC. Given that sympathetic ophthalmia is a known and visually threatening complication of mTS-CPC, it is an important consideration; however, it is also important to reassess the patient's known systemic



**Fig. 2.** Fluorescein angiogram OD, OS.

Images demonstrate (A-1) arteriovenous (AV) phase at 40 seconds: hypofluorescence from nonperfusion was noted supranasally, infranasally and supratemporally. Retrograde venous filling noted supratemporally. (A-2) Late recirculation phase at 8 minutes: perivascular hyperfluorescence with capillary nonperfusion are noted. Areas of macular leakage and optic nerve staining are present. (B-1) AV phase at 1 minute and 7 seconds: hypofluorescence from nonperfusion was noted superionasally. (B-2) Late recirculation phase at 7 minutes and 25 seconds: perivascular hyperfluorescence with capillary nonperfusion and mild optic nerve head staining are noted.

conditions and elicit any systemic symptoms that may have evolved. CREST vasculitis is a rare manifestation, but should be considered in patients with known CREST syndrome. Our case demonstrates an interesting correlation with the development of CREST vasculitis following mTS-CPC.

#### 4. Patient consent

The University of Texas Health San Antonio Institutional Review Board deemed protocol approval not necessary for this case report.

#### Funding

No funding or grant support.

#### Authorship

All authors attest that they meet the current ICMJE criteria for Authorship.

#### Declaration of competing interest

The following authors have no financial disclosures (ER, KB, CW, JS).

#### Acknowledgements

None.

#### References

- Miyawaki S, Asanuma H, Nishiyama S, Yoshinaga Y. Clinical and serological heterogeneity in patients with anticentromere antibodies. *J Rheumatol.* 2005;32(8):1488–1494.
- Yang S, Kopplin LJ, Rosenbaum JT. Retinal vasculitis associated with CREST syndrome. *Am J Ophthalmol Case Rep.* 2018;10(2):185–188.
- Gomes BA, Santhiago MR, Magalhães P, Kara-Junior N, Azevedo MN, Moraes Jr HV. Ocular findings in patients with systemic sclerosis. *Clinics.* 2011;66(3):379–385.
- Huerva V, Sánchez MC. Juxtafoveal telangiectasis associated with CREST syndrome. *Ocul Immunol Inflamm.* 2008;16(4):195–197.
- Proctor B, Chang T, Hay D. Parafoveal telangiectasia in association with CREST syndrome. *Arch Ophthalmol.* 1998;116(6):814–815.
- Raja MS, Marshall T, Burton BJ. Acute central retinal artery occlusion presenting as CREST syndrome: a case report. *Cases J.* 2009 Jan 5;2(1):9.
- Akman A, Akova YA, Yücel E, Aydin P. Granulomatous anterior uveitis in a patient with CREST syndrome. *Ocul Immunol Inflamm.* 2000;8(3):201–203.
- Courtade M, Gicquel JJ, Mercie M, Vabres B, Dighiero P. Granulomatous uveitis and CREST syndrome: a case study. *J Fr Ophthalmol.* 2004 Oct;27(8):918–920.