

# Representation of Central Endothelial Cell Density by Analysis of Single Best Specular Microscopy Image Regardless of Cell Size Variance

Yue Shi<sup>1,2</sup>, Jianyan Huang<sup>1,2</sup>, Elmira Baghdasaryan<sup>1,2</sup>, Ping Huang<sup>1,2</sup>, Xiwen Huang<sup>1</sup>, Srinivas R. Sadda<sup>1,2</sup>, and Olivia L. Lee<sup>1,2</sup>

<sup>1</sup> Doheny Eye Institute, Los Angeles, CA, USA

<sup>2</sup> Department of Ophthalmology, David Geffen School of Medicine at UCLA, Los Angeles, CA, USA

**Correspondence:** Olivia L. Lee, Doheny Eye Institute, 1355 San Pablo Street, Los Angeles, CA 90033, USA. e-mail: olee@doheny.org

**Received:** 17 October 2018

**Accepted:** 25 March 2019

**Published:** 29 May 2019

**Keywords:** corneal endothelial cells density; specular microscopy; polymegathism; coefficient of variance in cell size

**Citation:** Shi Y, Huang J, Baghdasaryan E, Huang P, Huang X, Sadda SR, Lee OL. Representation of central endothelial cell density by analysis of single best specular microscopy image regardless of cell size variance. *Trans Vis Sci Tech.* 2019;8(3):23, <https://doi.org/10.1167/tvst.8.3.23>

Copyright 2019 The Authors

**Purpose:** The purpose of this study is to evaluate whether a single best image can represent central endothelial cell density (ECD) in corneas of differing cell size coefficient of variance (CV).

**Methods:** Four hundred one healthy eyes but with variant CV values were enrolled. For each eye, three nonoverlapping central cornea endothelium images were obtained with Konan NSP-9900 specular microscope. ECD and CV were evaluated by two independent graders using the well-established Center method. Only corneas with high image quality rating (IQR) and ECD >800 cell/mm<sup>2</sup> by both graders were included in the study. The study sample was stratified into five CV levels (CV ≤ 35; ≥36; ≥38; ≥40; and ≥45). In each CV level, the ECD agreement, ECD variance, and the correlation between the ECD variation and CV values were analyzed. In addition, the ECD intragrader reproducibility and interframe differences were also analyzed for all levels except CV ≤ 35.

**Results:** The study sample includes a total of 278 eyes. High ECD agreement for the two independent graders (intraclass correlation coefficient [ICC] > 0.99), high ECD intragrader reproducibility (ICC > 0.95), low ECD variance (2.0% ± 1.6%, overall), no correlation between the ECD variation and the CV value (*P* > 0.05), and no significant ECD difference among frames (*P* > 0.05) was found in any studied CV levels.

**Conclusions:** CV does not appear to be associated with ECD variance in the central cornea.

**Translational Relevance:** This finding highlights that in healthy corneas but with high CV values, ECD can be reliably analyzed using one single image of best quality.

## Introduction

Cornea endothelial cell density (ECD) is an important factor in the evaluation of corneal health biomarker. Reduction in ECD indicates an attenuation of the corneal endothelium and may proceed to corneal edema, loss of visual acuity, and painful bullous keratopathy. Counting ECD accurately and in a reproducible manner plays an important role in this evaluation.

ECD variation usually would not be large between images captured from different locations of the central cornea.<sup>1</sup> We have demonstrated in previous

studies that cell analysis performed on the single best specular image would achieve a representative ECD value for the entire central cornea.<sup>1</sup> We would like to know whether the statement still holds in corneas with high coefficient of variance (CV) value.

Previous studies showed that image quality played a critical role in ECD consistency between frames of varying sample locations. Lower image quality increases ECD variation by introducing grader error.<sup>2-4</sup> In an image set with various levels of image quality, grading a single “best” image provides a more representative ECD value than the common practice of averaging multiple images.<sup>5</sup>

Our group also showed that, with standardized training and good image quality, cell density variation across nonoverlapping images can be negligible in eyes, no matter with or without guttata.<sup>1</sup> However, it is not clear that whether polymegathism associated with high CV levels has an impact on ECD variance.

Polymegathism is common in many situations, that is, contact lens wear,<sup>6–10</sup> cataract surgery,<sup>11–17</sup> glaucoma,<sup>18–20</sup> diabetes,<sup>21</sup> or simply aging.<sup>22–24</sup> It is necessary to develop a way to achieve reliable ECD values in these corneas, using the Konan imaging and center method.

The purpose of this study was to determine, given good image quality and in the absence of pre-existing endotheliopathy, ECD variance in normal corneas with differing levels of CV. We analyzed the impact of CV on ECD variation, and whether the ECD variation across frames allows grading the single best frame to achieve a representative ECD value for the entire central cornea, especially in eyes with polymegathism.

## Methods and Materials

Four hundred one corneas were imaged using the Konan NSP 9900 specular microscopy (Konan Medical USA Inc., Irvine, CA) at Doheny Eye Center UCLA in Pasadena, California. All patients were informed and gave their consent to the study in accordance to the Declaration of Helsinki. Institutional review board approval was obtained.

These eyes had no history of intraocular or corneal surgery, noncontact lens wearers, and no history of corneal trauma or inflammation or infection. Eyes with Fuchs endothelial dystrophy or presence of endothelial guttae were excluded, as were any eyes with other pre-existing corneal endothelial pathology or lack of corneal clarity.

The central cornea of each eye was imaged three times to generate three nonoverlapping endothelial images in the central cornea. Central cornea is defined as within the central 3 mm diameter.

At the Doheny Image Reading and Research Laboratory (DIRRL) in Los Angeles, California, all images were analyzed using a dual grader and one adjudicator system<sup>3</sup> to classify image quality and determine ECD and CV values. Two certified reading center graders independently classified each image as good, fair, or poor quality based on a previously published specular image quality scale<sup>5</sup> developed by our group, then performed manual specular cell analysis to produce ECD and CV values. In order

to achieve most reliable ECD values (single best is better than averaging), the graders were to grade on the best quality image of their own choice out of the three. ECD and CV values were evaluated using the Konan center method<sup>25–27</sup> in CellChek software. Any eye with very low ECD signifying pathologic endotheliopathy ( $ECD \leq 800$  cells/mm<sup>2</sup>) were excluded from analysis.

If the ECD determination between the two graders was  $\geq 5\%$ , and/or CV value from any grader  $>35$ , the images were flagged for adjudication. If not, the first two graders were considered as the final grader pair by default. When the adjudicator became involved, he/she independently determined the ECD by analyzing the best single image of his/her choice, and the adjudicator's ECD was compared with the ECDs of both initial graders. The final pair grader was determined among the three graders by the pair that achieves the smaller ECD variance, if it is  $<5\%$ . In fact, all the cases involved achieved final pair ECD with a variance  $<5\%$ .

ECD variance was defined as the difference of ECD determination between the two graders. It was computed using [equation 1](#). Note the two graders may choose to grade the image deemed as of the best quality, which was not necessarily the same image in the set.

$$ECD \text{ variation (\% error)} = \frac{ECD_{HIGH} - ECD_{LOW}}{ECD_{LOW}} \times 100 < 5\% \quad (1)$$

Finally, only image sets with all three images scored as “good” by both graders in the final grader pair were included in this study. This is to avoid a difference in image quality confounding the ECD reproducibility, as this will increase ECD difference between graders.<sup>2–4</sup>

Final ECD variances were determined by the ECD variance in the final grader pair, and final CV values were determined by the average CV achieved by the final grader pair.

## Determine the Correlation Between the ECD Variation and the CV Values

Average ECD variance and standard deviation were stratified for each CV cutoff levels, namely,  $CV \leq 35$ ;  $CV \geq 36$ ;  $CV \geq 38$ ;  $CV \geq 40$ , and  $CV \geq 45$ . Overall and stratified ECD variances were then correlated with corresponding group of CV values to determine the impact of CV on ECD variance.

**Table 1.** ECD Analyses Stratified by CV Cutoff Levels

	Overall	CV $\leq$ 35	CV $\geq$ 36
Total cases	278	188	90
ICC between the two graders (95% CI)	0.996 (0.995–0.997)	0.997 (0.996–0.998)	0.994 (0.992–0.996)
ECD variance > 5% cases, <i>n</i> (%)	7 (2.5)	4 (2.1)	3 (3.3)
Mean ECD variance $\pm$ standard deviation (range), %	2.0 $\pm$ 1.6 (0–14.3)	2.0 $\pm$ 1.6 (0–14.3)	2.0 $\pm$ 1.5 (0–6.7)
Pearson correlation CV vs. ECD variance	0.002	–0.0005	0.005
<i>P</i> value	0.915	0.993	0.914

CI, confidence interval.

**Table 1.** Extended

	CV $\geq$ 38	CV $\geq$ 40	CV $\geq$ 45
Total cases	71	40	14
ICC between the two graders (95% CI)	0.993 (0.989–0.996)	0.991 (0.984–0.995)	0.993 (0.980–0.998)
ECD variance > 5% cases, <i>n</i> (%)	3 (4.2)	2 (5.0)	1 (7.1)
Mean ECD variance $\pm$ standard deviation (range), %	2.1 $\pm$ 1.5 (0–6.7)	2.1 $\pm$ 1.6 (0–6.7)	2.0 $\pm$ 1.7 (0.4–6.2)
Pearson correlation CV vs. ECD variance	–0.034	–0.043	–0.013
<i>P</i> value	0.518	0.591	0.957

### Evaluate the Intra-grader ECD Reproducibility and Interframe ECD Differences, in Polymegathism Corneas

For the image set in which final determined CV was larger than 35, further study was performed to examine the ECD agreement among frames and ECD reproducibility in repeated analyses. In the further study, each frame was evaluated twice by each of the two graders in a masked manner. The interframe ECD difference across three frames was evaluated by analysis of variance (ANOVA) for each CV level. The intra-grader ECD reproducibility was examined by the intraclass correlation coefficient (ICC) between the two analyses, on the same frame and on the mean ECD across frames, respectively.

## Results

There were 278 sets of specular microscopy images that passed the study's inclusion and exclusion criteria; these were manually analyzed by dual grader system at DIRRL for inclusion into the study. The ECD for the entire cohort ranged from 902 to 3279 cells/mm<sup>2</sup>. The average ECD was 2155.44 cells/mm<sup>2</sup> with a standard deviation of 523.34 cells/mm<sup>2</sup>.

### Polymegathism Does Not Increase the ECD Variation

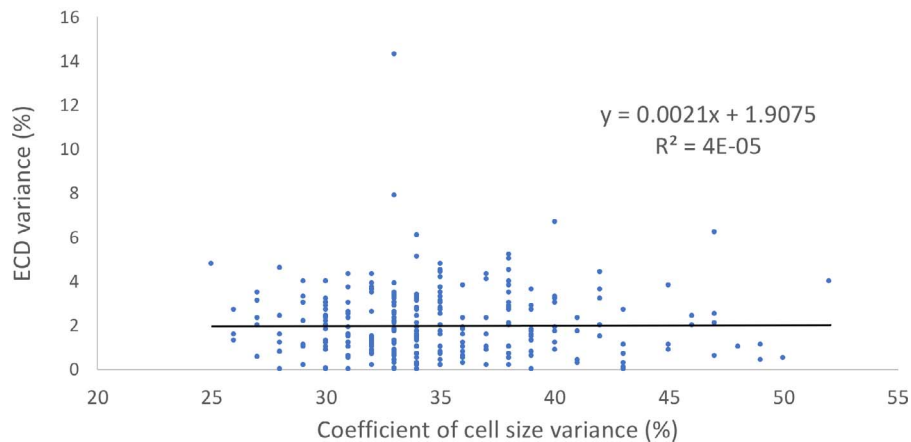
The number of cases, agreement between graders, ECD variance, and the correlation between ECD variance and CV values for each CV cutoff level were listed in [Table 1](#). There was no correlation between the ECD variance and the CV value ( $P > 0.05$ ), regardless of the CV cutoff levels. Refer to [Table 2](#) and [Figure 1](#).

### High Intra-grader ECD Reproducibility and No Significant ECD Differences Among Frames, in Polymegathism Corneas

Intra-grader reproducibility was analyzed between two masked readings of the same grader on the same frame. It was represented by the ICC of the ECDs between the two analyses for each frame and also the mean ECD of three frames ([Table 2](#)). The ICCs were all above 0.95, indicating that the intra-grader ECD reproducibility was excellent either in single frame or in three frames averaging, regardless of the CV levels.

ANOVA shows that the interframe differences of ECD were not significant for any CV cutoffs ( $P > 0.05$ ; [Table 3](#)).

## Overall



**Figure 1.** Correlation between the ECD variance and CV values. There was no significant correlation between the two.

## Discussion

In this study, we have found that ECD variance does not increase with increase in CV values. Despite high CV, even in cases of frank polymegathism, no statistically significant difference between nonoverlapping specular frames was found. However, it should be noted that the high intragrader reproducibility associated with this cohort can be explained by good image quality and exclusion of eyes with pathologically low ECD ( $\leq 800$  cells/mm<sup>2</sup>) suggesting true or impending corneal edema.

The ECD variance between graders (inter- and intragrader ECD agreement) in our study are comparable with that of other studies in the literature, which studied normal corneas and eye bank donor corneas. Table 4 lists the two most referenced studies in the literature and one study from our group, using the Konan Center method to evaluate the ECD of donor corneas or normal corneas in vivo. The data in this study indicate that it is possible to apply the same methodology for evaluating quantitative specular

data from corneas with high CVs that has been used to evaluate normal eyes.

Previous studies have shown that the interlocation ECD difference is not significant, as replicated in this study. Obregon et al.<sup>1</sup> analyzed the consistency of ECD value in different central cornea locations for normal corneas and diseased cornea with or without guttata. They found regardless of the clinical diagnosis of whichever conditions that were studied, the interlocation ECD difference is small. Similarly, in our study, we found no significant difference amongst ECD values obtained from different frames regardless of level of CV. The single best image yields ECD values that are representative of the entire central cornea, regardless of the CV level, as long as the cornea is stable. Therefore, if all images are of equally good quality (assuming they are all excellent), then it makes no significant difference whether the individual graders agree upon which is the single best image to select for ECD analysis.

In this study, we adopted only manual analysis due to many previous studies showing that automated

**Table 2.** ICC of the First and Second Analysis From One Single Grader

ICC (95% CI)	CV $\geq$ 36	CV $\geq$ 38	CV $\geq$ 40	CV $\geq$ 45
Frame 1	0.967 (0.949–0.978)	0.956 (0.934–0.975)	0.994 (0.989–0.997)	0.996 (0.988–0.998)
Frame 2	0.994 (0.990–0.996)	0.994 (0.991–0.997)	0.993 (0.987–0.996)	0.991 (0.975–0.997)
Frame 3	0.994 (0.990–0.996)	0.993 (0.989–0.996)	0.992 (0.985–0.996)	0.993 (0.980–0.997)
Mean ECD of three frames	0.991 (0.987–0.994)	0.989 (0.984–0.993)	0.992 (0.987–0.994)	0.988 (0.972–0.995)

CI, confidence interval.

**Table 3.** Mean ECD Values Between Nonoverlapping Central Frames From Corneas Stratified by CV Values

Mean $\pm$ SD	CV $\geq$ 36	CV $\geq$ 38	CV $\geq$ 40	CV $\geq$ 45
Frame 1	2174 $\pm$ 517	2150 $\pm$ 521	2128 $\pm$ 507	2051 $\pm$ 480
Frame 2	2184 $\pm$ 521	2164 $\pm$ 490	2128 $\pm$ 492	2057 $\pm$ 457
Frame 3	2186 $\pm$ 489	2168 $\pm$ 593	2137 $\pm$ 500	2061 $\pm$ 484
<i>P</i> value	0.985	0.978	0.995	0.998

The mean ECDs are the average value of the two final pair graders. *P* values were from the ANOVA among the difference of the ECDs of the three frames. None of them achieved a *P* value smaller than 0.05, suggesting there is no difference between ECD values. Interframe ECD differences were not significant in any CV level.

ECD analysis significantly overestimates ECD in the eyes with high polymegathism and/or large cell size, compared with manual analysis.<sup>5,25,28,29</sup> For the present study, we used only trained and certified reading center graders to perform the specular ECD analysis to eliminate confounding due to inexperience of the grader in performing manual method ECD analysis.

There are some limitations in this study. The sample size was limited in the polymegathism (very high CV) corneas. The number of high CV corneas included in this study is much lower than the low CV corneas in the sample. Involving more high CV corneas would make our study results more robust. However, these eyes were difficult to recruit because of our strict exclusion criteria that eliminated pseudophakic and eyes with comorbidities. Therefore, our findings may not extrapolate to pathologic eyes that are more commonly imaged for clinical purposes (besides eye banking) than normal corneas. In addition, we have no record of the patients' age in this study, which could be one of the important factors to explain the low ECD variance in the high CV corneas. Furthermore, the specular microscopy analysis performed in this study was done only by fixed frame technique using manually graded Center method in Konan CellChek software. Whether our results can extend to specular images captured on another device or analyzed using different methods or algorithms requires further validation.

There are also strengths in this study. Firstly, the determinations of CV value for each cornea were very reliable. We used a masked grading system that involves two independent certified graders to determine the CV values. Once even one grader reports a CV value greater than 35, an adjudicator became involved. This three-grader system guaranteed that the determination of high CV was reproducible. Secondly, the dual grader and one adjudicator system

also guaranteed reliable determinations of ECD. The high ICC in inter- and intragrader agreement exemplifies the high reliability of ECD evaluation in our study. Thirdly, this study is the first to describe the impact of high CV in ECD variance inter-, intragrader, and interframes.

## Conclusions

In corneas with ECD values in the normal range, CV does not play a role in ECD variance. Even in cases of polymegathism with normal ECD, there does not appear to be an associated increase in ECD variance, interframe ECD differences, or decreased intragrader ECD agreement. Using manual grading and Konan Center method on nonoverlapping good quality specular images of the central cornea, ECD can be reliably evaluated on a single best image, even in the presence of polymegathism. Practically speaking, our study results suggest a time and effort saving recommendation of performing ECD analysis on a single image instead of averaging the analysis of multiple images per eye.

In addition, this study conveys significant indications in cornea clinical practice: (1) relevance to patients with high CV—does not necessarily mean low ECD; therefore, patients with high CV will not necessarily experience corneal decompensation; (2) implications for eye banking—donor cornea with high CV but normal ECD can still be considered for transplantation and do not need to be excluded from donor pool.

Further study may extend to further validate the results in a larger population of high CV corneas, in stratified groups of different clinical causes leading to polymegathism, as well as other ECD evaluation methods.

**Table 4.** Inter- and Intra-grader ECD Variance Compared With Literature

	Study/Authors	
	Benetz et al. <sup>3</sup>	de Sanctis et al. <sup>27</sup>
Frame	Variable frame	Fixed frame
Counting method	Konan Center method	Konan Center method
Cornea	Eye bank corneas	Normal cornea in vivo
Grading system	Dual grader + adjudicator	Two graders on the same image per eye
Image/eyes	645 images	49 eyes, 3 images per eye
Intergrader ECD variance range	No <i>P</i> value reported 0 to 23%	Not significant ( <i>P</i> > 0.05) −17% to +14%
Intergrader ECD ICC	0.88 (95% CI: 0.86 to 0.90)	0.86 (95% CI: 0.79 to 0.93)
Intra-grader ECD variance/ICC	0 to 4% one reader 0 to 12% other reader ICC not reported	NA
Intergrader ECD variance <5% in all images, %	69	NA
Intergrader ECD variance <5% in excellent IQR images, %	93	NA
Intergrader ECD variance <5% in good IQR images, %	77	NA

The intergrader ECD variance range, ICC, percentage of cases with less than 5% intergrader ECD variance, and intra-grader ECD ICC are all comparable to the studies in the literature. Because we used only images of top level of image quality, we only compared the data in the literature on the excellent or good quality images. CI, confidence interval; IQR, image quality rating; NA, not available.

**Table 4.** Extended

	Study/Authors	
	Huang et al. <sup>5</sup>	This Study
Frame	Fixed frame	Fixed frame
Counting method	Konan Center method	Konan Center method
Cornea	Eye bank corneas	Normal and high CV corneas in vivo
Grading system	Dual grader + adjudicator	Dual grader + adjudicator
Image/eyes	536 images	278 eyes, 3 images per eye
Intergrader ECD variance range	Not significant ( <i>P</i> > 0.05) in excellent/good IQR images.	Not significant ( <i>P</i> > 0.05) 0 to 14.3%
Intergrader ECD ICC	Excellent IQR: 0.96 (0.94 to 0.98) Good IQR: 0.98 (0.97 to 0.99)	0.996 (95% CI: 0.995 to 0.997)
Intra-grader ECD variance/ICC	Excellent IQR: 0.99 (0.98 to 0.99) Good IQR: 0.99 (0.98 to 0.99)	>0.95
Intergrader ECD variance <5% in all images, %	67.0	97.5
Intergrader ECD variance <5% in excellent IQR images, %	98.5	97.5
Intergrader ECD variance <5% in good IQR images, %	83.5	NA

## Acknowledgments

Disclosure: **Y. Shi**, None; **J. Huang**, None; **E. Baghdasaryan**, None; **P. Huang**, None; **X. Huang**, None; **S.R. Sadda**, None; **O.L. Lee**, None

## References

- Jacome LFO, Modak C, Huang J, Sassa SR, Chopra V, Lee OL; Doheny Image Reading Center. Consistency in endothelial cell density values from different central locations as graded by specular microscopy. *Invest Ophthalmol Vis Sci.* 2014;55:2065–2065.
- McCarey BE, Edelhauser HF, Lynn MJ. Review of corneal endothelial specular microscopy for FDA clinical trials of refractive procedures, surgical devices and new intraocular drugs and solutions. *Cornea.* 2008;27:1–16.
- Benetz BA, Gal RL, Ruedy KJ, et al; Cornea Donor Study Group. Specular microscopy ancillary study methods for donor endothelial cell density determination of cornea donor study images. *Curr Eye Res.* 2006;31:319–327.
- Lass JH, Gal RL, Ruedy KJ, et al; Cornea Donor Study Group. An evaluation of image quality and accuracy of eye bank measurement of donor cornea endothelial cell density in the Specular Microscopy Ancillary Study. *Ophthalmology.* 2005;112:431–440.
- Huang J, Tepelus TC, Huang P, et al. Specular microscopy image quality scale for endothelial cell density determination in donor cornea tissue. *Int J Eye Bank.* 2017;5:1–6.
- Stocker EG, Schoessler JP. Corneal endothelial polymegathism induced by PMMA contact lens wear. *Invest Ophthalmol Vis Sci.* 1985;26:857–863.
- Carlson KH, Bourne WM, Brubaker RF. Effect of long-term contact lens wear on corneal endothelial cell morphology and function. *Invest Ophthalmol Vis Sci.* 1988;29:185–193.
- Setälä K, Vasara K, Vesti E, Ruusuvaara P. Effects of long-term contact lens wear on the corneal endothelium. *Acta Ophthalmol Scand.* 1998;76:299–303.
- Holden BA, Sweeney DF, Vannas A, Nilsson KT, Efron N. Effects of long-term extended contact lens wear on the human cornea. *Invest Ophthalmol Vis Sci.* 1985;26:1489–1501.
- Mac Rae SM, Matsuda M, Shellans S, Rich LF. The effects of hard and soft contact lenses on the corneal endothelium. *Am J Ophthalmol.* 1986;102:50–57.
- Mencucci R, Ponchietti C, Virgili G, Giansanti F, Menchini U. Corneal endothelial damage after cataract surgery: microincision versus standard technique. *J Cataract Refract Surg.* 2006;32:1351–1354.
- Bourne RR, Minassian DC, Dart JK, Rosen P, Kaushal S, Wingate N. Effect of cataract surgery on the corneal endothelium: modern phacoemulsification compared with extracapsular cataract surgery. *Ophthalmology.* 2004;111:679–685.
- Beltrame G, Salvetat ML, Driussi G, Chizzolini M. Effect of incision size and site on corneal endothelial changes in cataract surgery. *J Cataract Refract Surg.* 2002;28:118–125.
- Storr-Paulsen A, Norregaard JC, Ahmed S, Storr-Paulsen T, Pedersen TH. Endothelial cell damage after cataract surgery: divide-and-conquer versus phaco-chop technique. *J Cataract Refract Surg.* 2008;34:996–1000.
- Walkow T, Anders N, Klebe S. Endothelial cell loss after phacoemulsification: relation to preoperative and intraoperative parameters. *J Cataract Refract Surg.* 2000;26:727–732.
- Schultz RO, Glasser DB, Matsuda M, Yee RW, Edelhauser HF. Response of the corneal endothelium to cataract surgery. *Arch Ophthalmol.* 1986;104:1164–1169.
- Bourne WM, Brubaker RF, O'Fallon WM. Use of air to decrease endothelial cell loss during intraocular lens implantation. *Arch Ophthalmol.* 1979;97:1473–1475.
- Palko JR, Qi O, Sheybani A. Corneal alterations associated with pseudoexfoliation syndrome and glaucoma: a literature review. *J Ophthalmic Vis Res.* 2017;12:312–324.
- Sihota R, Lakshmaiah NC, Titiyal JS, Dada T, Agarwal HC. Corneal endothelial status in the subtypes of primary angle closure glaucoma. *Clin Exp Ophthalmol.* 2003;31:492–495.
- Yüksel N, Emre E, Pirhan D. Evaluation of corneal microstructure in pseudoexfoliation syndrome and glaucoma: In Vivo Scanning Laser Confocal Microscopic Study. *Curr Eye Res.* 2016; 41:34–40.
- Schultz RO, Matsuda M, Yee RW, Edelhauser HF, Schultz KJ. Corneal endothelial changes in type I and type II diabetes mellitus. *Am J Ophthalmol.* 1984;98:401–410.
- Bourne WM, Nelson LR, Hodge DO. Central corneal endothelial cell changes over a ten-year period. *Invest Ophthalmol Vis Sci.* 1997;38:779–782.

23. Yee RW, Matsuda M, Schultz RO, Edelhauser HF. Changes in the normal corneal endothelial cellular pattern as a function of age. *Curr Eye Res.* 1985;4:671–678.
24. Carlson KH, Bourne WM, McLaren JW, Brubaker RF. Variations in human corneal endothelial cell morphology and permeability to fluorescein with age. *Exp Eye Res.* 1988;47:27–41.
25. Huang J, Maram J, Tepelus TC, et al. Comparison of manual & automated analysis methods for corneal endothelial cell density measurements by specular microscopy. *J Optom.* 2018;11:182–191.
26. Huang J, Liu X, Tepelus TC, et al. Comparison of the center and flex-center methods of corneal endothelial cell analysis in the presence of guttae. *Cornea.* 2017;36:1514–1520.
27. de Sanctis U, Machetta F, Razzano L, Dalmasso P, Grignolo FM. Corneal endothelium evaluation with 2 noncontact specular microscopes and their semiautomated methods of analysis. *Cornea.* 2006;25:501–506.
28. Huang J, Maram J, Tepelus TC, Satta SR, Chopra V, Lee OL. Comparison of noncontact specular and confocal microscopy for evaluation of corneal endothelium. *Eye Contact Lens.* 2017; 44(suppl 1):S144–S150.
29. Doughty MJ. Evaluation of possible error sources in corneal endothelial morphometry with a semiautomated noncontact specular microscope. *Cornea.* 2013;32:1196–1203.