



## Macular hole closure at seven years after surgery

Keiichi Nishikawa<sup>a,b</sup>, Kenji Yamashiro<sup>a,b,\*</sup>

<sup>a</sup> Department of Ophthalmology, Otsu Red Cross Hospital, Otsu, Japan

<sup>b</sup> Department of Ophthalmology and Visual Sciences, Kyoto University Graduate School of Medicine, Kyoto, Japan

### ARTICLE INFO

#### Keywords:

Delayed closure  
Macular hole  
Internal limiting membrane  
Pars plana vitrectomy

### ABSTRACT

**Purpose:** To report a case of macular hole (MH) closure at seven years after internal limiting membrane (ILM) peeling.

**Observations:** A 66-year-old woman developed a MH in her left eye. Pars plana vitrectomy with ILM peeling and SF6 gas injection followed by face-down position for a week slightly improved the visual acuity from 20/400 to 20/200 but did not close the MH. During subsequent three years of follow-up without any treatment, the MH did not close. Seven years after the surgery, she visited us for cataract surgery in her right eye, and the optical coherence tomography (OCT) examination coincidentally found closure of the MH in her left eye. The visual acuity of her left eye remained 20/200 despite the MH closure.

**Conclusions and Importance:** ILM peeling might indirectly contribute to the closure of MH at seven years after the surgery although the mechanism is unclear. Sharing the serial OCT images until the MH closure would help us explore the mechanisms of ILM peeling to close MH and develop rational surgery technique manipulating ILM for MH.

### 1. Introduction

Pars plana vitrectomy (PPV) has been used to treat macular hole (MH) since 1982,<sup>1</sup> and internal limiting membrane (ILM) peeling technique was introduced in 1996.<sup>2</sup> ILM peeling improved the outcome of PPV for MH, and the first report of ILM peeling discussed that ILM removal might promote MH closure through the relief of tangential traction.<sup>2</sup> Although the precise mechanisms of ILM peeling to promote MH closure have not been elucidated, inverted ILM flap technique was introduced in 2010 and further modified surgical techniques manipulating ILM have been proposed by various study groups.<sup>3–10</sup> Recently, we experienced a case of delayed MH closure after ILM peeling. Sharing the serial optical coherence tomography (OCT) images until the MH closure would help us explore the mechanisms of ILM peeling to close MH.

### 2. Case report

A 66-year-old woman developed a flat-open MH after PPV for rhegmatogenous retinal detachment in her left eye. Since surgery for rhegmatogenous retinal detachment had been performed in other hospitals, details of the surgery were unclear. Three weeks after the surgery

for retinal detachment, she visited Otsu Red Cross Hospital for treatment of the MH. Her best-corrected visual acuity was 20/400 in the left eye, and the axial length of her left eye was 23.4 mm. An intraocular lens was fixed in her left lens capsule. Fundus examination revealed a MH in her left eye (Fig. 1). She underwent ILM peeling, fluid-gas exchange, and SF6 gas injection, and was asked to position face-down for a week. After the surgery, her visual acuity slightly improved to 20/200, but the MH did not close during three-years postoperative follow-up. Seven years after the ILM peeling surgery, she visited us for cataract surgery in her right eye, and the optical coherence tomography (OCT) examination coincidentally found closure of the MH in her left eye. The visual acuity of her left eye remained 20/200 despite the MH closure.

### 3. Discussion

Although MH can close spontaneously without any intervention, most cases with MH are treated with surgery. Given that most previous studies on surgical outcome for MH evaluated the success rate of MH closure during the first year after the surgery, MH closure should be rare after the first year. In the present case, the MH did not close for three years after the surgery, but the MH size gradually decreased in the second and the third year; the MH was suggested to be close during the

\* Corresponding author. Department of Ophthalmology, Otsu Red Cross Hospital, Otsu, Japan.

E-mail address: [yamashiro@kuhp.kyoto-u.ac.jp](mailto:yamashiro@kuhp.kyoto-u.ac.jp) (K. Yamashiro).

<https://doi.org/10.1016/j.ajoc.2021.101251>

Received 2 March 2021; Received in revised form 5 August 2021; Accepted 30 December 2021

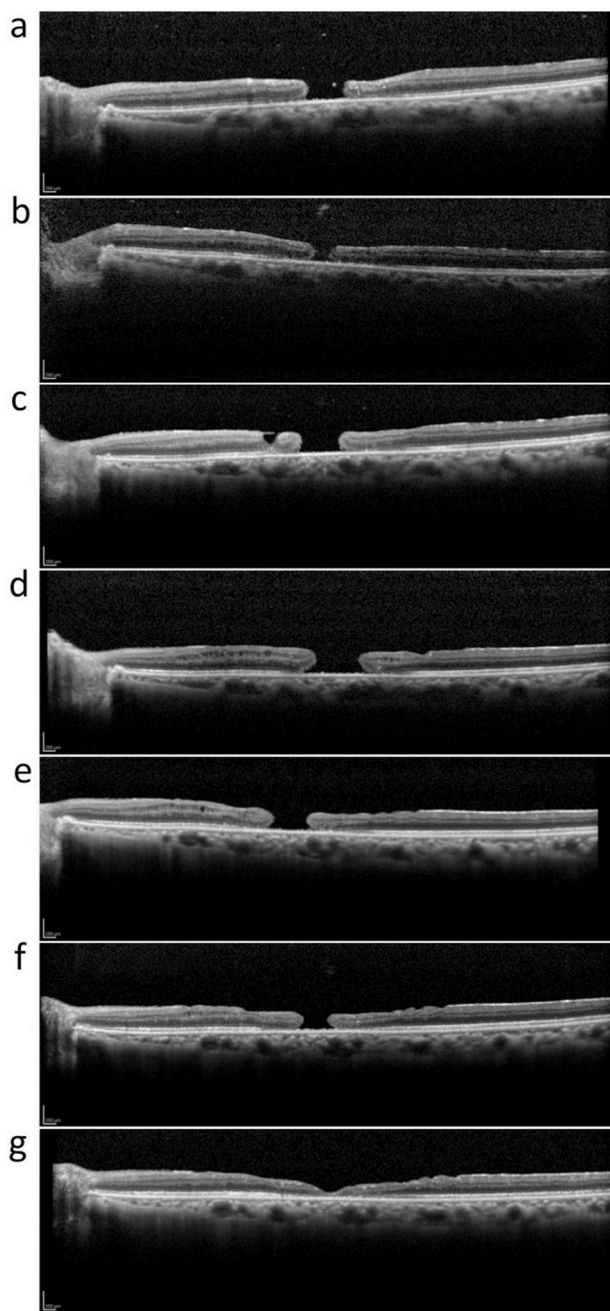
Available online 31 December 2021

2451-9936/© 2022 The Authors.

Published by Elsevier Inc.

This is an open access article under the CC BY-NC-ND license

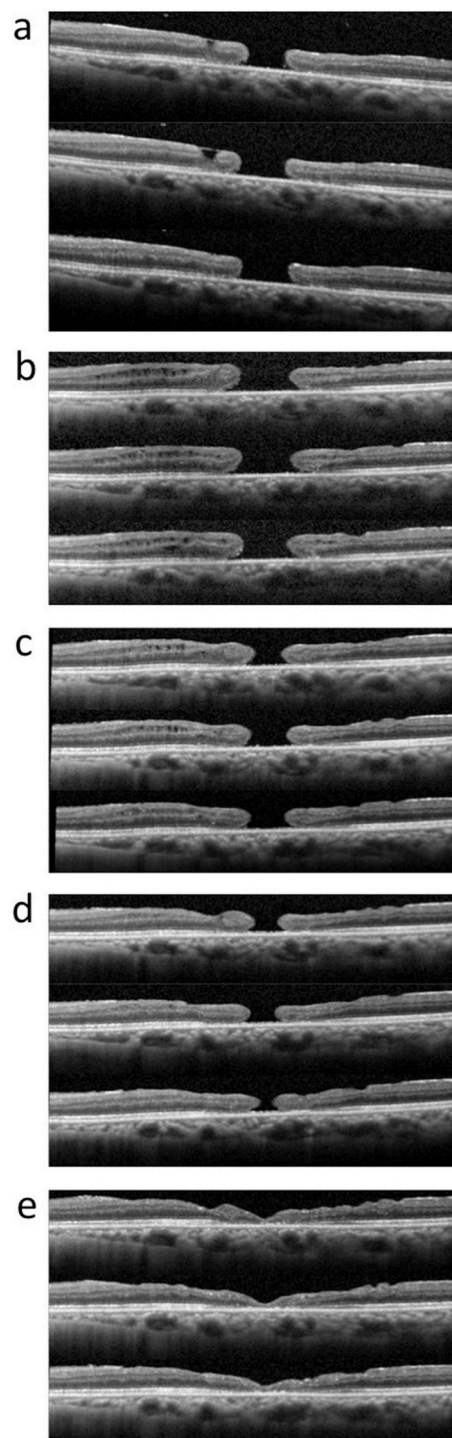
(<http://creativecommons.org/licenses/by-nc-nd/4.0/>).



**Fig. 1.** Vertical optical coherence tomography examination images across fovea before and after surgery for macular hole; before surgery (a), and one week (b), one month (c), nine months (d), two years (e), three years (f), and seven years (g) after internal limiting membrane removal.

4–6th year (Fig. 2). The subfoveal atrophic outer retina would account for the failure of visual acuity improvement after MH closure.

The present case underwent ILM peeling in 2012 when the inverted ILM flap technique had already been introduced for large MHs.<sup>3</sup> The ILM removal technique was chosen rather than the inverted ILM flap technique because the MH size was less than 400  $\mu\text{m}$ . Precise mechanisms of the ILM removal technique or the inverted ILM flap technique to promote MH closure have not been fully elucidated. ILM removal may relieve tangential traction,<sup>2</sup> while the inverted ILM flap may induce glial cell proliferation, resulting in MH filling with proliferating cells that enhance closure.<sup>3</sup> Although there is insufficient understanding of the roles of ILM removal or ILM flap in MH closure, further modified surgical techniques manipulating ILM have been proposed,<sup>5–10</sup> and



**Fig. 2.** Sequential optical coherence tomography examination images after surgery for macular hole; one month (a), nine months (b), two years (c), three years (d), and seven years (e) after internal limiting membrane removal.

different surgical techniques are used to treat MHs according to surgeons' discretion. The relief of tangential traction would not directly contribute to the MH closure after the delayed MH closer in the present case. ILM peeling might increase retinal tissue elasticity to decrease the size of MH gradually. Accumulation of various closure patterns of MH would lead to a precise understanding of the mechanisms by which ILM peeling promotes MH closure.

#### 4. Conclusions

The sequential OCT images of MH in this case suggest that the relief of tangential traction after ILM removal would not directly contribute to the delayed MH closure. We have to elucidate precise mechanisms of ILM peeling or ILM flap during MH closure through accumulation of various closure patterns of MH in order to develop rational and efficient surgical strategy for MH in the future.

#### Patient consent

Consent to publish the case report was not obtained. This report does not contain any personal information that could lead to the identification of the patient.

#### Funding/support

None.

#### Financial Disclosure(s)

The authors have made the following disclosures.

K.N.: None.

K.Y.: Lecture, Novartis Pharma, Tokyo, Japan; Alcon Pharma, Tokyo, Japan; Bayer Yakuhin, Osaka, Japan; Alcon Japan, Tokyo, Japan; Kowa Pharmaceutical Company, Nagoya, Japan; Santen Pharmaceutical Company, Osaka, Japan; Senju Pharmaceutical Company, Osaka, Japan; Canon, Tokyo, Japan.

All authors attest that they meet the current ICMJE criteria for Authorship.

#### References

1. Gonvers M, Macherer R. A new approach to treating retinal detachment with macular hole. *Am J Ophthalmol*. 1982;94(4):468–472.
2. Yooh HS, Brooks Jr HL, Capone Jr A, L'Hernault NL, Grossniklaus HE. Ultrastructural features of tissue removed during idiopathic macular hole surgery. *Am J Ophthalmol*. 1996;122(1):67–75.
3. Michalewska Z, Michalewski J, Adelman RA, Nawrocki J. Inverted internal limiting membrane flap technique for large macular holes. *Ophthalmology*. 2010;117(10):2018–2025.
4. Michalewska Z, Michalewski J, Dulczewska-Cichecka K, Adelman RA, Nawrocki J. Temporal inverted internal limiting membrane flap technique versus classic inverted internal limiting membrane flap technique: a comparative study. *Retina*. 2015;35(9):1844–1850.
5. Lai CC, Chen YP, Wang NK, et al. Vitrectomy with internal limiting membrane repositioning and autologous blood for macular hole retinal detachment in highly myopic eyes. *Ophthalmology*. 2015;122(9):1889–1898.
6. Chen SN, Yang CM. Inverted internal limiting membrane insertion for macular hole-associated retinal detachment in high myopia. *Am J Ophthalmol*. 2016;162:99–106. e101.
7. Takai Y, Tanito M, Sugihara K, Kodama T, Ohira A. Temporal inverted internal limiting membrane flap technique for a macular hole patient unable to maintain postoperative prone positioning. *Retin Cases Brief Rep*. 2016;10(4):323–326.
8. Chakrabarti M, Benjamin P, Chakrabarti K, Chakrabarti A. Closing macular holes with “macular plug” without gas tamponade and postoperative posturing. *Retina*. 2017;37(3):451–459.
9. Yamashiro K, Kinoshita-Nakano E, Ota T, Jingami Y, Nakata I, Hayashi H. Floating flap of internal limiting membrane in myopic macular hole surgery. *Graefes Arch Clin Exp Ophthalmol*. 2018;256(4):693–698.
10. Ho TC, Ho A, Chen MS. Vitrectomy with a modified temporal inverted limiting membrane flap to reconstruct the foveolar architecture for macular hole retinal detachment in highly myopic eyes. *Acta Ophthalmol*. 2018;96(1):e46–e53.