



## Case report

## Urrets-Zavalía syndrome with interface fluid syndrome following laser in situ keratomileusis

Alfonso Vasquez-Perez<sup>a</sup>, Francesco Aiello<sup>a,b,\*</sup>, Kirithika Muthusamy<sup>a</sup>, Stephen Tuft<sup>a</sup><sup>a</sup> Cornea and External Disease Department, Moorfields Eye Hospital NHS Foundation Trust, 162 City Road, EC1V 2PD, London, UK<sup>b</sup> Department of Experimental Medicine, University of Rome "Tor Vergata", Viale Oxford 81, 00133, Rome, Italy

## ARTICLE INFO

Presented at European Society of Cataract and Refractive Surgery (ESCRS) meeting, Lisbon, Portugal, October 2017.

## Keywords:

Interface fluid syndrome

LASIK

Urrets-Zavalía

LASIK complications

## ABSTRACT

**Purpose:** We describe the case of a 41-year-old male that underwent laser in situ keratomileusis (LASIK) complicated by Urrets-Zavalía syndrome with interface fluid syndrome and epithelial ingrowth.

**Observation:** The patient presented at our institution with headache and blurred vision three weeks after a right microkeratome-assisted LASIK procedure. On examination, the visual acuity was hand movements and the intraocular pressure (IOP) was 45 mmHg with fluid in the flap interface, a fixed pupil in moderate mydriasis, iris transillumination and cells in the anterior chamber. A Baerveldt tube implant was necessary to control the IOP. After three months, the corrected visual acuity was 20/40 with normal IOP and an early cataract.

**Conclusion and importance:** To our knowledge this is the first report of a case of combined Urrets-Zavalía syndrome and interface fluid syndrome after LASIK. We speculate that steroid induced ocular hypertension was the primary cause.

## 1. Introduction

Interface fluid syndrome (IFS) occurs in less than 0.2% of eyes after laser in situ keratomileusis (LASIK).<sup>1,2</sup> Interface fluid syndrome was first described by Lyle in 1999 as a collection of fluid at the flap interface.<sup>3</sup> It is commonly associated with an acute steroid-induced ocular hypertension response, hence the alternative name of pressure-induced stromal keratitis (PISK).<sup>4</sup> Urrets-Zavalía syndrome (UZS) is characterised by an anterior uveitis or fibrinous exudate, elevated intraocular pressure (IOP) and a dilated pupil in the early postoperative period. It has most frequently been reported following penetrating keratoplasty for keratoconus,<sup>5</sup> but can also occur after cataract surgery, trabeculectomy or lamellar keratoplasty.<sup>6,7</sup> Although IFS is a specific complication of laser-assisted in-situ keratomileusis (LASIK), to the best of our knowledge there are no reports of this complication developing in association with Urrets-Zavalía syndrome. Therefore, we report a case that developed Urrets-Zavalía syndrome in which IFS was further complicated by epithelial ingrowth. A persistently elevated IOP required tube drainage surgery for control.

## 2. Case report

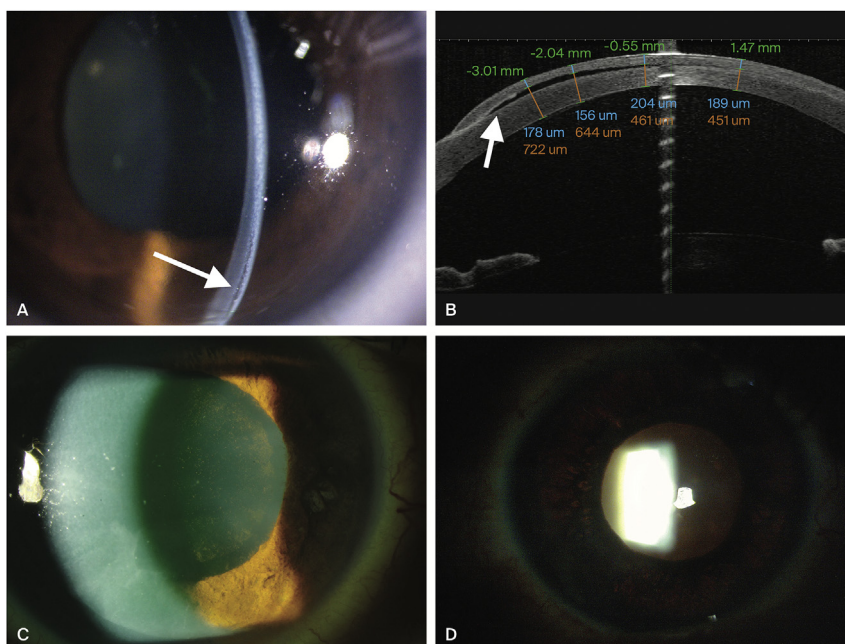
A 41 year-old male had an uneventful right LASIK for anisometropia

performed in another country with the flap formed using a microkeratome. The right pre-operative refraction was  $-3.50/-1.25 \times 5$  with a corrected visual acuity of 20/17. The preoperative examination reported a normal IOP in both eyes (13 mmHg in the right and 12 mmHg in the left eye) with normal funduscopy. There was no prior history of eye disease. Postoperatively, he was prescribed dexamethasone 1mg/ml and tobramycin 3mg/ml eye drops (Tobradex<sup>®</sup>, Alcon Laboratories Inc. Fort Worth, Texas, USA) two hourly for five days and then three times a day for one month after the procedure. He was reviewed five days after surgery with no signs of complications and he returned to the United Kingdom the following day. Twenty-one days after LASIK he developed pain in the eye, blurred vision and a headache that had increased over three days. On first examination, the visual acuity was hand movements. There was conjunctival hyperaemia and diffuse corneal oedema. There was a fluid interface beneath the flap (Fig. 1). The IOP (Icare<sup>®</sup> PRO) was 45 mmHg when measured superior to the LASIK flap. There was an intense anterior uveitis with flare and cells and fine pigmented keratic precipitates on the endothelium. There was also epithelial ingrowth in the nasal and inferior margin of the flap. The pupil was unreactive and mid-dilated (6.5 mm). Funduscopy was within normal limits. The left eye examination was normal. There were no guttae or evidence of corneal dystrophy; the IOP was within normal limit (13 mmHg) and there was no evidence of pigment dispersion syndrome.

\* Corresponding author. Moorfields Eye Hospital, 162 City Road, London, EC1V 2PD, UK.

E-mail address: [francesco.aiello@ptvonline.it](mailto:francesco.aiello@ptvonline.it) (F. Aiello).

<sup>1</sup> Present address: University of Rome "Tor Vergata", Viale Oxford 81, 00133, Rome, Italy.

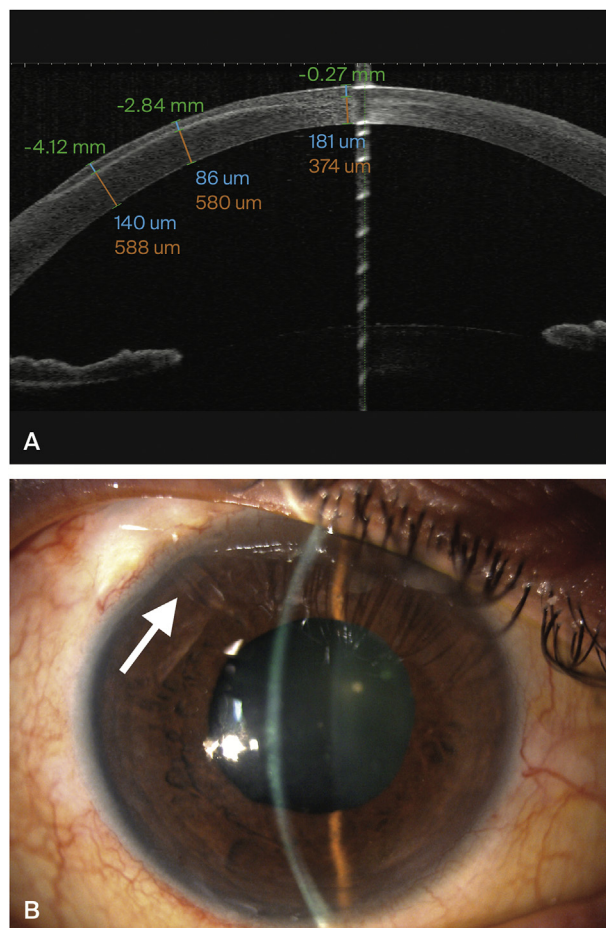


**Fig. 1.** Initial presentation three weeks after LASIK. A. Inferior fluid cleft separating the anterior flap from the posterior stroma (arrow). B. Anterior segment OCT scan showing interface fluid (arrow). C. Mid-dilated pupil with cells and pigment in the anterior chamber with iris transillumination (D).

The flap thickness measured with Optical Coherence Tomography (Tomey Casia OCT SS-1000) was 178 microns inferiorly. The initial management included oral acetazolamide (one initial dose of 500 mg and then 250 mg four times a day), topical timolol 5 mg/ml with dorzolamide 20 mg/ml (Cosopt® Merck Sharp & Dohme-Chibret, Clermont-Ferrand Cedex, France) twice a day, bimatoprost 0.3 mg/ml (Lumigan®, Allergan, Irvine, CA, USA) once a day and apraclonidine 1 mg/ml (Iopidine®, Alcon laboratories, inc. Fort Worth, Texas, USA) three times a day. On this regime, the IOP decreased to 24 mmHg and his headache reduced. Iris transillumination defects were then noted after the cornea clarity improved. The initial diagnosis was steroid-induced ocular hypertension and the dexamethasone was substituted with fluorometholone 1 mg/ml eye drops (FML® Allergan, Irvine, CA, USA) twice a day while the other medications were continued. However, although the IOP reduced, the anterior uveitis increased. He was therefore restarted on dexamethasone 0.1% two hourly. After one week, the interface fluid had resolved and the epithelial ingrowth was removed after lifting the flap and applying 20% alcohol. However, when the steroid was again tapered his IOP increased to 55 mmHg with evidence of optic disc excavation, and a Baerveldt drainage tube was implanted. Postoperatively his IOP decreased to normal and he continued with topical timolol 5 mg/ml with dorzolamide 20 mg/ml twice a day. A recurrence of the epithelial ingrowth was again removed as before without significant further subsequent recurrence. Four weeks after glaucoma surgery his ocular inflammation had resolved and topical steroids was discontinued. At four months, the IOP was normal, the pupil was mid-dilated and unreactive to light. The OCT this time revealed an irregular flap thickness that was measured 86 microns at the thinnest point inferiorly. The refraction was +2.75/-2.50 × 85 but his corrected visual acuity only improved to 20/40 due to a residual interface haze and early cataract (Fig. 2).

**3. Discussion**

It has been reported that a clinically significant rise in IOP (6–15 mmHg) occurs in 29% of individuals when they use topical steroid.<sup>8</sup> It is also thought that most cases of IFS are the result of an acute rise in intraocular pressure secondary to the use of topical steroid,<sup>1,4</sup> and thus an alternative name is pressure-induced stromal



**Fig. 2.** Final outcome at three months. A. Baerveldt tube opening into the anterior chamber. B. Anterior segment OCT scan showing a residual haze in the interface. Corneal flap thickness measurements at different levels with resolution of flap's oedema.

keratitis (PISK).<sup>4,7</sup> However, as there is no evidence of an inflammatory cell infiltrate, which is a feature of diffuse lamellar keratitis (DLK),<sup>9</sup> pressure-induced keratopathy may be a more accurate name.<sup>10</sup> Although IFS/PISK is an uncommon complication of LASIK, with a reported incidence of < 0.2%,<sup>1</sup> we believe that a steroid induced elevation in IOP was the most likely trigger for the subsequent complications in this case.

The depth of the fluid interface in IFS may be relatively small<sup>1,4</sup> and OCT can be useful to confirm its presence. The pressure within the fluid interface is thought to be low and this can lead to a misleadingly low IOP measurement when using Goldmann applanation tonometry.<sup>1,11</sup> Contact pneumotometry and rebound tonometry are less affected<sup>1</sup> and we also obtained measurements from the superior cornea where there was no fluid. The clinical signs of IFS are distinct from DLK or central toxic keratopathy (CTK) following LASIK,<sup>1,9,12,13</sup> but the differential diagnosis should include DLK, CTK or microbial infection. In addition, the onset of signs with DLK are usually within the first days following surgery.<sup>1,2</sup> Iris ischaemia is the likely mechanism of the pupil paresis and iris atrophy of Urrets-Zavalía syndrome.<sup>6,7</sup> Most patients with Urrets-Zavalía syndrome have an elevated IOP in the acute phase and this pressure may occlude the trans-scleral blood supply to the iris leading to a secondary uveitis.<sup>14</sup> Avadhani et al.<sup>15</sup> previously reported a case of Urrets-Zavalía syndrome after unilateral LASIK although they did not document an elevated IOP or subsequent iris atrophy.

Therefore, we speculate that in the present case an elevation in IOP secondary to topical steroid lead both to the pupil paresis as well as IFS. In our case the patient was prescribed combined topical dexamethasone 1mg/ml and tobramycin 3 mg/ml eye drops 2 hourly for 5 days and then tapered to 3 times a day for a month. We believe that post-operative steroid and antibiotic is not required after one week following LASIK treatment, not least because of the risk of steroid associated glaucoma.

An anterior uveitis can occur in isolation following LASIK, with an incidence of 0.18% reported in one retrospective case series.<sup>16</sup> The mechanism may be the result of a sudden change in IOP associated with the use of the suction ring and a mechanical microkeratome, which can cause a transient pressure increase up to 90 mmHg.<sup>16</sup> This may release pro-inflammatory cytokines as occurs after a closed eye injury.<sup>17</sup> There was no record of multiple attempts of microtome suction or the application of suction for a prolonged period. The patient said that the procedure was short and painless, and he was unaware of any intra-operative problems. Also, the patient did not receive a systemic fluorquinolone in the perioperative treatment, which has been reported as a potential cause for anterior uveitis with iris transillumination.<sup>18</sup>

Epithelial ingrowth after femtosecond laser assisted LASIK flap creation has been reported to be as low as 0.03% for first LASIK procedure<sup>19</sup> compared to between 0.4<sup>20</sup> and 9.1%<sup>21</sup> when a microkeratome is used. This complication is more frequent following hyperopic corrections and enhancements.<sup>22</sup> It is thought to result either from epithelial cells swept under the flap edge at the time of surgery, or ingrowth due to flap edge misalignment.<sup>21</sup> Elevated IOP is not a clinical feature of epithelial ingrowth. In our case there was the added risk of a fluid space and the subsequent flap edge gap formation may have facilitated the growth of the epithelial layer under the flap. To the best of our knowledge this is the first report of combined IFS and Urrets-Zavalía syndrome following LASIK. It potentially highlights the multiple downstream consequences (iris ischaemia, interface fluid, epithelial ingrowth) that can ensue from steroid induced ocular hypertension following LASIK, and the role of the flap in modifying the clinical picture of corneal disease.

#### Patient consent

Written consent to publish case details has been obtained from patient.

#### Funding

No funding or grant support

#### Conflicts of interest

The following authors have no financial disclosures: AVP, FA, KM, ST.

#### Authorship

All authors attest that they meet the current ICMJE criteria for Authorship.

#### Acknowledgements

None.

#### Appendix A. Supplementary data

Supplementary data to this article can be found online at <https://doi.org/10.1016/j.ajoc.2018.12.015>.

#### References

- Randleman JB, Shah RD. LASIK interface complications: etiology, management, and outcomes. *J Refract Surg (Thorofare, NJ)*. 2012;28(8):575–586.
- Stulting RD, Randleman JB, Couser JM, Thompson KP. The epidemiology of diffuse lamellar keratitis. *Cornea*. 2004;23(7):680–688.
- Lyle WA, Jin GJ. Interface fluid associated with diffuse lamellar keratitis and epithelial ingrowth after laser in situ keratomileusis. *J Cataract Refract Surg*. 1999;25(7):1009–1012.
- Belin MW, Hannush SB, Yau CW, Schultze RL. Elevated intraocular pressure-induced interlamellar stromal keratitis. *Ophthalmology*. 2002;109(10):1929–1933.
- Spierer O, Lazar M. Urrets-Zavalía syndrome (fixed and dilated pupil following penetrating keratoplasty for keratoconus) and its variants. *Surv Ophthalmol*. 2014;59(3):304–310.
- Jain R, Assi A, Murdoch IE. Urrets-Zavalía syndrome following trabeculectomy. *Br J Ophthalmol*. 2000;84(3):338–339.
- Bozkurt KT, Acar BT, Acar S. Fixed dilated pupilla as a common complication of deep anterior lamellar keratoplasty complicated with Descemet membrane perforation. *Eur J Ophthalmol*. 2013;23(2):164–170.
- Maurino V, Aiello F. Glaucoma risks in advanced corneal surgery. *Prog Brain Res*. 2015;221:271–295.
- Tourtas T, Kopsachilis N, Meiller R, Kruse FE, Cursiefen C. Pressure-induced interlamellar stromal keratitis after laser in situ keratomileusis. *Cornea*. 2011;30(8):920–923.
- Tourtas T, Cursiefen C. “PISK-itis” or “PISK-opathy”? *Cornea*. 2012;31(2):107.
- Fogla R, Rao SK, Padmanabhan P. Interface fluid after laser in situ keratomileusis. *J Cataract Refract Surg*. 2001;27(9):1526–1528.
- Kurian M, Shetty R, Shetty BK, Devi SA. In vivo confocal microscopic findings of interlamellar stromal keratopathy induced by elevated intraocular pressure. *J Cataract Refract Surg*. 2006;32(9):1563–1566.
- Jutley G, Aiello F, Robaei D, Maurino V. Central toxic keratopathy after laser in situ keratomileusis. *J Cataract Refract Surg*. 2014;40(12):1985–1993.
- Tuft SJ, Buckley RJ. Iris ischaemia following penetrating keratoplasty for keratoconus (Urrets-Zavalía syndrome). *Cornea*. 1995;14(6):618–622.
- Avadhani K, Prakash G, Srivastava D, Shakunthala A. Urrets-Zavalía syndrome after laser-assisted in situ keratomileusis (LASIK). *BMJ Case Rep*. 2015 July 8.
- Suarez E, Torres F, Vieira JC, Ramirez E, Arevalo JF. Anterior uveitis after laser in situ keratomileusis. *J Cataract Refract Surg*. 2002;28(10):1793–1798.
- Hernandez-Verdejo JL, Teus MA, Roman JM, Bolivar G. Porcine model to compare real-time intraocular pressure during LASIK with a mechanical microkeratome and femtosecond laser. *Invest Ophthalmol Vis Sci*. 2007;48(1):68–72.
- Wefers Bettink-Remeijer M, Brouwers K, van Langenhove L, et al. Uveitis-like syndrome and iris transillumination after the use of oral moxifloxacin. *Eye (London, England)*. 2009;23(12):2260–2262.
- Kamburoglu G, Ertan A. Epithelial ingrowth after femtosecond laser-assisted in situ keratomileusis. *Cornea*. 2008;27(10):1122–1125.
- Walker MB, Wilson SE. Incidence and prevention of epithelial growth within the interface after laser in situ keratomileusis. *Cornea*. 2000;19(2):170–173.
- Stulting RD, Carr JD, Thompson KP, Waring 3rd GO, Wiley WM, Walker JG. Complications of laser in situ keratomileusis for the correction of myopia. *Ophthalmology*. 1999;106(1):13–20.
- Wang MY, Maloney RK. Epithelial ingrowth after laser in situ keratomileusis. *Am J Ophthalmol*. 2000;129(6):746–751.