



Presumed cytomegalovirus retinitis in a non-immune compromised patient with breast carcinoma during treatment: A case report

Chia-Chen Kao^{a,b}, Shih-Liang Hsu^{a,b}, Shwu-Jiuan Sheu^{a,b,*}

^a Department of Ophthalmology, Kaohsiung Medical University Hospital, Taiwan

^b Kaohsiung Medical University, Kaohsiung, Taiwan

ARTICLE INFO

Keywords:
Cytomegalovirus retinitis
Valganciclovir
Panuveitis

ABSTRACT

Purpose: Cytomegalovirus (CMV) retinitis is one of the most common opportunistic infections in immunocompromised patients, including patients with acquired immunodeficiency syndrome (AIDS). CMV retinitis in non-human immunodeficiency virus (HIV)-infected patients has been reported with variable presentations. Significant intraocular inflammation is common, and visual prognosis is poor if not properly managed.

Observations: We present a case of presumed CMV retinitis in a non-immunocompromised breast cancer patient that occurred during cancer treatment. The ocular symptoms developed one day after partial mastectomy with intra-operative radiotherapy following five months of chemotherapy treatment. Ocular manifestations included panuveitis with mild peripheral retinitis.

Conclusions and Importance: Early diagnosis and prompt treatment with oral valganciclovir based on the clinical manifestation and serologic test findings helped to preserve vision.

1. Introduction

CMV retinitis is one of the most common opportunistic infection in immune compromised patients, like acquired immunodeficiency syndrome (AIDS). Although HAART has decreased the incidence of CMV retinitis, CMV retinitis remains the most common HIV-related ocular manifestation and lead to visual impairment.¹ The ocular manifestation is usually typical, but may be variable in non-HIV-infected patients. Significant intraocular inflammation was not uncommon, and the visual prognosis is poor if not properly managed.² We present a case of presumed CMV retinitis in a non-immune compromised woman with breast cancer during treatment. She presented with panuveitis with mild peripheral retinitis. Even though aqueous CMV polymerase chain reaction (PCR) was not done to confirm the diagnosis, we treated her successfully based on clinical manifestations and course after treatment with ganciclovir.

2. Case report

A 65-year-old female presented to our clinic with chief complaint of increased floaters in her right eye for five days. She had history of stage

2A left breast cancer, status post five months of chemotherapy, and had undergone left partial mastectomy with intra-operative radiotherapy one day prior to the onset of symptom. Her visual acuity (VA) was 1.0 in both eyes. Ocular examination of her right eye showed superficial punctate keratitis (SPK), trace aqueous cells in the anterior chamber, mild nuclear opacity, vitreous haze grade of 0.5, and a small creamy patch at the 3-o'clock position of the peripheral retina (Fig. 1A). Examination of her left eye was unremarkable except for mild SPK and lens opacity (Fig. 1B). Optical coherence tomography revealed slightly thickened choroid and some vitreous cells in the right eye (Fig. 2). Serological tests for possible infectious origins, including herpes simplex virus (HSV), and varicella zoster virus (VZV), were not specific except for high CMV IgG reactivity (>250.0 AU/mL). CMV, HSV, and VZV IgM titers were non-reactive. CD4 count was slightly below normal range at 440 cells/ μ L.

Five days after the initial visit, right eye VA dropped to 0.4 with increased vitreous opacity. CMV retinitis was presumed, and oral valganciclovir 900 mg twice daily was prescribed. Over the following two weeks, right eye VA improved to 0.8, although floaters persisted. Presence of inflammatory cells resolved gradually with more consolidation of the creamy patch in the peripheral retina (Fig. 3A). Valganciclovir

* Corresponding author. Department of Ophthalmology, Kaohsiung Medical University Hospital No.100, Tzyou 1st Rd., Sanmin Dist., Kaohsiung City, 80756, Taiwan.

E-mail address: 1080173@kmu.org.tw (S.-J. Sheu).

<https://doi.org/10.1016/j.ajoc.2021.101161>

Received 27 November 2020; Received in revised form 24 April 2021; Accepted 5 July 2021

Available online 7 July 2021

2451-9936/© 2021 Published by Elsevier Inc. This is an open access article under the CC BY-NC-ND license (<http://creativecommons.org/licenses/by-nc-nd/4.0/>).

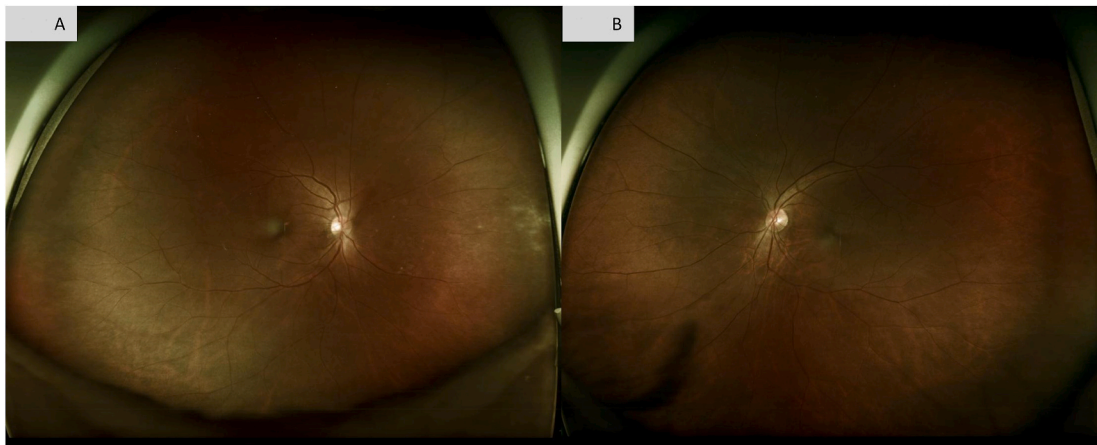


Fig. 1. A: Initial fundus presentation of the right eye showed mild vitreous opacity and a small creamy patch at the 3-o'clock position of the peripheral retina. B: Initial fundus presentation of the left eye was unremarkable.

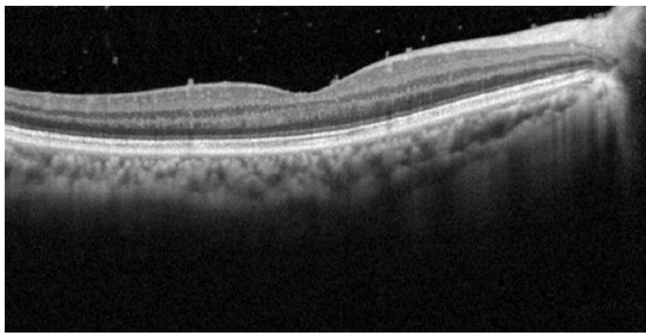


Fig. 2. Baseline optical coherence tomography scan of the right eye revealed slightly thickened choroid and vitreous cells.

was discontinued after three months of treatment. The patient's VA recovered to 1.0 with only residual mottling scars at the retina periphery. She felt no more blurred vision, and she was satisfied with the treatment course. No recurrence was observed up to the six-month follow-up visit (Fig. 3B).

3. Discussion

We present a case of presumed CMV retinitis in a non-immunocompromised patient with breast cancer that occurred during

cancer treatment. Ocular symptoms developed one day after the patient underwent partial mastectomy with intra-operative radiotherapy following five months of chemotherapy. Early diagnosis and prompt treatment based on clinical manifestation and serologic test results helped to preserve the patient's vision.

CMV retinitis is one of the most common opportunistic infection in immunocompromised patients, such as those with AIDS. Although the incidence of CMV retinitis has declined with the usage of highly reactive antiretroviral therapy, CMV retinitis remains the most common HIV-related ocular manifestation. Characteristics of typical clinical presentation include wedge-shaped areas of whitening with occasional hemorrhage, small dot-like lesions, and retinal vasculitis. With disease progression, full-thickness necrotizing lesions progress from the periphery centrifugally toward the posterior pole, and retinal necrosis involving the macula or optic nerve usually leads to significant visual impairment.³ The diagnosis of CMV retinitis is mainly based on clinical manifestation and serological tests, though aqueous CMV polymerase chain reaction was reported to have good sensitivity and specificity for diagnosing ocular CMV infections.⁴ Furthermore, CMV retinitis is known to occur in relatively late-stage HIV disease, which is typically associated with a CD4 count of <50 cells/ μL . However, our previously reported case series of HIV/AIDS patients showed that 82% patients with CMV retinitis had a CD4 count of <200 cells/ μL but only 36% patients had a CD4 count of <50 cells/ μL .⁵ The clinical presentation in this case is not typical for CMV retinitis, as the patient's CD4 count was 440 cells/ μL , which is slightly lower than normal but not as low as that

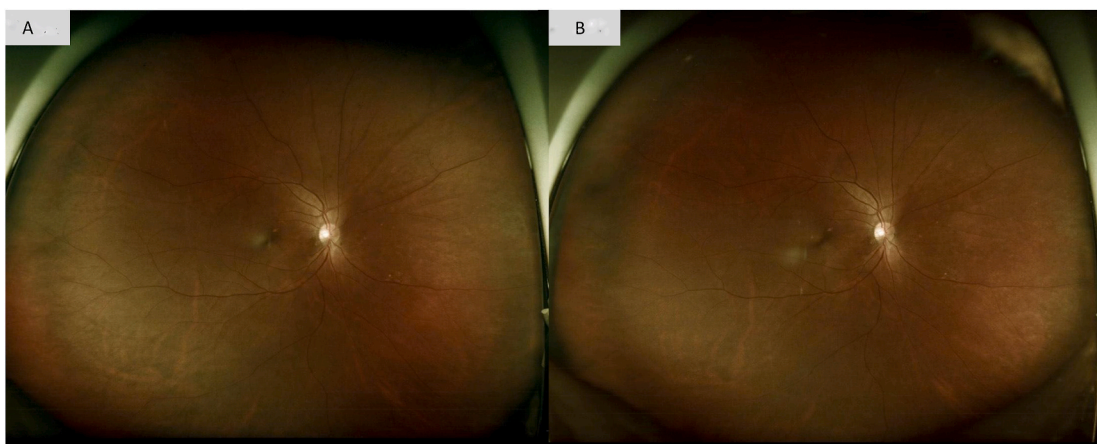


Fig. 3. A: Fundus picture of the right eye after one month of valganciclovir treatment revealed more consolidation of the creamy patch in the peripheral retina. B: Fundus picture of the right eye after three months of valganciclovir treatment showed residual mottling scars at the retina periphery.

observed in the AIDS cases. Aqueous tapping was not done considering the patient was still receiving chemotherapy. As her vision decreased markedly over one week after onset, we initiated treatment with oral valganciclovir, which has been shown to be as effective as intravenous ganciclovir when used as initial treatment for CMV retinitis.⁶ Fortunately, inflammation resolved and vision recovered without sequelae.

Although the presentation of CMV retinitis in non-HIV-infected patients has been reported to be variable, significant intraocular inflammation was a common feature and long-term visual outcome was poor, particularly in eyes with macular involvement.² Patches of hemorrhagic retinitis with perivascular sheathing with macula involvement was reported in an otherwise healthy 61 years-old woman who was then diagnosed with CMV retinitis by CMV PCR. Retinitis subsided from fovea after initiation of intravitreal injection of ganciclovir and oral valganciclovir, and her visual acuity improved from 4/20 to 8/20.⁷ Currently, no specific guidelines have been developed for the management of non-AIDS-related CMV retinitis. Typically, CMV retinitis manifests during the first year of immunocompromised status, and retinal lesions stop progressing within one to two weeks following treatment. Although our case received five months of chemotherapy followed by partial mastectomy with intra-operative radiotherapy on the day prior to the onset of symptoms, she did not meet criteria to be considered as immunocompromised. Presumed CMV retinitis was diagnosed based on the clinical presentation, high CMV IgG reactivity, and favorable response to oral valganciclovir. The final outcome supported our decision to start treatment early in order to prevent disease progression to the macula.

4. Conclusions

In conclusion, CMV retinitis in non-HIV-infected patients may be variable, especially in patients who are not immunocompromised. This case demonstrates the importance of early detection and diagnosis of presumed CMV retinitis as well as timely treatment in order to preserve vision.

Declaration of competing interest

No conflict of interest exists for any author.

Acknowledgements

None.

List of abbreviations

AIDS	Acquired immunodeficiency syndrome
HIV	Human immunodeficiency virus
CMV	Cytomegalovirus
VA	Visual acuity
SPK	Superficial punctate keratitis
HSV	Herpes simplex virus

VZV Varicella zoster virus

Patient consent

The patient's consented to publication of the case in writing.

Funding

No funding or grant support

Authorship

All authors attest that they meet the current ICMJE criteria for Authorship.

Intellectual property

We confirm that we have given due consideration to the protection of intellectual property associated with this work and that there are no impediments to publication, including the timing of publication, with respect to intellectual property. In so doing we confirm that we have followed the regulations of our institutions concerning intellectual property.

Research ethics

We further confirm that any aspect of the work covered in this manuscript that has involved human patients has been conducted with the ethical approval of all relevant bodies and that such approvals are acknowledged within the manuscript.

Written consent to publish potentially identifying information, such as details or the case and photographs, was obtained from the patient(s) or their legal guardian(s).

References

- Ledergerber B, Egger M, Erard V, Weber R, Hirschel B, et al. AIDS-related opportunistic illnesses occurring after initiation of potent antiretroviral therapy: the Swiss HIV Cohort Study. *J Am Med Assoc.* 1999;282:2220–2226.
- Iu Lawrence P, Fan Michelle C, Lau Jordy K, et al. Long-term follow-up of cytomegalovirus retinitis in non-HIV immunocompromised patients: clinical features and visual prognosis. *Am J Ophthalmol.* 2016;165:145–153.
- Port Alexander D, Anton Orlin, Kiss Szilard, et al. Cytomegalovirus retinitis: a review. *J Ocul Pharmacol Therapeut.* 2017;33:224–234.
- Dai Miyazaki, Shimizu Daisuke, Shimizu Yumiko, et al. Diagnostic efficacy of real-time PCR for ocular cytomegalovirus infections. *Graefes Arch Clin Exp Ophthalmol.* 2018;256:2413–2420.
- Tsen Chui-Lien, Chen Yao-Shen, Wu Kuan-Sheng, et al. Ocular manifestations of human immunodeficiency virus infection at a tertiary referral center in Taiwan. *Ocul Immunol Inflamm.* 2019;27:1071–1076.
- Martin Daniel F, Sierra-Madero Juan, Walmsley Sharon, et al. A controlled trial of valganciclovir as induction therapy for cytomegalovirus retinitis. *N Engl J Med.* 2002; 346:1119–1126.
- Karkhaneh Reza, Lashay Alireza, Ahmadraji Aliasghar. Cytomegalovirus retinitis in an immunocompetent patient: a case report. *Journal of Current Ophthalmology.* 2016: 93–95.