

## Case Report

# Primary Small Cell Carcinoma of the Esophagus: Clinico- pathological Features and Therapeutic Options

ANDREA NEVÁREZ<sup>(1)</sup>, A. SAFTOIU<sup>(2)</sup>, M.S. BHUTANI<sup>(3)</sup>

<sup>(1)</sup>Gastroenterology Unit, La Fe Hospital, Valencia, Spain; <sup>(2)</sup>Research Center of Gastroenterology and Hepatology Craiova, University of Medicine and Pharmacy Craiova, România; <sup>(3)</sup> Department of Gastroenterology, Hepatology and Nutrition, UT MD Anderson Cancer Center, Houston, Texas, USA

**ABSTRACT** Primary esophageal small cell carcinoma (SmCC) is a rare disease with a poor prognosis despite aggressive multimodality combination treatment. This article presents the case of a 76-year old women diagnosed with primary esophageal SmCC. The diagnosis was established by upper gastrointestinal endoscopy with biopsies that confirmed an esophageal SmCC positive to synaptophysin, chromogranin, CD56, TTF-1, and cytokeratin 8/18. Further staging procedures included CT, PET and EUS, followed by combination chemotherapy and radiotherapy. Restaging was then performed, again with PET and CT of the thorax, abdomen and pelvis. This was then followed by salvage esophagectomy due to the presence of residual tumor. Surgical pathology confirmed a 3 cm SmCC, with invasion of the submucosa and lymphovascular invasion. In conclusion, the article describes the rare occurrence of esophageal SmCC, together with the algorithm of diagnosis and staging based on state-of-the-art imaging methods. This was followed by combination chemoradiotherapy and surgical esophagectomy as the standard of care in this aggressive disease.

**KEY WORDS** esophageal small cell carcinoma (SmCC), positron emission tomography (PET), computer tomography (CT), endoscopic ultrasound (EUS)

## Introduction

Esophageal small cell carcinoma (SmCC) is a very uncommon disease. It accounts for up to 0.4 to 2.8% of all esophageal carcinomas<sup>1</sup>. The disease has been managed with various forms of treatment that include surgical resection, radiotherapy, chemotherapy and combinations of them; nonetheless, even with the use of aggressive treatment the prognosis of the tumor is still poor. We present a case of a 76-year-old woman with diagnosis of primary esophageal SmCC.

## Case report

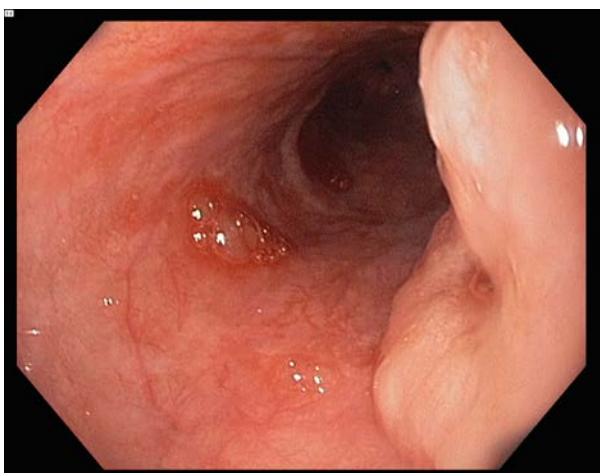
A 76-year-old woman with a three month history of sore throat and odynophagia associated with gastroesophageal reflux disease underwent an upper gastrointestinal endoscopy revealing a circumferential fungating mass, occupying 50% of the lumen, in the mid esophagus. She has no personal history of smoking or drinking alcohol. Tumor markers were within normal limits, with CEA levels of 1.9 NG/ML. The biopsy specimens showed SmCC positive to synaptophysin, chromogranin, CD56, TTF-1, and cytokeratin 8/18.

A positron emission tomography (PET) scan revealed hypermetabolic activity in the primary tumor, 4 cm beneath the carina, measuring 3 x 2 x 1 cm, with standardized uptake value (SUV) up to 3.8. No flourodeoxyglucose (FDG) avid lymphadenopathy was noted. A thoracic and

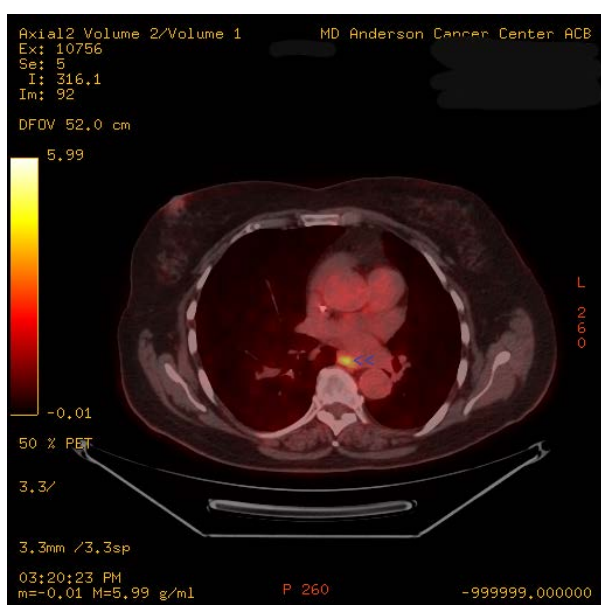
abdominal computer tomography (CT) scan showed no presence of lymph nodes or mediastinal lesions suspicious of metastasis. Endoscopic ultrasound (EUS) showed no lymphadenopathy but penetration through the muscularis propria into the adventitia with tumor stage as uT3N0. Chemotherapy was begun combined with radiotherapy as definitive therapy. She completed a total of 5 cycles of chemotherapy consistent of cisplatin, etoposide and carboplatin. She also received 50 Gy radiation therapy. After this treatment she underwent restaging testing. Repeat EGD revealed persistence of the esophageal mass at 29 to 32 cm, occupying 40% of the circumference (Figure 1). Biopsy specimens continued to show small cell carcinoma. Repeat PET scan showed a focal circumferential thickening of the wall of the esophagus in the middle third that had a low grade increased 18-FDG uptake suspicious of residual malignancy (SUV values of 4.6) (Figure 2). There were no FDG avid lymphnodes in the neck, thorax, abdomen or pelvis. Her CT scan of thorax, abdomen and pelvis showed no evidence of distant metastatic disease. She was treated with salvage esophagectomy due to presence of the residual tumor. Surgical pathology revealed 3 cm small cell carcinoma with 95% viable tumor invading the submucosa without involvement of the

muscularis propria. Lymphovascular invasion was identified.

img



**Figure 1: Endoscopic image of a mass in the esophagus with central depression biopsies of which showed small cell cancer of the esophagus despite treatment with chemotherapy and radiation.**



**Figure 2: Fused CT-PET image showing an FDG avid lesion in the esophagus (blue arrowheads) corresponding with small cell cancer of the esophagus seen in figure 1.**

## Discussion

SmCC occurs as a primary tumor mainly in the lung and accounts for 16% of lung cancers<sup>2</sup>. Extrapulmonary SmCC are rare, but many sites have been described including salivary glands, larynx, pharynx, prostate, bladder, endometrium, and gastro intestinal tract<sup>3-5</sup>. Primary esophageal SmCC was first described in 1952 by McKeown<sup>6</sup> and it is the most common location in the gastrointestinal tract. Esophageal SmCC is a very

uncommon disease. It accounts for up to 0.4 to 2.8% of all esophageal carcinomas<sup>1</sup>. Its clinical presentation is similar to other esophageal tumors. The most common symptoms are dysphagia, anorexia, weight loss, reflux and chest pain<sup>1, 7-10</sup>. There have been some reports of paraneoplastic syndrome with ectopic secretion of hormones, but this is a rare finding<sup>1</sup>. The lesion is more frequently located in the mid – lower esophagus<sup>3, 7, 9, 10, 12</sup>. Upper esophageal localization has been seen in approximately 5% of cases<sup>12</sup>. No predisposing risk factor has been identified with SmCC, but some associations with smoking, alcohol consumption and Barrett's disease have been made<sup>9, 12-14</sup>. The mean age of diagnosis is between 40 to 70 years, with male predominance. When the disease is suspected confirmation by histological diagnosis has to be done with adequate staging. The prognosis of the tumor is poor, with median survival ranging from 7- 19 months<sup>3, 8-10, 15</sup>. Most of the tumors have lymph node involvement and a high percentage of cases are diagnosed with distant metastasis (31-90%<sup>1</sup>); the most common site of metastasis is the liver, followed by peritoneum and bones<sup>1, 13</sup>.

Diagnosis is established by histological criteria for pulmonary small cell carcinoma proposed by the World Health Organization. It consists of small, round, ovoid or spindle-shaped cells with scanty cytoplasm, finely granular nuclear chromatin, and absence or not easily seen nucleoli<sup>1, 3, 5</sup>. There can also be components of squamous cell carcinoma or adenocarcinoma in some tumors<sup>7, 10, 12, 16</sup>. Most common immunohistochemical neuroendocrine markers are neuron-specific enolase, chromogranin, synaptophysin and CD56<sup>1, 3, 11, 17</sup>. Another marker that has been studied in lung tumors is thyroid transcription factor-1 (TTF-1), is almost always negative in gastrointestinal SmCC<sup>1</sup>. However in a study published by Yun PJ et al<sup>3</sup>; 71.4% TTF-1 positive tumors were reported, suggesting that it was a suitable marker for diagnosis and differentiation of esophageal SmCC. Esophageal SmCC is thought to originate from multipotential stem cells as initially proposed by Ho et al in 1984<sup>18</sup>. These cells may differentiate into squamous, glandular or neuroendocrine cells, which may explain the coexistence of mixed tumors in up to 40-50% of cases of SmCC<sup>1</sup>.

Treatment protocols have not been established nor have been studied by prospective randomized trials, due to the low incidence rate of this disease. The reported cases of SmCC have been managed with various forms of treatment that include surgical resection, radiotherapy, chemotherapy

and combinations of them. However prognosis is still poor even with the use of aggressive treatment because of the frequent presence of metastasis at time of diagnosis.

For limited disease (LD); defined as disease confined to the esophagus and adjacent organs with or without regional lymph node involvement<sup>1, 8, 9, 15</sup>, the most effective treatment has not been established. Many reports have combined surgery with chemotherapy and/or radiotherapy, with different survival rates. In general the median survival rates in these patients with LD is between 8 to 24 months<sup>8, 9, 12, 15</sup>. In a review published by Casas et al<sup>12</sup>, a significant survival difference was seen between limited and disseminated disease, as did also the size of tumor less than 5 cm and the use of combination therapy. This has also been reported by Lv et al<sup>15</sup> in clinical experience of 126 patients. It was seen that the stage of the disease and treatment with chemotherapy were independent prognostic factors for survival. They recommended the use of chemotherapy for the treatment of LD. Hudson et al<sup>8</sup> reported that chemotherapy combined with radiation may provide an effective treatment for local control, avoiding the morbidity of extensive surgery. It also recommended that surgery can be done in clinically selected patients where it may be reserved as salvage after documented local failure following chemoradiation, as done in our case. Ku et al<sup>9</sup> has also reported that long term survival can be achieved without surgery when chemotherapy followed by chemotherapy with radiotherapy is used. Nemoto et al<sup>19</sup> reviewed 12 patients with LD that underwent surgery, and later were treated with radiation (some of them also treated with chemotherapy). They couldn't determine the optimal local treatment due to the small number of patients, but their long-term survivors were treated with radiation and chemotherapy after surgery. With these findings they got to the conclusion that good local control rates can be obtained by definite or postoperative radiation therapy, with concurrent chemotherapy. Other studies also have shown that longest survivors have been seen in patients treated with esophagectomy combined with chemotherapy or radiotherapy<sup>1, 9</sup>. Nevertheless there have been reports where the response to chemotherapy is only 50%<sup>1</sup>. This could be explained by the number of tumors with mixed histology, and this can be handled by individualization of chemotherapy treatment.

Extensive disease (ED) is always treated with chemotherapy in those patients who have reasonable performance status. Median survival

rates in this kind of patients ranges from 3 to 11 months<sup>9, 12, 15, 17</sup>, it is well known that extent of the disease has a strong impact in survival<sup>1, 12, 13, 15, 20</sup>. Chemotherapeutic agents are those similarly used for the treatment of lung small cell carcinoma. Most commonly used agents are cisplatin, etoposide, cyclophosphamide and doxorubicin; these agents are usually used in combination<sup>1</sup>. It is also important to say that because of the significant number of tumors that have mixed histology, individualization of chemotherapy should also be assessed. Radiation therapy may be also beneficial to patients who need palliative treatment in ED.

## References

1. Brenner B, Tang L, Shia J, Klimstra D, Kelsen D. Small cell carcinomas of the gastrointestinal tract: clinicopathological features and treatment approach. *Semin Oncol* 2007; 34: 43-50.
2. NCCN Practice Guidelines in Oncology. Small Cell Lung Cancer. 2010.
3. Yun JP, Zhang MF, Hou JH, Tian QH, Fu J, Liang XM, Wu QL, Rong TH. Primary small cell carcinoma of the esophagus: clinicopathological and immunohistochemical features of 21 cases. *BMC Cancer* 2007; 7:38.
4. O'Kane AM, O'Donnell ME, Shah R, Carey DP, Lee J. Small cell carcinoma of the appendix. *World J Surg Oncol*. 2008 Jan 15; 6: 4.
5. Zhu W, Jian-Yang M, Jun-Jie Y, Yong-Fan Z, Shang-Fu Z. Primary small cell carcinoma of esophagus: Report of 9 cases and review of literature. *World J Gastroenterol* 2004;10(24):3680-3682.
6. McKeown F. Oat cell carcinoma of the esophagus. *J Path Bact* 1952;64: 889-91.
7. Sun K, He J, Cheng G, Chai L. Management of primary small cell carcinoma of the esophagus. *Chin Med J* 2007;120(5):355-358.
8. Hudson E, Powell J, Mukherjee S, Crosby TDL, Brewster AE, Maughan TS, Bailey H, Lesser JF. Small cell oesophageal carcinoma: an institutional experience and review of the literature. *Br J Cancer* 2007; 96: 708- 711.
9. Ku GY, Minsky BD, Rusch VW, Bains M, Kelsen DP, Ilson DH. Small-cell carcinoma of the esophagus and gastroesophageal junction: review of the Memorial Sloan-Kettering experience. *Ann Oncol* 2008; 19: 533- 537.
10. Pantvaidya GH, Pramesh CS, Deshpande MS, Jambhekar NA, Sharma S, Deshpande RK. Small cell carcinoma of the esophagus: the Tata Memorial Hospital experience. *Ann Thorac Surg* 2002; 74: 1924-7.
11. Yau KK, Siu TW, Wong DC, Chau H, Li CAN, Law BKB, Li MKW. Non-operative management of small cell carcinoma of the esophagus. *Dis Esophagus* 2007; 20 (6): 487-90.
12. Casas F, Ferrer F, Farrus B, Casals J, Biete A. Primary small cell carcinoma of the esophagus: a review of the literature with emphasis on therapy and prognosis. *Cancer* 1997; 80: 1366-1372.

13. Brenner B, Shan MA, Gonen M, Klimstra DS, Shia J, Kelsen DP. Small-cell carcinoma of the gastrointestinal tract: a retrospective study of 64 cases. *Br J Cancer* 2004; 90 (9): 1720 – 6.
14. Huncharek M, Muscat J. Small Cell carcinoma of the esophagus. The Massachussets General Hospital experience, 1987 to 1993. *Chest* 1995, 107(1): 179-181.
15. Lv J, Linag J, Wang J, Wang L, He J, Xiao Z, Yin W. Primary Small Cell Carcinoma of the Esophagus. *J Thorac Oncol.* 2008;3: 1460–1465.
16. Medgyesy CD, Wolff RA, Putnam JB Jr, Ajani JA. Small cell carcinoma of the esophagus: the University of Texas M.D. Anderson Cancer Center experience and literature review. *Cancer* 2000; 88: 262-267.
17. Bennouna J, Bardet E, Deguiral P, Douillard JY. Small cell carcinoma of the esophagus. Analysis of 10 cases and review of the published data. *Am J Clin Oncol* 2000; 23 (5): 455-459.
18. Ho JK, Herrera GA, Jones JM, Alexander CB. Small cell carcinoma of the esophagus: evidence for a unified histogenesis. *Hum Pathol* 1984; 15: 460-8.
19. Nemoto K, Zhao HJ, Goto T, Ogawa Y, Takai Y, Matsushita H, Takeda K, Takahashi C, Saito H, Yamada S. Radiation therapy for limited-stage small cell esophageal cancer. *Am J Clin Oncol* 2002; 25 (4): 404-407.
20. Lam KY, Law S, Tung P, Wong J. Esophageal cell carcinomas. Clinicopathologic parameters, p53 overexpression, proliferation marker and their impact on pathogenesis. *Arch Pathol Lab Med* 2000; 124: 228-233.

---

***Correspondence Address: Manoop S. Bhutani,MD,FACG,FASGE,FACP,AGAF; Professor of Medicine, Experimental Diagnostic Imaging and Biomedical Engineering; Eminent Scientist of the Year 2008, World Scientist Forum; Director of Endoscopic Research and Development; Department of Gastroenterology, Hepatology and Nutrition-Unit 1466; UT MD Anderson Cancer Center; 1515 Holcombe Blvd., Houston, Texas,USA 77030-4009;Phone:713-794-5073; Fax:713-563-4398; manoop.bhutani@mdanderson.org***