

Endoscopic-Assisted Anatomic Reconstruction of Chronic Proximal Hamstring Avulsion With Achilles Allograft



Aaron Leininger, D.O., Robert A. Duerr, M.D., Aakash Chauhan, M.D., M.B.A., Ryan P. McGovern, Ph.D., A.T.C., and John J. Christoforetti, M.D.

Abstract: Hamstring injuries commonly occur at the musculotendinous junction; however, they can occur as proximal avulsion injuries. A lack of recognition can lead to proximal hamstring injuries being frequently misdiagnosed, resulting in delayed treatment. Chronic proximal hamstring tears are often retracted and scarred to the surrounding soft tissues. Owing to the poor quality of tissue at the torn ends of the tendon, an augmented reconstruction using an allograft may be required. In cases with poor visualization of the ischial tuberosity and proximal hamstring footprint, an Achilles tendon allograft can be secured directly to the tuberosity with suture anchors. However, visualization of the footprint can be optimized using an arthroscope. This report describes a technique for endoscopic-assisted anatomic reconstruction using an Achilles allograft with both knotless and knotted suture anchors for chronic complete avulsions of the proximal hamstring.

Complete rupture of the proximal hamstring accounts for approximately 9% of all hamstring injuries.¹ Although hamstring muscle strains are among the most common injuries in athletes and respond well to conservative management, complete ruptures generally have poor outcomes with conservative treatment.¹⁻³ There is a lack of consensus regarding timing and indications for surgery,¹ with several reported indications including avulsion of 2 tendons with more than 2 cm of retraction, complete avulsion of all 3 tendons, displaced bony avulsions, and partial avulsions with persistent pain despite extensive conservative treatment.^{4,5} It is also important to consider patient factors during surgical consultation, such as age, activity level, functional demands, and expectations. Delayed

surgical intervention (>4 weeks) is associated with prolonged morbidity and can be associated with a higher rate of complications owing to the increased technical difficulty required to perform the surgical procedure. However, this is sometimes unavoidable in patients presenting late after injury.⁶⁻⁸

Chronic proximal hamstring avulsions are often retracted and scarred to surrounding soft tissues. This presentation is more typical of middle-aged patients with an isolated injury causing persistent pain, weakness, and sciatica-like symptoms due to nerve irritation. Preoperative magnetic resonance images showing a chronic proximal hamstring avulsion are presented in **Figure 1**. These patients are more likely to have poor-quality tissue at the torn ends of the tendon and may

From Allegheny Health Network West Penn Hospital, Pittsburgh, Pennsylvania, U.S.A.

A.L. is now with LECOM Health—Millcreek Community Hospital, Erie, Pennsylvania, U.S.A. R.A.D. is now with Jameson Crane Sports Medicine Institute, The Ohio State University Wexner Medical Center, Columbus, Ohio, U.S.A. A.C. is now with Dupage Medical Group, Naperville, Illinois, U.S.A. R.P.M. and J.J.C. are now with Texas Health Sports Medicine, Dallas/Fort Worth, Texas, U.S.A.

The authors report the following potential conflicts of interest or sources of funding: J.J.C. receives grant support from Allegheny Singer Research Institute; receives royalties for patents from Arthrex and Breg; receives payment for lectures including service on speakers bureaus from Arthrex and Breg; receives payment for development of educational presentations from Arthrex and Breg; and is a committee member of the Arthroscopy Association of North America.

J.J.C. is a board member of the International Society for Hip Arthroscopy; and receives personal fees from Arthrex and Breg. Full ICMJE author disclosure forms are available for this article online, as [supplementary material](#).

Received February 11, 2020; accepted April 12, 2020.

Address correspondence to Ryan P. McGovern, Ph.D., A.T.C., Texas Health Sports Medicine, 1120 Raintree Cir, Ste 280, Allen, TX 75013, U.S.A. E-mail: ryanmcgovern@texashealth.org

© 2020 by the Arthroscopy Association of North America. Published by Elsevier. This is an open access article under the CC BY-NC-ND license (<http://creativecommons.org/licenses/by-nc-nd/4.0/>).

2212-6287/20214

<https://doi.org/10.1016/j.eats.2020.04.011>

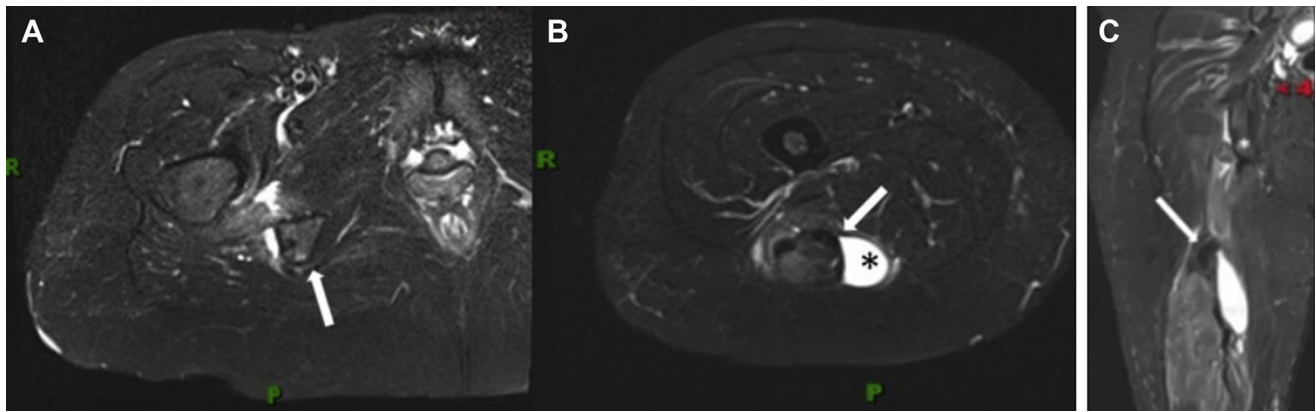


Fig 1. Preoperative magnetic resonance imaging showing hamstring avulsion. Patient in supine position. (A) An axial T1-weighted image of left proximal thigh shows a “bald” ischial tuberosity (arrow) with an adjacent fluid collection. (B) An axial T2-weighted magnetic resonance image shows the distal retraction of the hamstring tendon stump (arrow) with a large adjacent fluid collection (asterisk). (C) A sagittal T2-weighted image shows the extent of the tendon retraction with the tendon stump (arrow) located approximately 10 cm from the ischial tuberosity (asterisk). (R, right; P, posterior.)

require an augmented reconstruction using an allograft. A technique for Achilles allograft reconstruction of chronic complete proximal hamstring ruptures has previously been described with favorable results.^{9,10} This technique requires an extensive incision, identification of the sciatic nerve and torn tendons, fixation of the distal end of the Achilles allograft to the tuberosity as a bone plug with an interference screw, and suturing of the proximal allograft to the hamstring tendons with a combination of absorbable and nonabsorbable sutures at the desired tension.^{7,9} In cases with poor visualization of the ischial tuberosity–proximal hamstring footprint, the allograft Achilles tendon is secured directly to the tuberosity with suture anchors as dictated by visualization of the footprint.⁹ Achieving an anatomic reattachment of the proximal hamstring tendons to the footprint can be technically demanding in these cases. In this report, we describe a technique for endoscopic-assisted anatomic reconstruction using Achilles allograft with both knotless and knotted suture anchors for chronic complete avulsions of the proximal hamstring.

Surgical Technique

Preoperative Setup

After induction of general anesthesia, the patient is placed prone on the operating table with all bony prominences padded. In this case, an ultrasound examination was performed to identify the stump of the retracted proximal hamstring tendons and to mark the longitudinal limb of the skin incision. The horizontal limb of a T-shaped incision is marked in line with the gluteal fold (Fig 2). The entire extremity is prepared and draped in sterile fashion, with care taken to expose the area above the gluteal fold (Fig 3).

Surgical Exposure

A T-shaped incision is made as previously marked. The incision may be extended proximally as necessary for safe exposure of the sciatic nerve and proximal hamstring tendons. Full-thickness skin flaps are dissected to the level of the deep fascia. The gluteus maximus is retracted superiorly. The deep fascia

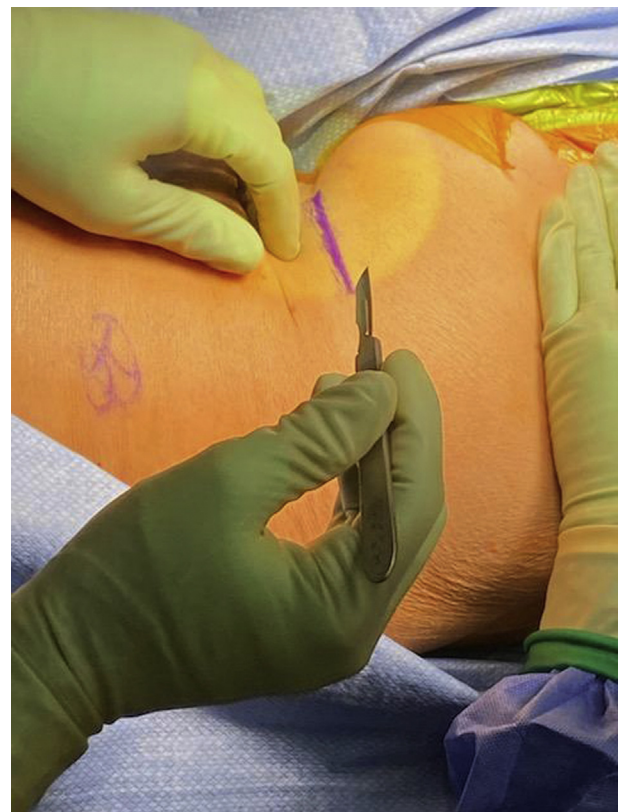


Fig 2. The horizontal limb of the T-shaped incision is marked in line with the gluteal fold (purple line).

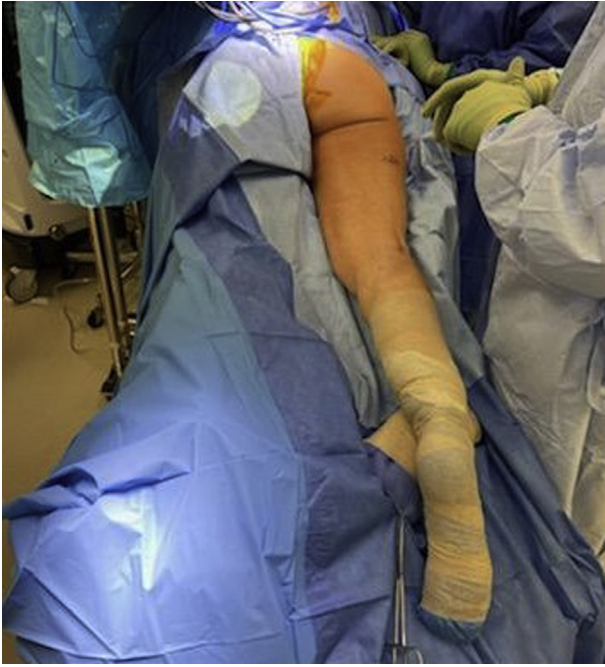

Fig 3. The patient is placed prone on the operating table with all bony prominences padded. The entire extremity is prepared and draped in sterile fashion, with care taken to expose the area above the gluteal fold.

overlying the proximal hamstring is sharply incised, which allows for exposure of the paratenon and torn ends of the tendon. Commonly, a seroma may be encountered depending on the chronicity of the tear. Care should be taken to protect the posterior femoral

cutaneous nerve at this stage of the procedure. Identification and neurolysis of the sciatic nerve comprise an important step, especially in symptomatic patients. Once the sciatic nerve is identified and protected, the ends of the tendon are identified, mobilized, and debrided of devitalized tissue (Fig 4, Video 1).

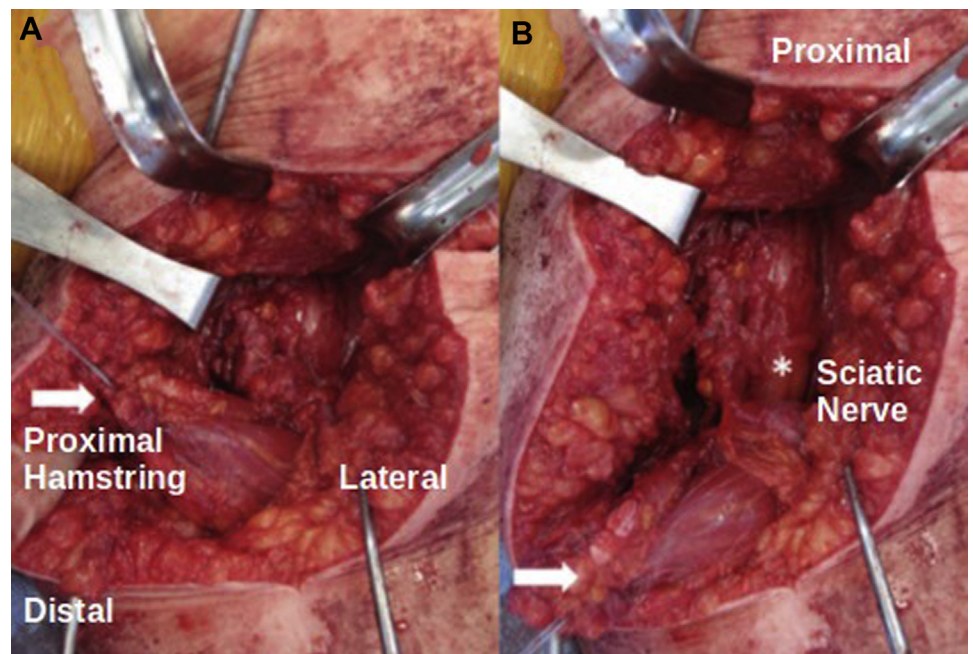
Bone Preparation

Attention is then turned to the ischial tuberosity preparation. This may be done through either an open or endoscopic approach. The ischial tuberosity is identified, and the proximal hamstring footprint is debrided to a bleeding bony bed. The anchors are placed in a diamond configuration with three 3.0-mm single-loaded SutureTak anchors (Arthrex, Naples, FL) placed in an inverted-triangle configuration and a 4.75-mm SwiveLock anchor (Arthrex) placed at the superior edge (Fig 5, Video 1).

Achilles Allograft Preparation

The Achilles allograft is prepared by initially removing any calcaneus bone block. The remaining tendon is sutured using a FiberLoop suture (Arthrex) that is whipstitched through the end of the Achilles tendon allograft. The whipstitch should exit at the superior end of the allograft with 10 cm of suture tail present. The final pass of the whipstitch ensures that the remaining tail exits inferiorly on the graft. The position of the desired exit point will vary depending on the degree of retraction and soft-tissue loss of the native hamstring tendon. In the case presented, the exit point is shown at approximately half the length of the allograft. As with the proximal

Fig 4. Intraoperative images during proximal hamstring reconstruction. (A) The proximal hamstring tendons (arrow) have been freed from chronic adhesions. (B) The sciatic nerve (asterisk) is visible with the hamstring tendons (arrow) reflected.



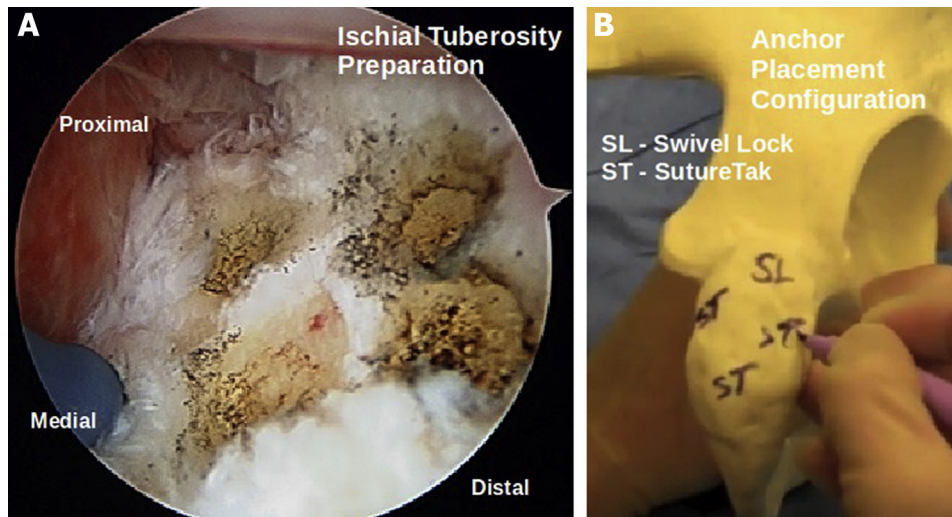


Fig 5. (A) Endoscopic image of ischial tuberosity with anchor placement marked by electrocautery. (B) Pelvis model showing diamond configuration of anchor placement on ischial tuberosity.

suture tails, at least 10 cm of suture tail should be present in the distal suture tails (Fig 6, Video 1).

Repair of Allograft to Ischial Tuberosity

Each limb of suture from the 3 SutureTak anchors is passed through the whipstitched allograft tendon in a similar inverted-triangle position, for a total of 6 suture limbs. The suture limbs should be kept separate to allow for knot tying (Fig 7). With tension held on these sutures, the allograft is shuttled to the ischial tuberosity footprint with the original looped suture and anchored with a 4.75-mm SwiveLock anchor in a knotless fashion (Fig 8). The remaining sutures are tied using an arthroscopic knot pusher to ensure adequate tension and contact of the tendon with the ischial tuberosity (Fig 9, Video 1).

Repair of Native Proximal Hamstring Tendons to Allograft

The native proximal hamstring tendon is secured with a running Krackow stitch with No. 2 FiberWire

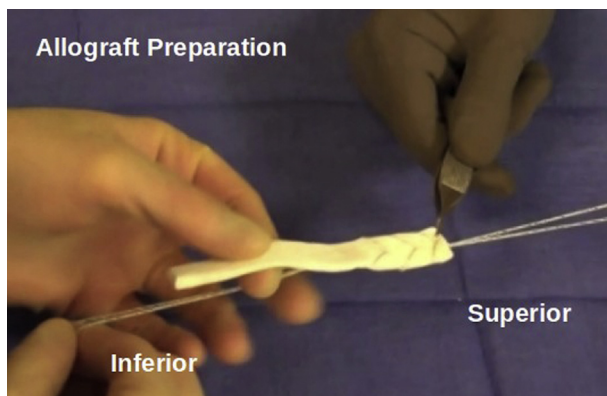


Fig 6. Achilles allograft preparation with whipstitch. The superior end is the end that will be fixed to the ischial tuberosity during reconstruction.

(Arthrex), and the ends of this suture are tied to the proximal end of the original FiberLoop suture that was passed through the allograft (Fig 10). Flexion of the knee should be performed to maintain appropriate tension as these sutures are tied (Figs 11 and 12). Side-to-side sutures can be added for additional strength of the allograft to the native tendon construct (Video 1). A surgical technique overview is provided in Table 1. Pearls and pitfalls of this procedure are outlined in Table 2.

Postoperative Protocol

The patient was seen in the office by the senior author (J.J.C.) the day after surgery. The patient was weight bearing as tolerated with a walker for 6 weeks postoperatively. The patient was pre-fit for a hip orthosis

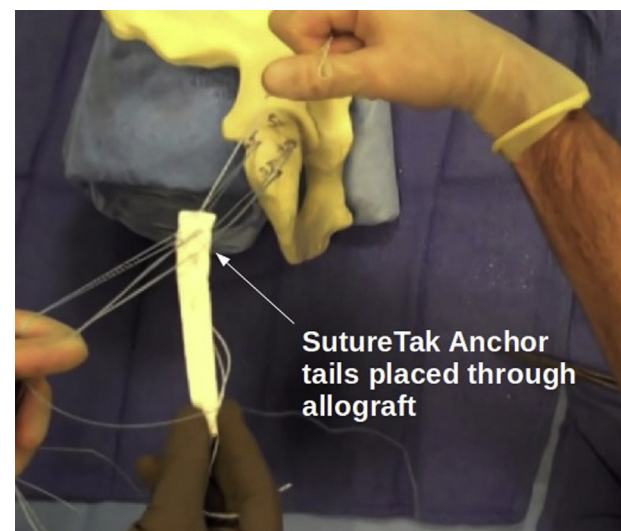


Fig 7. Sawbones model (Vashon Island, WA) showing the passage of the SutureTak anchor tails through the Achilles allograft.

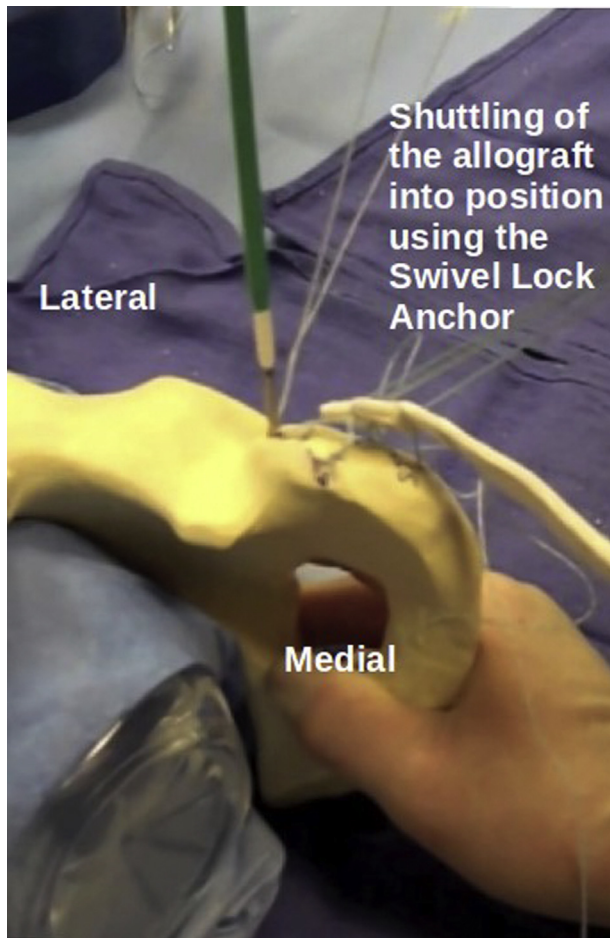


Fig 8. Sawbones model showing the shuttling process of the allograft into position using the Swivel Lock anchor. The superiorly exiting whipstitch is passed through the Swivel Lock anchor for this portion of shuttling.

(T-Scope Hip; Breg, Carlsbad, CA) by a trained medical equipment professional. The brace was set to allow full hip extension and 45° of hip flexion for the first 6 weeks. Daily mobilization with foot and ankle pumps was performed by the patient. Following in-office consultation with the senior author, the patient discontinued use of the walker at 6 weeks postoperatively. From week 6 to 12 postoperatively, the patient maintained wearing the brace unrestricted and was instructed to ambulate with caution and perform knee bending during toe-touch activities of daily living. Physical therapy focused on restoration of gait with gluteus and core isometrics. The patient returned to full pain-free athletic participation at 5 months postoperatively.

Discussion

Surgical management of proximal hamstring avulsions, especially chronic injuries, can pose a significant challenge. The functional demand of the hamstring requires a biomechanically strong, anatomic repair to achieve successful tendon-to-bone healing. In a recent

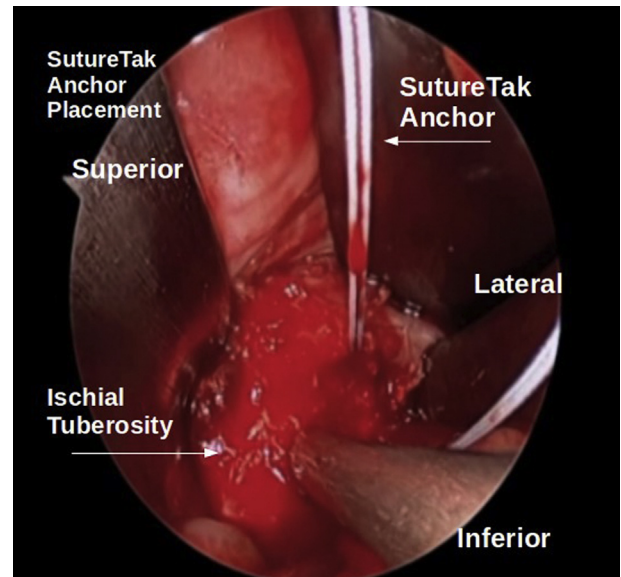


Fig 9. Endoscopic image of ischial tuberosity during placement of SutureTak anchors in the inferior 3 positions of the previously shown diamond configuration.

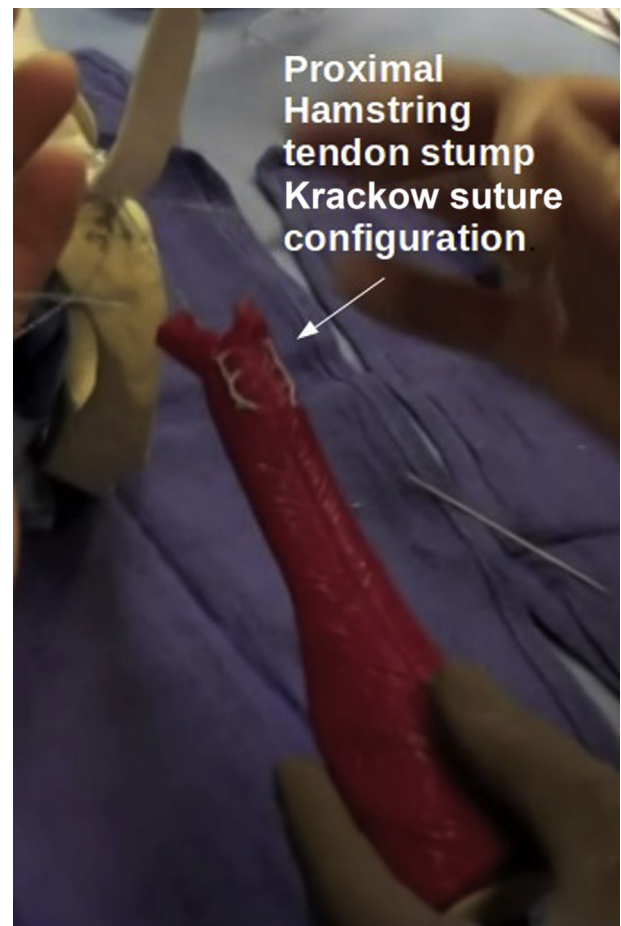

Fig 10. Sawbones model showing the Krackow stitch configuration in the proximal tendon stump. Two suture tails should be exiting from the stump once completed.

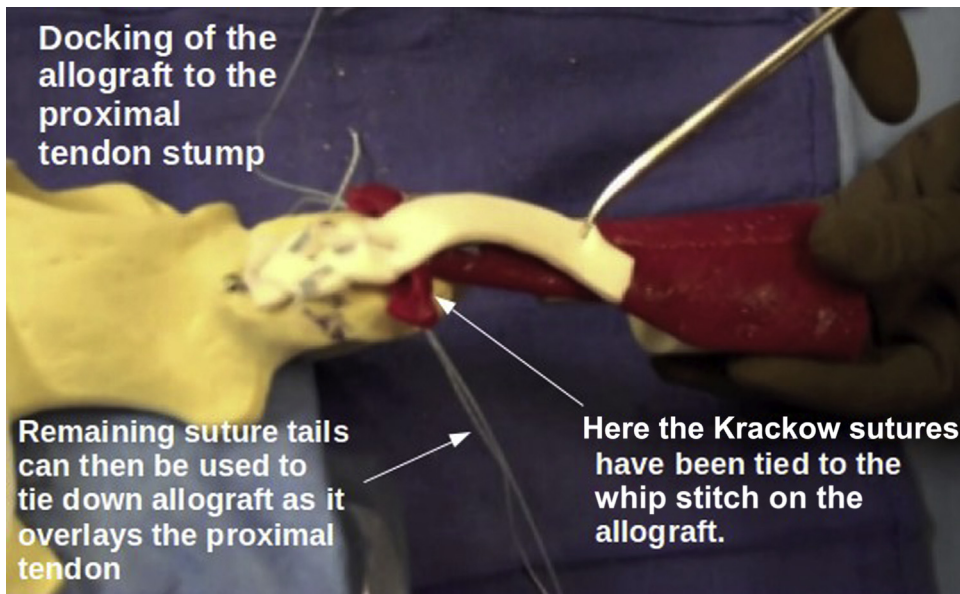


Fig 11. Sawbones model showing the docking of the proximal tendon stump with the allograft tissue. The Krackow suture tails of the stump are tied to the inferiorly exiting whipstitch on the allograft.

cadaveric study comparing 3 constructs for repair of complete proximal hamstring avulsions (2 small anchors, 2 large anchors, and 5 small anchors) with the intact proximal hamstring, the authors found that the repair using 5 small anchors provided similar strength to the intact proximal hamstring and was significantly stronger than either 2-anchor repair.¹¹ They believed that the 5-anchor construct provided a more secure repair to the large footprint as opposed to “focally spot-welding” with only 2 anchors.¹¹ We believe that our technique similarly uses sound biomechanical principles to better re-create the native anatomy and disperse forces with a diamond-configuration 4-anchor repair,

although further biomechanical testing is needed. Identifying the appropriate position and location of the proximal hamstring footprint can be difficult in large open cases, but we believe using the endoscope to identify and mark the positions of the suture anchors provided a more anatomic repair.

The theoretical advantages of this approach over a large open approach include a lower risk of iatrogenic sciatic nerve injury, lower infection risk, and improved identification of the proximal hamstring footprint anatomy. A similar technique described the advantages of a dry endoscopic-assisted repair over an all-endoscopic repair to include a similar infection risk, a

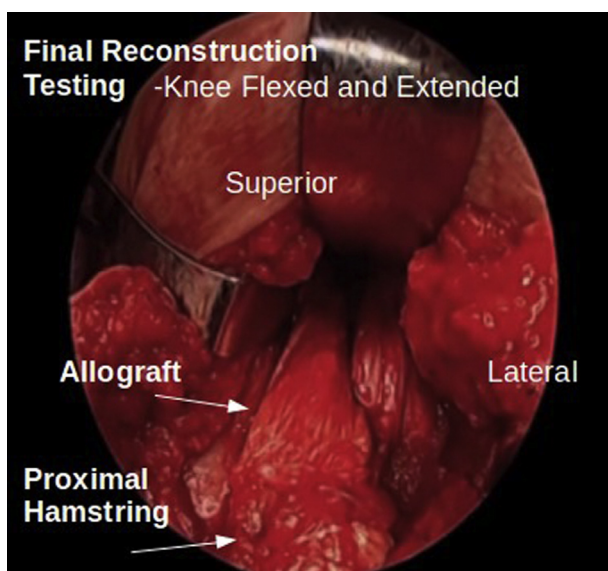


Fig 12. Intraoperative image showing the final reconstruction during testing of the construct. The knee is flexed and extended while the repair is directly visualized.

Table 1. Surgical Technique Overview

1. Expose the tuberosity, tendon stump, and sciatic nerve.
2. Prepare the tuberosity by removing the tendon stump and placing suture anchors.
3. Prepare the tendon stump using nonabsorbable suture in a Krackow fashion with 2 tails exiting the tendon stump.
4. Prepare the Achilles allograft.
 - a. Remove the bone block from the allograft (the end with the bone block will function as the proximal end of the graft).
 - b. Pass a Krackow suture through the allograft, leaving 10 cm of proximal suture and 10 cm of free distal suture.
 - i. Bear in mind that proximal limbs will pass through SwiveLock and distal limbs will anastomose with sutures placed in the hamstring stump.
5. Pass the tails of the pre-placed SutureTak anchors through the allograft in a matching inverted-triangle configuration.
6. Shuttle the allograft to the ischial footprint with the SwiveLock anchor and securely tie the SutureTak tails.
7. Tie the remaining suture tails of the allograft to the corresponding tendon stump to dock the distal end of the graft.
8. Use No. 2-0 FiberWire to oversew the fan-like distal allograft into the proximal hamstring stump.
9. Confirm that the sciatic nerve is free of the repair site and knee flexion-extension can proceed with graft integrity maintained.

Table 2. Pearls and Pitfalls

1. Endoscopy is performed with water if bleeding is minimal; otherwise, dry endoscopy is performed.
2. The T-shaped incision is made as large as necessary for safe exposure of the sciatic nerve and proximal hamstring tendons.
3. The diamond configuration for anchor placement is marked with electrocautery on the ischial tuberosity.
4. The borders of the ischial tuberosity should be identified to ensure the anchors are all placed completely in bone.
5. The surgeon should leave enough excess suture loop at the end of the allograft to shuttle the graft to the footprint.
6. The SutureTak suture limbs should be passed through the graft in a diamond configuration with a suture-passing device.
7. Suture management is critical during suture passage to maintain the diamond configuration and maximize tendon-to-bone contact.
8. Tension should be held on the SutureTak suture limbs while the graft is shuttled to the footprint.
9. The native proximal hamstring tendons should be secured to the graft with the knee flexed to 90° to ensure adequate tension.
10. Side-to-side sutures should be placed to improve the strength of the native tendon to the graft repair.

less technically demanding technique to achieve a more anatomic repair, and no risk of fluid extravasation.¹² Further studies comparing the outcomes of fully open, all-endoscopic, and endoscopic-assisted surgical techniques are needed.

As with any surgical procedure, there are risks associated with the described intervention. This procedure does have specific risks and limitations that should be discussed with the patient prior to intervention aside from the general risks of surgery alone: the use of allograft tissue and its potential for serving as a nidus for infection and/or disease transmission, the possibility of fibrous tissue formation that may limit functional outcome or reintroduction of scarring leading to sciatica symptoms in the affected extremity, and the risk of incomplete release of the scar tissue surrounding the sciatic nerve during the procedure. If the endoscopic method is used, care should be taken to ensure appropriate visualization is obtained and, if not possible, then conversion to more extensile exposure should be performed to ensure appropriate neurolysis and graft positioning are obtained.

Previous reports of allograft-augmented reconstructions of the proximal hamstring used extensive incisions and described difficulty in identifying the proximal hamstring footprint on the ischial tuberosity.^{9,10} We believe this endoscopic-assisted technique provides a safe and effective approach to achieve an

accurate repair of the proximal hamstring while decreasing the risk of postoperative infection and iatrogenic sciatic nerve injury associated with more extensile approaches.

References

1. van der Made AD, Reurink G, Gouttebauge V, Tol JL, Kerkhoffs GM. Outcome after surgical repair of proximal hamstring avulsions: A systematic review. *Am J Sports Med* 2015;43:2841-2851.
2. Vassallo AJ, Hiller CE, Pappas E. Conservative interventions for acute hamstring injuries (PEDro synthesis). *Br J Sports Med* 2016;50:1548-1549.
3. Harris JD, Griesser MJ, Best TM, Ellis TJ. Treatment of proximal hamstring ruptures—A systematic review. *Int J Sports Med* 2011;32:490-495.
4. Pasic N, Giffin JR, Degen RM. Practice patterns for the treatment of acute proximal hamstring ruptures. *Phys Sportsmed* 2020;48:116-122.
5. Domb BG, Linder D, Sharp KG, Sadik A, Gerhardt MB. Endoscopic repair of proximal hamstring avulsion. *Arthrosc Tech* 2013;2:e35-e39.
6. Ahmad CS, Redler LH, Ciccotti MG, Maffulli N, Longo UG, Bradley J. Evaluation and management of hamstring injuries. *Am J Sports Med* 2013;41:2933-2947.
7. Subbu R, Benjamin-Laing H, Haddad F. Timing of surgery for complete proximal hamstring avulsion injuries: Successful clinical outcomes at 6 weeks, 6 months, and after 6 months of injury. *Am J Sports Med* 2015;43:385-391.
8. Carmichael J, Packham I, Trikha SP, Wood DG. Avulsion of the proximal hamstring origin. Surgical technique. *J Bone Joint Surg Am* 2009;91:249-256 (suppl 2).
9. Folsom GJ, Larson CM. Surgical treatment of acute versus chronic complete proximal hamstring ruptures: Results of a new allograft technique for chronic reconstructions. *Am J Sports Med* 2008;36:104-109.
10. Rust DA, Giveans MR, Stone RM, Samuelson KM, Larson CM. Functional outcomes and return to sports after acute repair, chronic repair, and allograft reconstruction for proximal hamstring ruptures. *Am J Sports Med* 2014;42:1377-1383.
11. Hamming MG, Philippon MJ, Rasmussen MT, et al. Structural properties of the intact proximal hamstring origin and evaluation of varying avulsion repair techniques: An in vitro biomechanical analysis. *Am J Sports Med* 2015;43:721-728.
12. Gomez-Hoyos J, Reddy M, Martin HD. Dry endoscopic-assisted mini-open approach with neuromonitoring for chronic hamstring avulsions and ischial tunnel syndrome. *Arthrosc Tech* 2015;4:e193-e199.