

## CASE REPORT

# Osimertinib-related liver injury with successful osimertinib rechallenge: A case report

Yuan-Ling Cheng<sup>1</sup>  | Wei-Kuo Chang<sup>2</sup> | Hao Yen<sup>3</sup> | Yi-Jen Peng<sup>3</sup> |  
Wei-Chou Chang<sup>4</sup> | Ping-Ying Chang<sup>5</sup>

<sup>1</sup>Division of Urology, Department of Surgery, Tri-Service General Hospital, National Defense Medical Center, Taipei, Taiwan, ROC

<sup>2</sup>Division of Gastroenterology, Department of Internal Medicine, Tri-Service General Hospital, National Defense Medical Center, Taipei, Taiwan, ROC

<sup>3</sup>Department of Pathology, Tri-Service General Hospital, National Defense Medical Center, Taipei, Taiwan, ROC

<sup>4</sup>Department of Radiology, Tri-Service General Hospital, National Defense Medical Center, Taipei, Taiwan, ROC

<sup>5</sup>Division of Hematology/Oncology, Department of Internal Medicine, Tri-Service General Hospital, National Defense Medical Center, Taipei, Taiwan, ROC

## Correspondence

Ping-Ying Chang, Division of Hematology/Oncology, Department of Internal Medicine, Tri-Service General Hospital, National Defense Medical Center, Taipei, Taiwan, ROC.  
Email: max-chang@yahoo.com.tw  
Present address Ping-Ying Chang, No. 325, Sec 2, Cheng-Gong Road, Neihu District, 114, Taipei, Taiwan, ROC.

## Abstract

Osimertinib is approved as the first-line treatment for advanced non-small cell lung cancer patients with epidermal growth factor (EGFR) mutation and for patients who develop EGFR T790M mutation during EGFR tyrosine kinase inhibitor (TKI) treatment and disease progression. Asymptomatic elevation of aminotransferase levels is commonly observed during TKI treatment; however, significant hepatotoxicity is infrequent. Here, we report a patient with osimertinib-related drug-induced liver injury who was successfully managed with osimertinib rechallenge.

## KEYWORDS

drug-induced liver injury, non-small cell lung cancer, osimertinib

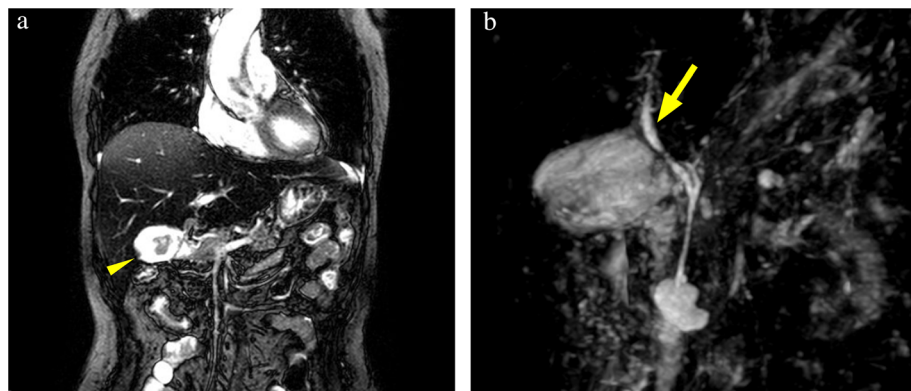
## INTRODUCTION

Osimertinib is a novel irreversible, covalent third-generation epidermal growth factor receptor (EGFR)-tyrosine kinase inhibitor (TKI) and potent inhibitor of EGFR T790M mutation in non-small cell lung cancer (NSCLC).<sup>1</sup> The AURA 3 trial demonstrated the superior clinical activity and safety of osimertinib in advanced NSCLC patients with T790M mutation after first-generation EGFR-TKI resistance.<sup>2</sup> Nonetheless, the FLAURA trial showed that osimertinib has superior efficacy than those of standard EGFR-TKIs in the first-line treatment of EGFR mutant advanced NSCLC, regardless of T790M mutation status.

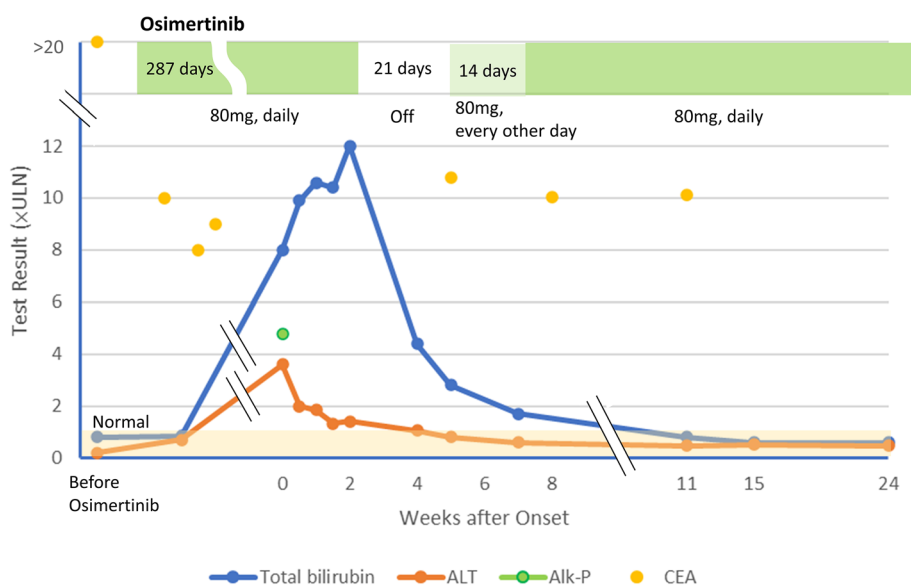
Current literature on drug-induced liver injury (DILI) secondary to osimertinib and the subsequent management processes is scarce.<sup>3–5</sup> Here, we report a patient with osimertinib-related DILI managed with osimertinib desensitization rechallenge.

## CASE REPORT

A 55-year-old female nonsmoker was diagnosed with NSCLC (right lower lobe, cT4N2M1b, stage IVB with EGFR exon 19 deletion) and lung to lung and bone metastases following surgery for a right humeral shaft fracture in September 2019. Afatinib (40 mg daily) had been initiated since October 2019, but newly developed lesions over the left lung, mediastinum, and bones were revealed after one year. Biopsy of the left lower lobe tumor revealed a T790M mutation. Consequently, afatinib had been changed to osimertinib 80 mg/day since December 2020. The patient experienced grade 1 diarrhea, vomiting, anorexia and skin toxicities during osimertinib treatment and was admitted due to progressive jaundice in September 2021. She did not take any drug and Chinese herb medicine concomitantly. Physical examination showed no fever, alert consciousness, icteric sclera, and right upper quadrant abdominal



**FIGURE 1** Magnetic resonance cholangiopancreatography images. (a) Edematous wall thickening of the gallbladder with sludges (arrowhead). (b) No obstruction in the common bile duct and intrahepatic ducts (arrow)



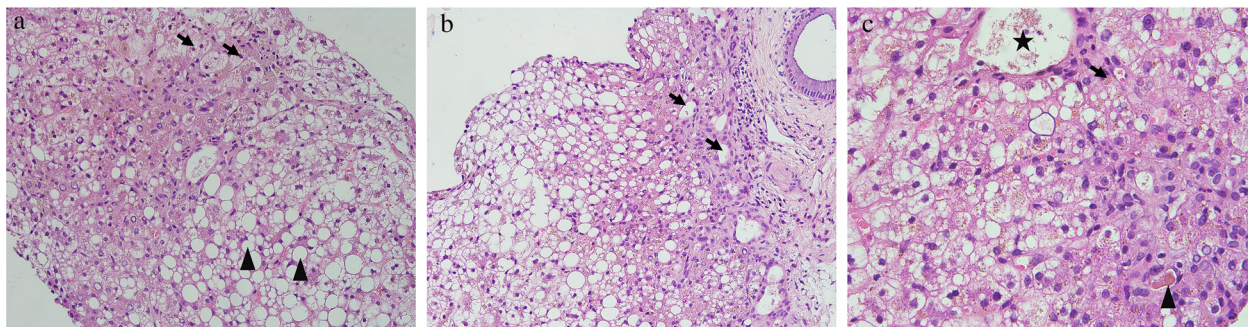
**FIGURE 2** Serum alkaline phosphatase, and total bilirubin, alanine aminotransferase (ALT), and CEA level changes during treatment with osimertinib

tenderness without positive Murphy's sign. There was no elevation of C-reactive pretension and procalcitonin. An increase in aspartate aminotransferase (AST, 209 U/l), alanine aminotransferase (ALT, 143 IU/l), bilirubin (total 8 mg/dl, and direct 4.3 mg/dl), alkaline phosphatase (Alk-P, 495 U/l), and gamma-glutamyltransferase (691 U/l) was detected. Viral tests, including hepatitis (A, B, C), Epstein-Barr, cytomegalovirus, herpes, and human immunodeficiency virus and autoimmune studies, including antinuclear antibody, rheumatoid factor, and antimicrochondria antibody, showed negative results. The serum lactate dehydrogenase, haptoglobin, and alpha-fetoprotein were within normal ranges. The abdominal computed tomography and magnetic resonance cholangiopancreatography after admission showed fatty liver, gallbladder with edematous wall thickening and sludge. Neither hepatomegaly nor biliary tract obstruction was identified (Figure 1).

Although the liver enzymes improved without discontinuing osimertinib, the bilirubin levels deteriorated (maximum: total 12.0 mg/dl, direct 6.3 mg/dl, Figure 2). We arranged a liver biopsy and Hematoxylin and eosin

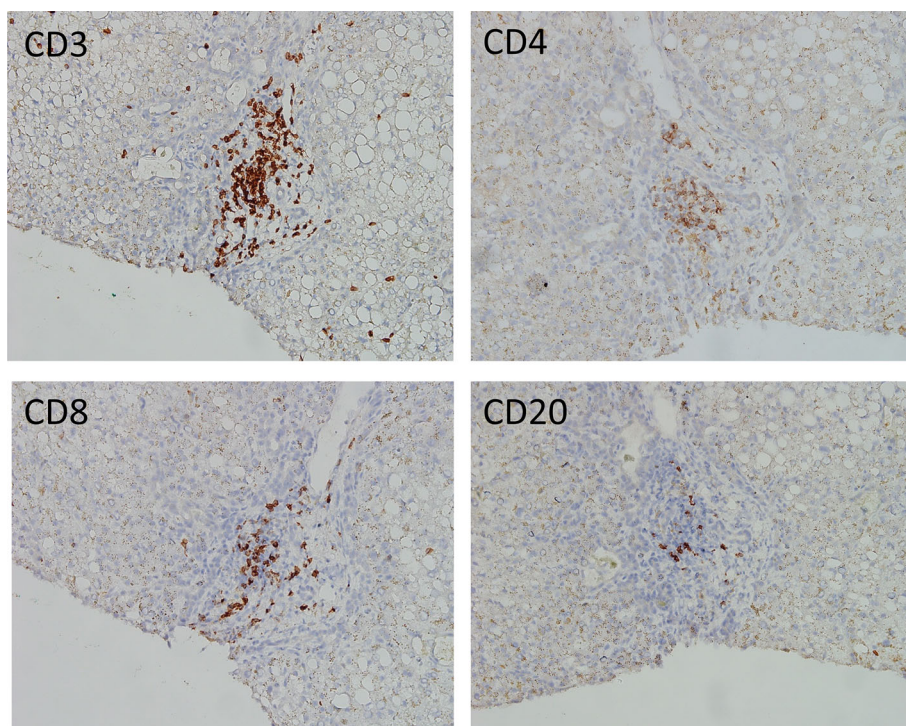
stain showed macro- and microvesicular steatosis with ballooning degeneration of hepatocytes and periportal lymphocytic infiltration, indicating steatohepatitis. Cholestasis presented with bile pigments and bile plugs within hepatic parenchyma around the central vein area was also seen. No obvious bile duct dilatation was shown (Figure 3). The immunohistochemistry (IHC) stain showed that portal tracts were mainly infiltrated by the CD3+, CD4+, CD8+ T cells in comparison with CD20+ B cells (Figure 4).

Because osimertinib-related moderate to severe DILI (moderate to severe grade [score 3] in the DILIN scoring system) was suspected, osimertinib was discontinued. Two weeks after discontinuing osimertinib, the total bilirubin concentration decreased to 4.4 mg/dl. The patient preferred treatment with osimertinib to chemotherapy. Three weeks after osimertinib had been discontinued with serum total bilirubin 2.8 mg/dl, we restarted osimertinib (80 mg every other day) for two weeks, and gradually increased to 80 mg per day. The total bilirubin levels eventually returned to normal ranges six weeks after rechallenge. The patient's Eastern



**FIGURE 3** Hematoxylin and eosin stain of the liver biopsy. (a) Macrovesicular (arrowhead) and microvesicular (arrow) steatosis with ballooning degeneration of the hepatocytes (200 $\times$ ). (b) No obvious bile duct dilatation (arrow) (200 $\times$ ). (c) Canalicular cholestasis with bile pigment (arrow) and bile plugs (arrowhead) within the hepatic parenchyma around the central vein area (star) (400 $\times$ )

**FIGURE 4** Immunohistochemistry stain of liver biopsy (200 $\times$ ). Periportal inflammation with CD3+, CD4+, CD8+ lymphocytes predominant infiltration compared to CD20+ lymphocytes



Cooperative Oncology Group performance status was 1 before and after osimertinib rechallenge. Only grade 1 skin toxicities were noted after the retreatment.

## DISCUSSION

The elevation in serum ALT levels is seen in approximately 6% of patients receiving osimertinib, and adverse events of grade 3 or higher observed in less than 1%.<sup>6</sup> After assessing with the Roussel Uclaf Causality Assessment Method system,<sup>7</sup> DILI was highly suspected in our case. Hoofnagle et al. classified DILI into direct, idiosyncratic and indirect subtypes.<sup>8</sup> The possible subtype of our case may be idiosyncratic or indirect and the phenotype may be cholestatic or mixed. Houron et al. have published a comprehensive literature review on multikinase inhibitor-related hepatotoxicity.

The authors reported that the latency is usually between one week to two months, and the TKI-related liver toxicity is often hepatocellular and less frequently mixed.<sup>9</sup> When it comes to osimertinib, the latency is 15 days to one month.<sup>3-5</sup> In our case, the latency was nine months and  $R$ -value was 0.57 (hepatocellular [ $R > 5$ ], cholestatic [ $R < 2$ ], or mixed DILI [ $2 < R < 5$ ]), suggesting cholestatic DILI.

The DILI network categorizes liver injury into 18 histological patterns.<sup>10-12</sup> Previous reports of liver biopsy pathology of EGFR TKI (gefitinib, erlotinib) showed active hepatitis with portal inflammation and bridging fibrosis.<sup>9</sup> In the case reported by Gonzalez et al., the pathology of liver biopsy revealed pericentral confluent necrosis which is classified as zone necrosis in the DILI network system and the portal tracts showed mild nonspecific chronic inflammation.<sup>5</sup> The adaptive immune system mediated mainly by cytotoxic (CD8+) T cells plays a major role in the

pathogenesis of idiosyncratic DILI.<sup>13</sup> Foureau et al. compared the portal hepatic infiltrating leukocytes in acute DILI and non-DILI cause of acute liver injury which showed predominantly CD8+ T cells, compared with CD20+ B cells in DILI.<sup>14</sup> Yamaguchi et al. also showed CD3+ and CD8+ lymphocytes were mainly infiltrating immune cells compared with CD20+ lymphocytes in the portal tracts in liver biopsy tissues of two cases with liver injury resulting from osimertinib after nivolumab therapy.<sup>15</sup> The pathology in our case showed a mixed pattern based on the DILI network classification and portal tracts were mainly infiltrated by the CD3+, CD4+, CD8+ T cells, while compared with CD20+ B cells on the IHC stain. Effector CD4+ T cells can orchestrate an immune response by upregulating membrane costimulatory molecules, producing cytokines and killing target cells via the membranous molecules.<sup>16</sup> Drug-triggered effector CD8+ and CD4+ T cells play an important role in DILI. Although the histological pattern was incompatible with the R-value, the current analysis revealed a limited correlation between biochemical categorization and the pathological pattern of injury.<sup>10</sup>

Desensitization rechallenge has been previously reported.<sup>3,4</sup> It took Hirabayashi et al. three weeks to increase the dose to 40 mg/day, whereas Yoshida et al. needed to wait seven weeks before increasing the dose to 80 mg/day with gradual titration. All patients were treated successfully without recurrence of the hepatotoxicity. In our case, it took us four weeks to increase the dose to 80 mg/day. Neither disease progression nor newly developed adverse events were noted after retreatment.

Although osimertinib-induced hepatotoxicity is rarely reported, osimertinib-related DILI should be the differential diagnosis in NSCLC patients with liver dysfunction. Desensitization rechallenge may be considered for osimertinib-related DILI.

#### ACKNOWLEDGMENT

We would like to thank Crimson Interactive Inc. for English language editing.

#### CONFLICT OF INTEREST

The authors declare that they have no competing interests.

#### ORCID

Yuan-Ling Cheng  <https://orcid.org/0000-0002-8447-0362>

#### REFERENCES

- Lee C-S, Milone M, Seetharamu N. Osimertinib in EGFR-mutated lung cancer: a review of the existing and emerging clinical data. *Oncotargets Ther.* 2021;14:4579–97.
- Mok TS, Wu Y-L, Ahn M-J, Garassino MC, Kim HR, Ramalingam SS, et al. Osimertinib or platinum-pemetrexed in EGFR T790M-positive lung cancer. *N Engl J Med.* 2017;376:629–40.
- Yoshida H, Kim YH. Successful osimertinib rechallenge after severe osimertinib-induced hepatotoxicity. *J Thorac Oncol.* 2018;12:e61–3.
- Hirabayashi R, Fujimoto D, Satsuma Y, Hirabatake M, Tomii K. Successful oral desensitization with osimertinib following osimertinib-induced fever and hepatotoxicity: a case report. *Invest New Drugs.* 2018;36(5):952–4.
- González I, Chatterjee D. Histopathological features of drug-induced liver injury secondary to Osimertinib. *ACG Case Rep J.* 2019;6:e00011.
- Soria J-C, Ohe Y, Vansteenkiste J, Reungwetwattana T, Chewakulyong B, Lee KH, et al. Osimertinib in untreated EGFR-mutated advanced non-small-cell lung cancer. *N Engl J Med.* 2018;378(2):113–25.
- Danan G, Teschke R. Roussel Uclaf causality assessment method for drug-induced liver injury: present and future. *Front Pharmacol.* 2019;10:853.
- Hoofnagle JH, Björnsson ES. Drug-induced liver injury—types and phenotypes. *N Engl J Med.* 2019;381(3):264–73.
- Houron C, Danielou M, Mir O, Fromenty B, Perlemuter G, Voican CS. Multikinase inhibitor-induced liver injury in patients with cancer: a review for clinicians. *Crit Rev Oncol Hematol.* 2021;157:103127.
- Kleiner DE. Histopathological challenges in suspected drug-induced liver injury. *Liver Int.* 2018;38:198–209.
- Kleiner DE, Chalasani NP, Lee WM, Fontana RJ, Bonkovsky HL, Watkins PB, et al. (DILIN). Hepatic histological findings in suspected drug-induced liver injury: systematic evaluation and clinical associations. *Hepatology.* 2014;59:661–70.
- Kurt F, Raj V, Romil S. Drug-induced liver injury. *Arch Pathol Lab Med.* 2015;139:876–87.
- Andrade RJ, Chalasani N, Björnsson ES, Suzuki A, Kullak-Ublick GA, Watkins PB, et al. Drug-induced liver injury. *Nat Rev Dis Primers.* 2019;5(1):1–22.
- Foureau D, Walling T, Maddukuri V, Anderson W, Culbreath K, Kleiner D, et al. Comparative analysis of portal hepatic infiltrating leukocytes in acute drug-induced liver injury, idiopathic autoimmune and viral hepatitis. *Clin Exp Immunol.* 2015;180(1):40–51.
- Yamaguchi O, Kaira K, Kawasaki T, Mouri A, Hashimoto K, Shiono A, et al. Severe hepatotoxicity due to osimertinib after nivolumab therapy in patients with non-small cell lung cancer harboring EGFR mutation. *Thorac Cancer.* 2020;11(4):1045–51.
- Gerussi A, Natalini A, Antonangeli F, Mancuso C, Agostinetto E, Barisani D, et al. Immune-mediated drug-induced liver injury: immunogenetics and experimental models. *Int J Mol Sci.* 2021;22(9):4557.

**How to cite this article:** Cheng Y-L, Chang W-K, Yen H, Peng Y-J, Chang W-C, Chang P-Y. Osimertinib-related liver injury with successful osimertinib rechallenge: A case report. *Thorac Cancer.* 2022;13(15):2271–4. <https://doi.org/10.1111/1759-7714.14556>