

Understanding Retroperitoneal Anatomy for Lateral Approach Spine Surgery

Tokumi Kanemura¹⁾, Kotaro Satake¹⁾, Hiroaki Nakashima¹⁾, Naoki Segi¹⁾, Jun Ouchida¹⁾, Hidetoshi Yamaguchi²⁾ and Shiro Imagama²⁾

1) Department of Orthopedic Surgery, Spine Center, Konan Kosei Hospital, Aichi, Japan

2) Department of Orthopedic Surgery, Nagoya University Graduate School of Medicine, Aichi, Japan

Abstract:

Lateral approach spine surgery provides effective interbody stabilization, and correction and indirect neural decompression with minimal-incision and less invasive surgery compared with conventional open anterior lumbar fusion. It may also avoid the trauma to paraspinal muscles or facet joints found with transforaminal lumbar interbody fusion and posterior lumbar interbody fusion. However, because lateral approach surgery is fundamentally retroperitoneal approach surgery, it carries potential risk to intra- and retroperitoneal structures, as seen in a conventional open anterior approach. There is an innovative lateral approach technique that reveals different anatomical views; however, it requires reconsideration of the traditional surgical anatomy in more detail than a traditional open anterior approach. The retroperitoneum is the compartmentalized space bounded anteriorly by the posterior parietal peritoneum and posteriorly by the transversalis fascia. The retroperitoneum is divided into three compartments by fascial planes: anterior and posterior pararenal spaces and the perirenal space. Lateral approach surgery requires mobilization of the peritoneum and its content and accurate exposure to the posterior pararenal space. The posterior pararenal space is confined anteriorly by the posterior renal fascia, anteromedially by the lateroconal fascia, and posteriorly by the transversalis fascia. The posterior renal fascia, the lateroconal fascia or the peritoneum should be detached from the transversalis fascia and the psoas fascia to allow exposure to the posterior pararenal space. The posterior pararenal space, however, does not allow a clear view and identification of these fasciae as this relationship is variable and the medial extent of the posterior pararenal space varies among patients. Correct anatomical recognition of the retroperitoneum is essential to success in lateral approach surgery. Spine surgeons must be aware that the retroperitoneal membrane and fascia is multilayered and more complex than is commonly understood. Preoperative abdominal images would facilitate more efficient surgical considerations of retroperitoneal membrane and fascia in lateral approach surgery.

Keywords:

Lateral approach spinal surgery, Extreme lateral interbody fusion, Oblique lateral interbody fusion, Retroperitoneum, Renal fascia, Lateroconal fascia, Posterior pararenal space, Transversalis fascia

Spine Surg Relat Res 2017; 1(3): 107-120
dx.doi.org/10.22603/ssrr.1.2017-0008

Lumbar spinal fusion is a common surgical procedure for various spinal disorders¹⁾. Surgical lumbar interbody fusion is an effective treatment option to stabilize the painful moving segment, and may provide indirect decompression of the neural elements, correct deformity, and restore lordosis²⁻⁵⁾. Many lumbar interbody fusion techniques have been developed and popularized, including anterior lumbar interbody fusion (ALIF), posterior lumbar interbody fusion (PLIF) and transforaminal lumbar interbody fusion (TLIF). Each of

these techniques has advantages and disadvantages⁶⁻¹¹⁾.

An anterior approach to the lumbar spine was initially introduced to manage spondylolisthesis and Pott's disease in the 1930s^{12,13)}. ALIF has become a common and widely accepted lumbar fusion technique over the last decade¹⁴⁻¹⁸⁾. Benefits of ALIF approach include access to the disc space, broad surface area for placement of a large structural graft, and the ability to take down the anterior longitudinal ligament, correct intervertebral height, and distract across the

Corresponding author: Tokumi Kanemura, spinesho@vmail.plala.or.jp

Received: January 30, 2017, Accepted: March 31, 2017

Copyright © 2017 The Japanese Society for Spine Surgery and Related Research

disc space to create lordosis^{19,20}. Posterior fixation, including transpedicular screw or translaminar screw supplemented ALIF, significantly improves segmental flexibility and fixation stiffness^{19,21-23}. However, ALIF with posterior instrumented fusion requires two separate approaches (anterior/posterior), which prolongs operative time in a single day or necessitates staging of procedures²⁴. In addition, ALIF has potential approach-related serious risks and complications, including vascular injury, ureteral damage, ileus, and retrograde ejaculation in males²⁵⁻³². Anterior approaches may also involve unfamiliar anatomy for spine surgeons, potentially placing the patient at risk for approach-related complications; therefore, many spine surgeons prefer the assistance of an “access surgeon” to perform the exposure³³.

PLIF has evolved since the initial description of the technique³⁴, with the development of additional autologous and synthetic bone grafting options, more advanced methods of spinal segmental fusion techniques, innovative implants, and the pedicle screw fixation. PLIF is a traditional posterior lumbar approach that many spine surgeons are very familiar with and well-trained in performing. The posterior exposure provides excellent visualization of the nerve roots and allows for neural decompression while maintaining posterior support structures. Furthermore, PLIF also allows for a 360-degree fusion through a single approach^{2,3,8,10,11,35,36}. Traditional open TLIF was first described in 1982³⁷. The main concerns with the PLIF are the extent of neural retraction required, potential nerve root injury, dural tears, and epidural fibrosis. TLIF avoids these complications by providing direct, unilateral access to the intervertebral foraminal space, and reducing direct dissection and surgical trauma to spinal muscles and structural integrity^{20,38-42}. Traditional open PLIF and TLIF have advanced to become mini-open or minimally invasive approaches⁴³.

The posterior approach in PLIF and TLIF, however, is associated with potential risks and complications such as significant iatrogenic paraspinal muscle damage, inadvertent durotomy, and retraction injury of nerve roots causing fibrosis and chronic radiculopathy. It may also be relatively more difficult to correct coronal imbalance and restore lordosis with PLIF/TLIF than ALIF. Furthermore, endplate preparation may be difficult compared to anterior fusion approaches^{20,38,44-47}.

More recently, the lateral trans-psoas approach, termed extreme, direct or lateral lumbar interbody fusion (XLIF[®], Nuvasive; DLIF[®], Medtronic; LLIF), has gained popularity. Initially developed in the late 1990s by Luiz Pimenta as a lateral endoscopic trans-psoas retroperitoneal approach⁴⁸, it was first published in the literature in 2006 by Ozgur et al.⁴⁹. Since then, LLIF has gained exponential acceptance as a minimally invasive option for thoracolumbar fusions. Compared with traditional open anterior access, LLIF allows a less invasive approach corridor and avoidance of great vessels⁴⁸⁻⁵⁰. Oblique lateral interbody fusion (OLIF, Medtronic[®]), another lateral approach surgery, was subsequently introduced as an alternative procedure to a lateral trans-

psoas approach. The OLIF procedure allows for psoas-preserving access via an anterior oblique retroperitoneal approach⁵¹.

These lateral procedures have advantages over the minimally invasive technique, including direct visualization with novel special instruments and light equipment, excellent disc space preparation, and the ability to place larger interbody cages; therefore, resisting subsidence and creating a biomechanically superior environment for bone healing. LLIF also allows disc height and alignment restoration, and decompression of the nerve roots by powerful indirect decompression through the ligamentotaxis created with intact anterior and posterior longitudinal ligament, as these ligaments have a key role in spinal alignment and stabilization^{49,52-54}. Furthermore, the LLIF approach, including lateral release and ligamentotaxis by disc height restoration, is an excellent option for sagittal and coronal deformity correction, especially in lumbar degenerative scoliosis with laterolisthesis⁵⁵⁻⁵⁷. Numerous lateral procedures have been performed worldwide, and variations and technical refinements have been proposed. The procedure has also been extended to a wider range of indications, now including primary and revision surgery for degenerative problems, adult deformity, trauma, and thoracic disc herniation^{52,58-67}.

The most recent advance in lateral approach surgery has received attention for its application to other spinal problems that were not indicated for original LLIF procedures. A lateral approach corpectomy and vertebral reconstruction with a vertebral cage comprising rectangular footplates (X-Core2[®], Nuvasive), which may provide better subsidence resistance, is an effective alternative to conventional approaches for the treatment of trauma and tumor⁶⁸⁻⁷¹. Another advanced lateral approach technique is anterior column realignment (ACR[®], Nuvasive), which provides a solution for sagittal imbalance. ACR involves a deliberate release of the anterior longitudinal ligament (ALL) and placement of hyperlordotic interbody cages at either 20 or 30 degrees of lordosis, which are then fixed to the vertebral body with one or two screws. ACR results in greater segmental correction than achieved with LLIF alone, successfully restores lumbar lordosis in patients with adult spinal deformity with sagittal imbalance⁷²⁻⁷⁶.

However, potential LLIF-related risks include injury to the psoas muscle and the lumbar plexus, and to the nerves that lie within it⁷⁷⁻⁸⁰. Therefore, the procedure requires the use of real-time electromyographic (EMG) monitoring⁸¹. Fundamentally, lateral approach surgery including LLIF, lateral corpectomy, and ACR is retroperitoneal approach surgery. An anterior retroperitoneal approach uses the latent space between the back and psoas muscles and the peritoneal content. As this approach has the potential risk for intraperitoneal or retroperitoneal structures (including viscera and vessels), surgical exposure requires extensive mobilization of the great vessels and the peritoneal content. Traditional ALIF method using a wide-open anterior approach, have largely been abandoned because of significant compli-

Table 1. The Extraperitoneal Spaces.

	Portion of the abdominal wall	Area
Retroperitoneal space =Retroperitoneum	Posteriorly Laterally	Between the parietal peritoneum of the posterior abdominal wall and transversalis fascia
Preperitoneal space (Properitoneal space)	Anteriorly	Between the parietal peritoneum of the anterior abdominal wall and the transversalis fascia.
Subperitoneal pelvic space	Caudally	Under the peritoneum

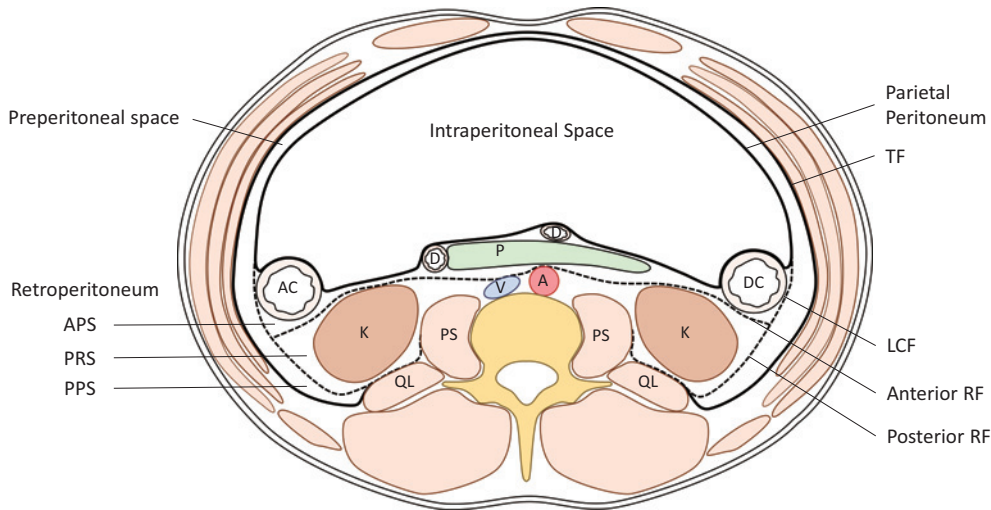


Figure 1. Extraperitoneal space and organs.

TF=transversalis fascia; RF=renal fascia; LCF=lateroconal fascia; PS=psoas muscle; QL=quadratus lumborum muscle; P=pancreas; K=kidney; AC=ascending colon; DC=descending colon; D=duodenum; A=aorta; V=vena cava.

cation rates and the high incidence of pain and abdominal wall herniation after surgery. A lateral approach with specialized instruments should be developed as a less invasive alternative to conventional open ALIF to avoid such complaints. However, one of present author’s major concerns is the limited visualization of the retroperitoneal space and minimized working space. Limited visualization does not warn the surgeon of the presence of viscera and vessels, even at close quarters. Minimized working space makes it more difficult to control vascular or visceral injury if it occurs. Many studies have described complications of lateral approach surgery concerning vascular or visceral injury^{73,76,82-86}, with some complications being catastrophic⁸⁷⁻⁸⁹. As the lateral approach requires mobilization of the peritoneum for exposure to the retroperitoneal space and subsequent lateral access, misunderstanding about the peritoneum and inadequate exposure to the retroperitoneal space increases the risk of injury to the peritoneum and its content. To avoid or manage such complications, surgeons should be aware of potential complications associated with the anterior approach and recognize the importance of a comprehensive understanding of the anatomy of the retroperitoneal space and its content. This article reviews the clinically relevant anatomy of the abdominal retroperitoneal spaces (the retroperitoneum) to facilitate the safe and reliable exposure to the

retroperitoneal space for lateral approach surgery.

Extraperitoneal space

The extraperitoneal space is the space between the parietal peritoneum and the investing fascia of the muscles. It circumferentially surrounds the abdominal cavity; posteriorly and laterally (retroperitoneal space), anteriorly (preperitoneal space), and caudally (subperitoneal pelvic space) (Table 1) (Fig. 1). In the posterior abdominal wall, the extraperitoneal space is called the retroperitoneum, which is confined to the posterior and lateral portion of the abdominal and pelvic wall. The investing fascia of the diaphragm, quadratus lumborum muscle, and the transversus muscle (with or without psoas muscle) is called transversalis fascia (TF). The extraperitoneal space in the anterior abdominal wall is called the preperitoneal space. In the pelvis, the extraperitoneal space is called the subperitoneal pelvic space⁹⁰.

The retroperitoneum

The retroperitoneum is the compartmentalized space bounded anteriorly by the posterior parietal peritoneum and posteriorly by the TF. It extends from the diaphragm superiorly to the pelvic brim inferiorly.

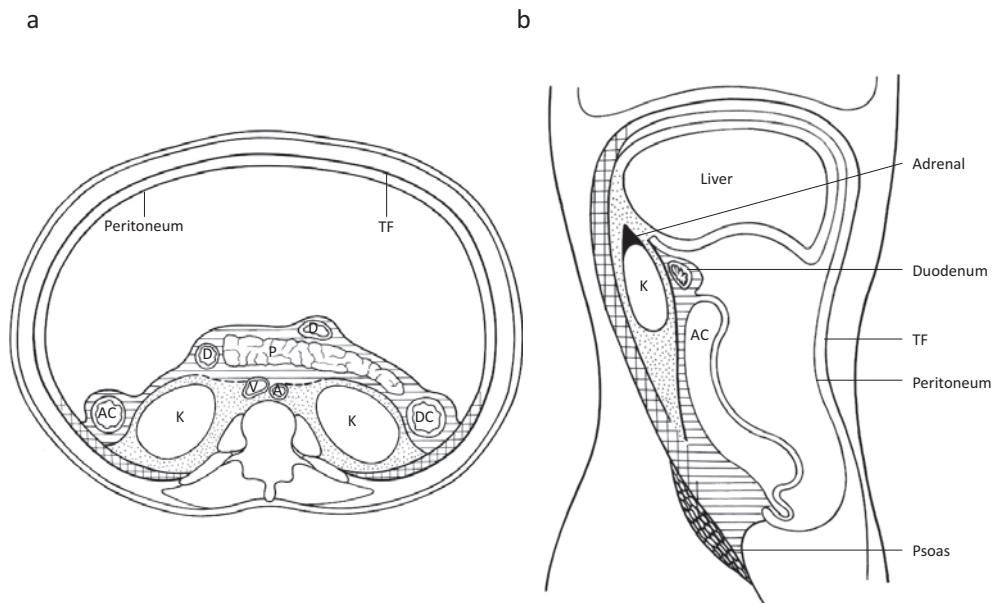


Figure 2. The three extraperitoneal compartments. Striped areas=anterior pararenal space; stippled areas=perirenal space; cross-hatched areas=posterior pararenal space; TF=transversalis fascia; P=pancreas; K=kidney; AC=ascending colon; DC=descending colon; D=duodenum; A=aorta; V=vena cava. Meyers MA, Charnsangavej C, Oliphant M. Meyers’ dynamic radiology of the abdomen: normal and pathologic anatomy. New York: Springer; 2011. xviii, 419 p. p 116; with permission.

Table 2. Three Compartments of Retroperitoneum.

		Boundary	Organs
Anterior pararenal space	APS	Anterior: Posterior parietal peritoneum Posterior: Anterior renal fascia Lateral: Lateroconal fascia	Ascending/descending colon Duodenal loop Pancreas
Perirenal space	PRS	Anterior: Anterior renal fascia (Gerota fascia) Posterior: Posterior renal fascia (Zuckerkindl fascia)	Kidney Renal vessel Adrenal glands Renal pelvis Proximal ureter
Posterior pararenal space	PPS	Anterior: Posterior renal fascia Anteromedial: Lateroconal fascia Posterior: Transversalis fascia Medial: Psoas fascia Superior: Subdiaphragmatic layer Inferior: Open to the pelvis	Fat tissue

Three compartments anatomy of the retroperitoneum

The retroperitoneum is divided by fascial planes into precisely three individual compartments: the anterior and posterior pararenal spaces and the perirenal space⁹¹⁻⁹⁶ (Fig. 2) (Table 2).

Anterior pararenal space (APS)

The APS is confined anteriorly by the posterior parietal peritoneum, and posteriorly the anterior renal fascia (RF). Significantly, it is confined laterally by the lateroconal fascia (LCF). It contains the ascending and descending colon, the duodenal loop, and the pancreas. Ventrally, the APS is anatomically continuous with the roots of the small bowel mes-

entry and transverse mesocolon^{97,98}.

Perirenal space (PRS)

The PRS has the shape of an inverted cone extending from the diaphragmatic fascia to the iliac fossa. It is confined by the anterior RF (Gerota fascia⁹⁹) and posterior RF (Zuckerkindl fascia¹⁰⁰). The PRS contains the kidneys, renal vessels, adrenal glands, renal pelvis, proximal ureters, and its investing fat (perirenal fat).

There is some controversy regarding the medial and inferior extents of the PRS. Historically, it was assumed that the PRS generally had no continuity across the midline^{92,96}. Medially, the posterior fascial layer fuses with the psoas or quadratus lumborum fascia¹⁰¹, and the anterior RF blends

Table 3. Retroperitoneal Fasciae (Abbreviations Used in This Article).

RF	Renal fascia (anterior, posterior)
LCF	Lateral conal fascia
TF	Transversalis fascia
FF	Fusion fascia
TLF	Thoracolumbar fascia

into the dense mass of connective tissue surrounding the great vessels at the root of the mesentery and behind the pancreas and duodenum¹⁰². However, in vivo cases and cadaveric injection studies suggest there may be some communication across the midline below the level of the renal hilum^{103,104}. In addition, there is controversy regarding the patency and caudal extent of the PRS. Previously, it was suggested that the PRS is closed inferiorly by the fusion of RF. However, in vivo cases and cadaveric injection studies demonstrated that the cone-like shape of PRS is open at its inferior extent in the extraperitoneal pelvis^{103,105} (Fig. 2b).

At the level of the iliac crest, below the cone of RF, the anterior and posterior pararenal spaces are in potential communication. At this same level, the LCF disappears as a distinct boundary, and the APS communicates laterally with the preperitoneal fat of the flank stripe. Superiorly, posterior pararenal fat continues as a thin subdiaphragmatic layer of extraperitoneal fat^{91,92,96}.

Posterior pararenal space (PPS)

The PPS is confined anteriorly by the posterior RF, posteriorly by the TF, and medially by the psoas muscle. It continues laterally external to the LCF as the preperitoneal fat of the abdominal wall. Inferiorly, the PPS is open to the pelvis¹⁰⁶. As opposed to the other two extraperitoneal spaces, the PPS contains no organs, and almost always only contains fat. Furthermore, its most notable feature is that it continues uninterrupted external to the LCF as preperitoneal fat on the abdominal wall. It is important to recognize that it is posterior pararenal fat, as it courses laterally external to the LCF and deep to the TF¹⁰⁵. The space is open laterally toward the flank and inferiorly toward the pelvis. Bilaterally, they are potentially in communication only via the preperitoneal fat of the anterior abdominal wall deep to the TF.

Interfascial planes

This traditional three-compartmental anatomy does not provide a complete explanation for the spread of fluid collections or tumors in the retroperitoneum. It is now believed that the retroperitoneal fasciae are multilaminated structures with potentially expandable interfascial planes¹⁰⁷. These planes are represented by the retromesenteric, retrorenal, lateroconal, and combined interfascial planes. Knowledge of the anatomy and interconnections of these interfascial planes can facilitate understanding of the extent and pathways of spread of retroperitoneal disease¹⁰⁸.

Membrane and fasciae

Fascia is fundamental to understanding retroperitoneal anatomy, but is often misunderstood in surgical practice. Definitions of fascia vary between texts and between countries¹⁰⁹. The retroperitoneal fascial planes are multilaminated rather than composed of single membranes. The fasciae are lamina of connective tissue approximately 2 mm thick that form the partitions between retroperitoneum compartments¹¹⁰. A clear concept and definition of fascia is important when approaching the retroperitoneum (Table 3).

Peritoneum

The peritoneum is a thin, translucent, serous membrane. The peritoneum that lines the abdominal wall is called the parietal peritoneum, whereas the peritoneum that covers a viscus or an organ is visceral peritoneum. Both types of peritoneum consist of a single layer of simple low-cuboidal epithelium called a mesothelium. The peritoneal cavity is the potential space between the parietal peritoneum, which lines the abdominal wall, and the visceral peritoneum, which envelops the abdominal organs¹¹¹.

Retroperitoneal fascial development

Derived from the mesoderm, the primitive mesenchyme differentiates to form subcutaneous, body, and retroperitoneal layers. The retroperitoneal layer forms three strata in late fetal development: the outer, intermediate, and inner strata¹¹².

Some orthopedic surgeons interpret the term fascia to always mean the membrane capsuling the myotome. However, this is not true. The retroperitoneal fasciae are not related to the fasciae of the dorsal myotomes. The abdominopelvic fasciae evolve from a continuous layer of retroperitoneal connective tissue. The outer stratum covers the epimysium of the abdominal wall muscles, forms the abdominal and pelvic fascia, and becomes the TF. The intermediate stratum forms the fascia that encloses the urinary tract, and the inner stratum is the connective tissue associated with the coelomic epithelium (peritoneum) itself. This becomes the fascia involved with the intestinal tract¹¹³. These embryologic strata categorize the retroperitoneal fasciae, which compartmentalize the spaces within the retroperitoneum¹¹⁴.

Renal fascia (RF)

The RF is a dense, collagenous, elastic connective tissue sheath that envelops the kidney and perirenal fat. The posterior RF was first described by Zuckerkandl¹⁰⁰ and the anterior RF by Gerota⁹⁹, but both fasciae have since been named Gerota's fascia¹¹⁵. Its two layers fuse behind the ascending or descending colon to form the LCF, which continues around the flank to blend with the peritoneal reflection to form the paracolic gutter. The posterior RF fuses with the psoas or quadratus lumborum fascia at the level of the renal hilum. Further down, it withdraws toward the quadratus lumborum muscle, and fuses with the posterolateral margin

of the psoas muscle at the level of the inferior apex of the cone^{105,116,117}.

Dissection studies have shown the posterior RF is divided into two laminae at a variable point from the kidney¹¹⁷. The thinner anterior leaf extends anteriorly, continuous with the anterior RF. The thicker posterior lamina continues the LCF. The potential space between the two laminae is anatomically continuous with the anterior pararenal space¹¹⁷ (Fig. 3).

Lateroconal fascia (LCF)

Although spine surgeons may not be familiar with this

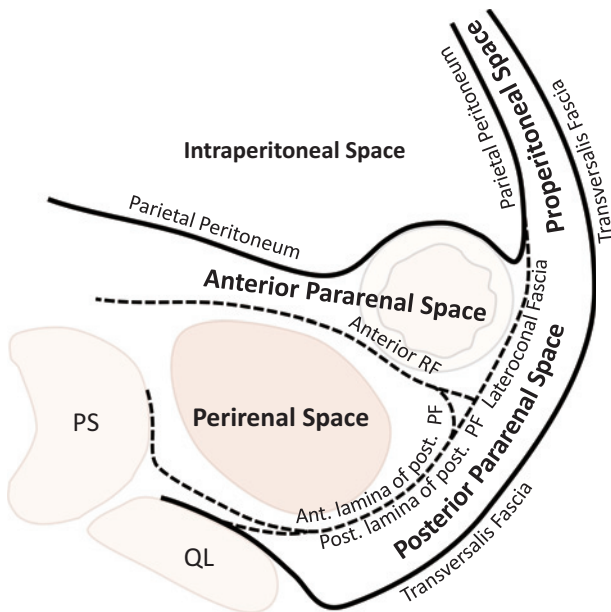


Figure 3. Schema of the retroperitoneal fasciae and spaces. RF=renal fascia; PS=psoas muscle; QL=quadratus lumborum muscle

fascia, the LCF was first described in early the 1900s^{101,118,119}. The anterior and posterior RF merge laterally on each side behind the ascending and descending colon to form the LCF, separating the APS and PPS and continuing antero-laterally deep to the TF^{102,120,121}. This space is occupied by a flat, capsule-like body of fat, similar to the renal adipose capsule in the perirenal space. The term “flank pad” is used for the flat fatty mass between the LCF and TF¹²⁰. However, variations in this fascia in adult specimens have been investigated. The site of blending of the LCF with the RF varies between patients, as well as from side-to-side and from cephalad to caudad, and ranges from a location anterior to one posterior to the kidney¹²¹. LCF variations may explain the uncommon occurrence of the retrorenal colon¹²²⁻¹²⁴ (Fig. 4). Abundant perirenal or pararenal fat is much more common in men than in women, and a lack of this adipose tissue may contribute to the colon lying lateral to, or even behind, the kidney¹²². Caution about retrorenal colon may have practical applications when an invasive retroperitoneal procedure is planned¹²⁵.

Furthermore, the origin of the LCF remains unknown. A recent study of human fetuses at two different developmental stages reported that the LCF did not appear to be a primary structure such as the RF, but a result of secondary mechanical stress due to fatty tissue developing earlier along the TF than in the perirenal space¹²⁵.

Fusional fasciae (FF)

The FF behind the right and left retroperitonealized mesocolon are called the right and left retrocolic fasciae of Toldt^{101,126}. This construct describes a retroperitoneal fascia formed by the fusion of an embryonic mesentery with embryonic retro-peritoneum (Fig. 5). The FF is created during embryogenesis when the inner stratum forms a multilayer

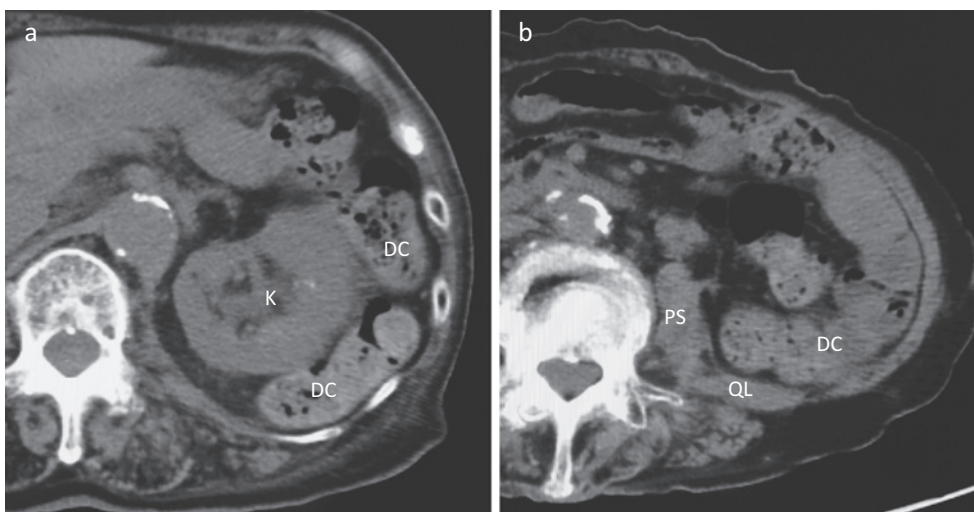


Figure 4. An 82-year-old woman with retrorenal colon. Axial computed tomography images show the descending colon wrapping around the left kidney (a), and extending posteriorly to the quadratus lumborum muscle and medially to the psoas muscles at L3/4 level (b).

K=kidney; DC=descending colon; PS=psoas muscle; QL=quadratus lumborum muscle.

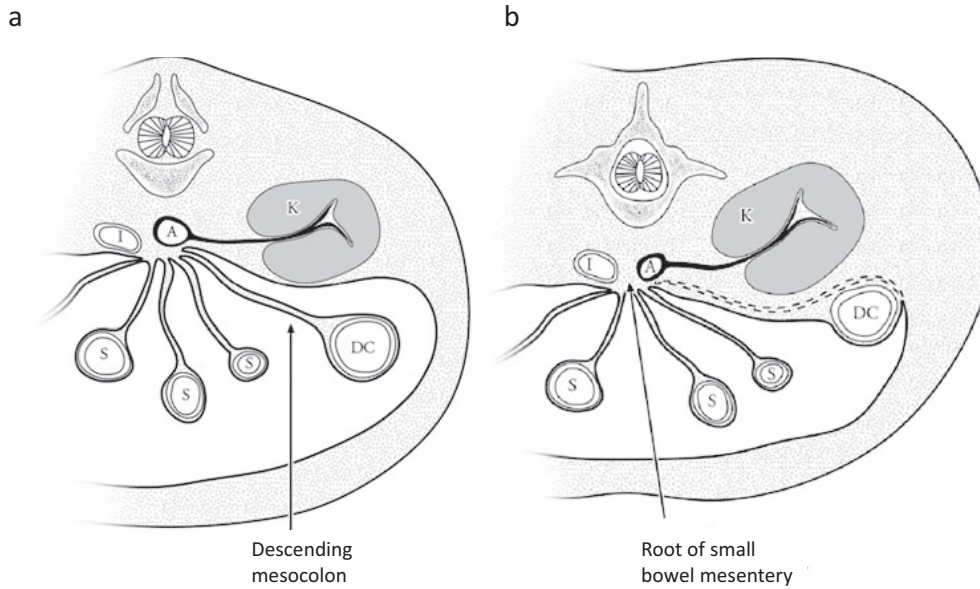


Figure 5. Origin of fusion fascia.

(a) Diagrammatic drawing of transverse section of a 12-week embryo. The colon has returned to the abdomen and is suspended by the dorsal mesentery. DC=descending colon; S=small bowel; A=aorta; I=inferior vena cava; K=kidney. (b) Fusion of the descending mesocolon with posterior parietal peritoneum (dashed lines). Note the subperitoneal region of the mesentery is preserved after fusion allowing continuity of the subperitoneal space.

Meyers MA, Charnsangavej C, Oliphant M. Meyers' dynamic radiology of the abdomen: normal and pathologic anatomy. New York: Springer; 2011. xviii, 419 p. 17; with permission.

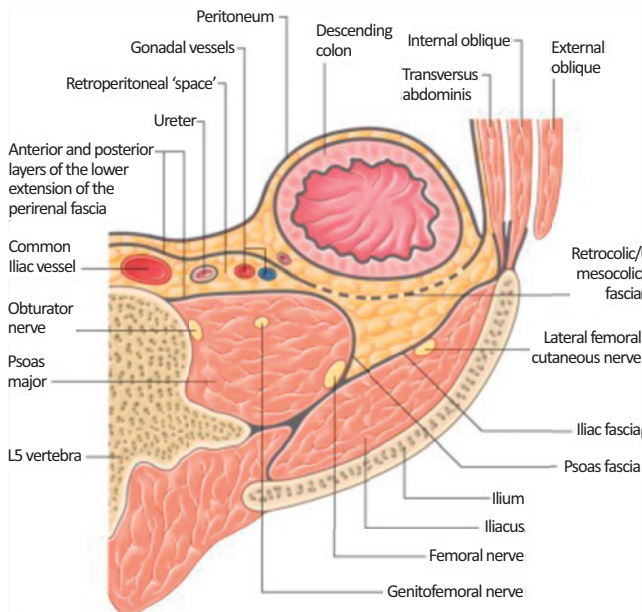


Figure 6. Compartments and fasciae of the lower retroperitoneum.

A transverse section at approximately the L5 vertebral level, showing the location and relationship of the pericolic space. Stranding S. Posterior abdominal wall and retroperitoneum. Forty-first edition. New York: Elsevier Limited; 2016. Gray's anatomy: the anatomical basis of clinical practice; Chapter 62, p. 1083-1097.e2; with permission.

FF with the primary dorsal peritoneum during the rotation and posterior attachment of the gastrointestinal viscera¹¹³. FF consists of thin (0.1-0.6 mm) connective tissue layers, sometimes bilaminar with a separate looser stratum¹⁰⁵.

Clinically, the white line of Toldt is a significant landmark for digestive surgery because it can be developed to mobilize the colon after incising along the line of Toldt. It is an avascular layer that allows a dissection plane to be developed, and limits the spread of disease. The FF is also clinically significant for spine surgeons because it immobilizes the ascending or descending colon to the lateral or posterior aspect of the abdominal cavity, which lies anterior to the anterior RF or LCF (Fig. 6)¹²⁷. Therefore, recognition of the ascending or descending colon position should always be considered in strategic retroperitoneal procedures.

Transversalis fascia (TF)

The outer stratum forms the TF, which lies deep to the transversus abdominis muscle and superficial to the preperitoneal fat and peritoneum. The TF is posterior to the kidney, and anterior to the fascia surrounding the quadratus lumborum. Some texts include the fascia of the psoas muscle with the TF¹²⁸. The TF may fuse medially with the posterior lamina of the posterior RF. This fusion creates the medial boundary of the posterior pararenal space^{112,114}.

Thoracolumbar fascia (TLF)

The TLF is a girdling structure comprising a complex arrangement of several aponeurotic and multiple fascial layers

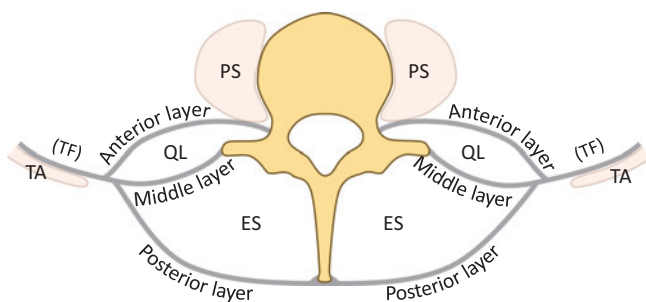


Figure 7. Laminae of the thoracolumbar fascia in the lumbar region.

The thoracolumbar fascia is composed of three distinct layers: posterior, middle, and anterior layers. Two compartments are delineated: the osteofibrous compartment for the erector spinae muscle, and the fascial compartment for the quadratus lumborum muscle.

PS=psoas muscle; QL=quadratus lumborum muscle; ES=erector spinae muscle; TA=transversus abdominis muscle; TF=transversalis fascia.

that separate the paraspinous muscles from the muscles of the posterior abdominal wall. In the lumbar region, the TLF is composed of three distinct layers: posterior, middle and anterior layers (Fig. 7). The posterior layer originates medially from the tip of the spinous processes of the lumbar vertebrae and the supraspinous ligament; a superficial lamina is the aponeurosis of the latissimus dorsi, and a deep lamina covers the posterior surface of the paraspinous muscles. The middle layer is attached to the tips of the transverse processes of the lumbar vertebrae and extends laterally behind the quadratus lumborum. The anterior layer covers the anterior surface of the quadratus lumborum and is attached medially to the transverse processes of the lumbar vertebrae behind psoas major. Superiorly, it is attached to the inferior border of the twelfth rib and extends to the transverse process of the first lumbar vertebra, forming the lateral arcuate ligament of the diaphragm⁽¹⁰⁹⁾. These three layers merge into one as they travel laterally. A common access point for the retroperitoneum is near the tip of the 12th rib, where layers merge. This single TLF layer anterolaterally merges with the aponeurosis of the transversus abdominis muscle⁽¹¹⁴⁾. The retroperitoneum can be entered from this point without incising muscle, which is an entry point for the conventional open anterior approach.

Psoas fascia

A relatively dense fascia layer covers the anterior surface of psoas major and psoas minor. The psoas fascia merges above with the medial arcuate ligament of the diaphragm and laterally with the TF⁽¹¹³⁾. Some texts include the psoas fascia with the TF⁽¹²⁸⁾. For spine surgeons, when mobilizing the abdominal, anterior pararenal, and perirenal cavities to expose the PPS, it is significant that the psoas fascia and the anterior layer of the TF fuses with the posterior RF.

Safe and reliable exposure to retroperitoneal space for lateral surgery

In contrast to the descriptions of the RF published by Gerota and Zuckerkandl over 100 years ago and that of the LCF published in 1920s, some of the surgical anatomy around the retroperitoneum remains controversial. The surgical interpretation of the retroperitoneum including the RF and LCF has changed over the years. Some of these changes can be observed in textbooks and manuscripts. This suggests that difficulty in discrimination result in misinterpretation of the laminar configurations during surgery. Laparoscopic urologic surgeons have emphasized a correct understanding of the LCF in the lateral aspect of the kidney^(129,130). However, the LCF remains unknown to many surgeons, especially spine surgeons, unfamiliar with older orthopedic or spinal surgery textbooks. As a result, most spine surgeons have a misunderstanding that the retroperitoneum is the compartmentalized space bounded anteriorly by only one membrane (namely the peritoneum) in any anterior aspect. Knowledge of the complex anatomy of the entities lying between the posterior abdominal wall and peritoneum, and recognition of common variations and their potential implications are crucial for successful surgery using a retroperitoneal approach.

Because lateral approach surgery is fundamentally retroperitoneal approach surgery, XLIF (DLIF) and OLIF can be considered as closely resembling the technique. However, there is a substantial difference between the two techniques regarding the first process of exposing the retroperitoneal space. The original OLIF technique use an antero-lateral approach similar to the conventional open anterior approach, in which the first process in exposing the retroperitoneal space to the preperitoneal space is confined between the parietal peritoneum of the anterior abdominal wall and the TF, including preperitoneal fat. Conversely, XLIF technique is true lateral or postero-lateral approach, in which the first process of exposing the retroperitoneal space to the PPS is confined between the posterior RF anteriorly and the TF posteriorly (Fig. 8). However, the anterior aspect of PPS is complex and diverse, including the posterior RF, the LCF, and the peritoneum. Furthermore, it is clinically significant for spine surgeons that the FF fuse the ascending or descending colon to the lateral or posterior aspect of the abdominal cavity, which lies closely anterior to the anterior RF or the LCF. This suggests that injury of the peritoneum or the fasciae in the first process of the exposure to the retroperitoneal space has a higher possibility of being injury to the ascending or descending colon in a true lateral approach than in an antero-lateral or conventional open anterior approach.

In the second LLIF process, mobilization of the peritoneum and its content or retroperitoneal content anteriorly is required to expose the PPS and allow subsequent lateral access. To provide this mobilization, the posterior RF and the LCF or the peritoneum should be detached from the TF and the psoas fascia, and extended into the immediate anterior side of the psoas. Understanding of the anatomical structures

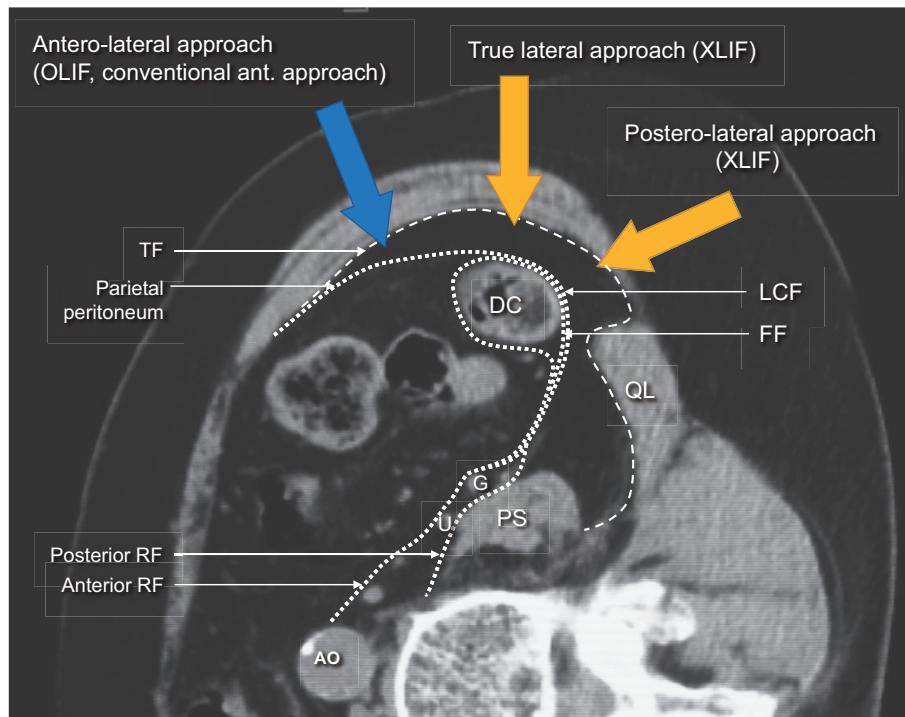


Figure 8. Lateral lumbar interbody fusion approaches.

A substantial difference exists between these two techniques (OLIF and XLIF) in terms of the first process of exposing the retroperitoneal space.

DC=descending colon; PS=psoas muscle; QL=quadratus lumborum muscle; AO=aorta; G=gonadal vessels; U=Ureter; RF=renal fascia; LCF=lateroconal fascia; TF=transversalis fascia; FF=fusion fascia.

in the retroperitoneum, especially retroperitoneal fasciae, has recently advanced with the development of image diagnosis and innovative surgical techniques. The posterior RF fuses with the psoas fascia and the TF, and the thicker posterior lamina of the RF becomes the LCF laterally (Fig. 3). However, such a clear view and identification of the membrane and fasciae cannot be observed in the PPS during actual surgery (Fig. 9). This suggests that correct anatomical recognition of the posterior RF and the LCF during operation is sometimes difficult. In addition, the pararenal space contains connective tissue fibers similar to the perirenal space¹²⁹. Therefore, clear anatomic assessment and identification of the pathway for exposure to the PPS in preoperative images is beneficial, and gentle and meticulous surgical detachment of the posterior RF, LCF, or the peritoneum from the TF and the psoas fascia is essential for safe and reliable lateral approach surgery. An alternative technique when there is no clear identification of the peritoneum and fasciae during surgery is the detachment of the psoas fascia and the fascia of the quadratus lumborum muscle from its own myotome, and mobilization of the peritoneum, the posterior RF, LCF, the psoas and quadratus lumborum fascia as one membrane.

The FF, resulting from adherence of the peritoneum of the colonic mesentery with the primary posterior peritoneum, consists of thin (0.1-0.6 mm) connective tissue layers¹⁰⁵. They lie anterior to the anterior RF or LCF, which are also thin layers. The normal thickness of these fascial planes is

1-2 mm¹⁰⁵. This means the distance between the posterior or lateral aspect of the ascending or descending colon and the anterior wall of the PPS (including the peritoneum, posterior RF and LCF) is less than 2 mm. Although the thickness of this fascia plane varies because of containing connective tissue fibers and fat tissue, this fascia plane is less thin than commonly identified by many spinal surgeons during surgery. We evaluated intraoperative 3D-images immediately after LLIF, and found that 30% of patients showed a dangerously thin margin (less than 1 mm) between the posterior surface of the colon and the exposed PPS¹³¹ (Fig. 10). These patients have a high possibility of colonic perforation during exposure to the PPS and the entire LLIF procedure after the setting of the retractor. To avoid colonic perforation during LLIF, anatomic assessment of the descending and ascending colon using preoperative abdominal computed tomography scans (e.g., the distance between the descending or ascending colon and the anterior margin of the quadratus lumborum muscle or amount of fat tissue in the PPS) is essential. Although special instruments and light equipment used in recent novel LLIF surgery are used for minimal-incision surgery as a less invasive alternative to conventional open ALIF, the most important factor is the safe and reliable creation of a spacious cavity in the retroperitoneum by entry along the correct planes.

In conclusion

Lateral approach spine surgery can provide effective interbody stabilization and correction, and indirect neural decompression with minimal-incision and less invasive surgery compared with conventional open ALIF. It may also avert the trauma to paraspinal muscles or facet joints found in TLIF and PLIF. However, because lateral approach surgery is fundamentally retroperitoneal approach surgery, there is potential risk to intra- and retroperitoneal structures (including viscera and vessels) as seen with a conventional open anterior approach. Minimal-incision and less invasive lateral surgery may be a trade-off with the limited visualization of the retroperitoneal space and minimized working space. An innovative lateral approach technique has demonstrated different anatomical views, but requires reconsideration of the traditional surgical anatomy in more detail than a traditional open anterior approach. Correct anatomical recognition for the retroperitoneum is essential to success in lateral approach surgery. It must be clear to the spine surgeon that the retroperitoneal membrane and fascia are more multilayered and complex than commonly understood. Therefore, preoperative abdominal images will support more efficient surgical consideration about the retroperitoneal membrane and fascia in lateral approach surgery. Such anatomical knowledge is also useful in a conventional open approach.

Conflicts of Interest: Tokumi Kanemura has served as a consultant to NuVasive and Medtronic. Other authors declare that there are no conflicts of interest.

Sources of funding: none

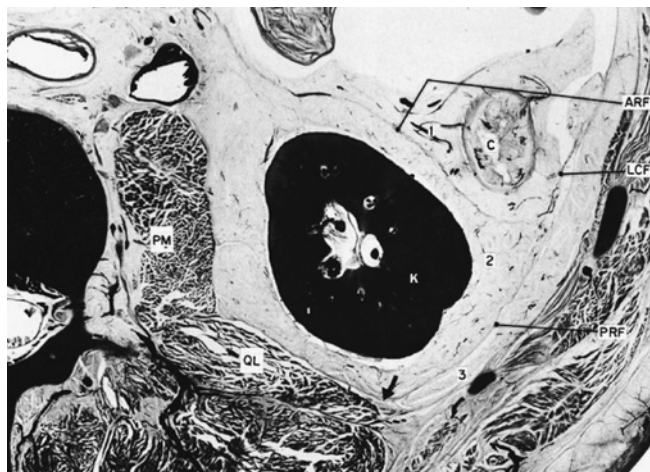


Figure 9. An anatomic cross-section below midlevel of the left kidney.

The anatomic cross-section shows the termination of the posterior renal fascia in relationship to the fascia of the quadratus lumborum muscle (arrow). A clear view and identification of these fasciae could not be observed at the posterior pararenal space because this relationship is variable and the medial extent of the posterior pararenal space varies from patient to patient.

K=kidney; PM=psoas muscle; C=descending colon; ARF=anterior renal fascia; LCF=lateroconal fascia; PRF=posterior renal fascia; 1=anterior pararenal space; 2=perirenal space; 3=posterior pararenal space.

Meyers MA, Charnsangavej C, Oliphant M. Meyers' dynamic radiology of the abdomen: normal and pathologic anatomy. New York: Springer; 2011. xviii, 419 p. 124; with permission.

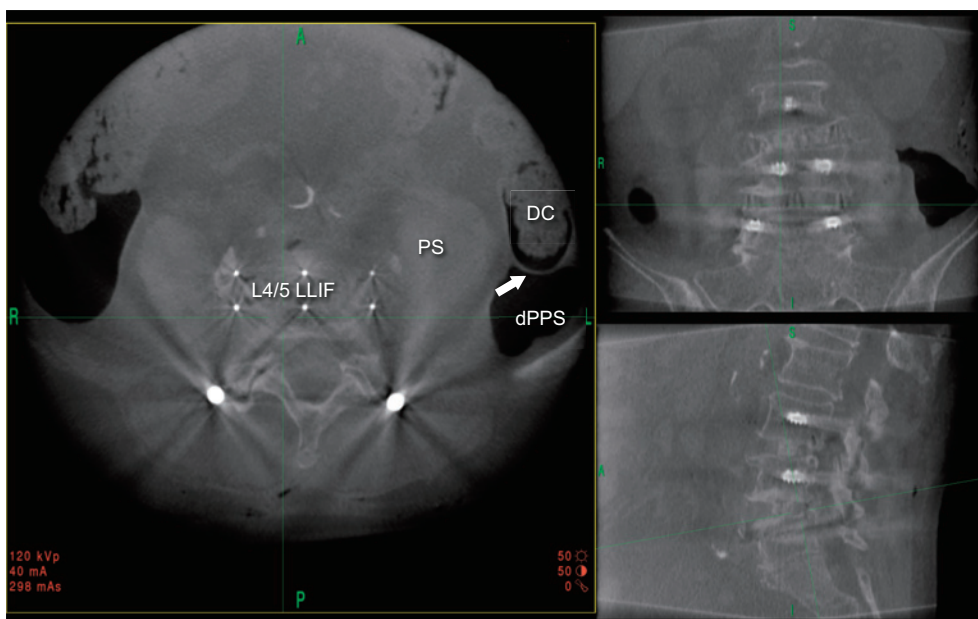


Figure 10. Intraoperative three-dimensional (3D) images immediately after lateral lumbar interbody fusion (LLIF).

The intraoperative 3D-images in a prone position immediately after LLIF (L4/5) showed a dangerously thin margin (less than 1 mm, white arrow) between the posterior or lateral surface of the colon and the developed posterior pararenal space.

DC=descending colon; dPPS=developed posterior pararenal space by LLIF procedure; PS=psoas muscle.

References

1. Fraser RD. Interbody, posterior, and combined lumbar fusions. *Spine (Phila Pa 1976)*. 1995;20(24 Suppl):167s-77s. eng.
2. McAfee PC. Interbody fusion cages in reconstructive operations on the spine. *J Bone Joint Surg Am*. 1999;81(6):859-80.
3. Zdeblick TA, Phillips FM. Interbody cage devices. *Spine (Phila Pa 1976)*. 2003;28(15 Suppl):S2-7.
4. Li J, Dumonski ML, Liu Q, et al. A multicenter study to evaluate the safety and efficacy of a stand-alone anterior carbon I/F Cage for anterior lumbar interbody fusion: two-year results from a Food and Drug Administration investigational device exemption clinical trial. *Spine (Phila Pa 1976)*. 2010;35(26):E1564-70.
5. Winder MJ, Gambhir S. Comparison of ALIF vs. XLIF for L4/5 interbody fusion: pros, cons, and literature review. *J Spine Surg*. 2016;2(1):2-8. eng.
6. Cloward RB. Posterior lumbar interbody fusion updated. *Clin Orthop Relat Res*. 1985(193):16-9.
7. Penta M, Fraser RD. Anterior lumbar interbody fusion. A minimum 10-year follow-up. *Spine (Phila Pa 1976)*. 1997;22(20):2429-34.
8. Harms JG, Joeszszky D. Die posteriore, lumbale, interkorporelle Fusion in unilateraler transforaminaler Technik. *Oper Orthop Traumatol*. 1998;10(2):90-102. ger.
9. Kang BU, Choi WC, Lee SH, et al. An analysis of general surgery-related complications in a series of 412 minilaparotomic anterior lumbosacral procedures. *J Neurosurg Spine*. 2009;10(1):60-5. eng.
10. Brantigan JW, Steffee AD, Lewis ML, et al. Lumbar interbody fusion using the Brantigan I/F cage for posterior lumbar interbody fusion and the variable pedicle screw placement system: two-year results from a Food and Drug Administration investigational device exemption clinical trial. *Spine (Phila Pa 1976)*. 2000;25(11):1437-46.
11. Christensen FB, Hansen ES, Eiskjaer SP, et al. Circumferential lumbar spinal fusion with Brantigan cage versus posterolateral fusion with titanium Cotrel-Dubouset instrumentation: a prospective, randomized clinical study of 146 patients. *Spine (Phila Pa 1976)*. 2002;27(23):2674-83.
12. Capener N. Spondylolisthesis. *Br J Surg*. 1932;19(75):374-86.
13. Ito H, Tsuchiya J, Asami G. A new radical operation for Pott's disease. *The J Bone Joint Surg Am*. 1934;16(3):499.
14. Stauffer RN, Coventry MB. Anterior interbody lumbar spine fusion. Analysis of Mayo Clinic series. *J Bone Joint Surg Am*. 1972;54(4):756-68.
15. Chow SP, Leong JC, Ma A, et al. Anterior spinal fusion or de-ranged lumbar intervertebral disc. *Spine (Phila Pa 1976)*. 1980;5(5):452-8.
16. Fujimaki A, Crock HV, Bedbrook GM. The results of 150 anterior lumbar interbody fusion operations performed by two surgeons in Australia. *Clin Orthop Relat Res*. 1982(165):164-7.
17. O'Brien JP, Dawson MH, Heard CW, et al. Simultaneous combined anterior and posterior fusion. A surgical solution for failed spinal surgery with a brief review of the first 150 patients. *Clin Orthop Relat Res*. 1986(203):191-5.
18. Kozak JA, Heilman AE, O'Brien JP. Anterior lumbar fusion options. Technique and graft materials. *Clin Orthop Relat Res*. 1994(300):45-51.
19. Pavlov PW, Meijers H, van Limbeek J, et al. Good outcome and restoration of lordosis after anterior lumbar interbody fusion with additional posterior fixation. *Spine (Phila Pa 1976)*. 2004;29(17):1893-9;discussion 900.
20. Hsieh PC, Koski TR, O'Shaughnessy BA, et al. Anterior lumbar interbody fusion in comparison with transforaminal lumbar interbody fusion: implications for the restoration of foraminal height, local disc angle, lumbar lordosis, and sagittal balance. *J Neurosurg Spine*. 2007;7(4):379-86.
21. Gerber M, Crawford NR, Chamberlain RH, et al. Biomechanical assessment of anterior lumbar interbody fusion with an anterior lumbosacral fixation screw-plate: comparison to stand-alone anterior lumbar interbody fusion and anterior lumbar interbody fusion with pedicle screws in an unstable human cadaver model. *Spine (Phila Pa 1976)*. 2006;31(7):762-8.
22. Liljenqvist U, O'Brien JP, Renton P. Simultaneous combined anterior and posterior lumbar fusion with femoral cortical allograft. *Eur Spine J*. 1998;7(2):125-31.
23. Zou X, Li H, Teng X, et al. Pedicle screw fixation enhances anterior lumbar interbody fusion with porous tantalum cages: an experimental study in pigs. *Spine (Phila Pa 1976)*. 2005;30(14):E392-9.
24. Fritzell P, Hagg O, Wessberg P, et al. Chronic low back pain and fusion: a comparison of three surgical techniques: a prospective multicenter randomized study from the Swedish lumbar spine study group. *Spine (Phila Pa 1976)*. 2002;27(11):1131-41.
25. Baker JK, Reardon PR, Reardon MJ, et al. Vascular injury in anterior lumbar surgery. *Spine (Phila Pa 1976)*. 1993;18(15):2227-30.
26. Faciszewski T, Winter RB, Lonstein JE, et al. The surgical and medical perioperative complications of anterior spinal fusion surgery in the thoracic and lumbar spine in adults. A review of 1223 procedures. *Spine (Phila Pa 1976)*. 1995;20(14):1592-9.
27. Nourian AA, Cunningham CM, Bagheri A, et al. Effect of Anatomic Variability and Level of Approach on Perioperative Vascular Complications With Anterior Lumbar Interbody Fusion. *Spine (Phila Pa 1976)*. 2016;41(2):E73-7.
28. Quraishi NA, Konig M, Booker SJ, et al. Access related complications in anterior lumbar surgery performed by spinal surgeons. *Eur Spine J*. 2013;22 Suppl 1:S16-20.
29. Rajaraman V, Vingan R, Roth P, et al. Visceral and vascular complications resulting from anterior lumbar interbody fusion. *J Neurosurg*. 1999;91(1 Suppl):60-4. eng.
30. Sasso RC, Best NM, Mummaneni PV, et al. Analysis of operative complications in a series of 471 anterior lumbar interbody fusion procedures. *Spine (Phila Pa 1976)*. 2005;30(6):670-4.
31. Sasso RC, Kenneth Burkus J, LeHuec JC. Retrograde ejaculation after anterior lumbar interbody fusion: transperitoneal versus retroperitoneal exposure. *Spine (Phila Pa 1976)*. 2003;28(10):1023-6.
32. Schizas C, Foko'o N, Matter M, et al. Lymphocele: a rare and little known complication of anterior lumbar surgery. *Eur Spine J*. 2009;18 Suppl 2:228-31.
33. Phan KMD, Xu J, Scherman DBB, et al. Anterior lumbar interbody fusion (ALIF) with and without an "Access Surgeon": A systematic review and meta-analysis. *Spine (Phila Pa 1976)*. 2017.
34. Briggs H, Milligan PR. Chip fusion of the low back following exploration of the spinal canal. *J Bone Joint Surg Am*. 1944;26(1):125-30.
35. Mobbs RJ, Phan K, Malham G, et al. Lumbar interbody fusion: techniques, indications and comparison of interbody fusion options including PLIF, TLIF, MI-TLIF, OLIF/ATP, LLIF and ALIF. *J Spine Surg*. 2015;1(1):2-18. eng.
36. Brantigan JW, Neidre A, Toohey JS. The Lumbar I/F Cage for posterior lumbar interbody fusion with the variable screw placement system: 10-year results of a Food and Drug Administration

- clinical trial. *Spine J.* 2004;4(6):681-8.
37. Harms J, Rolinger H. [A one-stager procedure in operative treatment of spondylolistheses: dorsal traction-reposition and anterior fusion (author's transl)]. *Z Orthop Ihre Grenzgeb.* 1982;120(3):343-7. ger.
 38. Humphreys SC, Hodges SD, Patwardhan AG, et al. Comparison of posterior and transforaminal approaches to lumbar interbody fusion. *Spine (Phila Pa 1976).* 2001;26(5):567-71.
 39. Lowe TG, Tahernia AD, O'Brien MF, et al. Unilateral transforaminal posterior lumbar interbody fusion (TLIF): indications, technique, and 2-year results. *J Spinal Disord Tech.* 2002;15(1):31-8.
 40. Moskowitz A. Transforaminal lumbar interbody fusion. *Orthop Clin North Am.* 2002;33(2):359-66.
 41. Phan K, Thayaparan GK, Mobbs RJ. Anterior lumbar interbody fusion versus transforaminal lumbar interbody fusion--systematic review and meta-analysis. *Br J Neurosurg.* 2015;29(5):705-11.
 42. Rosenberg WS, Mummaneni PV. Transforaminal lumbar interbody fusion: technique, complications, and early results. *Neurosurgery.* 2001;48(3):569-74;discussion 74-5.
 43. Foley KT, Holly LT, Schwender JD. Minimally invasive lumbar fusion. *Spine (Phila Pa 1976).* 2003;28(15 Suppl):S26-35.
 44. McAfee PC, DeVine JG, Chaput CD, et al. The indications for interbody fusion cages in the treatment of spondylolisthesis: analysis of 120 cases. *Spine (Phila Pa 1976).* 2005;30(6 Suppl):S60-5.
 45. Okuda S, Miyauchi A, Oda T, et al. Surgical complications of posterior lumbar interbody fusion with total facetectomy in 251 patients. *J Neurosurg Spine.* 2006;4(4):304-9.
 46. Park Y, Ha JW. Comparison of one-level posterior lumbar interbody fusion performed with a minimally invasive approach or a traditional open approach. *Spine (Phila Pa 1976).* 2007;32(5):537-43.
 47. Salerni AA. A minimally invasive approach for posterior lumbar interbody fusion. *Neurosurgical focus.* 2002;13(6):e6.
 48. Pimenta L. Lateral endoscopic transpoas retroperitoneal approach for lumbar spine surgery.. VIII Brazilian Spine Society Meeting. 2001.
 49. Ozgur BM, Aryan HE, Pimenta L, et al. Extreme Lateral Interbody Fusion (XLIF): a novel surgical technique for anterior lumbar interbody fusion. *Spine J.* 2006;6(4):435-43.
 50. Berjano P, Lamartina C. Minimally invasive lateral transpoas approach with advanced neurophysiologic monitoring for lumbar interbody fusion. *Eur Spine J.* 2011;20(9):1584-6.
 51. Fujibayashi S, Hynes RA, Otsuki B, et al. Effect of indirect neural decompression through oblique lateral interbody fusion for degenerative lumbar disease. *Spine (Phila Pa 1976).* 2015;40(3):E175-82.
 52. Elowitz EH, Yanni DS, Chwajol M, et al. Evaluation of indirect decompression of the lumbar spinal canal following minimally invasive lateral transpoas interbody fusion: radiographic and outcome analysis. *Minim Invasive Neurosurg.* 2011;54(5-6):201-6.
 53. Oliveira L, Marchi L, Coutinho E, et al. A radiographic assessment of the ability of the extreme lateral interbody fusion procedure to indirectly decompress the neural elements. *Spine (Phila Pa 1976).* 2010;35(26 Suppl):S331-7.
 54. Youssef JA, McAfee PC, Patty CA, et al. Minimally invasive surgery: lateral approach interbody fusion: results and review. *Spine (Phila Pa 1976).* 2010;35(26 Suppl):S302-11.
 55. Isaacs RE, Hyde J, Goodrich JA, et al. A prospective, nonrandomized, multicenter evaluation of extreme lateral interbody fusion for the treatment of adult degenerative scoliosis: perioperative outcomes and complications. *Spine (Phila Pa 1976).* 2010;35(26 Suppl):S322-30.
 56. Acosta FL, Liu J, Slimack N, et al. Changes in coronal and sagittal plane alignment following minimally invasive direct lateral interbody fusion for the treatment of degenerative lumbar disease in adults: a radiographic study. *J Neurosurg Spine.* 2011;15(1):92-6.
 57. Berjano P, Lamartina C. Far lateral approaches (XLIF) in adult scoliosis. *Eur Spine J.* 2013;22 Suppl 2:S242-53.
 58. Castellvi AE, Nienke TW, Marulanda GA, et al. Indirect decompression of lumbar stenosis with transpoas interbody cages and percutaneous posterior instrumentation. *Clin Orthop Relat Res.* 2014;472(6):1784-91.
 59. Sato J, Ohtori S, Orita S, et al. Radiographic evaluation of indirect decompression of mini-open anterior retroperitoneal lumbar interbody fusion: oblique lateral interbody fusion for degenerated lumbar spondylolisthesis. *Eur Spine J.* 2015. eng.
 60. Phillips FM, Isaacs RE, Rodgers WB, et al. Adult degenerative scoliosis treated with XLIF: clinical and radiographical results of a prospective multicenter study with 24-month follow-up. *Spine (Phila Pa 1976).* 2013;38(21):1853-61.
 61. Baghdadi YM, Larson AN, Dekutoski MB, et al. Sagittal balance and spinopelvic parameters after lateral lumbar interbody fusion for degenerative scoliosis: a case-control study. *Spine (Phila Pa 1976).* 2014;39(3):E166-73.
 62. Strom RG, Bae J, Mizutani J, et al. Lateral interbody fusion combined with open posterior surgery for adult spinal deformity. *J Neurosurg Spine.* 2016:1-9.
 63. Theologis AA, Mundis GM, Jr., Nguyen S, et al. Utility of multilevel lateral interbody fusion of the thoracolumbar coronal curve apex in adult deformity surgery in combination with open posterior instrumentation and L5-S1 interbody fusion: a case-matched evaluation of 32 patients. *J Neurosurg Spine.* 2016:1-12. eng.
 64. Alimi M, Hofstetter CP, Cong GT, et al. Radiological and clinical outcomes following extreme lateral interbody fusion. *J Neurosurg Spine.* 2014;20(6):623-35. eng.
 65. Formica M, Berjano P, Cavagnaro L, et al. Extreme lateral approach to the spine in degenerative and post traumatic lumbar diseases: selection process, results and complications. *Eur Spine J.* 2014;23 Suppl 6:684-92. eng.
 66. Tohmeh AG, Khorsand D, Watson B, et al. Radiographical and clinical evaluation of extreme lateral interbody fusion: effects of cage size and instrumentation type with a minimum of 1-year follow-up. *Spine (Phila Pa 1976).* 2014;39(26):E1582-91. eng.
 67. Serak J, Vanni S, Levi AD. The extreme lateral approach for treatment of thoracic and lumbar vertebral body metastases. *J Neurosurg Sci.* 2015. eng.
 68. Smith WD, Dakwar E, Le TV, et al. Minimally invasive surgery for traumatic spinal pathologies: a mini-open, lateral approach in the thoracic and lumbar spine. *Spine (Phila Pa 1976).* 2010;35(26 Suppl):S338-46.
 69. Uribe JS, Dakwar E, Le TV, et al. Minimally invasive surgery treatment for thoracic spine tumor removal: a mini-open, lateral approach. *Spine (Phila Pa 1976).* 2010;35(26 Suppl):S347-54.
 70. Pekmezci M, McDonald E, Kennedy A, et al. Can a novel rectangular footplate provide higher resistance to subsidence than circular footplates? An ex vivo biomechanical study. *Spine (Phila Pa 1976).* 2012;37(19):E1177-81.
 71. Theologis AA, Tabaraee E, Toogood P, et al. Anterior corpectomy via the mini-open, extreme lateral, transpoas approach

- combined with short-segment posterior fixation for single-level traumatic lumbar burst fractures: analysis of health-related quality of life outcomes and patient satisfaction. *J Neurosurg Spine*. 2016;24(1):60-8. eng.
72. Uribe JS, Smith DA, Dakwar E, et al. Lordosis restoration after anterior longitudinal ligament release and placement of lateral hyperlordotic interbody cages during the minimally invasive lateral transposas approach: a radiographic study in cadavers. *J Neurosurg Spine*. 2012;17(5):476-85.
 73. Berjano P, Cecchinato R, Sinigaglia A, et al. Anterior column realignment from a lateral approach for the treatment of severe sagittal imbalance: a retrospective radiographic study. *Eur Spine J*. 2015;24 Suppl 3:433-8. eng.
 74. Pimenta L, Forti F, Oliveira L, et al. Anterior column realignment following lateral interbody fusion for sagittal deformity correction. *Eur J Orthop Surg Traumatol*. 2015;25 Suppl 1:S29-33. eng.
 75. Turner JD, Akbarnia BA, Eastlack RK, et al. Radiographic outcomes of anterior column realignment for adult sagittal plane deformity: a multicenter analysis. *Eur Spine J*. 2015;24 Suppl 3: 427-32.
 76. Saigal R, Mundis GM, Jr., Eastlack R, et al. Anterior Column Realignment (ACR) in Adult Sagittal Deformity Correction: Technique and Review of the Literature. *Spine (Phila Pa 1976)*. 2016;41 Suppl 8:S66-73.
 77. Kepler CK, Bogner EA, Herzog RJ, et al. Anatomy of the psoas muscle and lumbar plexus with respect to the surgical approach for lateral transposas interbody fusion. *Eur Spine J*. 2011;20(4): 550-6.
 78. Le TV, Burkett CJ, Deukmedjian AR, et al. Postoperative lumbar plexus injury after lumbar retroperitoneal transposas minimally invasive lateral interbody fusion. *Spine (Phila Pa 1976)*. 2013;38 (1):E13-20. eng.
 79. Gammal ID, Spivak JM, Bendo JA. Systematic Review of Thigh Symptoms after Lateral Transposas Interbody Fusion for Adult Patients with Degenerative Lumbar Spine Disease. *Int J Spine Surg*. 2015;9:62. eng.
 80. Beckman JM, Vincent B, Park MS, et al. Contralateral psoas hematoma after minimally invasive, lateral retroperitoneal transposas lumbar interbody fusion: a multicenter review of 3950 lumbar levels. *J Neurosurg Spine*. 2017;26(1):50-4. eng.
 81. Tohmeh AG, Rodgers WB, Peterson MD. Dynamically evoked, discrete-threshold electromyography in the extreme lateral interbody fusion approach. *J Neurosurg Spine*. 2011;14(1):31-7.
 82. Tormenti MJ, Maserati MB, Bonfield CM, et al. Complications and radiographic correction in adult scoliosis following combined transposas extreme lateral interbody fusion and posterior pedicle screw instrumentation. *Neurosurg Focus*. 2010;28(3):E7.
 83. Uribe JS, Deukmedjian AR. Visceral, vascular, and wound complications following over 13,000 lateral interbody fusions: a survey study and literature review. *Eur Spine J*. 2015;24 Suppl 3: 386-96.
 84. Malham GM, Ellis NJ, Parker RM, et al. Clinical outcome and fusion rates after the first 30 extreme lateral interbody fusions. *Scientific World J*. 2012;2012:246989.
 85. Akbarnia BA, Mundis GM, Jr., Moazzaz P, et al. Anterior column realignment (ACR) for focal kyphotic spinal deformity using a lateral transposas approach and ALL release. *J Spinal Disord Tech*. 2014;27(1):29-39.
 86. Murray G, Beckman J, Bach K, et al. Complications and neurological deficits following minimally invasive anterior column release for adult spinal deformity: a retrospective study. *Eur Spine J*. 2015;24 Suppl 3:397-404.
 87. Aichmair A, Fantini GA, Garvin S, et al. Aortic perforation during lateral lumbar interbody fusion. *J Spinal Disord Tech*. 2015; 28(2):71-5. Eng.
 88. Assina R, Majmundar NJ, Herschman Y, et al. First report of major vascular injury due to lateral transposas approach leading to fatality. *J Neurosurg Spine*. 2014;21(5):794-8.
 89. Balsano M, Carlucci S, Ose M, et al. A case report of a rare complication of bowel perforation in extreme lateral interbody fusion. *Eur Spine J*. 2015;24 Suppl 3:405-8.
 90. Mirilas P, Skandalakis JE. Surgical anatomy of the retroperitoneal spaces part II: the architecture of the retroperitoneal space. *Am Surg*. 2010;76(1):33-42. eng.
 91. Meyers MA. Acute extraperitoneal infection. *Seminars in roentgenology*. 1973;8(4):445-64. eng.
 92. Meyers MA. Radiological features of the spread and localization of extraperitoneal gas and their relationship to its source. An anatomical approach. *Radiology*. 1974;111(1):17-26. eng.
 93. Meyers MA. Uriniferous perirenal pseudocyst: new observations. *Radiology*. 1975;117(3 Pt 1):539-45. eng.
 94. Meyers MA, Goodman KJ. Pathways of extrapelvic spread of disease: Anatomic-radiologic correlation. *Am J Roentgenol Radium Ther Nucl Med*. 1975;125(4):900-9. eng.
 95. Meyers MA, Whalen JP, Evans JA. Diagnosis of perirenal and subcapsular masses. Anatomic-radiologic correlation. *Am J Roentgenol Radium Ther Nucl Med*. 1974;121(3):523-38. eng.
 96. Meyers MA, Whalen JP, Peelle K, et al. Radiologic features of extraperitoneal effusions. An anatomic approach. *Radiology*. 1972;104(2):249-57.
 97. Meyers MA, Oliphant M, Berne AS, et al. The peritoneal ligaments and mesenteries: pathways of intraabdominal spread of disease. *Radiology*. 1987;163(3):593-604.
 98. Oliphant M, Berne AS, Meyers MA. Spread of disease via the subperitoneal space: the small bowel mesentery. *Abdom Imaging*. 1993;18(2):109-16.
 99. Gerota D. Beitrage zur Kenntnis des Befestigungsapparates der Niere. *Arch Anat Entwicklungsgesch*. Leipzig. 1895:265-86.
 100. Zuckerkandl E. Beitrage zur Anatomie des Menschlichen Korpers. Ueber den Fixationsapparat der Nieren. *Med Jahr*. 1883;13: 59-67.
 101. Congdon ED, Edson JN. The cone of renal fascia in the adult white male. *Anat Rec*. 1941;80(3):289-313.
 102. Mitchell GA. The renal fascia. *Br J Surg*. 1950;37(147):257-66.
 103. Lim JH, Kim B, Auh YH. Anatomical communications of the perirenal space. *Br J Radiol*. 1998;71(844):450-6. eng.
 104. Mindell HJ, Mastromatteo JF, Dickey KW, et al. Anatomic communications between the three retroperitoneal spaces: determination by CT-guided injections of contrast material in cadavers. *Am J Roentgenol*. 1995;164(5):1173-8.
 105. Meyers MA, Charnsangavej C, Oliphant M. Meyers' dynamic radiology of the abdomen: normal and pathologic anatomy. New York: Springer; 2011.xviii,419p.p
 106. Dodds WJ, Darweesh RM, Lawson TL, et al. The retroperitoneal spaces revisited. *AJR Am J Roentgenol*. 1986;147(6):1155-61. eng.
 107. Molmenti EP, Balfe DM, Kanterman RY, et al. Anatomy of the retroperitoneum: observations of the distribution of pathologic fluid collections. *Radiology*. 1996;200(1):95-103.
 108. Goenka AH, Shah SN, Remer EM. Imaging of the retroperitoneum. *Radiologic clinics of North America*. 2012;50(2):333-55, vii. eng.
 109. Willard FH, Vleeming A, Schuenke MD, et al. The thoracolum-

- bar fascia: anatomy, function and clinical considerations. *J Anat.* 2012;221(6):507-36.
110. Gore RM, Balfe DM, Aizenstein RI, et al. The great escape: interfascial decompression planes of the retroperitoneum. *AJR Am J Roentgenol.* 2000;175(2):363-70.
 111. Tirkes T, Sandrasegaran K, Patel AA, et al. Peritoneal and retroperitoneal anatomy and its relevance for cross-sectional imaging. *Radiographics: a review publication of the Radiological Society of North America, Inc.* 2012;32(2):437-51. eng.
 112. MacLennan GT, Hinman F. *Posterolateral and Posterior Body Wall: Hinman's atlas of urosurgical anatomy.* Philadelphia: Elsevier/Saunders; 2012.p
 113. Palmer DA, Moynzadeh A. *Surgical, Radiographic, and Endoscopic Anatomy of the Retroperitoneum.* 11th ed./editor-in-chief, Alan J. Wein; [editors], Louis R. Kavoussi, Alan W. Partin, Craig A. Peters ed.: Elsevier; 2016. Campbell-Walsh urology; p.764-83
 114. Chesbrough RM, Burkhard TK, Martinez AJ, et al. Gerota versus Zuckerkandl: the renal fascia revisited. *Radiology.* 1989;173(3):845-6.
 115. Feldberg MAM. *Computed tomography of the retroperitoneum: an anatomical and pathological atlas with emphasis on the fascial planes: Series in radiology.* Martinus Nijhoff Publishers Distributors for the United States and Canada, Kluwer Boston; 1983.xiv,190p.p
 116. Raptopoulos V, Kleinman PK, Marks S, Jr., et al. Renal fascial pathway: posterior extension of pancreatic effusions within the anterior pararenal space. *Radiology.* 1986;158(2):367-74. eng.
 117. Hinman F. *The principles and practice of urology.* Philadelphia London,: W.B. Saunders Company; 1935.1111p.p
 118. Southam AH. The Fixation of the Kidney. *QJM: INT J MED Journal.* 1923;os-16(64):283-308.
 119. Hinman F. *Atlas of urosurgical anatomy.* W.B. Saunders; 1993. xvi,553p.p
 120. Marks SC, Jr., Raptopoulos V, Kleinman P, et al. The anatomical basis for retrorenal extensions of pancreatic effusions: the role of the renal fasciae. *Surgical and radiologic anatomy: SRA.* 1986;8(2):89-97. eng.
 121. Hadar H, Gadoth N. Positional relations of colon and kidney determined by perirenal fat. *AJR Am J Roentgenol.* 1984;143(4):773-6.
 122. Hopper KD, Sherman JL, Luethke JM, et al. The retrorenal colon in the supine and prone patient. *Radiology.* 1987;162(2):443-6.
 123. Sherman JL, Hopper KD, Greene AJ, et al. The retrorenal colon on computed tomography: a normal variant. *J Comput Assist Tomogr.* 1985;9(2):339-41.
 124. Matsubara A, Murakami G, Niikura H, et al. Development of the human retroperitoneal fasciae. *Cells Tissues Organs.* 2009;190(5):286-96.
 125. Toldt C. *Lehrbuch der gewebelehre, mit vorzugsweiser berücksichtigung des menschlichen körpers.* Stuttgart,: F. Enke; 1877. xii,655,1p.p
 126. Stranding S. *Posterior abdominal wall and retroperitoneum.* Forty-first edition. ed. New York: Elsevier Limited; 2016. Gray's anatomy: the anatomical basis of clinical practice; p.1083-97
 127. Coffin A, Boulay-Coletta I, Sebbag-Sfez D, et al. Radioanatomy of the retroperitoneal space. *Diagn Interv Imaging.* 2015;96(2):171-86. eng.
 128. Tobin CE. The renal fascia and its relation to the transversalis fascia. *Anat Rec.* 1944;89(3):295-311.
 129. Kato H, Kiyokawa H, Inoue H, et al. Anatomical reconsideration to renal area: lessons learned from radical nephrectomy or adrenalectomy through a minimal incision over the 12th rib. *Int J Urol.* 2004;11(9):709-13. eng.
 130. Takahashi R, Furubayashi N, Nakamura M, et al. Surgical considerations of the renal fascia and the retroperitoneal space around the kidney. *J Bodyw Mov Ther.* 2012;16(3):392-6. eng.
 131. Kanemura T, Satake K, Yamaguchi H, et al.: Possibility of colonic perforation during extreme lateral interbody fusion: Distance between descending or ascending colon and lateral approach Pathway. 9th Annual SOLAS Meeting. 2016:16-7.

Spine Surgery and Related Research is an Open Access article distributed under the Creative Commons Attribution - NonCommercial - NoDerivatives 4.0 International License. To view the details of this license, please visit (<https://creativecommons.org/licenses/by-nc-nd/4.0/>).