

Magnetic resonance imaging evaluation of acetabular orientation in normal Chinese children

YiQiang Li, MD^a, YuanZhong Liu, MD^{a,*}, QingHe Zhou, MD^a, WeiDong Chen, MD^a, JingChun Li, MD^a, LingJia Yu, MD^a, HongWen Xu, MD^a, DengHui Xie, MD^{a,b}

Abstract

There are no data regarding the acetabular orientation on magnetic resonance imaging (MRI); this study investigates the changes of acetabular orientation with age in normal Chinese children.

We retrospectively analyzed the medical records of children who underwent hip MRI examination at our hospital from January 2009 to December 2015. A total of 180 patients with normal MRI reading of the hip joints were included and were divided into 14 groups according to age: from 6 months of age and then for each year from 1 to 16 years. The bony and cartilage acetabular anteversion angle (AAA), acetabular inclination angle (AIA), and acetabular index (AI) were measured. Total bony and cartilage femoral head coverage angles were measured on axial section total femoral head coverage angle (a-TCA) and coronal section total femoral head coverage angle (c-TCA).

The mean bony AAA and AIA were $12.2 \pm 2.5^\circ$ and $50.9 \pm 2.5^\circ$, respectively; both of them stayed constant from the age of 6 months to 16 years. Similar results were found in cartilage AAA ($12.1 \pm 2.5^\circ$) and AIA ($41.2 \pm 3.0^\circ$). There was no difference between bony and cartilage AAA, but bony AIA was significantly larger than cartilage AIA. Bony AI was $24.1 \pm 2.4^\circ$ at the age of 6 months, decreasing to $12.5 \pm 2.3^\circ$ by 12 to 13 years of age; cartilage AI ($5.9 \pm 1.7^\circ$) maintained a steady value with age. The mean bony a-TCA and c-TCA at 6 months were $117.0 \pm 5.8^\circ$ and $127.5 \pm 5.1^\circ$, increasing to $144.5 \pm 4.6^\circ$ and $140.7 \pm 2.5^\circ$ at the age of 16 years. However, the cartilage a-TCA ($145.2 \pm 7.2^\circ$) and c-TCA ($154.1 \pm 5.7^\circ$) did not change significantly with age.

Both bony and cartilage AAA and AIA remain constant up to the age of 16 years in normal Chinese pediatric population. Although the cartilage coverage of femoral head by the acetabulum remains unchanged with age, the bony coverage of femoral head increases.

Abbreviations: AAA = acetabular anteversion angle, AI = acetabular index, AIA = acetabular inclination angle, a-TCA = axial section total femoral head coverage angle, CT = computed tomography, c-TCA = coronal section total femoral head coverage angle, DDH = development dysplasia of the hip, MRI = magnetic resonance imaging, n.s. = no significant.

Keywords: acetabular anteversion angle, acetabular inclination angle, acetabular index, acetabular orientation, magnetic resonance imaging

1. Introduction

Acetabular orientation refers to the direction of the acetabular cup relative to the axial and coronal planes. This is an important

factor in the determination of the appropriate type and extent of operations on the hips, such as an osteotomy of the pelvis in development dysplasia of the hip (DDH), or total hip arthroplasty for osteoarthritis or trauma to the acetabulum.

Some investigators have developed methods to evaluate the acetabular orientation, including X-ray examination,^[1] computed tomography (CT),^[2,3] and magnetic resonance imaging (MRI).^[4] When evaluating acetabular orientation, 2 important angles are widely used, including the acetabular anteversion angle (AAA) and the acetabular inclination angle (AIA).^[5] They were measured on cadavers,^[6] X-ray films,^[1] 2-dimensional CT images,^[2,7] MRI,^[4,8] and 3-dimensional CT reconstruction systems.^[3]

CT images have been widely used to measure AAA and AIA. On CT imaging, the AAA is formed by a reference line perpendicular to the line connecting the posterior iliums and a line connecting the posterior and anterior margins of the acetabulum. The AIA is the angle between the face of the acetabular cup and the transverse axis. However, there are still some shortcomings because the cartilage of the acetabulum and the femoral head cannot be distinguished on CT and the information regarding the cartilaginous acetabulum is lost.

In recent years, more and more studies focusing on MRI evaluation of acetabular orientation are being reported.^[4,8] MRI

Editor: Heye Zhang.

The authors have no conflicts of interest to disclose.

^aGuangzhou Women and Children's Medical Center, Guangzhou Medical University, ^bSouthern Medical University, Guangzhou, China.

*Correspondence: HongWen Xu, Department of Orthopedics, Guangzhou Women and Children's Medical Center, Guangzhou Medical University, 9th JinSui Road, Guangzhou 510623, China (e-mail: gzorthopedics@qq.com); DengHui Xie, Department of Orthopedics, Guangzhou Women and Children's Medical Center, Guangzhou Medical University, 9th JinSui Road, Guangzhou 510623, China; Southern Medical University, Guangzhou 510515, China (e-mail: ste.ven.06@163.com).

Copyright © 2016 the Author(s). Published by Wolters Kluwer Health, Inc. All rights reserved.

This is an open access article distributed under the terms of the Creative Commons Attribution-Non Commercial-No Derivatives License 4.0 (CCBY-NC-ND), where it is permissible to download and share the work provided it is properly cited. The work cannot be changed in any way or used commercially.

Medicine (2016) 95:37(e4878)

Received: 23 March 2016 / Received in final form: 26 July 2016 / Accepted: 12 August 2016

<http://dx.doi.org/10.1097/MD.0000000000004878>

overcomes the shortcomings of CT, since it shows the cartilage and bone more clearly and may provide more useful information than does CT when evaluating acetabular orientation. Douira-Khomsni et al.^[9] conducted a prospective study about MRI evaluation of acetabular residual dysplasia in DDH, they demonstrated that MRI promoted more accurate selection of patients for pelvic osteotomy and aided in the choice of the most appropriate type of osteotomy.

Unfortunately, there are no MRI data regarding the measurement of AAA and AIA in normal children, making it difficult to differentiate normal from abnormal hips. Our study aims to investigate the change of AAA and AIA with age in normal Chinese children.

2. Materials and methods

A retrospective study of the medical records of children in our hospital who underwent MRI examination (including the hip joint) from January 2009 to December 2015 was performed. This study was approved by the Ethical Committee of Guangzhou Women and Children's Medical Center (no. 2015020904). Generally, these patients underwent MRI examination because of diseases pertaining to proximal femur or pelvis, or lower limb pain, or congenital abnormality of the urogenital system. The patients with a normal MRI reading of the hip joint or diagnosis of mild synovitis of the hip were included in this study. We excluded the patients with nonstandard positioning during MRI examination or with other diseases of the hip such as femoral head necrosis, DDH, septic arthritis of the hip, fractures of acetabulum or femoral neck, or tuberculosis of the hip. A total of 180 patients (81 girls and 99 boys) aged from 6 months to 16 years met our criteria for this study and were eligible for final analysis. These patients were grouped according to their age. MRI examination was performed using a 1.5T Philips Gyroscan Achieva MRI system (Philips, Best, The Netherlands) with the standard examination including the whole pelvis and proximal femur with axial, sagittal, and coronal plane sequences. The MRI examination was carried out under sedation or general anesthesia with the patients placed supine, legs in a neutral position, and with a body array coil placed anterior and posterior to the pelvis. The sequences included T1-weighted (T1-W) spin-echo (SE) images (repetition time/echo time [TR/TE] 372/7 milliseconds; time of acquisition 4 minutes 28 seconds) in the coronal and sagittal planes and T2-weighted (T2-W) fast field-echo (FFE) (repetition time 369 milliseconds; echo time 14 milliseconds; time of acquisition 3 minutes 16 seconds; flip angle 25°) in coronal and sagittal planes. All sequences used a 22 cm field of view, 3 mm slice thickness, 0.4 mm slice gap, 384-384 matrix, and 2 for the number of excitations.

Using the MRI images, the following bony and cartilage parameters were measured: the AAA, AIA, the acetabular index (AI), the axial section total femoral head coverage angle (a-TCA), and the coronal section total femoral head coverage angle (c-TCA). The angles of a-TCA and c-TCA are parameters of the relationship of acetabulum and femoral head; as the angle increases, the femoral head is covered by the acetabulum to a larger extent.

The method to measure AAA and AIA were similar to the methods used for CT by Stem et al.^[7] For measuring bony angles, we used the bony margins of the acetabulum, whereas for cartilage angles, we used the cartilage margins of the acetabulum. Figures 1 and 2 show the method. On T1-W SE sequences in the axial plane, at the level of the center of the hip joint (with a largest femoral head

diameter or deepest point of the acetabulum), AAA was measured as the angle formed by a reference line perpendicular to a line connecting the posterior iliac wings or triradiate cartilage and a line connecting the posterior and anterior margins of the acetabulum. The a-TCA is formed by 2 lines connecting the center of the femoral head to the posterior and anterior margins of the acetabulum. On T2-W FFE sequences in the coronal plane at the level of the center of the hip joint (using images with the largest femoral head diameter or greatest depth of the acetabulum), the AIA was measured as the angle formed by a reference line connecting the triradiate cartilage and a line connecting the superior and inferior margins of the acetabulum. The AI was measured as the angle formed by the same reference line connecting the triradiate cartilages and a line connecting the center of the acetabulum and the superior acetabulum. The c-TCA is formed by the 2 lines connecting the center of the femoral head to the superior and inferior margins of the acetabulum.

Two persons (orthopedic doctors) measured these angles independently, and both of them were trained by a radiologist in our hospital before measuring, to make sure all measurements were accurate and repeatable. Paired *t* tests were used to compare the difference between 2 measurers, differences between bony and cartilage angles, as well as the difference between the values of left and right side. Independent samples *t* test was used to compare the difference between male and female. One-way analysis of variance (ANOVA) and multiple comparisons were used to compare the angles among the different age groups.

3. Results

We show the results of the measurements of acetabular orientation angles in Tables 1 and 2.

Interobserver agreement was high between the 2 orthopedic surgeons ($P=0.352$). Thus, we used the sample mean values in final data analysis. There were no differences ($P=0.503$) between the left and right side, and thus we combined the data and used the sample mean values. There was no difference between male and female in bony and cartilage AAA, AIA, AI, a-TCA, and c-TCA ($P>0.05$).

3.1. Results of bony and cartilage AAA, AIA, and AI

The sample means of the bony AAA in the 6-month age group and the 14- to 16-year age group were $12.3 \pm 0.9^\circ$ and $13.8 \pm 1.8^\circ$, respectively. The total sample mean bony AAA was $12.2 \pm 2.5^\circ$, and there was no significant (n.s.) difference among the 14 different age groups ($P=0.169$) with analysis of variance. We found similar results for the bony AIA. The sample means of the bony AIA in the 6-month age group and in the 14- to 16-year age group were $51.1 \pm 2.1^\circ$ and $49.8 \pm 3.5^\circ$, respectively. The total sample mean bony AIA was $50.9 \pm 2.5^\circ$; again there was no difference between the 14 age groups ($P=0.103$). The mean bony AI decreased significantly with age ($P<0.01$). The mean bony AI in the 6-month age group was $24.1 \pm 2.4^\circ$, decreasing to $12.5 \pm 2.3^\circ$ in the 12- to 13-year age group.

The total sample mean cartilage AAA was $12.1 \pm 2.5^\circ$ and there were n.s. differences between the 14 different age groups ($P=0.316$). Similar results were found for the cartilage AIA ($P=0.272$) and cartilage AI ($P=0.627$). The total sample means of the cartilage AIA and AI were $41.2 \pm 3.8^\circ$ and $5.9 \pm 1.7^\circ$, respectively. These results indicated that both cartilage AAA, AIA, and AI remained unchanged with age. No differences were found between bony and cartilage AAA ($P=0.250$); however, bony AIA was significantly larger than cartilage AIA ($P<0.001$).

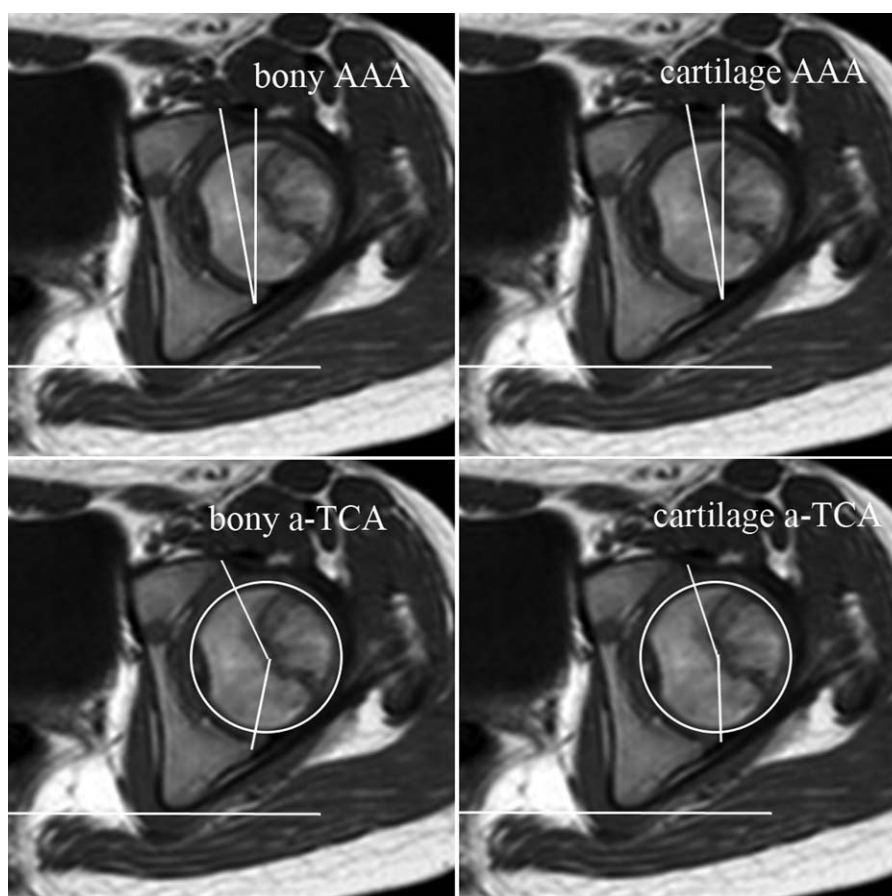


Figure 1. The measurement of bony and cartilage acetabular anteversion angle and axial section total femoral head coverage angle on axial section imaging of magnetic resonance imaging in an 8-year-old male.

3.2. Result of bony and cartilage total femoral head coverage angle

The bony a-TCA and c-TCA significantly change with age ($P < 0.001$). The mean bony a-TCA at 6 months was $117.0 \pm 5.8^\circ$, increasing to $144.5 \pm 4.6^\circ$ in the 14- to 16-year age group. The mean c-TCA at 6 months was $127.5 \pm 5.1^\circ$, increasing to $140.7 \pm 2.5^\circ$ at 14- to 16-year age group. No differences were found in a-TCA between the 6-month, 1-, 2-, 3-, 4-, and 5-year age groups (n.s.). However, the a-TCA in the 6-month, 1-, 2-, 3-, and 4-year age groups were significantly lower than the a-TCA in the remaining groups, and similar results were found for age-specific c-TCA values.

The total sample means of cartilage a-TCA and c-TCA were $145.2 \pm 7.2^\circ$ and $154.1 \pm 5.7^\circ$, both of them remained unchanged with age (n.s.). In the 14- to 16-year age group, cartilage c-TCA was significantly larger than bony c-TCA ($P < 0.001$). However, cartilage a-TCA was similar when compared to bony a-TCA ($P = 0.599$).

Figures 3 and 4 are the comparisons of 0.5- and 12-year-old patients on bony and cartilage AAA, AIA, AI, a-TCA, and c-TCA. Both of them are males.

4. Discussion

In this study, we investigated the changes of acetabular orientation using MRI in children. This is not a cross-sectional population study, and thus there is potential bias in the selection of patients. We believe that our study is the first to measure the

acetabular orientation on MRI in normal children during the course of skeletal maturation. The results of our study provide important information in understanding the normal growth of the hip joint and the variation between individuals. It will assist us to evaluate the hip with what appears to be an abnormal acetabular anteversion and acetabular inclination on bony and cartilage. In addition, it will also help us to make operation plans pertaining to the hip, providing more accurate information for the selection of patients for pelvic osteotomy and the choice of the most appropriate type of osteotomy.

In our study, the overall sample mean bony and cartilage AAA were 12.2° and 12.1° , respectively, and both of them did not change among different age groups in normal Chinese children. So far, few studies have been conducted on the acetabular orientation in normal children. McKibbin^[6] measured the AAA on 15 pelvises from fresh infant cadavers, and their sample means for the AAA in normal male and female neonatal hips were 6° and 9° , respectively. Jacquemier et al^[10] measured the AAA on CT scans in 143 normal children aged from 1 to 15 years and reported a mean AAA of 13° which remained constant during growth. Similar results were reported by Weiner et al.^[11] Our bony and cartilage AAA measurements agree well with those reported by Jacquemier et al^[10] and Weiner et al,^[11] but differ from those reported by McKibbin.^[6] We did not observe any significant increase of the AAA before walking age. The mean bony and cartilage AAA measured in our sample of children at 6 months were 12.3° and 13.6° on MRI, respectively. In addition, no differences were observed between the 6-month and the 1- or

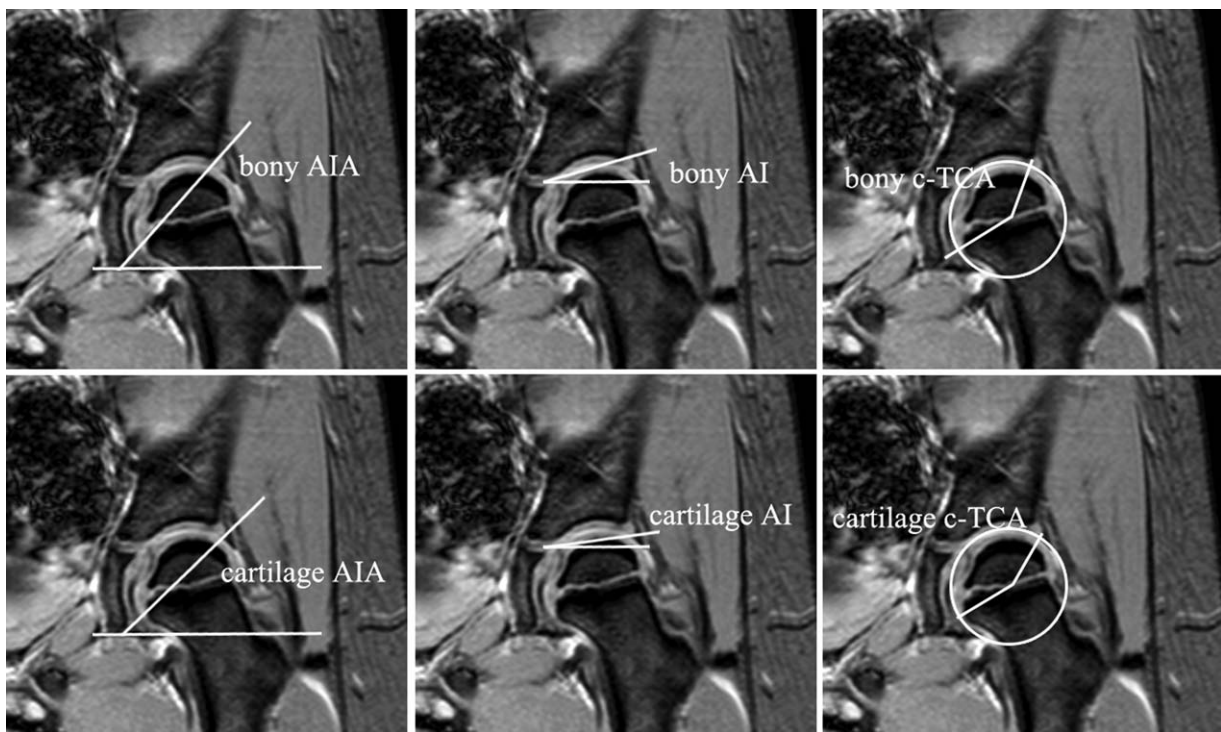


Figure 2. The measurement of bony and cartilage acetabular inclination angle, acetabular index, and coronal section total femoral head coverage angle on coronal section imaging of magnetic resonance imaging in a 6-year-old male.

2-year age groups. Some reasons may be responsible for these different results. First, in the study of McKibbin,^[6] they measured AAA on cadavers. Although it may reflect the cartilaginous AAA as measured in our study, it probably may be different from an AAA measured by either CT or MRI. In addition, McKibbin^[6] measured AAA on fresh newborn cadavers (died within the first 2 weeks of life). Their measurements may be different from our measured AAA at the age of about 6 months. Although we did not measure the bony AAA in patients older than 16 years, some

studies indicated a significantly increased bony AAA in adults^[12,13] (Table 3). Furthermore, our results are more similar to the results of Jacquemier et al^[10] and Weiner et al,^[11] indicating that there is probably no difference between Chinese children and other ethnicities regarding AAA.

Our study also showed that the bony and cartilage AIA remained constant during skeletal maturation in normal Chinese children until 14 to 16 years of age. The mean bony and cartilage AIA in our sample of apparently normal children were 50.9° and

Table 1
Sample means of bony AAA, AIA, AI, a-TCA, and c-TCA in different age groups (N = 180).

Age group, y	N	Sex (male/female)	AAA, °	AIA, °	AI, °	a-TCA, °	c-TCA, °
0.5	7	5/2	12.3 ± 0.9	51.1 ± 2.1	24.1 ± 2.4	117.0 ± 5.8	127.5 ± 5.1
1	13	9/4	13.1 ± 1.5	52.3 ± 3.0	22.8 ± 3.7	126.3 ± 3.9	125.9 ± 8.2
2	14	8/6	12.0 ± 0.9	51.8 ± 2.8	23.0 ± 2.3	118.4 ± 6.5	128.6 ± 4.5
3	16	8/8	12.5 ± 2.0	50.4 ± 1.2	19.3 ± 2.7	120.9 ± 3.8	128.1 ± 6.4
4	17	10/7	11.4 ± 3.0	52.0 ± 1.6	19.1 ± 2.2	125.5 ± 7.8	132.5 ± 6.2
5	14	5/9	11.5 ± 2.7	51.6 ± 1.8	17.9 ± 2.7	130.3 ± 5.9	128.5 ± 4.21
6	15	10/5	12.1 ± 3.3	50.2 ± 1.2	15.4 ± 4.0	132.2 ± 2.7	134.9 ± 6.9
7	13	9/4	12.0 ± 2.4	50.9 ± 1.8	16.4 ± 3.2	139.4 ± 6.8	135.4 ± 6.8
8	13	6/7	13.8 ± 1.9	49.9 ± 1.9	14.8 ± 2.2	137.6 ± 4.2	132.8 ± 6.5
9	11	5/6	12.0 ± 2.9	51.1 ± 2.4	14.0 ± 2.7	144.7 ± 13.1	134.9 ± 6.3
10	11	8/3	10.8 ± 1.7	51.2 ± 2.6	15.1 ± 2.1	148.4 ± 14.3	134.2 ± 4.6
11	13	4/9	11.6 ± 2.5	49.9 ± 3.3	13.0 ± 3.2	147.9 ± 9.9	144.4 ± 9.4
12–13	14	7/7	12.3 ± 4.1	50.6 ± 3.7	12.5 ± 2.3	137.0 ± 24.7	141.0 ± 4.4
14–16	9	5/4	13.8 ± 1.8	49.8 ± 3.5	–	144.5 ± 4.6	140.7 ± 2.5
Mean	180	99/81	12.2 ± 2.5	50.9 ± 2.5	–	–	–
		F	1.390	1.555	9.058	13.923	10.168
		P	0.169	0.103	<0.001	<0.001	<0.001

AAA = acetabular anteversion angle, AI = acetabular index, AIA = acetabular inclination angle, a-TCA = axial section total femoral head coverage angle, c-TCA = the coronal section total femoral head coverage angle.

Table 2
Sample means of cartilage AAA, AIA, AI, a-TCA, and c-TCA in different age groups (N=180).

Age group, y	N	Sex (male/female)	AAA, °	AIA, °	AI, °	a-TCA, °	c-TCA, °
0.5	7	5/2	13.6±2.1	41.7±1.7	6.1±1.9	143.0±9.1	152.1±3.8
1	13	9/4	11.4±1.0	39.6±4.9	6.7±2.6	141.6±6.4	156.1±7.5
2	14	8/6	12.1±1.7	42.1±3.9	6.4±1.8	147.6±10.5	155.9±7.3
3	16	8/8	11.7±4.0	41.8±2.9	6.6±1.8	143.0±5.8	151.8±6.7
4	17	10/7	11.6±2.6	42.5±4.8	5.6±1.4	143.6±5.1	152.9±4.0
5	14	5/9	11.2±1.9	39.1±4.7	5.7±1.5	146.2±7.2	152.5±4.5
6	15	10/5	12.8±2.5	42.0±3.33	5.6±1.8	143.2±6.5	154.2±4.2
7	13	9/4	11.7±2.9	41.5±2.8	5.6±1.3	145.1±7.7	157.7±2.1
8	13	6/7	11.3±2.0	40.8±2.5	6.1±1.6	145.4±7.7	152.8±2.9
9	11	5/6	10.9±1.9	41.0±4.2	5.7±1.0	143.9±8.4	151.4±6.5
10	11	8/3	12.0±3.2	42.9±4.4	5.5±1.5	148.2±9.2	154.2±5.0
11	13	4/9	11.8±4.6	41.3±2.3	5.6±1.6	148.5±4.3	153.6±8.4
12-13	14	7/7	13.5±1.6	39.7±4.7	6.2±1.9	147.7±4.8	155.1±5.6
14-16	9	5/4	11.9±2.7	41.9±1.6	-	146.0±5.2	157.3±5.6
Mean	180	99/81	12.1±2.5	41.2±3.8	5.9±1.7	145.2±7.2	154.1±5.7
		F	1.156	1.215	0.823	1.272	1.561
		P	0.316	0.272	0.627	0.235	0.101

AAA = acetabular anteversion angle, AI = acetabular index, AIA = acetabular inclination angle, a-TCA = axial section total femoral head coverage angle, c-TCA = the coronal section total femoral head coverage angle.

41.2° on MRI, respectively. To our knowledge, there are no studies focusing on AIA in normal children using MRI measurements. However, there are some studies reporting on the bony AIA in adults by other imaging methods. In the study by Stem et al,^[7] the mean AIA in their adult sample was 39°. Suo et al^[14] evaluated acetabular orientation on X-ray films of 40 hips, and the average AIA was 44.1°. In a study by Fukui et al,^[15] 25 cadavers (31 hips) were used to examine the orientation of the cup component aligned with the transverse acetabulum ligament. The average radiographic AIA was 43.5°. The mean bony AIA in our sample of apparently normal children was 50.9° and somewhat larger than the results reported by Fukui et al,^[15] but the cartilage AIA in our study (41.2°) is similar to them. Considering the adult studies mentioned, we hypothesize that there may be a continued decrease in the AIA after skeletal maturity, this may be attributed to the ossification of acetabular cartilage at the outer margin of acetabulum, and therefore the final bony AIA resembles the cartilage AIA.

Our study also indicates that cartilage AI remains unchanged with age, but the bony AI decreases with age, in similarity to the results of other studies. In the study of Huber et al,^[16] who analyzed 115 hips, the bony AI decreased until the age group of 4 to 6 years and then remained relatively constant around 15°, and the cartilage AI (around 5°) stayed relatively constant until the age of 13 years. Tonnis^[17] measured the AI on X-ray films in a large number of normal hips, and the mean AI was about 30° at the time of birth and 15° at the age of 5 to 7 years. Shi et al^[18] measured the AI on 2333 apparently normal X-ray films of the pelvis, and the mean AI was 28.39° in the newborn period and 12.80° at the age of 10 years. In our study, the bony AI measured by MRI in normal children at the age of 6 months was 24.1° and decreased to 12.5° in the 12- to 13-year-old age group, in agreement with the results of *Tonnis* and *Shi*.

Some factors may contribute to the stable value of the AAA and the AIA in our sample of children. The acetabulum is formed by 3 bones: ilium (superiorly), ischium (inferiorly), and pubis

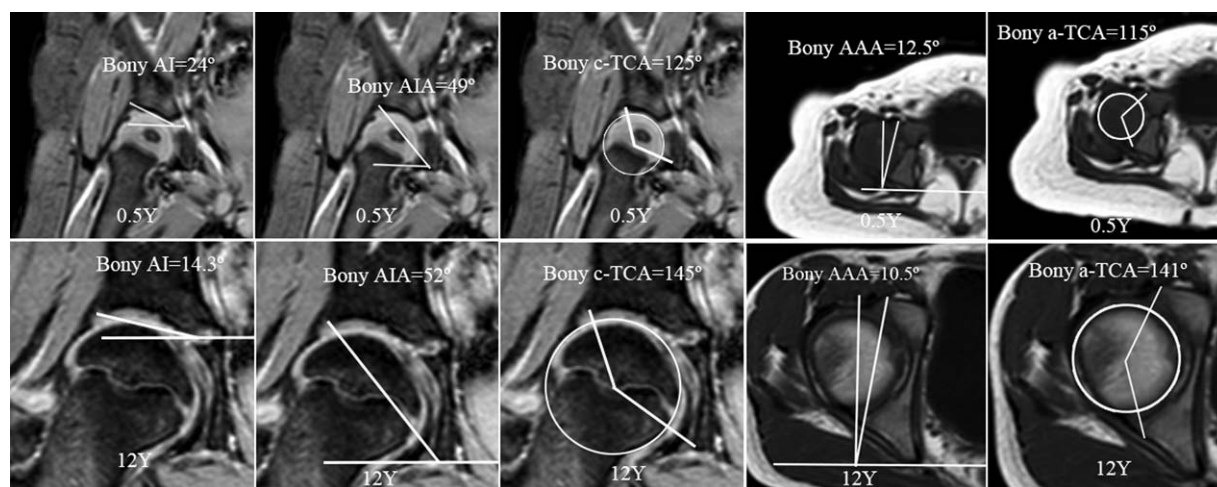


Figure 3. Comparisons of 0.5- and 12-year-old patients on bony acetabular anteversion angle, acetabular inclination angle, acetabular index, axial section total femoral head coverage angle, and coronal section total femoral head coverage angle. Both of them are males.

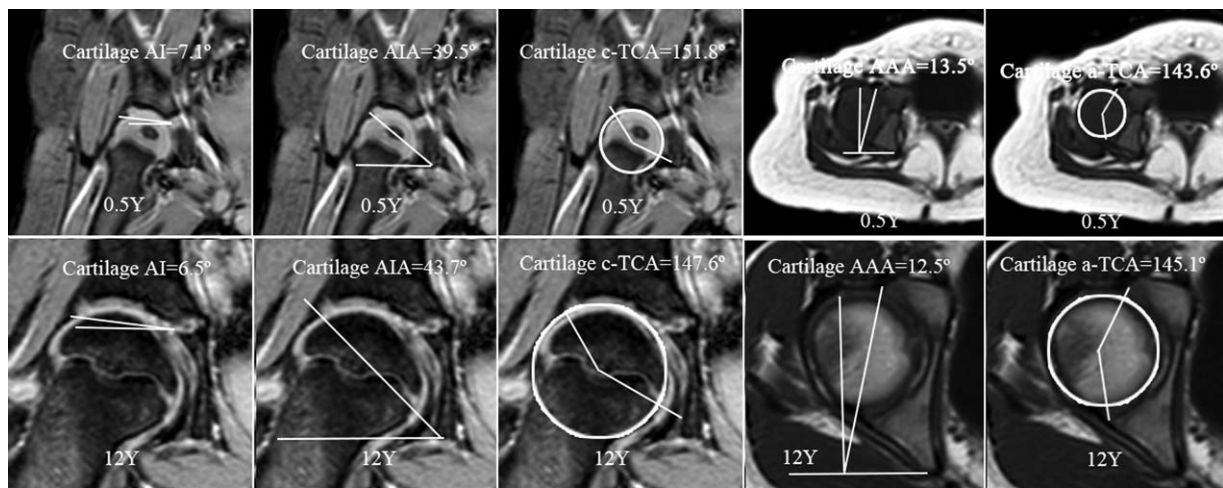


Figure 4. Comparisons of 0.5- and 12-year-old patients on cartilage acetabular anteversion angle, acetabular inclination angle, acetabular index, axial section total femoral head coverage angle, and coronal section total femoral head coverage angle. They are the same patients of Fig. 3, and both of them are males.

(anteriorly). The triradiate cartilage is the center of the acetabulum and connects the 3 bones, subsequently forming the acetabular cup. The growth of acetabulum is closely associated with the process of enchondral ossification in the acetabulum. It has been demonstrated that biomechanical loading regulates enchondral ossification, and thus biomechanical factors play a role in the development of acetabulum,^[19,20] including acetabular orientation. In normal hips, there is a congruent relationship of the acetabulum with the femoral head, and compressive stress is distributed across the acetabulum during endochondral ossification. This may lead to a very balanced growth of ilium, ischium, and pubis within the cartilaginous acetabulum which maintains a stable acetabular orientation. This putative balanced ossification process has evidence in the study of Weiner et al.^[11] Weiner et al measured the anterior and posterior center edge angles on CT scans. Their results indicated that changes in the ossification of the acetabular anterior and posterior walls were minimal and resulted in only minor variations in acetabular anteversion with growth. We believe that the ossification of the acetabular labral cartilage may account for the changes that appear to occur in the AAA and AIA after skeletal maturity.

Our study showed that the bony femoral head coverage increased with age, but the cartilage femoral head coverage remained unchanged from 6 months to 16 years of age.

Generally, as the acetabulum is growing, the cup becomes larger in diameter and deepens, and a larger portion of the femoral head is thus covered by the acetabulum. However, this increase of coverage area may not change the rate of femoral head coverage. From our study, we consider that the increase of bony femoral head coverage rate may be attributed to the ossification of the acetabular cartilage at the acetabulum margin, as the bony a-TCA at 14 to 16 years (144.5°) was similar to cartilage a-TCA (145.2°). Interestingly, our study also indicated that the bony femoral head coverage angles (a-TCA and c-TCA) remained stable until 4 to 5 years of age, but significantly increased with age afterward.

It should be noted that there are still some limitations in the present study. Although the patients with a normal MRI reading of the hip joint were included, they were not healthy children and had diseases pertaining to proximal femur or pelvis, or lower limb pain, or congenital abnormality of the urogenital system. In addition, we could only measure cartilage AAA on T1-W SE sequences. In fact, it would be more clear if measured on T2-W FFE. Both of them might influence the results of measurements.

5. Conclusion

We found a mean bony and cartilage AAA of $12.2 \pm 2.5^\circ$ and $12.1 \pm 2.5^\circ$; and a mean bony and cartilage AIA of $50.9 \pm 2.5^\circ$ and

Table 3
Bony AAA and AIA values reported by different investigators.

Author	Year	Patient	Method	AAA, °	AIA, °
Li YQ (this study)	2016	Children	MRI	12.2	50.9
Jacquemier et al ^[10]	1992	Children	CT	12.78	–
Weiner et al ^[11]	1993	Children	CT	12.1	–
Suo et al ^[14]	2003	Adult	X-ray	9.2	44.1
		Adult	Cadaver	9.1	44.0
Stem et al ^[7]	2006	Adult	CT	23	39
Tallroth and Lepisto ^[13]	2006	Adult	CT	23 (female) 17 (male)	–
Fukui et al ^[15]	2013	Adult	Cadaver	18.2	43.5
Chong le and Too ^[12]	2014	Adult	CT	24 (prone) 21.3 (supine)	– –

AAA = acetabular anteversion angle, AIA = acetabular inclination angle, CT = computed tomography, MRI = magnetic resonance imaging.

$41.2 \pm 3.8^\circ$ in an apparently normal sample of 180 Chinese children. Both measures remain constant up to the age of 14 to 16 years. The bony coverage of the femoral head by the acetabulum increases with age, but the cartilage coverage of the femoral head remains stable up to 14 to 16 year of age.

Acknowledgments

Thanks to Edward Southern for the help of editing this paper.

References

- [1] Nomura T, Naito M, Nakamura Y, et al. An analysis of the best method for evaluating anteversion of the acetabular component after total hip replacement on plain radiographs. *Bone Joint J* 2014;96-B:597–603.
- [2] Kim SS, Frick SL, Wenger DR. Anteversion of the acetabulum in developmental dysplasia of the hip: analysis with computed tomography. *J Pediatr Orthop* 1999;19:438–42.
- [3] Ma H, Han Y, Yang Q, et al. Three-dimensional computed tomography reconstruction measurements of acetabulum in Chinese adults. *Anat Rec* 2014;297:643–9.
- [4] Mootha AK, Saini R, Dhillon MS, et al. MRI evaluation of femoral and acetabular anteversion in developmental dysplasia of the hip. A study in an early walking age group. *Acta Orthop Belg* 2010;76:174–80.
- [5] Murray DW. The definition and measurement of acetabular orientation. *J Bone Joint Surg Br* 1993;75:228–32.
- [6] McKibbin B. Anatomical factors in the stability of the hip joint in the newborn. *J Bone Joint Surg Br* 1970;52:148–59.
- [7] Stem ES, O'Connor MI, Kransdorf MJ, et al. Computed tomography analysis of acetabular anteversion and abduction. *Skeletal Radiol* 2006;35:385–9.
- [8] Muhamad AR, Freitas JM, Bomar JD, et al. Acetabular version on magnetic resonance imaging: analysis of two different measuring techniques. *Hip Int* 2012;22:672–6.
- [9] Douira-Khomsis W, Smida M, Louati H, et al. Magnetic resonance evaluation of acetabular residual dysplasia in developmental dysplasia of the hip: a preliminary study of 27 patients. *J Pediatr Orthop* 2010;30:37–43.
- [10] Jacquemier M, Jouve JL, Bollini G, et al. Acetabular anteversion in children. *J Pediatr Orthop* 1992;12:373–5.
- [11] Weiner LS, Kelley MA, Ulin RI, et al. Development of the acetabulum and hip: computed tomography analysis of the axial plane. *J Pediatr Orthop* 1993;13:421–5.
- [12] Chong le R, Too CW. Comparison of acetabular version angle measurement between prone and reformatted supine computed tomography images. *Skeletal Radiol* 2014;43:289–95.
- [13] Tallroth K, Lepisto J. Computed tomography measurement of acetabular dimensions: normal values for correction of dysplasia. *Acta Orthop* 2006;77:598–602.
- [14] Suo P, Gao J, Mei H. The methods of accurate determination of acetabular phase parameters and their clinical significance. *China J Orthop Trauma* 2003;16:711–3. [Article in Chinese].
- [15] Fukui T, Fukunishi S, Nishio S, et al. Assessment of acetabulum anteversion aligned with the transverse acetabulum ligament: cadaveric study using image-free navigation system. *Orthop Rev* 2013;5:e5.
- [16] Huber H, Mainard-Simard L, Lascombes P, et al. Normal values of bony, cartilaginous, and labral coverage of the infant hip in MR imaging. *J Pediatr Orthop* 2014;34:674–8.
- [17] Tonnis D. Normal values of the hip joint for the evaluation of X-rays in children and adults. *Clin Orthop Relat Res* 1976;39–47.
- [18] Shi Y, Liu T, Zhao Q, et al. The measurements of normal acetabular index and Sharp acetabular angle in Chinese hips. *Chin J Orthop* 2010;30:748–53. [Article in Chinese].
- [19] Zuscik MJ, Hilton MJ, Zhang X, et al. Regulation of chondrogenesis and chondrocyte differentiation by stress. *J Clin Invest* 2008;118:429–38.
- [20] Archer CW, Buxton P, Hall BK, et al. Mechanical regulation of secondary chondrogenesis. *Biorheology* 2006;43:355–70.