



Case report

Pulmonary nocardiosis in Chronic Obstructive Pulmonary Disease: A new clinical challenge



Giorgio Castellana^{a,*}, Anna Grimaldi^b, Marco Castellana^c, Claudio Farina^d, Giuseppe Castellana^e

^a Institute of Respiratory Disease, Aldo Moro University of Bari, Piazza Giulio Cesare 11, Bari, Italy

^b Clinical Laboratory Medicine, P.O. "Di Venere-Triggiano", ASL Bari, Viale A. Moro, Triggiano, Bari, Italy

^c Aldo Moro University of Bari, Piazza Giulio Cesare 11, Bari, Italy

^d Microbiology Institute, AO "Papa Giovanni XXIII", Piazza OMS 1, Bergamo, Italy

^e District Health Center, ASL Bari, Via Edmondo De Amicis 36, Conversano, Bari, Italy

ARTICLE INFO

Article history:

Received 23 October 2015

Received in revised form

9 March 2016

Accepted 10 March 2016

Keywords:

Pulmonary nocardiosis

Opportunistic infections

Chronic obstructive pulmonary disease

Tuberculosis

ABSTRACT

Pulmonary nocardiosis (PN) is a rare but severe disease caused by *Nocardia* spp. Despite the traditional description as opportunistic infection, case reports and case series of pulmonary nocardiosis have recently been reported in immunocompetent patients too, in particular among people with chronic pulmonary diseases such as advanced Chronic Obstructive Pulmonary Disease (COPD).

PN is characterized by non-specific symptoms and radiological findings; bacteriological culture can be difficult. For the reasons above, diagnosis of PN is challenging, sometimes resulting in a misdiagnosis of tuberculosis.

We report an interesting case of PN in a 75-year-old male with COPD. He complained a 3-months history of fatigue, evening rise in body temperature, night sweats, unexplained weight loss of 5 kg, worsening dyspnea, cough and mucopurulent sputum. The chest X-ray showed multiple nodules with cavitations bilaterally in the apical and subclavian regions. *Nocardia cyriacigeorgica* with 100% identity was identified in three sputum samples.

Since the patient has never undergone a systemic and/or inhaled steroid therapy, and has no respiratory failure and comorbidities entailing immunodepression, it is conceivable that, in this immunocompetent patient, the COPD could represent an isolated risk factor for PN.

Risk factors, clinical presentations, radiographic findings, differential diagnosis and review of the literature of PN cases in COPD, pointing out the similarities and differences, are also described.

© 2016 The Authors. Published by Elsevier Ltd. This is an open access article under the CC BY-NC-ND license (<http://creativecommons.org/licenses/by-nc-nd/4.0/>).

1. Introduction

Pulmonary nocardiosis (PN) is a rare but severe opportunistic infectious disease caused by *Nocardia* spp. The microorganism was first isolated by Edmond Nocard in 1888 from cattle with bovine farcy [1]; Eppinger reported the first human case of nocardiosis in 1890 [2]. The bacteria is commonly found in long standing dust, soil

and stagnant water. Aerosol route is the main portal of entry into the body; direct inoculation as result of trauma or intravenous drug assumption or, more rarely, ingestion of contaminated food have also been described [3]. Human-to-human transmission has not been documented [4,5].

The prevalence of PN is not known. Traditionally, PN has been described in immunocompromised patients, with human immunodeficiency virus (HIV) infection, alcohol abuse, diabetes mellitus, organ transplantation and lymphoreticular neoplasm as the most frequently associated conditions [4,5]; lung transplant patients have the highest frequency of PN among recipients of solid organs [6]. Iatrogenic immunosuppression is a further risk factor, with long-term steroid, chemotherapeutic immunosuppressive and anti TNF- α agents as the most commonly associated drugs [4–8]; in particular, chronic steroid therapy has been highlighted in 36% [8],

Abbreviations: Chronic Obstructive Pulmonary Disease, COPD; Human Immunodeficiency Virus, HIV; High Resolution Computed Tomography, HRCT; Pulmonary Nocardiosis, PN; Tuberculosis, TB; trimethoprim-sulfamethoxazole, TMP-SMX.

* Corresponding author.

E-mail addresses: giorgiocastellana@virgilio.it (G. Castellana), anna_grimaldi64@alice.it (A. Grimaldi), mcastellana01@yahoo.it (M. Castellana), cfarina@hpg23.it (C. Farina), bepcaste@libero.it (G. Castellana).

<http://dx.doi.org/10.1016/j.rmcr.2016.03.004>

2213-0071/© 2016 The Authors. Published by Elsevier Ltd. This is an open access article under the CC BY-NC-ND license (<http://creativecommons.org/licenses/by-nc-nd/4.0/>).

62.2% [9] and 64% [4] PN patients in three reviews. Intravenous drug abuse has also been described [10].

Commonly, PN presents as a subacute or chronic disease, with a marked tendency towards remissions and exacerbations. It is characterized by non-specific symptoms such as low fever, night sweats, weight loss, cough, expectoration, dyspnea and chest pain; radiological findings include areas of consolidation, nodules and cavitations which are not pathognomonic [4]. Bacteriological culture can be problematic too. Therefore the clinical and imaging presentation can be very similar to tuberculosis (TB) which represents one of the differential diagnosis [11,12]. Mortality is very high, ranging from 14 to 40% and increasing to 60–100% in patients with dissemination to the central nervous system [5,13]. Life-saving treatments are widely available: trimethoprim-sulfamethoxazole (TMP-SMX) is often used alone, but combination therapy is recommended and should continue until clinical patient improvement occurs and *Nocardia* species identification and antimicrobial drug susceptibility information can be confirmed; single-drug therapy may suffice thereafter [14].

In recent years, nocardiosis has been described among immunocompetent patients, both as isolated cases and case series, in lungs and other sites [15–20]. They can represent from 33% to 56% of total cases [21,22]. In particular, among patients with chronic respiratory diseases, Chronic Obstructive Pulmonary Disease (COPD) and bronchiectasis have been found as predisposing factors [23–39]. Despite reports in literature are limited, COPD is considered the third most common risk factor, surpassed only by chronic steroid treatment and solid organ transplantation [4,33,40–42].

Moreover, COPD life expectancy can be strongly affected by PN: a mortality rate of 17% within the first month and 33% within the first year from diagnosis of PN have been reported [42]. In comparison, the mortality rate for acute exacerbation of COPD is 8% during hospital stay and 23% after 1 year of follow-up [43].

Here we present a case of PN mimicking TB in a patient with undiagnosed COPD.

2. Case presentation

A 75-year-old white male, weighing 65 kg, presented to our center with complaints of a 3-months history of fatigue, evening rise in body temperature, night sweats, unexplained weight loss of 5 kg, worsening dyspnea, cough and mucopurulent sputum. He was a current smoker (30 pack/years) and worked in a stone quarry up to 12 years before; he had a history of chronic catarrhal bronchitis, benign prostatic hypertrophy and an intestinal polypectomy. He denied performing spirometry and taking systemic or inhaled corticosteroids; a chest x-ray of 3 years before showed rarefaction of bronchovascular tree.

On examination, he was afebrile and reduced vesicular murmur and widespread rhonchi were heard on auscultation of the chest. Remainder of the physical examination was unremarkable.

Blood tests showed neutrophilic leukocytosis (white blood cells 16500/mL, 70% neutrophils), mild anemia (hemoglobin 11,4 g/dl), moderate increase in serum inflammatory markers (erythrocyte sedimentation rate 72 mm/h, C-reactive protein 20 mg/l). Plasma immunoglobulin, liver and renal function were in the normal range and HIV antibody testing was negative.

A spirometry test was performed, revealing a severe obstructive ventilation defect, post b2 agonist Forced Vital Capacity of 72% and Forced Expiratory Volume in one second of 46% predicted. The chest X-ray showed, bilaterally in the apical and subclavian regions, sclerosis and multiple nodules with cavitations (Fig. 1). The chest high resolution computed tomography (HRCT) was reported as following: “Multiple nodular opacities are recognized in the upper

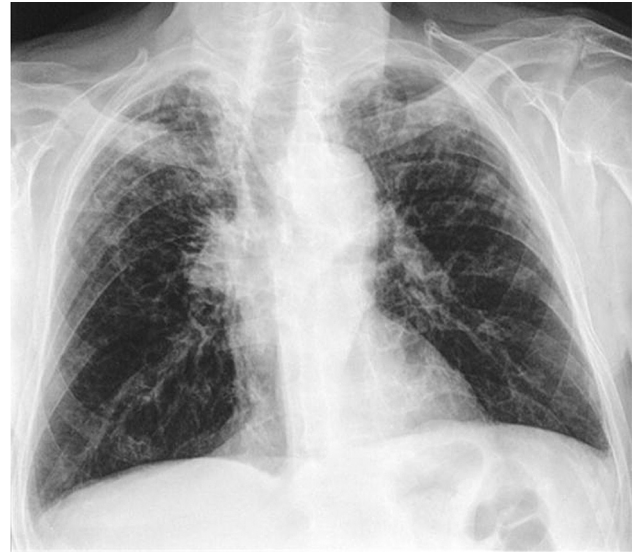

Fig. 1. Chest X-ray showing sclerosis and multiple nodules with cavitations in upper and medium lung zones bilaterally.

lobes, in the apical segments of the lower lobes and in subpleural location; small and regular central cavitations are there in some of these lesions. Multiple focal points of “tree in bud” and bronchiectasis, with prevalent cystic type, in both lung apices are also present. No significant mediastinal lymphadenopathy. These findings are consistent with chronic TB” (Fig. 2).

Three sputum samples on three different days were collected and submitted for the search of *Mycobacteria* spp. Specimen were digested and decontaminated according to Kubica procedure; sputum smears for acid-fast bacilli examination using Kinyoun staining and culture on solid (Löwenstein–Jensen) and liquid medium (Mycobacteria Growth Indicator Tube) were then prepared. The microscopic examination showed filamentous, slim, branched (mycelium and hyphae), blue-to-fuchsia colored (acid-alcohol variable) elements (Fig. 3). *Nocardia* spp. was suspected and confirmed by Gram staining (not shown) and blood agar culture (Fig. 4). Culture on Löwenstein–Jensen medium is showed in Fig. 5. All the previous exams were negative for *M. tuberculosis*.

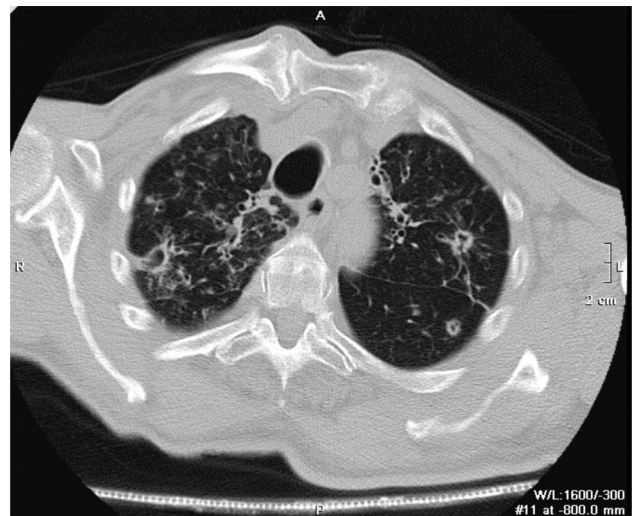


Fig. 2. Chest HRCT scan showing multiple nodular lesions with cavitations in upper lung zone bilaterally.

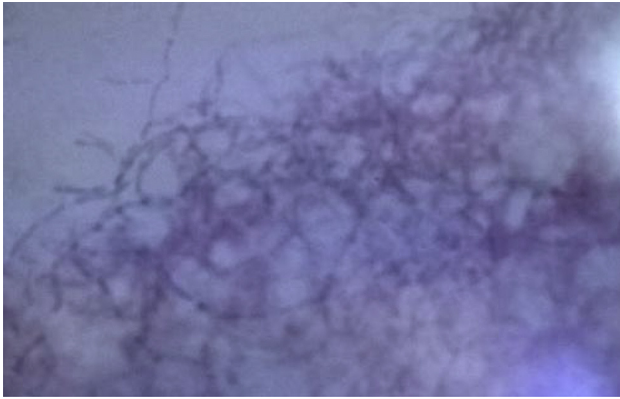


Fig. 3. Kinyoun-stained sputum sample showing filamentous, slim, branched (mycelium and hyphae), blue-to-fuchsia colored (acid-alcohol variable) elements.

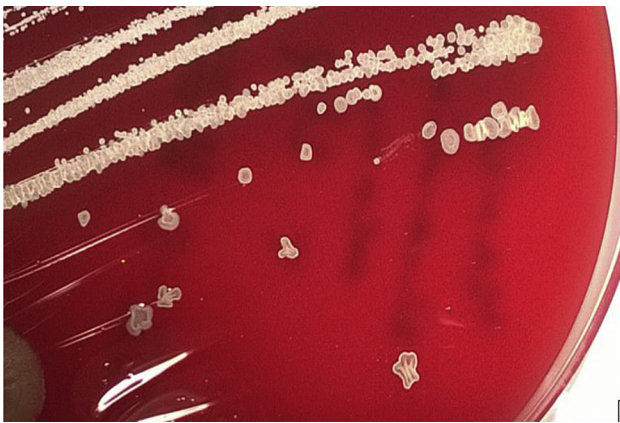


Fig. 4. Sputum culture on blood agar showing wrinkled chalky white or cream-to-pink colored colonies.

Genotypic identification was performed by amplification and sequencing of a DNA fragment coding a rRNA 16S (Applied Biosystem, USA). Sequences were compared with the reference ones present in the GenBank database through BLAST and *Nocardia*




Fig. 5. Sputum culture on Lowenstein-Jensen showing wet salmon-to-yellow colored colonies.

cyriacigeorgica with 100% identity was identified.

Minimal inhibitory concentrations were determined on Mueller Hinton Agar following a 24 h incubation at 37 °C (Etest, Bio-Mérieux). Results were revised and interpreted according to CLSI criteria: amikacin 0.25 µg/mL; amoxicillin plus clavulanic acid (8 µg/mL); ceftriaxone (1 µg/mL); cefepime (2 µg/mL); ciprofloxacin (4 µg/mL); clarythromycin (4 µg/mL); imipenem (0.38 µg/mL); linezolid (0.50 µg/mL); tobramycin (0.047 µg/mL); trimethoprim plus sulfonamide (0.006 µg/mL).

Patient was then started on trimethoprim-sulfamethoxazole (160/800 one tablet twice per day) for 6 months. Following this, a rapid improvement of symptoms, regression of the purulent sputum and of the neutrophilic leukocytosis had been achieved. A second chest radiograph was performed 2 months later, showing an improvement of radiological findings too. A spirometry test was then repeated, confirming the suspect of COPD; specific therapy was started.

The patient gave an informed consent for the case report.

3. Discussion

Although nocardiosis is a rare disease, the clinical suspicion even in immunocompetent patients and the microbiological warning can lead to an early diagnosis and a life-saving treatment. Our case represents a typical presentation of PN with clinical and radiological findings mimicking TB.

3.1. Which patients should be suspected of PN?

Characteristics of PN may be summarized as follows. The disease is more common among males (73%) [20,41]. The mean age is 66 years, even if it can be higher in COPD cases or lower among organ transplant recipients and patients with HIV or pulmonary alveolar proteinosis [4,44]. As already mentioned in Section 1, symptoms of PN are far from being specific. Among the laboratory tests, neutrophilic leukocytosis and elevated C-reactive protein levels are commonly seen in patients without HIV infection, leukopenia in patients with HIV infection [5,20,42,45].

3.2. Which is the radiological presentation of PN?

As already mentioned in Section 1, radiographic findings are also non pathognomonic. Very scanty information is available in the literature about PN on HRCT. The predominant presentation is a bilateral involvement with areas of consolidations, sometimes associated with cavitations; nodules with or without cavitation are most common in HIV-infected patients [46–50]. According to two recent reviews, other findings may include masses, bronchial wall and septal line thickening, bronchiectasis, ground glass opacity and a crazy paving appearance around the previous lesions which are in general more common in middle rather than peripheral areas; intrathoracic lymphadenopathy, pleural effusion and pericardial effusion have also been described [22,51].

3.3. How can the clinical and radiological suspect of PN be confirmed?

The diagnosis of PN requires isolation and identification of the organism from a clinical samples: sputum, tracheal aspiration or bronchoalveolar lavage. Sputum samples can be diagnostic in 77–90% patients. The physician should inform the laboratory about the suspect in order to increase the overall accuracy of the exam. Specimen should first be processed and stained for microscopy, then cultured for at least 48–72 hours; typical stains include modified acid-fast and Gram stains. When isolated, biochemical

Table 1
Case series of pulmonary nocardiosis in literature.

Author, year [Ref.]	Pulmonary nocardiosis	Any chronic respiratory disease	COPD	COPD GOLD IV ^a	Chronic respiratory disease other than COPD	Malignancies	Diabetes	Chronic renal failure	Autoimmune disease	Systemic steroid therapy
Lacassagne et al., 1996 [26]	3	3	2	2	2	–	–	–	–	1
Mari et al., 2001 [45]	10	6	6	3	1(1)	–	–	–	1	5(4)
Farina et al., 2002 [64]	18	10	5	–	5	2	–	–	–	–
Pintado et al., 2002 [59]§	34	14	16	–	2	–	4	–	–	–
Saubolle and Sussland, 2003 [65]	16	12	–	–	–	–	–	–	–	–
Hui et al., 2003 [29]	35	22	10	–	19(7)	10(3)	–	–	2	20(8)
Matulionyte et al., 2004 [60]	16	3	1	–	–	–	–	–	–	–
Mootsikapun et al., 2005 [66]	31	3	1	–	2	–	–	–	–	–
Martinez-Tomás et al., 2007 [4]	20	6	6	–	1(1)	1	–	–	3	15(3)
Munóz et al., 2007 [41]	26	19	19	1	0	4(4)	2	–	5(3)	15(9)
Chedid et al., 2007 [13]	17	8	5	1	3	5(1)	2(1)	–	3	12(2)
Tuo et al., 2008 [36]	21	11	8	–	3	–	2	–	–	10
Tan et al., 2009 [67]	38	10	2	–	2	7(2)	6	5	7	11(1)
Valerio Minero et al., 2009 [9]	26	11	8	–	3	3(1)	–	–	5(2)	19(6)
Maraki et al., 2009 [38]	2	2	2	–	–	–	–	–	1	1
Al-Jahdali et al., 2011 [33]	25	13	13	–	–	–	–	–	–	–
Garcia-Bellmunt et al., 2012 [42]	30	30	30	17	6	7	3	4	6	15
Chen YC et al., 2012 [68]	20	7	–	–	–	2	6	4	–	5
Hardak et al., 2012 [37]	32	11	3	–	8	–	–	–	–	–
Kurahara et al., 2013 [20]	59	52	13	–	42	12	4	1	2	–
Yang et al., 2014 [69]	40	34	6	–	–	5	13	4	8	20
Chen J et al., 2014 [70]	–	17	4	–	–	2	–	3	3	11
Maggiorelli et al., 2014 [35]	4	3	3	2	3	–	–	–	–	2
Aggarwal et al., 2015 [27]	3	3	3	–	1	–	–	–	–	2
Singh et al., 2015 [28]	4	3	2	1	3(1)	2	–	–	–	2(1)

Notes: Number patients with concomitant COPD is reported in brackets.

^a According to Guideline GOLD 2010.

reactions and enzymatic tests based on a panel of a nine conventional phenotypes can be used for the rapid identification of the most common *Nocardia* spp. [52]. Molecular techniques (polymerase chain reaction, restriction enzyme, 16S rRNA gene sequencing) are also available, even if restricted to referral laboratories. In patients intolerant to sulfonamides, in severe cases and in refractory cases, an antimicrobial susceptibility testing should be performed [4,28,53].

3.4. Differential diagnosis

TB, Pneumonia, carcinoma or abscessus are the most common diseases with a similar presentation.

Based on clinical and imaging findings, fungal infections (aspergillosis, zigomycosis, histoplasmosis, blastomycosis, cryptococcosis), bacterial infections (mycobacterial infections, actinomycosis and *Rhodococcus equi* infections) and malignancies (primary and secondary lung cancer) should all be considered in differential diagnosis of PN. Based on HRCT, pulmonary abscess, septic emboli, sarcoidosis, Wegener granulomatosis should also be taken into consideration when multiple nodules with cavitation are present [14].

The most important differential diagnosis is Mycobacterial infection, including *Mycobacterium tuberculosis* and non-tuberculosis species. As already stated in Section 1, PN can mimic TB because of both similar clinical presentation and radiological

Inhaled steroids	Immunosuppressive therapy other than steroids	Immunosuppressive therapy (not specified)	Immunosuppressive disease (HIV, ...)	Co-infection	Other comorbidities	Immunosuppression (not specified)	COPD – no information reported	COPD as only risk factor
–	–	–	–	–	–	–	–	–
–	–	–	3	–	1(1)	–	–	1
–	–	–	2	–	1	–	5	–
–	–	8	8	–	–	–	–	–
–	–	–	–	–	–	–	–	–
–	9	21	3	5(2)	–	–	–	1
1	–	–	–	–	–	–	–	–
–	–	–	–	–	–	–	1	–
1(1)	8	–	3	–	–	–	–	–
–	–	–	3(1)	–	–	–	–	–
–	–	–	1(1)	–	–	12	–	1
–	1	–	–	9	2	–	8	–
–	4	–	1	–	–	–	–	–
–	–	–	4	1(1)	–	–	–	1
–	1	–	–	–	–	–	–	–
–	–	–	–	–	–	–	13	–
–	7	–	–	–	2	7	–	–
–	–	–	–	–	8	–	–	–
–	–	–	–	3	–	17	–	–
–	–	2	–	26	–	–	–	–
–	7	–	1	–	–	–	–	–
0	3	–	1	–	–	–	–	–
3	–	–	–	–	–	–	–	–
1	–	–	–	–	–	–	–	–
–	–	–	–	4(2)	–	–	–	–

findings; this can easily lead to an initial unconfirmed diagnosis of TB. Cases of concurrent PN and TB especially in HIV-infected patients are also reported in literature. According to some case series, more than two thirds of PN cases were initially misdiagnosed with TB and about 5% of the patients with proven pulmonary TB were shown to be co-infected by *Nocardia* spp [11,12,35,45,54–60]. Concurrent infection of PN and *Mycobacterium avium-intracellulare* complex and PN and aspergillosis have also been reported [29,61,62].

3.5. Is truly COPD an isolated risk factor for PN?

The main characteristics of PN case series and PN single case in COPD reported in literature are listed in Table 1 and Table 2,

respectively. A significant association between PN and COPD is evident, but the analysis of case series and case reports shows that many patients have a severe COPD with respiratory failure and/or other comorbidities and coinfections.

In particular, it has been argued that COPD patients generally receive chronic systemic and/or inhaled steroid [35], which could be confounding when considering lung disease as the only risk factor; this is considered to be true at least in two COPD phenotypes: COPD with frequent exacerbations and COPD with presence of bronchiectasis.

Four patients - one per each of the following case series: Valerio Minero et al. [9], Chedid et al. [13], Hui et al. [29], Mari et al. [45] - had no comorbidities and did not undergo systemic steroid treatment; but no additional information on spirometry and

Table 2

Case reports of pulmonary nocardiosis in COPD in literature.

Author, year [Ref.]	COPD	COPD GOLD IV	Chronic respiratory disease other than COPD	Malignancies	Systemic steroid therapy	Inhaled steroids	Co-infection	Other comorbidities	Immunosuppression (not specified)	COPD as only risk factor
Lederman <i>et al</i> , 2004 [21]	yes			yes	yes			yes		
Diez-Garcia <i>et al</i> , 2005 [24]	yes	yes			yes	yes		yes		
Aidê <i>et al</i> , 2008 [32]	yes	yes	yes		yes	yes	yes			
Azizi <i>et al</i> , 2011 [25]	yes					yes				
Anderson and Kuźniar 2012 [39]	yes				yes	yes				
Rivière <i>et al</i> , 2011 [23]	yes		yes							
Our case	yes									yes

Shading used to divide the features analysed.

chronic inhaled steroid therapy was reported on those patients and no emphasis was given to the COPD as only risk factor. The only clinical case with features similar to our patient is the one described by Rivière *et al.* [23]: given that the patient had never undergone a chronic oral and/or inhaled steroid therapy, the Authors questioned themselves whether COPD could represent a single risk factor for PN. However, their patient had suffered from bronchiectasis after pulmonary tuberculosis many years before.

However, as noted by some Authors, this confounding factors is usually brief and doesn't cause a significant impairment of cellular immune responses: the review of Stuck *et al.* shows that patients administered with <10 mg/day or a cumulative dose of <700 mg of prednisone have similar infectious rates of the general population [34]. Apart from the possible use of steroids, patients with COPD may have an increased susceptibility to bacterial and fungal infections for several reasons, such as a change in bronchial architecture, mucociliary dysfunction, epithelial damage, frequent hospitalization or antibiotic treatments, and comorbidities [4,23,63]. Moreover, in some case in immunocompetent patients genetic factors could play a role in determining susceptibility to infection [23].

4. Conclusions

PN is an infrequent but challenging disease which should always be considered both in immunocompromised and immunocompetent patients. Symptoms, signs and imaging features (chest X-ray, HRCT) can mimic other diseases, in particular TB, therefore a high order of suspicion is crucial for a prompt microbiological evaluation and a life-saving treatment.

COPD is commonly considered a risk factor for PN. The reported case - COPD patient with no respiratory failure, never treated with systemic and inhaled steroid therapy and without comorbidities—is an exemplary case for having COPD as the only risk factor for PN. Whether COPD on its own is able to promote PN is still unclear and requires further assessment.

Conflict of interest

Dr. Giorgio Castellana has nothing to disclose. Dr. Anna Grimaldi has nothing to disclose. Dr. Marco Castellana has nothing to disclose. Dr. Claudio Farina has nothing to disclose. Dr. Giuseppe Castellana has nothing to disclose.

Funding sources

None.

References

- [1] E. Nocard, Note sur la maladie des boeufs de la Gouadeloupe conque sous le nom de farcin, *Ann. Inst. Pasteur.* 2 (1888) 293–302.
- [2] H. Eppinger, Über eine neue pathogene Cladothrix und eine durch sie hervorgerufene Pseudotuberculosis (Cladothrichica), *Beitr. Pathol. Anat. Allg. Pathol.* 9 (1891) 287–328.
- [3] P. Vohra, M. Sharma, A. Yadav, U. Chaudhary, Nocardiosis: a review of clinical-microbiological features, *Int. J. Life ScBt Pharm. Res.* 2 (2013) 20–29.
- [4] R. Martínez Tomás, R. Menéndez Villanueva, S. Reyes Calzada, M. Santos Durantez, J.M. Vallés Tarazona, M. Modesto Alapont, M. Gobernado Serrano, Pulmonary nocardiosis: risk factors and outcomes, *Respirology* 12 (3) (2007 May) 394–400.
- [5] R. Martínez, S. Reyes, R. Menéndez, Pulmonary nocardiosis: risk factors, clinical features, diagnosis and prognosis, *Curr. Opin. Pulm. Med.* 14 (3) (2008 May) 219–227, <http://dx.doi.org/10.1097/MCP.0b013e3282f85dd3>.
- [6] A.Y. Peleg, S. Husain, Z.A. Qureshi, F.P. Silveira, M. Sarumi, K.A. Shutt, E.J. Kwak, D.L. Paterson, Risk factors, clinical characteristics, and outcome of Nocardia infection in organ transplant recipients: a matched case-control study, *Clin. Infect. Dis.* 44 (10) (2007 May 15) 1307–1314. Epub 2007 Apr 3.
- [7] I. Marie, E. Guglielmino, Non tuberculous anti-TNF associated opportunistic infections, *Rev. Med. Interne* 31 (5) (2010 May) 353–360, <http://dx.doi.org/10.1016/j.revmed.2009.04.010>. Epub 2010 Apr 8.
- [8] J. Ambrosioni, D. Lew, J. Garbino, Nocardiosis: updated clinical review and experience at a tertiary center, *Infection* 38 (2) (2010 Apr) 89–97, <http://dx.doi.org/10.1007/s15010-009-9193-9>. Epub 2010 Mar 20.
- [9] M.V. Minero, M. Marín, E. Cercenado, P.M. Rabadán, E. Bouza, P. Muñoz, Nocardiosis at the turn of the century, *Med. Baltim.* 88 (4) (2009 Jul) 250–261, <http://dx.doi.org/10.1097/MD.0b013e3181afa1c8>.
- [10] J. Santos, R. Palacios, A. Rivero, M.A. García-Ordóñez, L. Aliaga, M.A. Muniain, D. Selma, R. Luque, J. Corzo, A. Barrera, Grupo andaluz para el estudio de las enfermedades infecciosas GAEI. Nocardiosis in patients with HIV infection, *Rev. Clin. Esp.* 202 (7) (2002 Jul) 375–378.
- [11] V. Chopra, G.C. Ahir, G. Chand, P.K. Jain, Pulmonary Nocardiosis mimicking pulmonary tuberculosis, *Ind. J. Tub* 48 (2001) 211–213.
- [12] H.M. Alnaum, M.M. Elhassan, F.Y. Mustafa, M.E. Hamid, Prevalence of Nocardia species among HIV-positive patients with suspected tuberculosis, *Trop. Doct.* 41 (4) (2011 Oct) 224–226, <http://dx.doi.org/10.1258/td.2011.110107>. Epub 2011 Aug 30.
- [13] M.B. Chedid, M.F. Chedid, N.S. Porto, C.B. Severo, L.C. Severo, Nocardial infections: report of 22 cases, *Rev. Inst. Med. Trop. Sao Paulo* 49 (4) (2007 Jul-Aug) 239–246.
- [14] J.W. Wilson, Nocardiosis: updates and clinical overview, *Mayo Clin. Proc.* 87 (4) (2012 Apr) 403–407, <http://dx.doi.org/10.1016/j.mayocp.2011.11.016>.
- [15] S. Chain, H. Luciardi, G. Feldman, S. Berman, C. Estrella, Nocardia endocarditis in aortic and tricuspid native valves, *Med. B Aires* 67 (3) (2007) 279–281.
- [16] E. Chatelus, R.M. Javier, J. Sibilia, J.L. Kuntz, E. Forestier, J. Gaudias, Nocardia discitis in an immunocompetent patient, *Jt. Bone Spine* 74 (2) (2007 Mar) 207–209. Epub 2007 Feb 2.

- [17] K. Darwiche, B. Totzeck, S. Gatermann, M. Bollow, S. Ewig, Nocardiosis as a differential diagnosis of a PET-positive pulmonary nodule, *Pneumologie* 61 (3) (2007 Mar) 176–180.
- [18] T. de Silva, C. Evans, H.S. Mudhar, I. Rennie, S.T. Green, Isolated endogenous endophthalmitis secondary to *Nocardia* spp in an immunocompetent adult, *J. Clin. Pathol.* 59 (11) (2006 Nov) 1226.
- [19] Y. Karakan, O. Elbek, M. Uyar, Y. Zer, M. Tulu, O. Dikensoy, *Nocardia transvalensis* infection in an immunocompetent patient reported from Turkey, *Tuberk. Toraks* 55 (3) (2007) 295–298.
- [20] Y. Kurahara, K. Tachibana, K. Tsuyuguchi, M. Akira, K. Suzuki, S. Hayashi, Pulmonary nocardiosis: a clinical analysis of 59 cases, *Respir. Investig.* 52 (3) (2014 May) 160–166, <http://dx.doi.org/10.1016/j.resinv.2013.09.004>. Epub 2013 Nov 7.
- [21] E.R. Lederman, N.F. Crum, A case series and focused review of nocardiosis: clinical and microbiologic aspects, *Med. Baltim.* 83 (5) (2004 Sep) 300–313.
- [22] P. Mehriani, E. Esfandiari, M.A. Karimi, B. Memari, Computed tomography features of pulmonary nocardiosis in immunocompromised and immunocompetent patients, *Pol. J. Radiol.* 80 (2015 Jan 7) 13–17, <http://dx.doi.org/10.12659/PJR.892042> eCollection 2015.
- [23] F. Rivière, M. Billhot, C. Soler, F. Vaylet, J. Margery, Pulmonary nocardiosis in immunocompetent patients: can COPD be the only risk factor? *Eur. Respir. Rev.* 20 (121) (2011 Sep 1) 210–212, <http://dx.doi.org/10.1183/09059180.00002211>.
- [24] M.J. Díez-García, A.L. Andreu, E. Chiner, Bronchopneumonia due to *Nocardia asteroides* in a man with chronic obstructive pulmonary disease, *Arch. Bronconeumol.* 41 (11) (2005 Nov) 642–643.
- [25] F. Azizi, I.A. Darazam, K. Najafizadeh, A. Dorudinia, J. Heshmatnia, P. Poursamimi, P. Tabarsi, S.D. Mansouri, A 60-year-old woman with pulmonary nodules, *Tanaffos* 10 (4) (2011) 69–72.
- [26] L. Lacassagne, A. Didier, M. Murrisespin, R.M. Rouquet, D. Clave, J. Lemozy, J. Giron, P. Leophonte, *Nocardia* respiratory infection in patients with chronic obstructive lung disease, *Rev. Mal. Respir.* 13 (4) (1996) 433–436.
- [27] D. Aggarwal, K. Garg, J. Chander, V. Saini, A.K. Janmeja, Pulmonary nocardiosis revisited: a case series, *Lung India* 32 (2) (2015 Mar–Apr) 165–168, <http://dx.doi.org/10.4103/0970-2113.152638>.
- [28] I. Singh, F.M. West, A. Sanders, B. Hartman, D. Zappetti, Pulmonary nocardiosis in the immunocompetent host: case series. case reports in pulmonology, ID 314831 (2015) 6, <http://dx.doi.org/10.1155/2015/314831>.
- [29] C.H. Hui, V.W. Au, K. Rowland, J.P. Slavotinek, D.L. Gordon, Pulmonary nocardiosis re-visited: experience of 35 patients at diagnosis, *Respir. Med.* 97 (6) (2003 Jun) 709–717.
- [30] M.J. Cremades, R. Menéndez, M. Santos, M. Gobernado, Repeated pulmonary infection by *Nocardia asteroides* complex in a patient with bronchiectasis, *Respiration* 65 (3) (1998) 211–213.
- [31] A. Ferrer, V. Liorenç, G. Codina, J. de Gracia-Roldán, Nocardiosis and bronchiectasis. An uncommon association? *Enferm. Infect. Microbiol. Clin.* 23 (2) (2005 Feb) 62–66.
- [32] M.A. Aidé, S.S. Lourençol, E. Marchiori, G. Zanetti, P.J.J. Mondino, Nocardiose pulmonar em portador de doença pulmonar obstrutiva crônica e bronquiectasias, *J. Bras. Pneumol.* 34 (11) (Nov. 2008). São Paulo, <http://dx.doi.org/10.1590/S1806-37132008001100016>.
- [33] H. Al-Jahdali, S. Baharoon, S. Alothman, Z. Memish, A. Waness, Nocardiosis in a tertiary care hospital in Saudi Arabia, *J. Glob. Infect. Dis.* 3 (2) (2011 Apr) 128–132, <http://dx.doi.org/10.4103/0974-777X.81688>.
- [34] A.E. Stuck, C.E. Minder, F.J. Frey, Risk of infectious complications in patients taking glucocorticosteroids, *Rev. Infect. Dis.* 11 (6) (1989 Nov–Dec) 954–963.
- [35] C. Maggiorelli, I. Di Piero, C. Manta, U. Maccari, I. Galanti, Scala R, Nocardia and lungs in COPD: beyond immuno-deficiencies. *Copd, J. Chronic Obstr. Pulm. Dis.* 12 (3) (2015) 321–326.
- [36] M.H. Tuo, Y.H. Tsai, H.K. Tseng, W.S. Wang, C.P. Liu, C.M. Lee, Clinical experiences of pulmonary and bloodstream nocardiosis in two tertiary care hospitals in northern Taiwan, 2000–2004, *J. Microbiol. Immunol. Infect.* 41 (2008) 130–136.
- [37] E. Hardak, M. Yigla, G. Berger, H. Sprecher, I. Oren, Clinical spectrum and outcome of nocardia infection: experience of 15-Year period from a single tertiary medical center, *Am. J. Med. Sci.* 4 (2012) 286–290.
- [38] S. Maraki, E. Scoulica, E. Nioti, Y. Tselentis, Nocardial infection in Crete, Greece: review of fifteen cases from 2003–2007, *Scand. J. Infect. Dis.* 41 (2009) 122–127.
- [39] M. Anderson, T.J. Kuźniar, Pulmonary nocardiosis in a patient with chronic obstructive pulmonary disease—case report and literature review, *Pneumonol. Alergol. Pol.* 6 (2012) 565–569.
- [40] R. Menéndez, P.J. Cordero, M. Santos, M. Gobernado, V. Marco, Pulmonary infection with *Nocardia* species: a report of 10 cases and review, *Eur. Respir. J.* 10 (7) (1997 Jul) 1542–1546.
- [41] J. Muñoz, B. Mirelis, L.M. Aragón, N. Gutiérrez, F. Sánchez, M. Español, O. Esparcia, M. Gurguá, P. Domingo, P. Coll, Clinical and microbiological features of nocardiosis 1997–2003, *J. Med. Microbiol.* 56 (Pt 4) (2007 Apr) 545–550.
- [42] L. García-Bellmunt, O. Sibila, I. Solanes, F. Sanchez-Reus, V. Plaza, Pulmonary nocardiosis in patients with COPD: characteristics and prognostic factors, *Arch. Bronconeumol.* 48 (8) (2012 Aug) 280–285, <http://dx.doi.org/10.1016/j.arbres.2012.04.009>. Epub 2012 May 30.
- [43] K.H. Groenewegen, A.M. Schols, E.F. Wouters, Mortality and mortality-related factors after hospitalization for acute exacerbation of COPD, *Chest* 124 (2) (2003 Aug) 459–467.
- [44] J. Pascual, M.A. Gómez Aguinaga, R. Vidal, A. Maudes, A. Sureda, E. Gómez Mampaso, L. Fogué, Alveolar proteinosis and nocardiosis: a patient treated by bronchopulmonary lavage, *Postgrad. Med. J.* 65 (767) (1989 Sep) 674–677.
- [45] B. Mari, C. Montón, D. Mariscal, M. Luján, M. Sala, C. Domingo, Pulmonary nocardiosis: clinical experience in ten cases, *Respiration* 68 (4) (2001) 382–388.
- [46] J.H. Hwang, W.J. Koh, G.Y. Suh, M.P. Chung, H. Kim, O.J. Kwon, K.S. Lee, N.Y. Lee, J. Han, Pulmonary nocardiosis with multiple cavitary nodules in a HIV-negative immunocompromised patient, *Intern Med.* 43 (9) (2004 Sep) 852–854.
- [47] M.R. Kramer, R.B. Uttamchandani, The radiographic appearance of pulmonary nocardiosis associated with AIDS, *Chest* 98 (2) (1990 Aug) 382–385.
- [48] J.A. Buckley, A.R. Padhani, J.E. Kuhlman, CT features of pulmonary nocardiosis, *J. Comput. Assist. Tomogr.* 19 (5) (1995 Sep–Oct) 726–732.
- [49] K.N. Blackmon, J.G. Ravenel, J.M. Gomez, J. Ciolino, D.W. Wray, Pulmonary nocardiosis: computed tomography features at diagnosis, *J. Thorac. Imag.* 26 (3) (2011 Aug) 224–229, <http://dx.doi.org/10.1097/RTI.0b013e3181f45dd5>.
- [50] A.A. Oszyoglu, J. Kirsch, T.L. Mohammed, Pulmonary nocardiosis after lung transplantation: CT findings in 7 patients and review of the literature, *J. Thorac. Imag.* 22 (2) (2007 May) 143–148.
- [51] N. Tsujimoto, T. Saraya, K. Kikuchi, S. Takata, Y. Kurihara, S. Hiraoka, H. Makino, S. Yonetani, K. Araki, H. Ishii, H. Takizawa, H. Goto, High-resolution CT findings of patients with pulmonary nocardiosis, *J. Thorac. Dis.* 4 (6) (2012 Dec) 577–582, <http://dx.doi.org/10.3978/j.issn.2072-1439.2012.11.07>.
- [52] G. Wauters, V. Avesani, J. Charlier, M. Janssens, M. Vaneechoutte, M. Delmée, Distribution of nocardia species in clinical samples and their routine rapid identification in the laboratory, *J. Clin. Microbiol.* 43 (6) (2005 Jun) 2624–2628.
- [53] Y. Glupczynski, C. Berhin, M. Janssens, G. Wauters, Determination of antimicrobial susceptibility patterns of *Nocardia* spp. from clinical specimens by Etest, *Clin. Microbiol. Infect.* 12 (9) (2006 Sep) 905–912.
- [54] T. Shimokubo, J. Ashitani, T. Ihi, T. Higa, K. Kumamoto, A case of mixed infection by *Nocardia asteroides* and *Mycobacterium tuberculosis*, *Nihon Kokyuki Gakkai Zasshi* 40 (8) (2002 Aug) 703–707.
- [55] R.C. Chaudhury, A.R. Aher, V. Rastogi, T.K. Prabhu, A case of mixed pulmonary infection by nocardia and *Mycobacterium tuberculosis*, *Indian J. Pathol. Microbiol.* 52 (2) (2009 Apr–Jun) 294–295.
- [56] A. Kumar, A. Mehta, G. Kavathia, M. Madan, Pulmonary and extra pulmonary tuberculosis along with pulmonary nocardiosis in a patient with human immunodeficiency virus infection, *J. Clin. Diagnostic Res.* 5 (1) (2011) 109–111.
- [57] Z. Aminzadeh, I.A. Darazam, Concomitant pulmonary nocardiosis and tuberculosis in a patient with rheumatoid arthritis: a new view Point Jundishapur, *J. Microbiol.* 6 (1) (2012 October) 91–94, <http://dx.doi.org/10.5812/jjm.5362>.
- [58] A. Ekrami, A.D. Khosravi, A.R. Samarabaf Zadeh, M. Hashemzadeh, Nocardia coinfection in patients with pulmonary tuberculosis, *Jundishapur J. Microbiol.* 7 (12) (2014 Dec 1) e12495, <http://dx.doi.org/10.5812/jjm.12495> eCollection 2014.
- [59] V. Pintado, E. Gómez-Mampaso, J. Cobo, C. Quereda, M.A. Meseguer, J. Fortún, E. Navas, S. Moreno, Nocardial infection in patients infected with the human immunodeficiency virus, *Clin. Microbiol. Infect.* 9 (7) (2003 Jul) 716–720.
- [60] R. Matulionyte, P. Rohner, I. Uçkay, D. Lew, J. Garbino, Secular trends of nocardia infection over 15 years in a tertiary care hospital, *J. Clin. Pathol.* 57 (2004) 807–812, <http://dx.doi.org/10.1136/jcp.2004.016923>.
- [61] A. Mohan, S.K. Sharma, V.K. Arora, S. Sharma, J. Prakash, Concurrent pulmonary Aspergillosis and Nocardiosis in an old tubercular cavity masquerading as malignancy in an immunocompetent individual, *Respir. Med. CME* 1 (3) (2008) 231–234.
- [62] K. Yagi, M. Ishii, H. Namkoong, T. Asami, H. Fujiwara, T. Nishimura, F. Saito, Y. Kimisuka, T. Asakura, S. Suzuki, T. Kamo, S. Tasaka, T. Gono, K. Kamei, T. Betsuyaku, N. Hasegawa, Pulmonary nocardiosis caused by *Nocardia cyriacigeorgica* in patients with *Mycobacterium avium* complex lung disease: two case reports, *BMC Infect. Dis.* 14 (2014 Dec 10) 684, <http://dx.doi.org/10.1186/s12879-014-0684-z>.
- [63] F. Ader, S. Nseir, R. Le Berre, S. Leroy, I. Tillie-Leblond, C.H. Marquette, A. Durocher, Invasive pulmonary aspergillosis in chronic obstructive pulmonary disease: an emerging fungal pathogen, *Clin. Microbiol. Infect.* 11 (6) (2005 Jun) 427–429.
- [64] C. Farina, P. Boiron, I. Ferrari, F. Provost, A. Goglio, Report of human nocardiosis in Italy between 1993 and 1997, *Eur. J. Epidemiol.* 17 (2001) 1019–1022.
- [65] Saubolle MA and Sussland D. Nocardiosis. Review of clinical and laboratory experience, *J. Clin. Microbiol.* 2033;41:4497–4501.
- [66] P. Mootsikapun, B. Intarapoka, W. Liawnoraset, Nocardiosis in srinagarind hospital, Thailand: review of 70 cases from 1996–2001, *Int. J. Infect. Dis.* 9 (2005) 154–158.
- [67] C.K. Tan, C.C. Lai, S.H. Lin, C.H. Liao, C.H. Chou, H.L. Hsu, Y.T. Huang, P.R. Hsueh, Clinical and microbiological characteristics of Nocardiosis including those caused by emerging *Nocardia* species in Taiwan, 1998–2008, *Clin. Microbiol.*

- Infect. 16 (2010) 966–972.
- [68] Y.C. Chen, C.H. Lee, C.C. Chien, T.L. Chao, W.C. Lin, J.W. Liu, Pulmonary nocardiosis in southern Taiwan, *J. Microbiol. Immunol. Infect.* 46 (2013) 441–447.
- [69] M. Yang, M. XU, Wei W, H. GAO, X. Zhang, H. Zhao, J. Hu, H. Dong, L. Xu, L. Li, Clinical findings of 40 patients with nocardiosis: a retrospective analysis in a tertiary hospital, *Exp. Ther. Med.* 8 (2014) 25–30.
- [70] J. Chen, H. Zhou, P. Xu, P. Zhang, S. Ma, J. Zhou, Clinical and radiographic characteristics of pulmonary nocardiosis: clues to earlier diagnosis, *PLoS* (2014), <http://dx.doi.org/10.1371/journal.pone.0090724>.