

## Conduits for Coronary Bypass: Internal Thoracic Artery

Hendrick B Barner, M.D.

This second report in the series on coronary artery bypass presents the authors experience and personal views on the internal thoracic artery (ITA) which date to 1966. There has been a very gradual evolution in the acceptance of this conduit which was initially compared with the saphenous vein and viewed as an improbable alternative to it. As is common with concepts and techniques which are 'outside the box' there was skepticism and criticism of this new conduit which was more difficult and time consuming to harvest for the surgeon who had to do it all. It was viewed as small, fragile, spastic and its flow capacity was questioned. Only a few surgeons employed it because of these issues and some of them would frequently graft it to the diagonal artery as it was thought not to supply adequate flow for the left anterior descending unless it was small. After a decade, angiographic data revealed superior patency to vein grafts. Even this evidence and survival benefit reported a few years later did not convince many surgeons that their concerns about limitations justified its use. Thus widespread adaption of the ITA as the conduit of choice for the anterior descending required another decade and bilateral use is only now expanding to more than 5% of patients in the US and somewhat faster in other countries.

Key words: 1. Coronary artery disease  
2. Coronary grafting  
3. Mammary arteries

### INTRODUCTION

This second in a series on conduits for coronary bypass features the internal thoracic artery.

Surprisingly, or not, the left internal thoracic artery (ITA), and also the right in a few instances, was the first and only conduit utilized in a series of patients beginning in 1964 which followed case reports of saphenous vein coronary bypass in 1962 [1,2]. Also surprising was the off-pump approach applied by Kolesov and Kolesov [3] and the non-availability of coronary angiography at that time. By 1976, 132 patients had been operated by him [3].

One might argue that Vineberg's clinical use of the ITA

beginning in 1950 as a myocardial implant after a decade of experimental studies and that Murray's experimental ITA-coronary anastomosis were necessary feasibility studies but in all likelihood unknown to Kolesov [4,5]. Although the implanted ITA remained patent in 80% to 90% of canines and humans it provided less than 5 mL/min of flow [6]. It was Green [7] who after laboratory studies began use of the left ITA, aided by an operating microscope, in 1968 and reported on 165 patients by 1972. We did not use the left ITA until January 1972 after more than two years of laboratory evaluation indicating that its flow capacity was appropriate and histology unchanged from preoperatively up to 18 months after grafting [8]. This was in contrast to vein grafts which had medial fib-

Division of Cardiothoracic Surgery, St. Louis University Hospital

Received: November 10, 2012, Revised: November 11, 2012, Accepted: November 12, 2012

Corresponding author: Hendrick B Barner, Division of Cardiothoracic Surgery, St. Louis University Hospital, 3635 Vista Ave, St. Louis, MO 63110, USA

(Tel) 1-314-577-8359 (Fax) 1-314-577-8315 (E-mail) [hbarner@slu.edu](mailto:hbarner@slu.edu)

© The Korean Society for Thoracic and Cardiovascular Surgery. 2012. All rights reserved.

© This is an open access article distributed under the terms of the Creative Commons Attribution Non-Commercial License (<http://creativecommons.org/licenses/by-nc/3.0>) which permits unrestricted non-commercial use, distribution, and reproduction in any medium, provided the original work is properly cited.

rosis, intimal proliferation and luminal irregularity on angiography by six months [8].

## LEFT INTERNAL THORACIC ARTERY USE

Green's report stimulated ITA use at two sites in Europe (Karolinska Institute in Stockholm and Gasthuis University in Belgium) and multiple sites in North America. Follow-up coronary angiography was relatively common in the early years of coronary surgery and revealed one year patency of 89% to 99% [9]. However there was not widespread enthusiasm for this conduit: harvest time was long and iatrogenic conduit injury occurred; conduit spasm was recognized and resulted in diminished flow; the ITA was more fragile than saphenous vein and the anastomosis technically difficult so that there was a definite learning curve [9]. Most but not all surgeons adapted surgical loupes while the operating microscope was rarely used except by Green. Later it was demonstrated that most graft failures occurred in the first year reflecting conduit injury, technical errors and occasionally competitive coronary flow so that grafts patent at one year had a 97% patency at a mean of 64 months [10].

Two important reports in the mid 1980's revealed patency and survival advantage for the left ITA. Ten year patency was 85% for the ITA and 40% for saphenous vein [11]. Ten year survival was significantly better for patients having the left ITA grafted to the left anterior descending (LAD) coronary with vein grafts for other vessels, than in patients having only vein grafts [12]. Additionally there was greater freedom from ischemic events and reintervention with use of the ITA [12]. These two papers initiated a pendulum swing toward wider application of the left ITA. Two surveys revealed that 5.7% of US surgeons at least occasionally used the ITA in 1975 and 13% in 1980. By 1990 the Society of Thoracic Surgeons database revealed that ITA was used in 65% and by 2010 in more than 90% of patients having coronary artery bypass (CAB). Use of the left ITA for the LAD became the "standard operation" world-wide but bilateral ITA grafting occurred in only 4% of CAB patients in the US is well below that in other countries [13].

## LEFT INTERNAL THORACIC ARTERY HARVESTING

Exposure is achieved with a spreading or table mounted retractor and appropriate positioning of the table. The table mounted retractor provides the best exposure by virtue of its ability to elevate the sternal leaf but at slightly greater risk of sternal fracture, costochondral separation or brachial plexus stretch injury caused by too vigorous sternal elevation. Costochondral separation is most common and usually involves one or two ribs, requires no treatment and is not associated with significant postoperative pain. A sternal fracture is usually secured by standard closure but overlapping figure of eight wires is appropriate for all closures and the most secure. Fracture is more common if the sternal incision is not midline with a thin left sternal leaf and more than one fracture may occur which requires a vertical Robicsek weave to reinforce the sternum [14].

In the early years some surgeons used blunt and sharp dissection to harvest a 2 cm wide pedicle, extending from the sternal edge laterally, of pleura, endothoracic fascia and venous comitantes. I was concerned that electrocautery dissection might injure the artery so I did not use it for the first decade but the transition to bilateral ITA grafting pushed me to use cautery to shorten harvest time, which it did. To avoid conduit injury it is important to use a low power current (range, 10 to 20 watts). The artery may be injured by grasping it with forceps or by retracting on the artery too vigorously with forceps even though they are placed on pedicle tissue and not the artery itself. Some ITA's have diffuse intimal thickening, most often in diabetics, and are more vulnerable to traction injury which is associated with intimal fracture creating an intimal flap which may restrict flow or initiate a subintimal dissection which is a lesion specific to the ITA and not seen with other arterial conduits.

ITA branches are suitably controlled by several techniques. Placing two clips and cutting between them is laborious and tedious. A proximal clip or ligature and distal cautery division is preferred by some. I prefer cautery division which is expedient but care must be taken to divide larger branches slowly as rapid division may not coagulate the vessel fully

and fail to achieve persistent hemostasis. A divided branch may immediately spasm down and appear hemostatic but will later relax and bleed if the lumen is not obliterated by coagulation.

Dissection is initiated in the middle third to expose the large medial vein which becomes a guide to the laterally adjacent artery. With this landmark identified the dissection is continued proximal and distal to gain wider exposure and then to expose the intercostal fat pads and the intervening cartilages. The fat pad is dissected anteriorly from the intercostal muscle using the cautery blade with and without power. The flat cautery blade works well as a dissector with the current off to allow teasing the anterior surface of the artery from the costal cartilage. Arterial branches are best exposed as they leave the fat pad to enter the intercostal muscle anteriorly and laterally where they are easily divided with cautery well away from the ITA to avoid thermal injury. When the distal dissection reaches the bifurcation I prefer to divide each branch (musculophrenic branch and superior epigastric artery) between clips to preserve the bifurcation and obtain maximal length which occasionally is important. It is expedient to divide the ITA at this time rather than return to it later. Some want to have the patient heparinized before dividing the ITA but I do not. Others divide the ITA later (on initiation of cardiopulmonary bypass or immediately before the distal anastomosis) but I have not seen problems with ITA thrombus unless there has been surgical injury to the ITA. Heparin given at this early stage may result in more bleeding during the remainder of the dissection and particularly if bilateral ITA harvest is planned.

Distal division allows the pedicle to fall posteriorly to a greater degree which facilitates proximal dissection, but is not a necessity, to reach the subclavian vein with the ITA passing posteriorly to it. Dissection is continued proximally and the pedicle continues to fall posteriorly and will lie parallel to the phrenic nerve which must be visualized at this time as it courses anteriorly from its mid-lateral mediastinal position on the pericardium. The phrenic nerve can be injured as it approaches the ITA to lie posteromedial to it. At the thoracic inlet the nerve may have any possible relationship to the ITA but always passes from lateral above the thoracic inlet to medial below [15]. The internal thoracic vein joins the sub-

clavian vein and is usually not divided although it may be. Additional ITA length can be gained by dividing the vein and dissecting the ITA from the subclavian vein when more ITA length is required as this maneuver can add up to 3 cm of length [16]. This length is gained by greater posterior positioning of the proximal ITA which normally is an anterior structure while its destination, usually the LAD, lies posterior to the *in situ* ITA, even though the LAD is an anterior structure on the heart. These details can be very important when length is an issue such as with a longitudinal thoracic cavity which positions the heart away from the thoracic inlet; when the ITA is used as a sequential graft to the diagonal artery and LAD; or when the ITA is used as a (composite) T-graft which may necessitate greater posterior positioning to allow the branch graft to reach very distal targets such as the posterolateral or posterior descending arteries, or both. Thus the surgeon must anticipate various grafting options and focus on having adequate conduit length to fit anatomic vagaries and preserve as many options as possible until the operation is completed.

Skeletonization was initially utilized in an effort to improve sternal blood flow after bilateral ITA harvest and reduce the incidence of mediastinal infection. It was also found to increase conduit length and in some reports free flow was greater [16]. With increasing experience and facility some surgeons expanded this technique to single ITA harvest. The pleura over the medially positioned vein is opened sharply and the lateral edge is retracted inferiorly to expose the ITA which is dissected bluntly in combination with low current electrocautery or ultrasound. Branches are controlled with cautery, ultrasound or clips as the dissection continues to the ends of the vessel as described above. Some have used a modified technique to include the medial internal thoracic vein with the artery.

## LEFT INTERNAL THORACIC ARTERY ROUTING

The shortest route from the thoracic inlet to the LAD is parallel to the phrenic nerve so it is logical to position the artery adjacent to it until the artery enters the pericardial space which is achieved by incising the pericardium trans-

versely, from its midline opening, across the pulmonic valve to within a centimeter of the phrenic nerve. Occasionally the phrenic nerve lies more anteriorly in which case the nerve can be dissected off the pericardium to allow posterior extension of the incision which may be combined with an extension of the incision caudad and parallel to the nerve to achieve an optimal (more posterior) pericardial entry. Granted that frequently the ITA has sufficient length to reach its target without these simple maneuvers but this is not always the case and inflation of the lung may result in excessive tension on the ITA pedicle which is not intrapleural and adjacent to the phrenic. There is another very cogent reason for intrapleural positioning which has to do with the possibility of future reoperation. If the ITA is not intrapleural it is always pushed toward or usually to the midline by the left lung. When intrapleural the lung pushes it against the mediastinum and there is virtually no change in its position from that noted before the lung is inflated and therefore no change in its effective length. When the lung is inflated after completion of the cardiac portion of the operation it may insinuate itself under the ITA and create significant tension on the graft as the anesthesiologist vigorously expands the lung which may damage the anastomosis. An observant anesthesiologist will be aware of this potential mishap and warn the surgeon that the lung is about to be inflated. At reoperation the intrapleural ITA is not at risk of injury until the left side of the heart is being mobilized from the pericardium in which case the dissection should be from the apex toward the base to encounter the LAD which will then guide the surgeon to the anastomosis and further dissection of the ITA undertaken if needed. When the ITA is not positioned intrapleurally it will lie in the mediastinum adjacent to the aorta, or even adherent to it, and is difficult to locate because of mediastinal fat, in which there are few landmarks to guide dissection. It is at risk of injury as it courses to the LAD from this medial and anterior position. This profound medial deviation of the course of the left ITA can be appreciated on a chest radiograph if the branches have been clipped and are in distinct contrast to the straight course of the intrapleural ITA. Some surgeons prefer to make an isolated incision in the pericardium immediately anterior to the phrenic nerve for passage into the pericardium which achieves the same intrapleural positioning. With T or

Y grafting the anastomosis may lie at or near the point of pericardial entry and it is preferable to have visual and physical access to this site by having the pericardium open rather than having a small, separate incision.

## PHARMACOLOGIC MANAGEMENT

Although harvest induced spasm is prevalent it usually resolves by the time of anastomosis. Spasm in vein grafts is resolved with hydrostatic dilation which in the ITA may cause endothelial injury and wall edema or even intimal rupture and dissection, and is contraindicated. However, many surgeons utilize spasmolytic therapy and much has been written about this whether topical, intraluminal or systemic. Most common is topical papaverine diluted in saline and sprayed on the pedicle during dissection and/or after dissection, or wrapping the ITA pedicle with a laparotomy sponge moistened with the same solution. Others inject the papaverine solution into the perivascular tissue. I prefer intraluminal papaverine (0.5 mg/mL in heparinized blood) in a volume of 3 to 5 mL and placing a soft, disposable bulldog clamp distally to allow arterial pressure to dilate the artery [17,18]. Temporary cannulation without a ligature using a 2 mm olive tipped plastic cannula will usually suffice but a small ITA may require a 1 mm olive tipped metal cannula. This must be done carefully because any intraluminal intervention on the ITA has the potential to damage the intima and cause dissection which commonly precludes use of the conduit. Papaverine as packaged is highly acidic and diluted in saline (1 mg/mL) has a pH of 3.5 to 5.0 which is safe for general use but not intraluminal injection which would damage endothelium. Placed in blood it is buffered to a pH of 7.2 to 7.3 which is not injurious to endothelium.

Spasmolytic therapy is important to assure optimal graft flow on clamp release even though physiologic spasmolysis will frequently occur with minimal surgical trauma and healthy endothelium producing nitric oxide. If not there may be hypoperfusion at the critical time of reperfusion and discontinuation of cardiopulmonary bypass. The surgeon may also be faced with the dilemma of low free flow in a conduit prior to the anastomosis and uncertainty as to whether the cause is spasm or an intimal dissection/flap? If spasm it will

respond to pharmacotherapy but an intimal injury will not. Mills and Bringaze [17] recommended a free flow of 200 mL/min before using the ITA. I am comfortable with 50 mL/min or even 25 mL/min for a 1.5 mm distal ITA in a small patient and frequently an eyeball reading of the vigor of flow from the conduit will suffice. If there is concern about flow adequacy a timed collection (range, 30 to 60 seconds) is made and if flow is not appropriate additional vasodilator therapy indicated to achieve adequate flow before proceeding. Blood pressure must be in a physiologic range when measuring flow.

Nitroglycerin, nitroprusside, amlodipine, nifedipine, verapamil, and milrinone are vasodilators used by some but I have no personal experience with them [19-22]. They may be used intraoperatively, both systemically and locally, and also postoperatively. Postoperative spasm of the ITA is rare and has been associated with the also rare complication of coronary spasm which may be a manifestation of physiologic stress causing release of catecholamines, sympathetic hyperactivity, and/or iatrogenic use of vasoconstrictors.

#### LEFT INTERNAL THORACIC ARTERY TO LEFT ANTERIOR DESCENDING GRAFTING

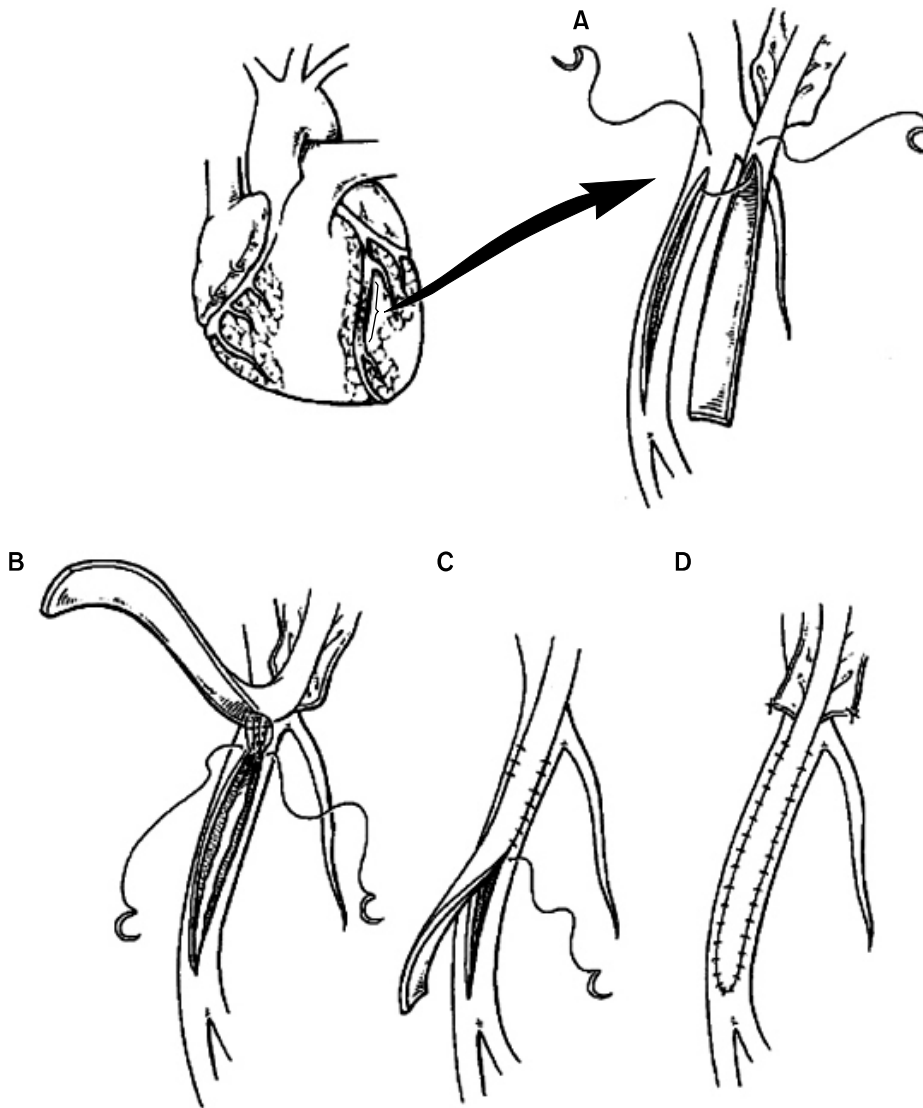
The left ITA grafted to the LAD has become the 'gold standard' because of patency and durability to which all other grafts and targets are compared. There are few contraindications to this configuration and age is not one. Emergency situations or hemodynamic instability may not allow time for harvest. Prior chest wall radiation may result in periarterial fibrosis or even direct injury to the ITA. In the first decade of experience it was not uncommonly said that the ITA was too small or that free flow was insufficient which usually represented harvest spasm or injury to the artery from harvesting trauma. Although a relative contraindication to bilateral ITA harvest because of the increased risk of mediastinal infection, morbid obesity combined with diabetes will deter most surgeons. Lesser obesity when combined with an unfavorable (short) bodily habitus provides poor exposure because the short sternum does not elevate well.

The ITA is transected just proximal to the bifurcation and

adequacy of free flow confirmed. Anastomotic site is selected on the basis of angiography, visualization and palpation which may require extensive exposure (dissection) to find the optimal site(s). Frequently the LAD is visible over much of its middle and distal thirds with the proximal third hidden by cardiac fat which occasionally covers most or all of the artery; with the latter even finding the artery may be challenging and often a bit of luck is helpful. When initial exploration does not reveal the artery a diagonal branch can be dissected retrogradely to the LAD or the LAD may surface distally, at or near the ventricular apex, and be traced proximally.

It is not rare for the LAD to be submuscular, often in the middle third but also more extensively, and if not visible distally it may be located as described above. There may be only one diagonal and if it is proximal it will lead to the LAD at a point which is too proximal for the anastomosis so that the LAD must be traced distally by dividing the overlying fat and/or muscle. This may create what I call a "trench" because the anastomosis is literally in a trench which can be technically challenging. After the anastomosis it is important to close the epicardium of the fatty trench with 6-0 polypropylene to control venous bleeding in the trench which will stop with this closure after protamine is given. If this is not done controlling venous bleeding at the end of the operation can be difficult and frustrating. I do not close the epicardium of the submuscular portion of a trench.

Interestingly the wall of the submuscular LAD is thinner and more fragile and also usually free of atherosclerosis and for this reason an optimal anastomotic site. The thickness of the overlying muscle can vary from 1 to 5 mm. The submuscular LAD is positioned over the intraventricular septum but lies on the right side where it may be adjacent to the endocardium of the right ventricle which can be inadvertently entered during dissection to expose the artery. Repairing such an entry has been problematic and several techniques have been reported using supported sutures placed beneath the LAD to incorporate right and left ventricular muscle and epicardium. I believe this approach is overkill, having used it several times, and it is possible that septal arteries might be occluded or damaged. The optimal strategy is immediate recognition and direct repair of the endocardial rent with fine



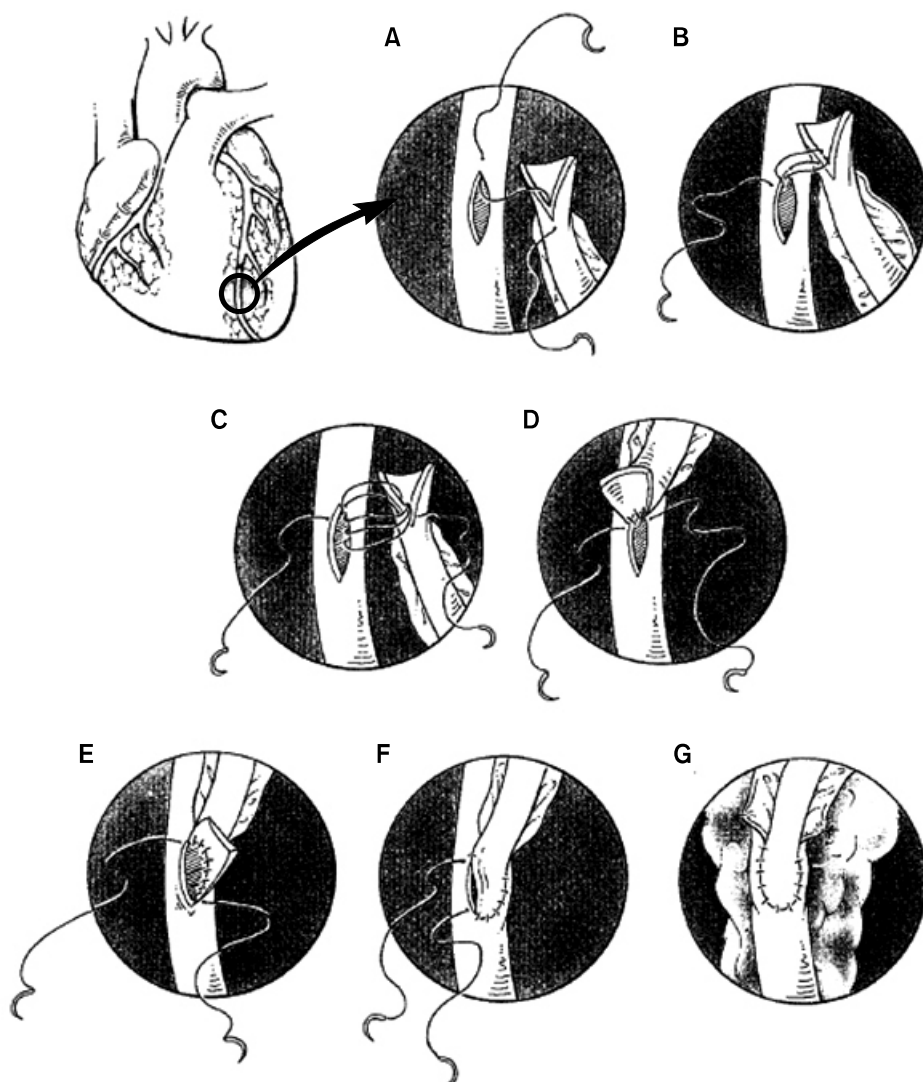
**Fig. 1.** An angioplasty anastomosis requires an incision extending proximal and distal to a plaque to provide proximal and distal flow when there is a second more proximal lesion restricting inflow (A). After placing five or more suture bites at the heel the suture line is tightened and the far side of the anastomosis completed followed by the toe and the near side (B-D) (Reproduced from Edmunds LH. Cardiac surgery in the adult. New York: McGraw-Hill; 1997, with permission from the McGraw-Hill Companies) [23].

suture (6-0 polypropylene) which works because the endocardium is the strongest layer to the myocardium. If the repair is secure and the surgeon confident with it the coronary anastomosis can be made at this site; alternatively the bridging myocardium over the LAD is re-approximated to reinforce the direct endocardial closure and the anastomosis made proximal or distal to this site.

Selection of the anastomotic site determines preparation of the ITA by shortening if appropriate, exposing 5 to 10 mm of artery and making a posterior incision of 2 to 3 mm for a 4 to 5 mm coronary arteriotomy. Occasionally it is appropriate to make a long arteriotomy, up to 20 mm or more, when it is necessary to bridge a long coronary lesion (Fig. 1)

[23]. The latter is useful when there is a proximal lesion and a more distal but significant stenosis which warrants treatment with the options of sequential anastomosis to the LAD or a long (angioplasty) anastomosis. The latter is generally faster because the lateral portions of an anastomosis can be performed rapidly compared to the more critical toe and heel which require more care and time. Many surgeons are not comfortable with sequential anastomosis using arterial conduits so the angioplasty anastomosis is the obvious choice for them and does not add complexity to the procedure.

The suture, 7-0 or 8-0 polypropylene, begins several bites to the patient's right of the heel and is continued clockwise through the heel in a parachute fashion before tightening the



**Fig. 2.** In this anastomosis the suture line is initiated at the mid-point of the heel (A) and three bites taken toward the surgeon (B) and three bites taken away from the surgeon (C) and the suture line tightened (D). The far side of the anastomosis is made (E), then the toe (F) before completing the near side (G) (Reproduced from Edmunds LH. Cardiac surgery in the adult. New York: McGraw-Hill; 1997, with permission from the McGraw-Hill Companies) [23].

suture and continuing clockwise through the toe and back to the starting point (Fig. 2) [23]. Prior to completion gentle probing of 5 to 10 mm, with a coronary sized probe, in both directions will ascertain that there is no anastomotic stenosis. The soft bulldog is released to check for hemostasis and then reapplied unless it is appropriate to release the cross clamp at this time. The pedicle is tacked to the epicardium with fine sutures placed at each distal corner of the pedicle to reduce tension and avoid angulation at the anastomosis.

When ventilation is resumed the surgeon must observe the pedicle and the lung to prevent the lung from coming beneath the pedicle and lifting it which, if the anesthesiologist is not paying attention, can create sufficient tension on the

pedicle to tear the anastomosis. When positioned correctly the lung will come over the pedicle which lies adjacent to the phrenic nerve without creating tension on the pedicle during the respiratory cycle. If tension is noted on the pedicle (by palpation with one finger so as to not displace the lung) it can be lengthened as described above. The pedicle is checked for torsion immediately before making the anastomosis but if per chance it is noted at this time a judgment must be made as to whether it is tolerable or whether the anastomosis must be redone. If there is redundancy without tension it is safe to leave an inadvertent 360 degree torsion. If it must be corrected it is possible to redo the distal anastomosis or the ITA can be divided proximally and anastomosed directly to the

aorta or via the hood of a vein graft. This decision is based on various considerations such as the tolerance of the myocardium to additional ischemia and the quality of the LAD and the aorta for anastomosis. The definitive position of the ITA pedicle must be confirmed after protamine is given so that it remains paramediastinal with the lung over it rather than mediastinal where it may have been pushed by the lung and will remain to be at risk of injury during closure as well as at reoperation. Once protamine is given and clotting occurs all grafts become definitively fixed and will remain so unless the surgeon repositions them.

## SEQUENTIAL GRAFTING

Although sequential grafting was employed early in the history of vein grafting there was reluctance to apply this technique to the ITA because of its small size, fragility, concern over flow capacity and fear that a technical error would compromise distal flow into what is usually the most important of the two anastomoses. The first two and the last concerns could seemingly be overcome by technical excellence and experience and the third was answered by success of left ITA grafting for very high-grade, proximal LAD lesions in which flow would be delivered to both the LAD and diagonal arteries as with a sequential graft. After seven sequential grafts were followed 4.5 years and five patients had elective coronary angiography showing all anastomoses were patent it was deemed prudent to proceed with routine use of this configuration as dictated by coronary anatomy and concomitant disease [24]. Use of this technique was expanded to sequential LAD-LAD, diagonal-diagonal-LAD and to other vessels (ramus intermedius and obtuse marginal).

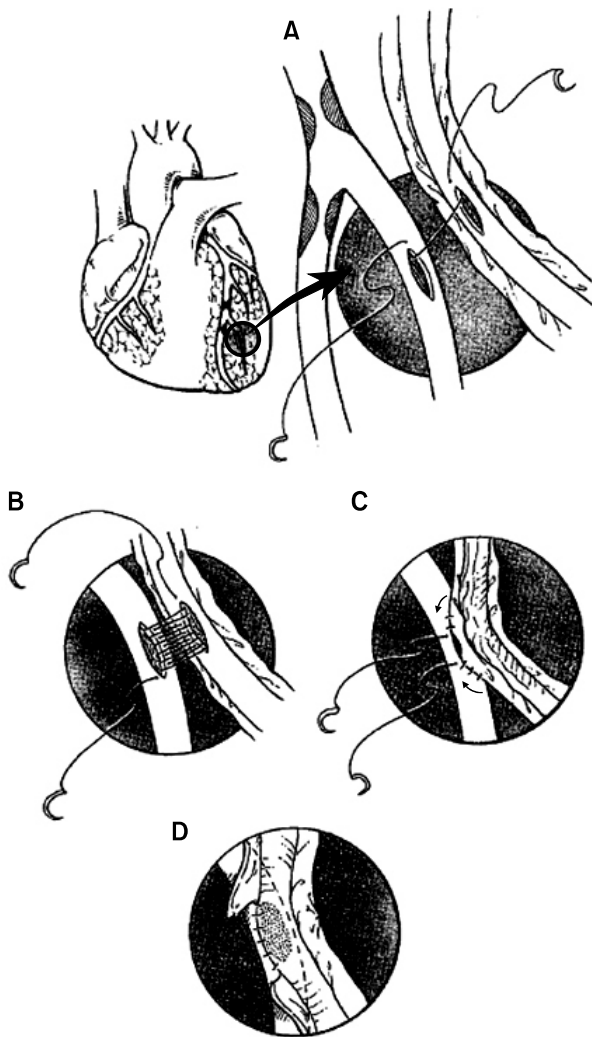
A side-to-side anastomosis to a very proximal diagonal, ramus or marginal artery can be problematic as the anastomosis lies posterior to the pericardial incision and the ITA must loop over the pericardial edge to reach the anastomotic site and achieve a parallel approach which may require a significant length of vessel and not leave adequate length for the ITA to curve anteriorly and reach the LAD. Thus, it may be appropriate to graft the left ITA to the ramus and marginal arteries sequentially and graft the LAD with a free right ITA (from the aorta or as a composite graft from the left ITA) or

as an *in situ* right ITA. Adequate length may also be a problem when the diagonal lesion is more distally located so that the anastomosis lies further from the LAD and a greater length of ITA is required. A similar problem arises when the diagonal makes a broad angle with the LAD and if a parallel anastomosis is made the length of ITA needed to curve back to the LAD is substantially increased if acute angulation of the ITA at the distal extent of the side-to-side anastomosis is to be avoided.

Alternatively the distal ITA is amputated, the end of the ITA grafted to the LAD, and the free segment grafted to the diagonal and end-to-side to the ITA. This usually requires 2 cm of graft which is less than required for a sequential anastomosis in which the ITA must travel laterally and then return toward the midline. Occasionally anatomy and pathology are such that the side-to-side anastomosis would lie distal to the end-to-side in which case the first anastomosis is to the LAD and the end anastomosis is to the diagonal.

Technically the anastomosis is usually parallel because crossing anastomosis is problematic with a small diameter conduit but feasible if the conduit is larger, at least 2.5 to 3.0 mm. The 3 to 5 mm incisions (slightly smaller for a crossing anastomosis) can be made 10 to 30 degrees off midline to facilitate graft position and reduce angulation at the toe of the side-to-side anastomosis as the ITA must curve back to the LAD. The heel, left side and toe of the anastomosis (using 7-0 polypropylene) is initiated at the heel and accomplished in a parachute fashion with the two structures positioned side-by-side 1cm apart and the suture tightened after completion of the toe (Fig. 3) [23]. Tightening of a long suture line can be frustrating without a plan. The 4th to 6th suture loop (counting from the starting point) can be pulled up and the heel sutures usually come down. The loop which was pulled up can usually be tightened by pulling on the free suture at the heel and if not the loop must be moved in the opposite direction by pulling the third suture bite toward the toe and repeating this step as needed through the toe. After the suture line is tightened through the near side of the anastomosis is completed. Tacking sutures are placed from pedicle to epicardium at the toe and heel to prevent angulation and at the heel to counter anterior tension on the anastomosis which may exist depending on whether the proximal pedicle is re-





**Fig. 3.** This side-to-side anastomosis requires incisions of equal length with positioning of the internal thoracic artery 10 to 15 mm away and parallel before placing the initial suture at the mid-point of the heel (A). The posterior (far side) suture line is completed and carried through the toe before tightening the suture line (B) which must be done in an organized fashion by pulling, from the outside, the fifth suture loop from the starting point. When this is snug pull the free heel suture to tighten the heel suture loops then tighten every third suture loop to the toe. Take 2 to 3 bites on the adjacent side of the toe (C) and use the heel suture to complete the anastomosis (D) (Reproduced from Edmunds LH. Cardiac surgery in the adult. New York: McGraw-Hill; 1997, with permission from the McGraw-Hill Companies) [23].

dundant enough to fall posteriorly which is the ideal to avoid tension on the anastomosis. Of particular concern is if this anastomosis lies posterior to the edge of the pericardium that

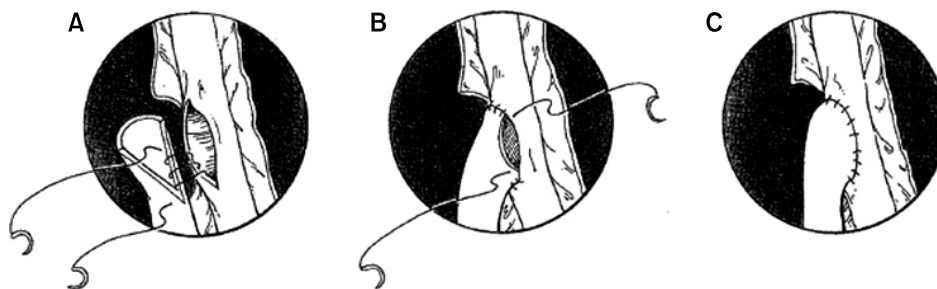
as the heart is returned to the pericardial space the anastomosis may engage the edge with loosening or tearing of the anastomosis which is countered by placing a lateral tacking suture from the pedicle to the epicardium at the midpoint of the anastomosis and/or by further incising the pericardium to prevent impingement.

### RIGHT INTERNAL THORACIC ARTERY BACKGROUND

As experience with the left ITA accrued there was occasional use of the right, independently or in combination with its counterpart. Because most surgeons did not believe that the left ITA had particular advantage over vein grafts there was little interest in the right. An early report of bilateral ITA grafting was associated with increased mediastinal wound infection and 30 day mortality [25]. However, by the early 1980's 10 year data began to appear demonstrating superior patency for the ITA over vein and the landmark paper showing a survival advantage for the left ITA over vein grafts in 1986 [11,12]. This stimulated interest in use of the ITA, but as indicated above surgeons were reluctant to begin using the left, much less both ITA's except for a few groups. In the 1990's another Cleveland Clinic report revealed survival advantage for two ITA's over one, but even by 2010 less than 10% of patients were receiving bilateral grafts in the US [13,26].

### RIGHT INTERNAL THORACIC ARTERY HARVEST

In the first 15 years the right ITA was harvested with the same technique as the left but a several fold increase in mediastinal infection with bilateral harvest resulted in techniques which were less traumatic to the chest wall and better preserved its vascularity. The ultimate application being skeletonized dissection of the artery incorporating ultrasonic dissection, control of branches using clips or ultrasound and minimal or absent use of electrocautery to preserve collateral blood flow to the chest wall [27]. These modifications were shown to not harm the conduit and extend its length by 1 to 3 cm as attachment to the pedicle restricted its length



**Fig. 4.** A 3.0 mm incision in the left internal thoracic artery (ITA) is matched by a smaller incision in the right ITA for end-to-side anastomosis beginning at the heel (A) and continuing through the toe (B) and continuing to the starting point (C) (Reproduced from Edmunds LH. Cardiac surgery in the adult. New York: McGraw-Hill; 1997, with permission from the McGraw-Hill Companies) [23].

[16,28]. The latter is particularly important for the right because its usual targets (right coronary/posterior descending or left sided targets) lie further from the thoracic inlet, and the aorta as well, than do usual targets of the left ITA. Likewise proximal dissection to the fullest extent is routine and includes division of the internal thoracic vein which has a more medial course than on the left as it joins the subclavian vein at its junction with the innominate vein. The right ITA is also dissected from the subclavian vein and phrenic nerve whether used *in situ* or as a free graft. Additional length can be achieved by dissection of the superior epigastric artery up to 2 cm which is suitable for anastomosis in many patients.

## RIGHT INTERNAL THORACIC ARTERY GRAFTING

In contrast to left ITA grafting to the LAD, which is virtually automatic, there are many options for the right. A very logical choice is grafting the second most important coronary, assuming the LAD is the most important, which is defined by artery size and health of the subserved myocardium. Some have suggested that both ITA's should always be grafted to the left side of the heart but the weight of evidence supports the first option [29].

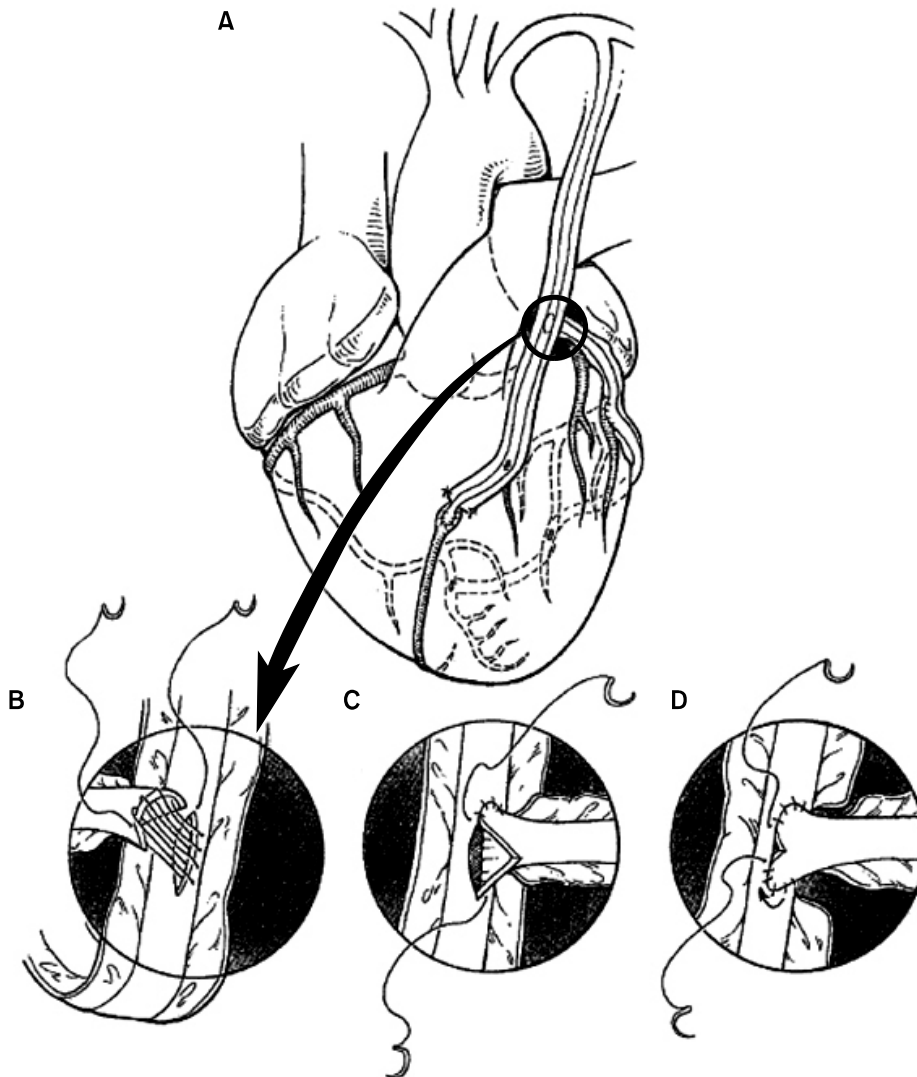
When the right coronary is chosen this usually means the posterior descending artery because there is frequently bifurcation disease or will be in the future. About 50% of the time the *in situ* graft will reach the posterior descending artery so that free grafting from the aorta may be necessary and if a posterolateral branch is to be grafted it is almost al-

ways necessary.

If the left ITA is not available or is used for the circumflex artery the right ITA can reach the LAD as an *in situ* graft or as a free graft from the aorta or from the left ITA as a Y-graft. The *in situ* approach is avoided by many because of the difficulty of avoiding injury to it if repeat sternotomy is needed.

Grafting the circumflex system can be accomplished by routing the *in situ* right ITA through the transverse sinus but frequently only the first marginal artery is reachable. A free right ITA from the aorta will reach more distal branches but I believe the best option is its use as a composite Y-graft from the left ITA (Fig. 4) [23] which was promoted by Calafiore et al. [30]. Tector introduced the T-graft (Fig. 5) [23] which differed from the Y-graft only by making multiple distal anastomoses with the right ITA, including the posterior descending artery and sequentially to other branches if desired [31]. Although Tector's experience is large this complex technique has not been widely adapted [32]. Both of these approaches had been reported by Sauvage et al. [33] in 1986 with later 12 year follow-up.

Anastomosis of the ITA to the aorta historically has been associated with a 5% to 10% loss of patency which has improved to 1% to 2% currently. Anastomosis of a small caliber conduit to a large, thick walled structure is problematic because the small diameter requires a small punch (range, 3 to 4 mm) and intima-to-intima approximation is lacking. If there is excessive scar formation or endothelial hyperplasia during healing the aortic opening can become stenotic or even close. Thus, if there is an associated vein graft it is



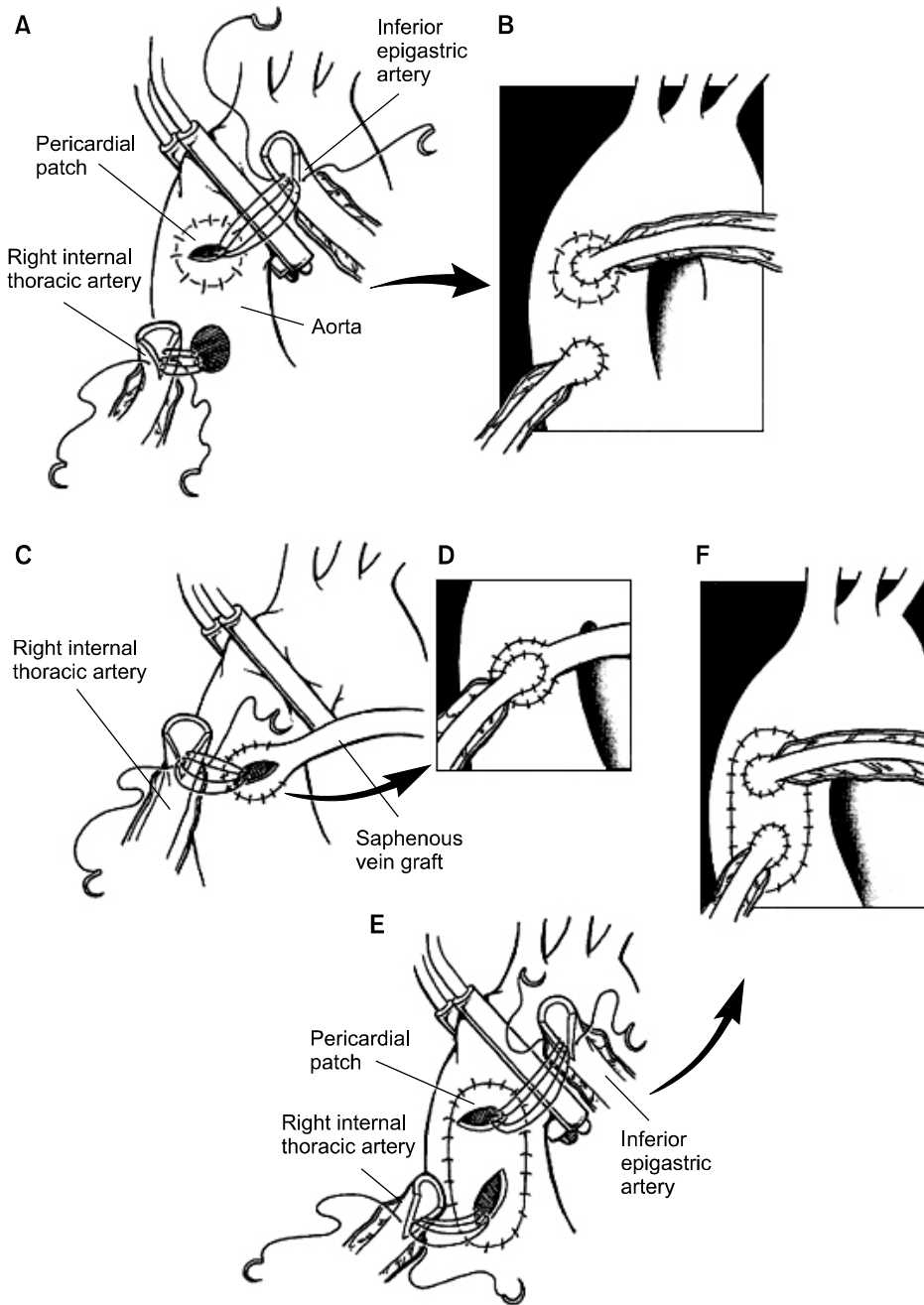
**Fig. 5.** This “T” anastomosis described by Tector is completed before cannulation and is positioned on the posterior (smooth side) aspect of the left internal thoracic artery (ITA) at the level of the left atrial appendage with the right ITA grafted to the obtuse marginal, the left posterolateral and the posterior descending arteries while the left ITA supplies a diagonal and the anterior descending arteries (A) (Reproduced from Edmunds LH. *Cardiac surgery in the adult*. New York: McGraw-Hill; 1997, with permission from the McGraw-Hill Companies) [23].

preferable to attach the arterial graft to the hood of the vein (Fig. 6) [23] which is a “privileged site” and for uncertain reasons protected from atherosclerotic deterioration. If there is no vein graft and the aortic wall is diseased or even thickened resection of the aortic wall to create a 15 mm circular or 10 by 20 mm rectangular defect into which a pericardial or vein patch is sutured (4-0 to 6-0 polypropylene) is effective (Fig. 6) [23]. The graft is attached after punching a small hole or an incision in the patch (6-0 or 7-0 polypropylene) [34].

Although composite grafting with arterial conduits as popularized by Calafiore has been adapted by many surgeons, most have not embraced the T-graft which requires complex

sequential grafting and may not provide adequate flow particularly to the most distal anastomosis. Calafiore avoids sequential anastomosis by using multiple Y branches which may require additional arterial conduits (radial, gastroepiploic, and inferior epigastric arteries). All of these complex techniques require ultimate technical skills, a thorough understanding of the principle involved and an appreciation of blood flow dynamics with routine measurement of conduit flow using the transonic flowmeter.

The location of the conduit-to-conduit anastomosis is frequently critical to achieve optimum length for both limbs. A position over the left atrial appendage corresponds to the point at which the left ITA enters the pericardial space near



**Fig. 6.** Direct aortic anastomosis, usually with a 3.0 mm punch, is feasible if the aorta is healthy or if diseased, can be facilitated with a pericardial patch placed into a larger opening (A, B). If there is an associated vein graft it is appropriate to attach an arterial graft to the 'hood' of the vein (C, D). Downstream positioning of the anastomosis would expose the arterial graft to progressive vein graft disease while the hood is not usually involved. A larger pericardial patch, 10 by 20 mm, is suitable for anastomosis of two arterial grafts (E, F) (Reproduced from Edmunds LH. Cardiac surgery in the adult. New York: McGraw-Hill; 1997, with permission from the McGraw-Hill Companies) [23].

the apex of the transverse pericardial incision which is the most posterior position of the ITA in its course to the LAD. If the anastomosis is proximal to this point the effective length of the free graft, usually the right ITA, is reduced and if it is distal the left ITA may be pulled posteriorly as it needs to curve anteriorly to reach the LAD and its distal length could be compromised. The anastomosis (7-0 or 8-0

polypropylene) is positioned on the posterior aspect of the left ITA and 3 to 5 mm in length with a 2 mm incision in the end of the right and is most easily accomplished before cannulation with an uncluttered field (Fig. 5) [23]. The anastomosis can be reinforced with adventitial sutures of 7-0 polypropylene at the toe and heel which are potential stress points and is much easier and more effective if the left ITA

has a pedicle the tissue of which can be utilized for reinforcing sutures. Unfortunately if more than one sequential anastomosis is needed it may not be possible to make parallel anastomoses which may require a loop of graft between them and the only option is crossing anastomosis to have adequate conduit length to reach the posterior descending artery. When the graft is secured by multiple anastomoses tacking sutures may not be necessary but a loop between two anastomoses frequently requires them to keep it positioned and prevent anastomotic angulation or even flipping over of the loop which would obstruct flow.

### INTERNAL THORACIC ARTERY GRAFT FLOW

There was early interest in measuring arterial conduit flow because of concern over adequacy of flow with these smaller conduits (compared to vein grafts) which could be ascertained by timed free flow into a calibrated container. Free flow is determined by mean arterial pressure and graft resistance and is always greater than flow measured after grafting which is almost always limited by intrinsic coronary vascular resistance. It was learned that exposure of the graft to papaverine increased free flow and that completion flow (after grafting) was comparable in vein and arterial grafts [17,35]. Later with composite grafting there was renewed interest in measuring both free and completion graft flow and a few reports of late flow measurements confirmed the presence of arterial conduit remodeling [36]. Remodeling may enlarge or diminish the lumen over time depending on flow through the graft [37]. Flowing blood creates shear stress at the endothelial-blood interface which is sensed by endothelial cells that elaborate nitric oxide, a smooth muscle relaxant. Endothelial cells achieve a stable shear stress by the level of nitric oxide released which controls vessel diameter. Diameter can change in seconds through vasoconstriction or vasorelaxation while chronic change in vessel diameter results in structural alterations in the arterial wall termed remodeling. In most instances arterial grafts can meet increased flow requirements by acute vasodilation of 10% to 15% (in diameter) which for a 2.0 mm diameter ITA achieves an increase in cross sectional area from 3.14 mm squared to 3.80 mm squared or 21% for a 10% di-

ameter increase.

This principle is the basis for “flow mediated vasodilation” which is a methodology for assessing the health of arteries generally and particularly endothelium. Inflating a blood pressure cuff on the arm for five minutes causes distal ischemia; deflating the cuff results in a several fold increase in flow above baseline during ischemic reperfusion with resultant dilation of the inflow artery. The change in diameter, which restores shear stress toward control during hyperemia, is measured with an ultrasound probe placed over the brachial or radial artery.

Vein graft flow measurements have had minimal impact on prediction of patency unless graft flow is quite low (<20 mL/min). Flow measurements have had somewhat more success in predicting patency of arterial grafts primarily related to the advent of the transit time flow meter and the ability to analyze several components of flow. Thus, low mean graft flow (<10–15 mL/min), pulsatility index of <3.0, systolic dominant or balanced systolic/diastolic flow curve in the left coronary territory or a systolic dominant pattern flow curve in the right coronary distribution are indicators of less than optimal graft function and has led to successful correction of technical problems in 3% to 7% of grafts studied [38,39].

### GRAFT PATENCY

Patency of 90% or more at 10 years and 88% at 15 years has been reported for the left ITA grafted to the LAD [40,41]. Patency of the right or left ITA to the LAD or first marginal artery is similar whether the graft is *in situ* or free and whether based on the aorta or as a composite graft [40,42]. Targets other than the LAD have slightly reduced patency compared to the LAD [40,41]. Patency of ITA grafts in the face of decreasing coronary stenosis declines gradually without a definite break point for the left coronary system but not the right as discussed below [43]. Female gender and smoking are associated with reduced patency [41]. There is no loss of patency for sequential ITA grafts [44]. Off-pump coronary grafting achieves similar excellent patency with ITA conduits [45].

Competitive coronary flow is associated with reduced arterial graft patency and although there is no critical or break

point for the left ITA to the left coronary system or for the right ITA to the left side this is not true for the right ITA to the right coronary [46]. The apparent reason is that the right coronary is frequently larger than the LAD or the circumflex so that an 80% stenosis of a 5 mm coronary gives a residual lumen of 3.94 mm squared which compares with the lumen of a 2.0 mm normal coronary of 3.14 mm squared. Thus, an arterial conduit with a 2.0 mm distal lumen will deliver less flow than the coronary because of its greater length and therefore resistance. Measuring the residual lumen with bi-plane coronary angiography and using an arterial graft only if the residual diameter is  $<1.1$  mm diameter predicted good patency [46]. However measuring residual lumen is problematic in that even precise angiographic detail cannot compensate for geographically complex lesions, is not usual in most laboratories and there is a physiologic alternative. Fractional flow reserve (FFR) is now well established and routine in our catheterization laboratory for assessing all lesions that do not appear hi-grade and has been established as determining the appropriateness of coronary stenting and predicting better outcomes with a “cut off” of  $<0.8$  [47]. However, here are limited data supporting its validity in predicting graft patency [48]. Thus on an angiographic basis only (without use of FFR) left sided lesions should have 70% stenosis or greater whereas right coronary lesions should be 90% or more, unless the right system is small, to obtain optimal patency with arterial grafts. It is no surprise that the left ITA to the LAD has become the gold standard to which all other grafts and targets are compared from the patency standpoint.

## SURVIVAL BENEFIT

The two landmark studies, which are retrospective and observational, suggest survival benefit for one ITA graft over only vein grafts and for two ITA conduits over one at 10 and 20 years, respectively [12,26]. These data are further supported by meta-analysis and recent observational studies [13,49-52]. One very long observational study of bilateral versus single ITA grafting reversed the negative influence of gender on outcomes [52]. For the first time survival in diabetics with bilateral ITA grafting was equal to that of non-diabetics [50]. Although some reports have suggested that the

second ITA should be directed to the left side of the heart the weight of evidence indicates that the second ITA should be directed to the second best target, after the LAD, without regard to whether it is the right or left coronary system [29,41].

In addition to survival benefit of arterial grafts, and perhaps contributing to it, is the apparent associated benefit of reduced, distal disease progression of 8% to 10% versus 40% in coronaries receiving an arterial graft [53]. It is postulated that this is derived from the functioning endothelium of arterial grafts which is known to be intrinsically more biologically active than vein endothelium and also to be essentially equivalent to the endothelium of healthy coronary arteries. The established properties of nitric oxide in addition to vasodilation include inhibition of platelet aggregation and adhesion; neutrophil adhesion, release and chemotaxis; and inhibition of smooth muscle growth all of which implicate it as a potential inhibitor of atherosclerosis [54].

## MEDIASTINAL INFECTION

Mediastinal wound infection is the bete noire of bilateral ITA harvest which is distressing to all, occasionally results in death and has even been viewed by the US insurance industry as an avoidable complication for which hospitals should not be reimbursed for additional necessary care. Clearly a 1% infection rate is not unacceptable although rates under 1% have been reported for single ITA use. The incidence of sternal infection has been higher (range, 2% to 3%) with bilateral harvest, and higher in diabetics but this has not been statistically significant in some reports and has been improved by skeletonization [13,49,50,55]. Three current reports have observed sternal infection rates of less than 1.0% and in which bilateral ITA harvest, diabetes and age were not observed to be risk factors for this complication [49-51]. One group that is recognized to be at risk for deep sternal infection is the morbidly obese diabetic and most would also add female as a descriptor. Most surgeons intuitively avoid bilateral ITA harvest in this subgroup of patients and some would add the descriptor of having preoperative glycosylated hemoglobin levels greater than 7.5% [50]. It may be that these recent reports of sternal wound infection rates of less

than 1.0% reflect the surgeons avoidance of those patients recognized to be at higher risk for this complication.

## CONCLUSION

It is evident that the ITA is the graft of choice for long term patency, which implies freedom from atherosclerotic degeneration as the goal. After all only continued patency of a graft or stent provides benefit. Employment of the ITA can be simple, like the left ITA for the LAD, or complex and therefore problematic like the ITA T-graft with many shades in between which are distinguished by variables which include surgeon, patient and the disease. Furthermore the process continues to evolve as we learn more, techniques change and improve and long-term outcomes are reported and suggest new directions.

Even today some are not convinced by the apparent favorable results reported for the ITA which are only supported by retrospective analysis and not by prospective randomized clinical trials. In response to this deficiency Taggart et al. [56] have reported one year results of the first such trial comparing one and two ITA grafts.

## CONFLICT OF INTEREST

No potential conflict of interest relevant to this article was reported.

## REFERENCES

1. Sabiston DC Jr. *Direct surgical management of congenital and acquired lesions of the coronary circulation*. Prog Cardiovasc Dis 1963;6:299-316.
2. Garrett HE, Dennis EW, DeBakey ME. *Aortocoronary bypass with saphenous vein graft: seven-year follow-up*. JAMA 1973;223:792-4.
3. Kolesov VI, Kolesov EV. *Twenty years' results with internal thoracic artery-coronary artery anastomosis*. J Thorac Cardiovasc Surg 1991;101:360-1.
4. Vineberg AM, Jewett BL. *Development of an anastomosis between the coronary vessels and a transplanted internal mammary artery*. Can Med Assoc J 1947;56:609-14.
5. Murray G, Porcheron R, Hilario J, Roschlau W. *Anastomosis of systemic artery to the coronary*. Can Med Assoc J 1954; 71:594-7.
6. Barner HB, Kaiser GC, Mudd JG, Jellinek M, Hanlon CR. *Internal mammary artery implantation: effects upon coronary flow and ventricular function*. J Thorac Cardiovasc Surg 1968;56:43-50.
7. Green GE. *Internal mammary artery-to-coronary artery anastomosis: three-year experience with 165 patients*. Ann Thorac Surg 1972;14:260-71.
8. Barner HB, Kaiser GC, Jellinek M, et al. *Aorto-coronary vein graft and internal mammary-coronary anastomosis*. Arch Surg 1972;105:908-11.
9. Barner HB, Mudd JG, Mark AL, Ahmad N, Dickens JF. *Patency of internal mammary-coronary grafts*. Circulation 1976;54(6 Suppl):III70-3.
10. Barner HB, Swartz MT, Mudd JG, Tyras DH. *Late patency of the internal mammary artery as a coronary bypass conduit*. Ann Thorac Surg 1982;34:408-12.
11. Barner HB, Standeven JW, Reese J. *Twelve-year experience with internal mammary artery for coronary artery bypass*. J Thorac Cardiovasc Surg 1985;90:668-75.
12. Loop FD, Lytle BW, Cosgrove DM, et al. *Influence of the internal-mammary-artery graft on 10-year survival and other cardiac events*. N Engl J Med 1986;314:1-6.
13. Kurlansky PA, Traad EA, Dorman MJ, Galbut DL, Zucker M, Ebra G. *Thirty-year follow-up defines survival benefit for second internal mammary artery in propensity-matched groups*. Ann Thorac Surg 2010;90:101-8.
14. Robicsek F, Daugherty HK, Cook JW. *The prevention and treatment of sternum separation following open-heart surgery*. J Thorac Cardiovasc Surg 1977;73:267-8.
15. Sajja LR. *Internal thoracic artery: anatomical and biological characteristics revisited*. Ann Thorac Surg In press 2012.
16. Behranwala AA, Raja SG, Dunning J. *Is skeletonised internal mammary harvest better than pedicled internal mammary harvest for patients undergoing coronary artery bypass grafting?* Interact Cardiovasc Thorac Surg 2005;4:577-82.
17. Mills NL, Bringaze WL 3rd. *Preparation of the internal mammary artery graft: which is the best method?* J Thorac Cardiovasc Surg 1989;98:73-7.
18. Zabeeda D, Medalion B, Jackobshvilli S, Ezra S, Schachner A, Cohen AJ. *Comparison of systemic vasodilators: effects on flow in internal mammary and radial arteries*. Ann Thorac Surg 2001;71:138-41.
19. Formica F, Ferro O, Brustia M, et al. *Effects of papaverine and glycerylnitrate-verapamil solution as topical and intraluminal vasodilators for internal thoracic artery*. Ann Thorac Surg 2006;81:120-4.
20. Dregelid E, Heldal K, Resch F, Stangeland L, Breivik K, Svendsen E. *Dilation of the internal mammary artery by external and intraluminal papaverine application*. J Thorac Cardiovasc Surg 1995;110:697-703.
21. Cooper GJ, Wilkinson GA, Angelini GD. *Overcoming peri-operative spasm of the internal mammary artery: which is*

- the best vasodilator?* J Thorac Cardiovasc Surg 1992;104:465-8.
22. Jett GK, Guyton RA, Hatcher CR Jr, Abel PW. *Inhibition of human internal mammary artery contractions. An in vitro study of vasodilators.* J Thorac Cardiovasc Surg 1992;104:977-82.
  23. Barner HB. *Techniques of myocardial revascularization.* In: Edmunds LH Jr, editor. *Cardiac surgery in the adult.* New York: McGraw-Hill; 1997. p. 481-534.
  24. McBride LR, Barner HB. *The left internal mammary artery as a sequential graft to the left anterior descending system.* J Thorac Cardiovasc Surg 1983;86:703-5.
  25. Barner HB. *Double internal mammary-coronary artery bypass.* Arch Surg 1974;109:627-30.
  26. Lytle BW, Blackstone EH, Loop FD, et al. *Two internal thoracic artery grafts are better than one.* J Thorac Cardiovasc Surg 1999;117:855-72.
  27. Calafiore AM, Vitolla G, Iaco AL, et al. *Bilateral internal mammary artery grafting: midterm results of pedicled versus skeletonized conduits.* Ann Thorac Surg 1999;67:1637-42.
  28. Deja MA, Wos S, Golba KS, et al. *Intraoperative and laboratory evaluation of skeletonized versus pedicled internal thoracic artery.* Ann Thorac Surg 1999;68:2164-8.
  29. Kurlansky PA, Traad EA, Dorman MJ, Galbut DL, Zucker M, Ebra G. *Location of the second internal mammary artery graft does not influence outcome of coronary artery bypass grafting.* Ann Thorac Surg 2011;91:1378-83.
  30. Calafiore AM, Di Giammarco G, Luciani N, Maddestra N, Di Nardo E, Angelini R. *Composite arterial conduits for a wider arterial myocardial revascularization.* Ann Thorac Surg 1994;58:185-90.
  31. Tector AJ, Amundsen S, Schmahl TM, Kress DC, Peter M. *Total revascularization with T grafts.* Ann Thorac Surg 1994;57:33-8.
  32. Tector AJ, McDonald ML, Kress DC, Downey FX, Schmahl TM. *Purely internal thoracic artery grafts: outcomes.* Ann Thorac Surg 2001;72:450-5.
  33. Sauvage LR, Rosenfeld JG, Roby PV, Gartman DM, Hammond WP, Fisher LD. *Internal thoracic artery grafts for the entire heart at a mean of 12 years.* Ann Thorac Surg 2003;75:501-4.
  34. Kanter KR, Barner HB. *Improved technique for the proximal anastomosis with free internal mammary artery grafts.* Ann Thorac Surg 1987;44:556-7.
  35. Barner HB. *Blood flow in the internal mammary artery.* Am Heart J 1973;86:570-1.
  36. Wendler O, Hennen B, Markwirth T, et al. *T grafts with the right internal thoracic artery to left internal thoracic artery versus the left internal thoracic artery and radial artery: flow dynamics in the internal thoracic artery main stem.* J Thorac Cardiovasc Surg 1999;118:841-8.
  37. Barner HB. *Remodeling of arterial conduits in coronary grafting.* Ann Thorac Surg 2002;73:1341-5.
  38. Kim KB, Kang CH, Lim C. *Prediction of graft flow impairment by intraoperative transit time flow measurement in off-pump coronary artery bypass using arterial grafts.* Ann Thorac Surg 2005;80:594-8.
  39. Leong DK, Ashok V, Nishkantha A, Shan YH, Sim EK. *Transit-time flow measurement is essential in coronary artery bypass grafting.* Ann Thorac Surg 2005;79:854-7.
  40. Tatoulis J, Buxton BF, Fuller JA. *The right internal thoracic artery: the forgotten conduit--5,766 patients and 991 angiograms.* Ann Thorac Surg 2011;92:9-15.
  41. Sabik JF 3rd, Lytle BW, Blackstone EH, Houghtaling PL, Cosgrove DM. *Comparison of saphenous vein and internal thoracic artery graft patency by coronary system.* Ann Thorac Surg 2005;79:544-51.
  42. Calafiore AM, Contini M, Vitolla G, et al. *Bilateral internal thoracic artery grafting: long-term clinical and angiographic results of in situ versus Y grafts.* J Thorac Cardiovasc Surg 2000;120:990-6.
  43. Sabik JF 3rd, Lytle BW, Blackstone EH, Khan M, Houghtaling PL, Cosgrove DM. *Does competitive flow reduce internal thoracic artery graft patency?* Ann Thorac Surg 2003;76:1490-6.
  44. Dion R, Glineur D, Derouck D, et al. *Long-term clinical and angiographic follow-up of sequential internal thoracic artery grafting.* Eur J Cardiothorac Surg 2000;17:407-14.
  45. Kim KB, Cho KR, Jeong DS. *Midterm angiographic follow-up after off-pump coronary artery bypass: serial comparison using early, 1-year, and 5-year postoperative angiograms.* J Thorac Cardiovasc Surg 2008;135:300-7.
  46. Glineur D, D'hoore W, de Kerchove L, et al. *Angiographic predictors of 3-year patency of bypass grafts implanted on the right coronary artery system: a prospective randomized comparison of gastroepiploic artery, saphenous vein, and right internal thoracic artery grafts.* J Thorac Cardiovasc Surg 2011;142:980-8.
  47. De Bruyne B, Pijls NH, Kalesan B, et al. *Fractional flow reserve-guided PCI versus medical therapy in stable coronary disease.* N Engl J Med 2012;367:991-1001.
  48. Botman CJ, Schonberger J, Koolen S, et al. *Does stenosis severity of native vessels influence bypass graft patency? A prospective fractional flow reserve-guided study.* Ann Thorac Surg 2007;83:2093-7.
  49. Grau JB, Ferrari G, Mak AW, et al. *Propensity matched analysis of bilateral internal mammary artery versus single left internal mammary artery grafting at 17-year follow-up: validation of a contemporary surgical experience.* Eur J Cardiothorac Surg 2012;41:770-5.
  50. Puskas JD, Sadiq A, Vassiliades TA, Kilgo PD, Lattouf OM. *Bilateral internal thoracic artery grafting is associated with significantly improved long-term survival, even among diabetic patients.* Ann Thorac Surg 2012;94:710-5.



51. Locker C, Schaff HV, Dearani JA, et al. *Multiple arterial grafts improve late survival of patients undergoing coronary artery bypass graft surgery: analysis of 8622 patients with multivessel disease.* *Circulation* 2012;126:1023-30.
52. Kurlansky PA, Traad EA, Dorman MJ, et al. *Bilateral internal mammary artery grafting reverses the negative influence of gender on outcomes of coronary artery bypass grafting surgery.* *Eur J Thorac Cardiovasc Surg* In press 2012.
53. Dimitrova KR, Hoffman DM, Geller CM, Dincheva G, Ko W, Tranbaugh RF. *Arterial grafts protect the native coronary vessels from atherosclerotic disease progression.* *Ann Thorac Surg* 2012;94:475-81.
54. Moncada S, Palmer RM, Higgs EA. *Nitric oxide: physiology, pathophysiology, and pharmacology.* *Pharmacol Rev* 1991; 43:109-42.
55. Sajja LR, Mannam G, Dandu SB, Sompalli S. *Reduction of sternal wound infections in diabetic patients undergoing off-pump coronary artery bypass surgery and using modified pedicle bilateral internal thoracic artery harvest technique.* *J Thorac Cardiovasc Surg* 2012;144:480-5.
56. Taggart DP, Altman DG, Gray AM, et al. *Randomized trial to compare bilateral vs. single internal mammary coronary artery bypass grafting: 1-year results of the Arterial Revascularisation Trial (ART).* *Eur Heart J* 2010;31:2470-81.