

CASE REPORT

SALL4 as an indicator for the diagnosis of hepatoid carcinoma of the ovary: A case report and literature review

Jiana Li^{1,2}  | Xiaohua Wu^{1,2}

¹Department of Oncology, Shanghai Medical College, Fudan University, Shanghai, China

²Department of Gynecologic Oncology, Fudan University Shanghai Cancer Center, Shanghai, China

Correspondence

Xiaohua Wu, Department of Gynecologic Oncology, Fudan University Shanghai Cancer Center, Shanghai 200032, China.
Email: docwuxh@163.com

Funding information

National Natural Science Foundation of China, Grant/Award Number: 81972431 and 82272898

Key Clinical Message

Primary HCO is a rare, aggressive ovarian malignant tumor, morphologically resembling HCC. SALL4 can be adopted to differentiate HCO from HCC. The serum AFP and CA125 rather than HE4 can be employed as possible biomarkers to track treatment and monitor recurrence.

Abstract

We report a case of a postmenopausal woman presenting with lower abdominal pain and vaginal bleeding. She went through a maximal debulking surgery, and the pathological biopsy revealed hepatoid carcinoma of the ovary (HCO). Immunohistochemical assay demonstrates SALL4 as an indicator to differentiate HCO from hepatocellular carcinoma (HCC).

KEYWORDS

diagnosis, HCO, hepatoid carcinoma of the ovary, SALL4, therapy

1 | INTRODUCTION

Hepatoid carcinoma is a rare type of malignant tumor with morphologic characteristics similar to HCC, arising outside the liver, most commonly in the stomach and less in the ovary, uterus, lung, bladder, or kidney.¹ In 1987, Ishikura and Scully first reported five cases of HCO, mainly in postmenopausal women who presented with an ovarian mass and elevated serum AFP.² The microscopic characteristics of these tumors are sheets, trabeculae, and cords of cells with moderate-to-large amounts of eosinophilic cytoplasm and round to oval central nuclei.³ HCO must be distinguished from the HCC metastatic to the ovary⁴ and other ovarian tumors with abundant eosinophilic cytoplasm, including hepatoid yolk sac tumors (HYSTs),⁵ Sertoli-Leydig cell tumors, and oxyphilic clear cell carcinomas. We describe an additional case of

a 64-year-old postmenopausal Chinese woman diagnosed with HCO, featuring with significantly elevated serum AFP and CA125 levels.

2 | CASE PRESENTATION

A 64-year-old postmenopausal female was admitted to our hospital with lower abdominal pain for 3 months and vaginal bleeding for 21 days. Her physical examination revealed the existence of a lower abdominal mass about the size of 8-9 cm in diameter on deep palpation, closely related to the uterus. Obvious tenderness and rebound pain were complained about. Shifting dullness was positive, and a small amount of blood clot was seen in the vagina. The abdominal computed tomography (CT) showed a cystic and solid mass in the right annex and a cystic

This is an open access article under the terms of the [Creative Commons Attribution-NonCommercial](https://creativecommons.org/licenses/by-nc/4.0/) License, which permits use, distribution and reproduction in any medium, provided the original work is properly cited and is not used for commercial purposes.

© 2023 The Authors. *Clinical Case Reports* published by John Wiley & Sons Ltd.

mass in the left annex with a large amount of ascites. The magnetic resonance imaging (MRI) confirmed the same finding of bilateral masses, with thickened and dense peritoneum and mesentery (Figure 1). No obviously abnormal imaging performance in the upper digestive tract, liver, pancreas, or kidney. Laboratory tests showed an elevated AFP level of 3630 ng/mL (normal <10), CA 125 level of 337.9 U/mL (normal <35), and HE4 level of 142.7 pmol/L (normal <81.9). She had a cesarean section 26 years ago and had no family history of any malignancy.

A maximal debulking surgery was arranged under the impression of ovarian cancer due to the patient's willingness to undergo surgery as soon as possible. During the surgery, a right ovarian tumor of 9 × 7 × 4 cm and a left one of 3.3 × 3 × 1.5 cm were discovered with direct invasion to the pelvic peritoneum, uterus, rectum, and mesentery. Multiple solid nodules of 2–3 cm in diameter were palpable in the omentum. A contracted tumor tissue about 6 × 6 × 8 cm in size was found in the sigmoid colon mesentery. A 10 cm section of colorectum presented significant stiffness, thickening, edema, and flatulence, with fixed adhesion to the uterus posterior wall. Radical surgery was performed, including a total hysterectomy, bilateral salpingo-oophorectomy, omentectomy, appendectomy, and pelvic floor peritoneum resection. Additionally, a partial colorectal resection and end-to-end anastomosis were performed and an ileostomy was created. The postoperative pathological results suggested a poorly differentiated adenocarcinoma displaying a hepatoid pattern without yolk sac tumor-like areas. The omentum mass, pelvic peritoneum, rectal and appendiceal mesentery were positive for malignancy, and malignant cells were seen in ascites. All the resected pelvic lymph nodes were negative. The final diagnosis was HCO of stage IIIC.

One month after the surgery, the AFP level of our patient decreased from 3630 ng/mL to 158.5 ng/mL. Then, she was treated with combined chemotherapy of paclitaxel and carboplatin for 9 courses since her serum AFP level continued to decline after six standard courses of chemotherapy. The response was satisfactory, and her serum AFP level returned to within the normal range.

The patient was disease-free for about 1 year, confirmed by MRI and stable serum AFP level. However,

10 months after the last course of therapy, she onset with the symptoms of intestinal obstruction, and her serum AFP was gradually elevated. Her pelvic MRI revealed pelvic effusion and metastasis in the omentum, peritoneum, and mesenteric nodules. Recurrence of ovarian cancer was considered, but we applied palliative treatment instead of the aggressive one due to the high risk of surgery. Chemotherapy was administered with paclitaxel and carboplatin. The patient's AFP level did decrease after the course, but the chemotherapy was terminated after the third course of administration because of the severe adverse reaction (IV-degree myelosuppression). The chest and abdominal CT revealed pleural effusion and a large amount of peritoneal effusion with multiple small nodules in the peritoneum and swollen retroperitoneal lymph nodes. In spite of comprehensive supportive treatment, the patient died of cachexia and multiple organ failure, about 3 years after the initial diagnosis.

The patient's diagnosis, treatment, follow-up, and outcome are presented in chronological order in Table 1. Figure 2 depicts the whole course of disease monitoring using AFP, CA125, and HE4 values.

3 | PATHOLOGY

Tumor tissues were formalin-fixed, paraffin-embedded, and stained with hematoxylin and eosin. Immunohistochemistry was performed on a subset of the sections.⁶ Gross findings showed that the right ovarian of 9 × 7 × 4 cm and the left one of 3.3 × 3 × 1.5 cm were both involved with malignancy. Under the microscope, the cords of hepatoid cells are arranged in thick trabecular structures, with abundant eosinophilic cytoplasm and clear boundaries. The structure was similar to that of hepatocellular carcinoma.⁴ Mitotic images of tumor cells were occasionally observed. The immunohistochemistry staining of AFP was found positive inside the clear cell components and around the tumor cells (Figure 3A). SALL4, P53, AE1/AE3, EMA, CD10, and villin staining were also found to be extensively positive (Figure 3B–D), while Hepa-1, CD10, and HNF1-β were found to be focally positive. CK7, Arg-1, ER, PR, Vimentin,

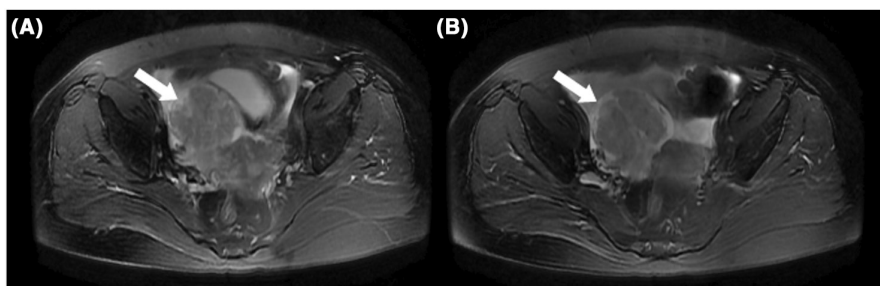
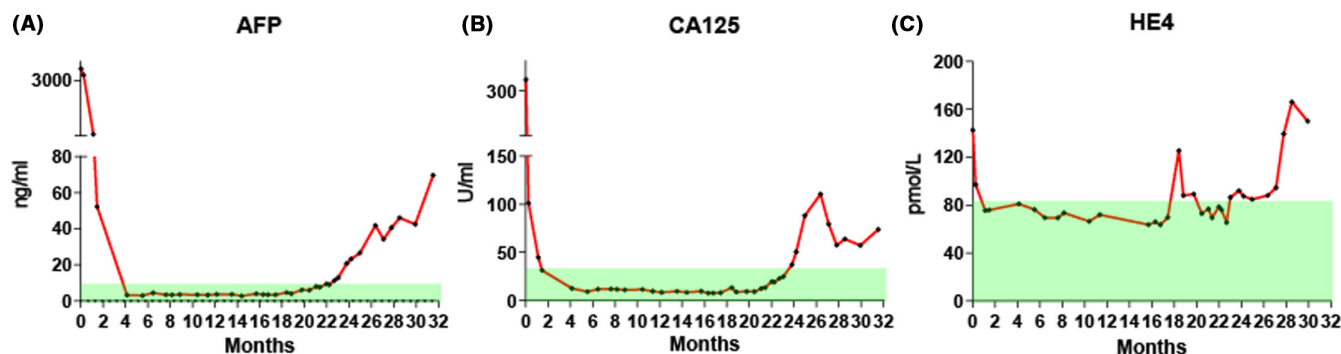


FIGURE 1 (A, B) T2-weighted MRI of the pelvis. MRI showed a cystic and solid mass in the right annex (arrow) and a cystic mass in the left annex with thickened and dense peritoneum and mesentery, and a large amount of ascites.

TABLE 1 Timeline of diagnosis, treatment, follow-up, and outcome of the patient.

Day 0	Initial presentation with lower abdominal pain and vaginal bleeding
3 months	Abdominal CT and MRI revealed bilateral adnexal masses and pelvic effusion
3 months	Laboratory tests showed AFP 3630 ng/mL, CA125 337.9 U/mL, and HE4 142.7 pmol/L
4 months	Maximal debulking surgery
5 months	Discharge from hospital
5 months	Administration of the first course of chemotherapy (paclitaxel and carboplatin)
1 year and 5 months	Administration of the ninth course of chemotherapy (paclitaxel and carboplatin)
1 year and 8 months	MRI showed no sign of recurrence, with serum AFP and CA125 in normal range
2 years	MRI showed no sign of recurrence, with serum AFP and CA125 in normal range
2 years and 3 months	PET/CT showed no abnormal increase in FDG metabolism through systemic imaging
2 years and 4 months	Laboratory tests showed rapidly elevated serum CA125 and AFP
2 years and 5 months	Complaint of abdominal pain, distension, and stop defecating
2 years and 5 months	MRI revealed pelvic effusion and metastasis in omentum, peritoneum, and mesenteric nodules
2 years and 5 months	Start chemotherapy (paclitaxel and carboplatin)
2 years and 10 months	Stop chemotherapy due to severe adverse events
2 years and 11 months	CT revealed pleural effusion and a large amount of peritoneal effusion with multiple small nodules in the peritoneum and swollen retroperitoneal lymph nodes
3 years	Our patient passed away due to cachexia and multiple organ failure

**FIGURE 2** Whole course of disease monitoring using AFP, CA125, and HE4 values.

WT1, CK30, and Napsin A were all observed to be negative. No foci of yolk sac tumor, teratoma, or other malignant germ cell tumors were observed grossly or microscopically.^{7,8} The ultimate histological diagnosis was hepatoid carcinoma of the ovary, a poorly differentiated adenocarcinoma with a hepatoid appearance.

4 | DISCUSSION

Primary hepatoid carcinoma of ovary is a poorly differentiated and aggressive ovarian malignant tumor that originates from an extrahepatic part but resembles hepatocellular tumor in histopathological type and immunophenotype. It is an uncommon tumor type that has now been reported in no more than 50 cases in literature since Ishikura and Scully first designated it in 1987.² (Listed in

Table S1) Patients range in age from 27 to 79 years old, with a median age of 57.1, more common in postmenopausal women.⁶ Most patients have no obvious symptoms in early period and often present with abdominal distention, lower abdominal pain, and a pelvic mass. The tumor mainly involves unilateral ovary and rarely bilateral. Elevated serum AFP is often detected, but there are still several cases exhibiting normal AFP level.^{6,9} Due to the high degree of malignancy, most HCO cases are found in advanced stages, and pelvic and lung metastasis is common.^{10,11} The average survival period after initial diagnosis is about 2 years.¹²

Histopathological characteristics of hepatoid carcinoma of the ovary include microscopically tumor cells arranged in flakes, nests, or trabecular structures; rich in blood sinus, similar to the arrangement of liver cancer cells; containing abundant eosinophilic cytoplasm;

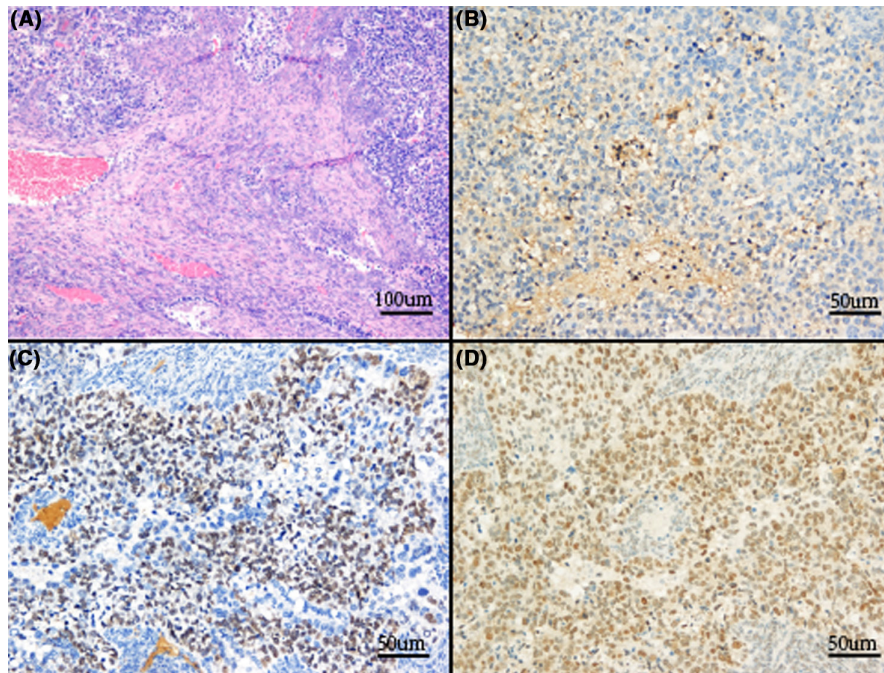


FIGURE 3 (A) (100 \times) H&E staining revealed eosinophilic cytoplasm, round to oval central nuclei resembling hepatocytes, and distinct cell boundaries resembling hepatocellular carcinoma in neoplastic cells. (B, C, D) (200 \times) Positive immunohistochemical stains of AFP, SALL4, and P53.

uniformity of cell size; occasionally with giant bizarre cells and multinucleated tumor cells; and positive hyaline globules inside and outside the cytoplasm.^{13–15} The unique pathologic appearance of HCO must be distinguished from HCC and HYST. Currently, there is no reliable way of laboratory tests to completely rule out HCC unless combined with clinical and radiographical data. HYSTs are more common in a younger age group, mostly accompanied with gonadal dysgenesis, and pathologically characterized by uniform cells lacking giant bizarre cells with abundant cytoplasm,⁸ which is totally different from HCO. Immunohistochemical staining of AFP was broadly applied to diagnose HCO. However, negative AFP staining cannot exclude the diagnosis of HCO according to previous examples.^{6,9,16–18} More accurate diagnostic method should be established. In our case, immunohistochemical studies revealed SALL4 positivity. SALL4 is an important marker of germ-cell tumors,¹⁹ but it is not expressed in hepatocellular tumors, and there have also been reports of other hepatoid adenocarcinomas expressing SALL4.^{20–22} Therefore, SALL4 may be a potential indicator to differentiate HCO from metastatic HCC.

The histogenesis of this tumor is mostly recognized as surface epithelial ovarian tumors. There is abundant evidence to support this opinion. The onset age of HCO is similar to that of epithelial ovarian cancer.²² In some cases, the tumor tissue was mixed with serous or mucinous carcinoma, also suggesting epithelial origin on the ovarian surface.²³ The fact that most patients have high levels of serum CA125 and CA125 antigen expression by immunohistochemistry is another crucial clue. Moreover, like high-grade serous carcinoma, most HCOs have an

aggressive clinical history with rapid progression, extensive intraperitoneal dissemination, and poor treatment response.¹⁴ In spite of this, it is important to remember that the hepatoid phenotype is nonspecific, necessitating the integration of pathologic and clinical information to make a definite diagnosis.

There is still insufficient data to determine the optimal treatment of HCO patients. Although there is no standard regimen, most patients are treated with surgery (optimal or maximal cytoreduction) and adjuvant chemotherapy the same as epithelial ovarian cancer. According to the serological AFP level monitoring of our patient before and after chemotherapy, we can draw a conclusion that adjuvant chemotherapy can lower AFP in certain patients and lengthen their lives. Pandey et al. used Sorafenib, a hepatocellular carcinoma medication, as adjuvant treatment for postoperative HCO patients; however, the outcomes were disappointing.¹³

5 | CONCLUSION

The histogenesis and immunohistochemical profile of HCO have yet to be determined. AFP staining has been shown routinely positive but still with several exceptions. SALL4 may be regarded as a good indicator of HCO despite its low positive rate.²² Both AFP and CA125, rather than HE4, can be employed as prognostic biomarkers and may be used to track therapy response and screen for recurrence. Treatment approaches are not unified, but a cytoreductive surgery followed by a platinum and taxane-based chemotherapy has shown

similar results to other ovarian carcinomas. The second-line therapy after platinum resistance requires further exploration.

AUTHOR CONTRIBUTIONS

Jiana Li: Investigation; methodology; writing – original draft. **Xiaohua Wu:** Conceptualization; project administration; resources; validation; writing – review and editing.

ACKNOWLEDGMENTS

Not applicable.

FUNDING INFORMATION

Funding was provided by the National Natural Science Foundation of China (No. 81972431 & 82272898).

CONFLICT OF INTEREST STATEMENT

The authors declare that the research was conducted in the absence of any commercial or financial relationships that could be construed as a potential conflict of interest.

DATA AVAILABILITY STATEMENT

The data that support the findings of this study are available from the corresponding author upon reasonable request.

ETHICS STATEMENT

Shanghai Cancer Center Institutional Review Board clearance obtained (Ethics Code: 050432–4-2108*). The patient's family was fully informed and consented to present the case.

CONSENT STATEMENT

The authors declare that a written informed consent was obtained from the patient for the publication of this case report.

ORCID

Jiana Li  <https://orcid.org/0000-0003-4091-2509>

REFERENCES

- Ishikura H, Fukasawa Y, Ogasawara K, Natori T, Tsukada Y, Aizawa M. An AFP-producing gastric carcinoma with features of hepatic differentiation. A case report. *Cancer*. 1985;56(4):840-848. doi:10.1002/1097-0142(19850815)56:4
- Ishikura H, Scully RE. Hepatoid carcinoma of the ovary. A newly described tumor. *Cancer*. 1987;60(11):2775-2784. doi:10.1002/1097-0142(19871201)60:11
- Tejerina González E, Argüelles M, Jiménez-Heffernan JA, Dhimes P, Vicandi B, Pinedo F. Cytologic features of hepatoid carcinoma of the ovary: a case report with immunocytologic evaluation of HepPar1. *Acta Cytol*. 2008;52(4):490-494. doi:10.1159/000325560
- Lee JM, Park KM, Lee SY, Choi J, Hwang DW, Lee YJ. Metastasis of hepatocellular carcinoma to the ovary: a case report and review of the literature. *Gut Liver*. 2011;5(4):543-547. doi:10.5009/gnl.2011.5.4.543
- Prat J, Bhan AK, Dickersin GR, Robboy SJ, Scully RE. Hepatoid yolk sac tumor of the ovary (endodermal sinus tumor with hepatoid differentiation): a light microscopic, ultrastructural and immunohistochemical study of seven cases. *Cancer*. 1982;50(11):2355-2368. doi:10.1002/1097-0142(19821201)50:11
- Liu Y, Zhou R, Wang S, Zhang G. Extra-hepatic hepatoid carcinomas in female reproductive system: three case-reports with a literature review. *Cancer Manag Res*. 2021;13:1625-1636. doi:10.2147/cmar.S288913
- Ulbright TM. Germ cell tumors of the gonads: a selective review emphasizing problems in differential diagnosis, newly appreciated, and controversial issues. *Mod Pathol*. 2005;18:S61-S79. doi:10.1038/modpathol.3800310
- Euscher ED. Germ cell tumors of the female genital tract. *Surg Pathol Clin*. 2019;12(2):621-649. doi:10.1016/j.path.2019.01.005
- Ishiguro T, Kashima K, Yachida N, Motoyama T, Enomoto T. Recurrent ovarian undifferentiated carcinoma resembling hepatoid morphology treated with pegylated liposomal doxorubicin and bevacizumab. *J Obstet Gynaecol Res*. 2017;43(5):957-961. doi:10.1111/jog.13298
- Mahmood H, Fatima H, Faheem M. Metastatic hepatoid carcinoma of ovarian origin – a case report from northern Pakistan. *Gynecol Oncol Rep*. 2017;21:24-27. doi:10.1016/j.gore.2017.05.007
- Naffouje SA, Anderson RR, Salti GI. A case report of hepatoid carcinoma of the ovary with peritoneal metastases treated with cytoreductive surgery and hyperthermic intraoperative intraperitoneal chemotherapy without systemic adjuvant therapy. *Int J Surg Case Rep*. 2016;27:83-86. doi:10.1016/j.ijscr.2016.08.020
- Lazaro J, Rubio D, Repolles M, Capote L. Hepatoid carcinoma of the ovary and management. *Acta Obstet Gynecol Scand*. 2007;86(4):498-499. Epub 2007/05/09. doi:10.1080/00016340600593117
- Pandey M, Truica C. Hepatoid carcinoma of the ovary. *J Clin Oncol*. 2011;29(15):e446-e448. doi:10.1200/jco.2010.33.6321
- Wang L, Zhong Y, Sun L, Zhou H, Chen W, Zhang X. Clinical and pathological features of hepatoid carcinoma of the ovary. *World J Surg Oncol*. 2013;11:29. doi:10.1186/1477-7819-11-29
- Watanabe Y, Umemoto M, Ueda H, Nakai H, Hoshiai H, Noda K. Cytopathologic and clinicopathologic features of ovarian hepatoid carcinoma. A case report. *Acta Cytol*. 2003;47(1):78-82. doi:10.1159/000326479
- Nishida T, Sugiyama T, Kataoka A, et al. Ovarian hepatoid carcinoma without staining for alpha-fetoprotein in the primary site. *Int J Gynecol Cancer*. 1995;5(4):314-318. doi:10.1046/j.1525-1438.1995.05040314.x
- Sung JH, Kim TH, Park HG, et al. Hepatoid carcinoma of the ovary without staining for alpha-fetoprotein. *Obstet Gynecol Sci*. 2013;56(1):41-44. doi:10.5468/ogs.2013.56.1.41
- Mazouz A, Amaadour L, Ameurtesse H, et al. Primary hepatoid carcinoma of the ovary: a case report. *Pan Afr Med J*. 2015;20:93. doi:10.11604/pamj.2015.20.93.5953

19. Randolph LK, Hopkins MK, Hopkins MP, Wasdahl DA. Hepatoid carcinoma of the ovary: a case report and review of the literature. *Gynecol Oncol Rep*. 2015;13:64-67. doi:10.1016/j.gore.2015.06.006
20. Camparo P, Comperat EM. SALL4 is a useful marker in the diagnostic work-up of germ cell tumors in extra-testicular locations. *Virchows Arch*. 2013;462(3):337-341. doi:10.1007/s00428-012-1353-5
21. Sideras K, Bots SJ, Biermann K, Sprengers D, Polak WG. Tumour antigen expression in hepatocellular carcinoma in a low-endemic western area. *Br J Cancer*. 2015;112(12):1911-1920. doi:10.1038/bjc.2015.92
22. Acosta AM, Pins MR. Hepatoid carcinoma of the ovary: clinical, histopathologic, and immunophenotypic features. *Arch Pathol Lab Med*. 2019;143(7):883-889. doi:10.5858/arpa.2017-0485-RS
23. Tochigi N, Kishimoto T, Supriatna Y, Nagai Y, Nikaido T, Ishikura H. Hepatoid carcinoma of the ovary: a report of three cases admixed with a common surface epithelial carcinoma.

Int J Gynecol Pathol. 2003;22(3):266-271. doi:10.1097/01.Pgp.0000055173.04957.66

SUPPORTING INFORMATION

Additional supporting information can be found online in the Supporting Information section at the end of this article.

How to cite this article: Li J, Wu X. SALL4 as an indicator for the diagnosis of hepatoid carcinoma of the ovary: A case report and literature review. *Clin Case Rep*. 2023;11:e7706. doi:10.1002/ccr3.7706