






CASE REPORT

REVISED Case Report: Sudden death related to unrecognized cardiac hydatid cyst [version 3; peer review: 2 approved]

Med Amin Mesrati ¹, Yosra Mahjoub¹, Nouha Ben Abdejilil¹, Marwa Boussaid ¹, Meriem Belhaj¹, Hiba Lيمem ¹, Ali Chadly¹, Abdelfeteh Zakhama², Abir Aissaoui¹

¹Department of Forensic Medicine, University of Monastir, Mahdia, 5100, Tunisia

²Department of Pathology, University of Monastir, Monastir, 5000, Tunisia

V3 First published: 24 Apr 2020, 9:286
<https://doi.org/10.12688/f1000research.23277.1>
 Second version: 18 Dec 2020, 9:286
<https://doi.org/10.12688/f1000research.23277.2>
 Latest published: 22 Sep 2022, 9:286
<https://doi.org/10.12688/f1000research.23277.3>

Abstract

Echinococcosis, also known as hydatid disease, is a common parasitic human infestation found in sheep-breeding areas. It is caused by the larvae stage of *Echinococcus granulosus*, and cysts develop mostly in the lungs and the liver. Cardiac involvement is unusual and silent until acute complications or a fatal outcome occurs. Herein, we report an autopsy case of a young healthy adult who died suddenly. The autopsy revealed an external bulging on the right heart ventricle outlet with a fluid-filled cystic cavity discovered on sectioning. Dissection of other organs did not reveal other cyst locations. Histological examination ascertained the diagnosis of hydatid cyst, and death was attributed to cardiac arrhythmias. Pathologists should keep in mind that hydatid cysts can develop anywhere in the body. Solitary cardiac cyst is rare and can simulate a "silent bomb". Unfortunately, sudden death remains the frequent manner of revelation of this disease in endemic areas.

Keywords





sudden death, hydatid cyst, right ventricle, autopsy, pathology




This article is included in the **Neglected Tropical Diseases** collection.

Open Peer Review

Approval Status  

	1	2
version 3 (revision) 22 Sep 2022		
version 2 (revision) 18 Dec 2020		 view
version 1 24 Apr 2020	 view	  view

- Mejdi Ben Messaoud** , Fattouma
Bourguiba University Hospital, Monastir,
Tunisia
- Omer Tanyeli**, Necmettin Erbakan University,
Konya, Turkey

Any reports and responses or comments on the article can be found at the end of the article.

Corresponding author: Med Amin Mesrati (mesrati.amin@gmail.com)

Author roles: **Mesrati MA:** Conceptualization; **Mahjoub Y:** Methodology; **Ben Abdejlil N:** Resources; **Boussaid M:** Visualization; **Belhaj M:** Visualization; **Limem H:** Writing – Original Draft Preparation; **Chadly A:** Writing – Review & Editing; **Zakhama A:** Writing – Review & Editing; **Aissaoui A:** Writing – Review & Editing

Competing interests: No competing interests were disclosed.

Grant information: The author(s) declared that no grants were involved in supporting this work.

Copyright: © 2022 Mesrati MA *et al.* This is an open access article distributed under the terms of the [Creative Commons Attribution License](#), which permits unrestricted use, distribution, and reproduction in any medium, provided the original work is properly cited.

How to cite this article: Mesrati MA, Mahjoub Y, Ben Abdejlil N *et al.* **Case Report: Sudden death related to unrecognized cardiac hydatid cyst [version 3; peer review: 2 approved]** F1000Research 2022, 9:286 <https://doi.org/10.12688/f1000research.23277.3>

First published: 24 Apr 2020, 9:286 <https://doi.org/10.12688/f1000research.23277.1>

REVISED Amendments from Version 2

We have added reference 19 in the text and the bibliography.

Any further responses from the reviewers can be found at the end of the article

Introduction

Echinococcosis, also known as hydatid disease, is a parasitic human infestation that commonly occurs in countries where sheep farming is widespread, such as Mediterranean countries¹. In Tunisia, the prevalence and incidence of this contagion are estimated to be high (15/100000 individuals)². It is attributed to the larval stage of a tapeworm, chiefly *Echinococcus granulosus*. The mature worm inhabits the intestines of the dog and humans are accidental hosts in their life cycle. Hydatid cysts can develop anywhere in the human body, predominantly in the lung and the liver^{3,4}. Cardiac involvement is very scarce, even in endemic regions, and its clinical evolution is asymptomatic until acute complications or a fatal outcome occurs. Herein, we report an autopsy case of a young patient who died suddenly due to an unrecognized hydatid cyst located in the right heart ventricle.

Case report

A previously healthy 26-year-old man, without any relevant past medical family history, was discovered dead at home. A forensic medical examination and an autopsy were ordered by the judicial authorities. Information provided by the patient's relatives revealed that the deceased was the owner of a large farm that he had been managing for the past 5 years. A few days ago, the patient had experienced mild chest pain with syncope but did not visit a cardiologist.

During external examination, the corpse was that of a young white male, medium-build, 183cm of tall. There was no external evidence of violence or trauma, and examination of the skin revealed no rash. At autopsy, there was multi-visceral congestion without any internal haemorrhage. Internal organs were unremarkable except for the heart, which was found to be enlarged, weighing 530g (normal range: 260–350g) with an external bulging on the right ventricle outlet (Figure 1). Sectioning of the heart revealed a fluid-filled cystic cavity, measuring 5×4cm, occupying half the volume of the right chamber and spreading to the septum. The cyst was enveloped by a thick fibrous tissue, and it featured germinative membranes, which infiltrated the myocardium. There was no hypertrophy of the myocardium. The left ventricle was 12mm of thick (Figure 2).

Microscopic examination using haematoxylin and eosin staining of paraffin sections of the cyst revealed classic layers of a hydatid cyst; pericyst (fibrous outer layer), ectocyst (laminated, hyaline and acellular middle layer) and endocyst (inner germinative layer) (Figure 3). This ascertained the diagnosis of hydatid disease.

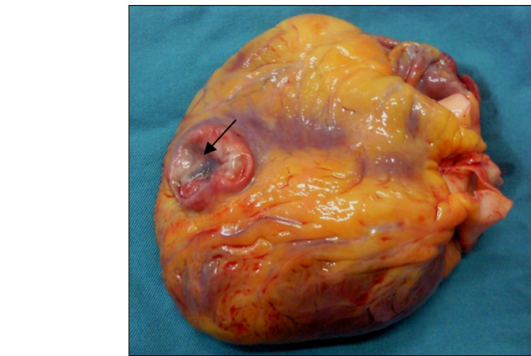


Figure 1. Cyst found in the right ventricle of the heart.

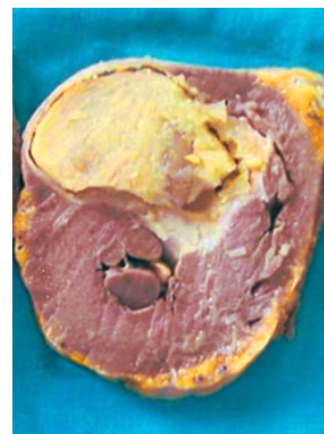


Figure 2. Right ventricle intra-cavitary cyst (after fixation in formalin).

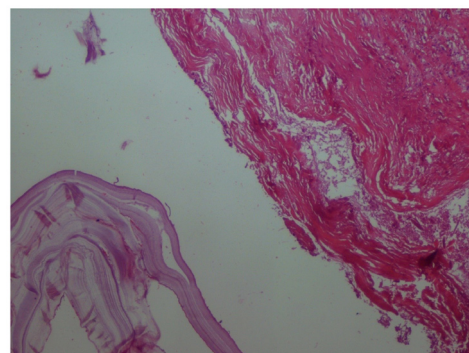


Figure 3. Microscopic appearance of the cyst wall. Haematoxylin and eosin, x40 magnification.

Histological findings of the left ventricle and coronary arteries were unremarkable. Examination of the lungs and liver did not reveal any abnormality, and no cysts were detected at dissection of these organs. The pulmonary arteries also did not display morphological changes, notably there were no

fragments of membranes or vesicles obstructing the vessels. Toxicological screening was negative. Death was attributed to cardiac arrhythmias.

Discussion

Hydatid disease is a parasitic infection most often induced by the larval form of the tapeworm *E. granulosus*, for which dogs are the definitive host⁵. In rural areas, dogs are common companions for sheep farmers. Typically, dogs become infected with *E. granulosus* from eating carcasses of infected sheep in endemic areas. Adult parasites colonize the intestinal tract and the faeces of infected dogs. Humans are intermediate hosts and may accidentally acquire infection by eating contaminated food such as water or salad or after close contact, e.g. hand-to-mouth transmission, with an infected dog. After ingestion, the larvae pass through the duodenal wall, reach the portal blood system and shelter in the liver, where they are found in ~60% of cases⁶. Some larvae may escape via the hepatic filter and cross into the pulmonary circulation, while others may continue to the systemic circulation, resulting in the generation of hydatid cysts in other organs, e.g. the lungs, muscles, bones or kidneys.

Secluded cardiac involvement by *E. granulosus* is very uncommon, and has not been described widely in the literature. Its incidence is estimated to be at about 0.4–3% of hydatid cyst cases⁷. This scarcity is attributed to the natural resistance of heart contraction. The first described case of cardiac hydatid cyst was reported in 1836⁸. Most reports documented in the literature are of single cases, and a previous literature review of the topic identified only 100 case presentations to date⁹.

The coronary circulation is the main pathway by which the parasitic larvae reach the heart. The second route of infestation is the pulmonary vein¹⁰. Due to their thickness and rich blood supply, the interventricular septum and the free wall of the left ventricular are the most common cardiac sites involved with hydatid cyst (55–60%). Pericardium, atria and right ventricle involvement have also been described; however, identification of an isolated right ventricle located hydatid cyst, like in our case, is atypical and quite rare¹¹.

Cardiac hydatid cysts are often latent. They remain symptomless and silent for a considerable time and clinical manifestation of cardiac hydatid disease may vary and depends on the size and the location of the cysts¹². The process of growth of cardiac cysts is slow because of the permanent traumatic action of myocardial contraction. After 2–7 years they can mimic the size of a chicken egg⁷. Unless it's in a critical anatomic site, cardiac hydatid disease is usually diagnosed late, as patients can manifest non-specific symptoms such as cough, palpitations and chest pain. The cyst may affect cardiac function leading to conduction and rhythmic disturbances, chest pain or angina, acute

myocardial infarction or valvular dysfunction and thus pulmonary hypertension may develop¹³. Cystic rupture is the most frequent complication (24–60%) and generally results in anaphylactic reaction with circulatory collapse. Other complications may occur leading to death, such as pericarditis, embolus, obstruction of cardiac chambers, cardiac tamponade and cardiac arrhythmias¹⁴.

Hydatid cysts located in the right cardiac chambers have special features, dissimilar from those of left sided cysts. In fact, right-sided cysts, such as in our case, have a tendency to extend subendocardially and intracavitarily¹⁵. In our case, the cyst seemed to extend to the septum. Cysts fissuration or rupture is more frequent, as this may trigger pulmonary embolic complication, anaphylaxis or sudden death. Chadly *et al.*¹ reported a case of a 22-year old man who died of pulmonary artery emboli because of the rupture of right ventricle located hydatid cyst. Pansard *et al.*¹⁶ documented a case of progressive fissure of a hydatid cyst of the right ventricle, which led to a chronic pulmonary hypertension. The authors suggested that it was probably secondary to microemboli migration in the small vessels of the lung. Buris *et al.*¹⁷ reported a sudden death caused by hydatid embolism in a previously healthy man who died during a race, and at autopsy hydatid cysts in the right ventricle were detected. The necropsy revealed that the cysts had embolized into the pulmonary arteries.

In our case, ventricular arrhythmia seemed to be the fatal outcome of the cardiac cyst which was found macroscopically intact. Malamou-Mitsi *et al.*⁷ also have reported a case in which the cyst was found intact; they suggested that the death seemed to be due to fatal left ventricular arrhythmias. Singh *et al.*^{18,19} reported a case of a 57-year-old man who presented with syncope due to ventricular tachycardia, and imaging revealed a right ventricular hydatid cyst. In our case, although no allergic signs were observed, anaphylactic shock cannot be excluded from the scope of mechanisms of death beyond pulmonary embolism. This fact may be explained by the rapidity and unwitnessed death.

Pathologists should keep in mind that hydatid cysts can develop anywhere in the body. Solitary cardiac cyst is rare and can simulate a “silent bomb”. Unfortunately, sudden death remains the frequent manner of revelation of this disease in endemic areas.

Consent

Written informed consent for publication was obtained from the legally authorized representative of the decedent.

Data availability

All data underlying the results are available as part of the article and no additional source data are required.

References

- Chadly A, Krimi S, Mghirbi T: **Cardiac hydatid cyst rupture as cause of death.** *Am J Forensic Med Pathol.* 2004; **25**(3): 262–4.
[PubMed Abstract](#) | [Publisher Full Text](#)
- Pakis I, Akyildiz EU, Karayel F, et al.: **Sudden death due to an unrecognized cardiac hydatid cyst: three medicolegal autopsy cases.** *J Forensic Sci.* 2006; **51**(2): 400–2.
[PubMed Abstract](#) | [Publisher Full Text](#)
- Cotran RS, Kumar V, Robbins SI: **Infectious diseases: fungal, protozoal and helminthic diseases and sarcoidosis.** In: Lichenberg F, editor, *Robbins pathologic basis of disease.* Philadelphia PA: WB Saunders; 1989; 385–433.
- Tanyeli O, Dereli Y, Mercan I, et al.: **New World's old disease: cardiac hydatid disease and surgical principles.** *Cardiovasc J Afr.* 2017; **28**(5): 304–308.
[PubMed Abstract](#) | [Publisher Full Text](#) | [Free Full Text](#)
- Budke CM, Carabin H, Ndimubanzi PC, et al.: **A systematic review of the literature on cystic echinococcosis frequency worldwide and its associated clinical manifestations.** *Am J Trop Med Hyg.* 2013; **88**(6): 1011–27.
[PubMed Abstract](#) | [Publisher Full Text](#) | [Free Full Text](#)
- Anderson WAD, Scotti TM: **Mycotic, protozoan and helminthic infections.** In: Anderson WAD, editor, *Synopsis of pathology.* 10th ed. St. Louis, MO: the C.V. Mosby Company; 1980; 197–219.
- Malamou-Mitsi V, Papa L, Vougiouklakis T, et al.: **Sudden death due to an unrecognized cardiac hydatid cyst.** *J Forensic Sci.* 2002; **47**(5): 1062–4.
[PubMed Abstract](#) | [Publisher Full Text](#)
- Williams WH: **Hydatiden in demherzeneineskindes.** *Schmidts Jahrb.* 1836; **9**: 29.
- Di bello R, Menendez H: **Intracardiac rupture of hydatid cysts of the heart. A study based on three personal observations and 101 cases in the world literature.** *Circulation.* 1963; **27**: 366–74.
[PubMed Abstract](#) | [Publisher Full Text](#)
- Ameli M, Mobarhan HA, Nouraii SS: **Surgical treatment of hydatid cysts of the heart: report of six cases.** *J Thorac Cardiovasc Surg.* 1989; **98**(5 Pt 2): 892–901.
[PubMed Abstract](#) | [Publisher Full Text](#)
- Byard RW, Bourne AJ: **Cardiac Echinococcosis With Fatal Intracerebral Embolism.** *Arch Dis Child.* 1991; **66**(1): 155–6.
[PubMed Abstract](#) | [Publisher Full Text](#) | [Free Full Text](#)
- Lanzoni AM, Barrios V, Moya JL, et al.: **Dynamic Left Ventricular Outflow Obstruction Caused by Cardiac Echinococcosis.** *Am Heart J.* 1992; **124**(4): 1083–5.
[PubMed Abstract](#) | [Publisher Full Text](#)
- Trehan V, Shah P, Yusuf J, et al.: **Thromboembolism: A Rare Complication of Cardiac Hydatidosis.** *Indian Heart J.* 2002; **54**(2): 199–201.
[PubMed Abstract](#)
- Birincioğlu CL, Bardakci H, Küçük SA, et al.: **A clinical dilemma: cardiac and pericardiac echinococcosis.** *Ann Thorac Surg.* 1999; **68**(4): 1290–4.
[PubMed Abstract](#) | [Publisher Full Text](#)
- Dursun M, Terzibasoglu E, Yilmaz R, et al.: **Cardiac hydatid disease: CT and MRI findings.** *AJR Am J Roentgenol.* 2008; **190**(1): 226–32.
[PubMed Abstract](#) | [Publisher Full Text](#)
- Pansard Y, De Brux JL, Cohen-Solal A, et al.: **Kyste hydatique du coeur droit et hypertension pulmonaire post-embolique.** *Arch Mal Coeur Vaiss.* 1987; **5**: 667–669.
- Buris L, Takacs P, Varga M: **Sudden death caused by hydatid embolism.** *Z Rechtsmed.* 1987; **98**(2): 125–8.
[PubMed Abstract](#) | [Publisher Full Text](#)
- Singh SK, Singh V, Kumar S, et al.: **Right ventricular hydatid cyst presented as tachyarrhythmia.** *Asian Cardiovasc Thorac Ann.* 2019; **27**(6): 489–491.
[PubMed Abstract](#) | [Publisher Full Text](#)
- Aissaoui A: **Mort subite et kyste hydatique.** Thesis for Doctor of Medicine. FMM. 2011.

Open Peer Review

Current Peer Review Status:  

Version 2

Reviewer Report 18 January 2021

<https://doi.org/10.5256/f1000research.31143.r76284>

© 2021 Tanyeli O. This is an open access peer review report distributed under the terms of the [Creative Commons Attribution License](#), which permits unrestricted use, distribution, and reproduction in any medium, provided the original work is properly cited.



Omer Tanyeli

Department of Cardiovascular Surgery, Meram Medicine Faculty, Necmettin Erbakan University, Konya, Turkey

Thanks for the authors for the revised version of the article.

Competing Interests: No competing interests were disclosed.

Reviewer Expertise: Cardiac surgery

I confirm that I have read this submission and believe that I have an appropriate level of expertise to confirm that it is of an acceptable scientific standard.

Version 1

Reviewer Report 28 August 2020

<https://doi.org/10.5256/f1000research.25698.r69471>

© 2020 Tanyeli O. This is an open access peer review report distributed under the terms of the [Creative Commons Attribution License](#), which permits unrestricted use, distribution, and reproduction in any medium, provided the original work is properly cited.



Omer Tanyeli

Department of Cardiovascular Surgery, Meram Medicine Faculty, Necmettin Erbakan University, Konya, Turkey

The cardiac hydatid disease is a relatively rare disease, especially causing symptoms in farmers. In this case report, the etiology of sudden death was attributed to possible arrhythmias caused by

huge cyst in the right ventricle.

In the literature, the cardiac hydatid cyst is reported many times both for therapeutic options, and for its morbidity, e.g. arrhythmias. But in some Mediterranean countries, the disease is still a problem which should be kept in mind. The disease also seems to be in an increase, due to immigration/common travel policies all around the world; so that the disease can be seen in both urban and rural areas.

I advise the authors to also read Tanyeli *et al.* (2017¹).

Although it's not the first or the last case report in the "cardiac hydatid cyst" field, it may deserve indexing for the dramatic postmortem pictures of the heart.

References

1. Tanyeli O, Dereli Y, Mercan I, Gormus N, et al.: New World's old disease: cardiac hydatid disease and surgical principles. *Cardiovasc J Afr.* **28** (5): 304-308 [PubMed Abstract](#) | [Publisher Full Text](#)

Is the background of the case's history and progression described in sufficient detail?

Yes

Are enough details provided of any physical examination and diagnostic tests, treatment given and outcomes?

Partly

Is sufficient discussion included of the importance of the findings and their relevance to future understanding of disease processes, diagnosis or treatment?

Partly

Is the case presented with sufficient detail to be useful for other practitioners?

Partly

Competing Interests: No competing interests were disclosed.

Reviewer Expertise: Cardiac surgery

I confirm that I have read this submission and believe that I have an appropriate level of expertise to confirm that it is of an acceptable scientific standard, however I have significant reservations, as outlined above.

Author Response 31 Aug 2020

med amin mesrati, University of Monastir, Mahdia, Tunisia

Dear Tanyelli,

Thank You very much for your comments. They are so pertinent and considered by all authors.

It is true that many cases were reported in the literature about cardiac hydatid cyst but as you advanced, the exemplarity of our case remains in post-mortem pictures of the heart. We have read your article published in this field and we considered it very interesting.

Cordially

Competing Interests: none

Author Response 30 Nov 2020

med amin mesrati, University of Monastir, Mahdia, Tunisia

Dear Dr. Tanyeli,

Thank you very much for your comments. They are so pertinent and considered by all authors.

It is true that many cases were reported in the literature about cardiac hydatid cyst but as you advanced, the exemplarity of our case remains in post-mortem pictures of the heart. We have read your article published in this field and we considered it very interesting. It was included in our references.

Cordially

Competing Interests: No competing interests were disclosed.

Reviewer Report 02 June 2020

<https://doi.org/10.5256/f1000research.25698.r63961>

© 2020 Ben Messaoud M. This is an open access peer review report distributed under the terms of the [Creative Commons Attribution License](#), which permits unrestricted use, distribution, and reproduction in any medium, provided the original work is properly cited.



Mejdi Ben Messaoud 

Cardiology A Department, Fattouma Bourguiba University Hospital, Monastir, Tunisia

Editorial Note from F1000Research 7th September 2022 - This report has been updated to include a conflict of interest statement explaining the relationship between the reviewer and the author's institutional affiliations.

I read with great interest the report written by Med Amine Mesrati *et al.* about a case of sudden death due to cardiac hydatid cyst of the right ventricle. Only few similar cases were reported in the literature. The authors attributed the sudden death to ventricular arrhythmia. I think that other causes, such as anaphylactic shock (although the cyst was intact) or pulmonary embolism or right

ventricular obstruction are not excluded based on the lack of some data, especially imaging exams. Additionally, other cyst locations, such as cerebral or renal, should be excluded by authors (only lungs and liver were reported) to confirm the cardiac etiology of the death.

Is the background of the case's history and progression described in sufficient detail?

Yes

Are enough details provided of any physical examination and diagnostic tests, treatment given and outcomes?

Yes

Is sufficient discussion included of the importance of the findings and their relevance to future understanding of disease processes, diagnosis or treatment?

Yes

Is the case presented with sufficient detail to be useful for other practitioners?

Yes

Competing Interests: I work in the Cardiology A department at Fattouma Bourguiba University Hospital, Monastir City which is part of the University and Faculty of Medicine of Monastir, at which the authors of this article are also affiliated. I confirm that I have had no professional collaboration or personal relationship with any of the authors of this article and I can review this work objectively.

Reviewer Expertise: interventional cardiology, valvular heart disease, echocardiography, heart failure

I confirm that I have read this submission and believe that I have an appropriate level of expertise to confirm that it is of an acceptable scientific standard.

Author Response 02 Jun 2020

med amin mesrati, University of Monastir, Mahdia, Tunisia

Dear Reviewer,

Thank you for your considerations.

Response to question 1: the autopsy findings and histological tests which are always more accurate than pre-mortem imaging had excluded a pulmonary embolism or obstruction of the RV. Thus we attributed the death to cardiac arrhythmias

Response to question 2: we report in the section of the case report that others organs were unremarkable. This is to say that kidney and brain didn't exhibit hydatid cyst.

Cordially

Competing Interests: none

The benefits of publishing with F1000Research:

- Your article is published within days, with no editorial bias
- You can publish traditional articles, null/negative results, case reports, data notes and more
- The peer review process is transparent and collaborative
- Your article is indexed in PubMed after passing peer review
- Dedicated customer support at every stage

For pre-submission enquiries, contact research@f1000.com

F1000Research