

Received: 2015.07.06
Accepted: 2015.08.23
Published: 2015.09.07

Expression of Cofilin-1 and Transgelin in Esophageal Squamous Cell Carcinoma

Authors' Contribution:
Study Design A
Data Collection B
Statistical Analysis C
Data Interpretation D
Manuscript Preparation E
Literature Search F
Funds Collection G

ABCD 1 **Yan Zhang***
ABCF 2 **Ruyi Liao***
D 3 **Hui Li**
E 4 **Ling Liu**
ADF 4 **Xiao Chen**
AEF 5 **Hongming Chen**

1 Institute of International Education, College of Basic Medical Sciences, Xinjiang Medical University, Urumqi, Xinjiang, P.R. China
2 Department of Gastroenterology, The First Affiliated Hospital of Xinjiang Medical University, Urumqi, Xinjiang, P.R. China
3 Scientific Research and Innovation Center, Xinjiang Medical University, Urumqi, Xinjiang, P.R. China
4 Department of Pathology, College of Basic Medical Sciences, Xinjiang Medical University, Urumqi, Xinjiang, P.R. China
5 Department of Histology and Embryology, College of Basic Medical Sciences, Xinjiang Medical University, Urumqi, Xinjiang, P.R. China

* These authors contributed equally to this work Co-first authors – Yan Zhang and Ruyi Liao

Corresponding Author: Hongming Chen, e-mail: shenhongming5709@163.com; Xiao Chen, e-mail: xjchenxiao@sina.com

Source of support: The study was supported by the Natural Science Foundation of Xinjiang Uygur Autonomous Region, China (No. 2014211C020)

Background: Esophageal squamous cell carcinoma (ESCC) has attracted much research attention around the world, and the number of ESCC cases has increased gradually in recent years. Identifying the specific biomarkers of ESCC is an effective approach for the early diagnosis of tumors.





Material/Methods: Immunohistochemical streptavidin-peroxidase method was used to determine the expressions of Cofilin-1 and transgelin in 68 patients with esophageal squamous cell carcinoma (ESCC) and 48 individuals with normal esophageal tissues. In addition to the relationships between the expression of Cofilin-1 and transgelin, the clinicopathologic features of ESCC were also discussed. The correlation between Cofilin-1 and transgelin protein expression in ESCC was analyzed.

Results: (1) The positive expression rates of Cofilin-1 and transgelin were 60.3% (41/68) and 54.4% (37/68) in esophageal carcinoma tissue, respectively. The positive expression rates of Cofilin-1 and transgelin in normal esophageal tissue were 27.1% (13/48) and 29.1% (14/48), respectively. The differences were statistically significant ($P < 0.05$). (2) The positive expression rate of Cofilin-1 did not differ significantly ($P > 0.05$) with sex, age, ethnicity, tumor size, or infiltration depth; but did have a statistically significant ($P < 0.05$) difference with various degrees of tumor differentiation, lymph node metastasis, and clinical stages. (3) The positive expression rate of transgelin did not differ significantly ($P > 0.05$) with sex, age, ethnicity, tumor size, infiltration depth, and clinical stage, but did significantly ($P < 0.05$) differ with degree of tumor differentiation and lymph node metastasis.

Conclusions: Cofilin-1 and transgelin may play roles in the carcinogenesis and development of esophageal squamous cell carcinoma. Cofilin-1 may be useful as an important biomarker for indicating the degree of malignancy of esophageal squamous cell carcinoma, and the detection of transgelin is valuable in early diagnosis of esophageal squamous cell carcinoma.

MeSH Keywords: Cofilin 1 • Esophageal Neoplasms • Myocytes, Smooth Muscle

Full-text PDF: <http://www.medscimonit.com/abstract/index/idArt/895242>

 1637  4  2  34



Background

Esophageal squamous cell carcinoma (ESCC) has attracted much research attention around the world, and the number of ESCC cases has increased gradually in recent years. Xinjiang is the highest-incidence area of esophageal cancer in China [1]. Esophageal cancer mortality is 68.88/100 000 in the Kazakh ethnic group and is a serious threat to people's health. Lv Xiuping et al. [2] studied the differentially expressed proteins between human normal esophageal epithelial cells (NEEC) and esophageal squamous cell carcinoma cells. The proteins of the cells were separated by 2-dimensional gel electrophoresis (2-DE) and analyzed using ImageMASTER 2D software. Differential proteins between NEEC and ESCC cells were identified by matrix-assisted laser desorption ionization time-of-flight mass spectrometry (MALDI-TOF-MS). As a result, 43 protein spots were discovered and 15 were up-regulated. Zhang et al. [3] also found obvious up-regulation of Bmi-1 in ESCC cells. This study aimed to determine the expressions of Cofilin-1 and transgelin in 68 cases of esophageal squamous cell carcinoma (ESCC) by using SP method, and to statistically analyze the expressions of Cofilin-1 and transgelin and clinical pathological characteristics of ESCC [4,5].

Material and Methods

Study population and materials

The study was conducted at the First Affiliated Hospital of Xinjiang Medical University. We selected ESCC tissue specimens from 68 patients between 2012 and 2014. All specimens were obtained following surgical resection and were proved by pathologists. Of these 68 patients, there were 35 males and 33 females; 16 were under age 50 years and 52 were over 50; 36 were of Kazakh ethnicity and 32 were Han ethnicity; 27 had tumor size less than 5 cm and 41 had tumors 5 cm or greater in size; 24 patients had tumors with high differentiation, 33 had moderate differentiation, and 11 had low differentiation; 6 patients had tumors infiltrating the esophageal mucosa and submucosa, 27 patients had tumors that infiltrated the muscular layer and 35 patients had them in the placenta percreta layer; 52 patients experienced lymphatic metastasis and 16 did not. Additionally, we enrolled 48 individuals with normal tissues and recorded basic information including sex, age, and ethnicity. Specimens were collected, read, and analyzed by 2 experienced pathologists. The study was funded by the Natural Science Foundation of Xinjiang and was reviewed by the medical ethics committee of our hospital. All participants acknowledged and signed the informed consent documents.

Study design

SP immunohistochemical method was used to determine the expression of Cofilin-1 and transgelin in 68 patients. The immunohistochemical EnVision 2 footwork method was used to determine the protein expression of Cofilin-1 and transgelin in each group.

Interpretation of the results

Positive Cofilin-1 and transgelin expression was indicated by tan or brown granular particles in the cytoplasm. Expression in normal esophageal mucosa cells was used as a positive control.

Statistical analysis

Statistical analyses were performed using SPSS17.0 software for analyzing sex, age, ethnicity, size of tumor, degree of differentiation, depth of infiltration, and lymphatic metastasis, and we used the χ^2 test. Inspection level $\alpha=0.05$, $P<0.05$ was considered statistically significant.

Results

Expression of Cofilin-1 and transgelin in ESCC and normal esophageal tissue

The expression of Cofilin-1 in ESCC refers is shown in Figure 1. The rates of expression of Cofilin-1 in esophageal cancer tissue and normal tissue were 60.3% (41/68) and 27.1% (13/48), respectively. The difference in rates was statistically significant between cancer tissue and normal tissue ($P<0.05$) (Table 1).

The expression of transgelin in ESCC is shown in Figure 2. The rates of expression of transgelin in esophageal cancer tissue and normal tissue were 54.4% (37/68) and 29.1% (14/48), respectively. The difference in rates was statistically significant between cancer tissue and normal tissue ($P<0.05$) (Table 2).

Relationship between Cofilin-1 and transgelin expression and clinical pathological parameters

The differences of Cofilin-1 positive expression rates in patients with low, moderate, or high differentiation were statistically significant ($P<0.05$), which indicates that Cofilin-1 expression gradually increased with higher degree of differentiation. The differences in Cofilin-1 expression rates in patients with lymphatic metastasis and without lymphatic metastasis were statistically significant ($P<0.05$), showing that there is a relationship between Cofilin-1 expression and lymphatic metastasis. At clinical stages I-II and III-IV the positive expression of Cofilin-1 was 37.9% and 76.9%, respectively

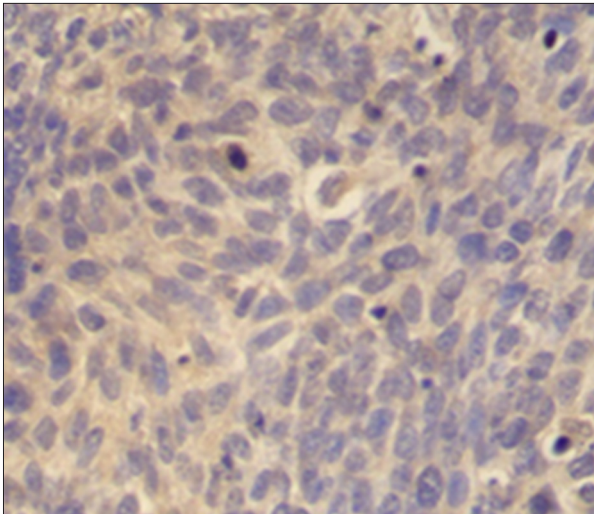


Figure 1. Positive expression of Cofilin-1 in esophageal squamous cell carcinoma (x400).

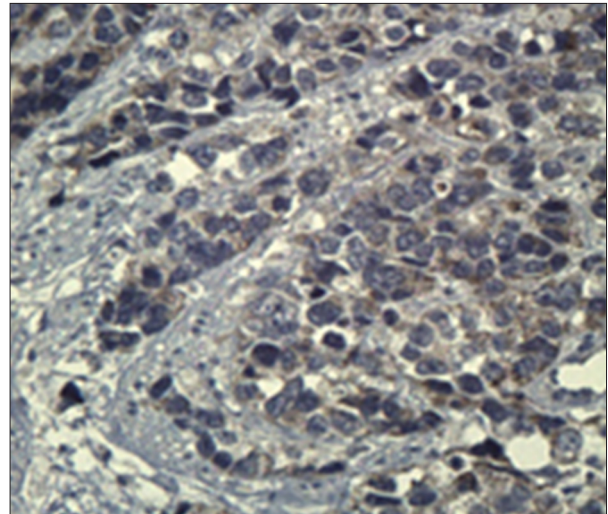


Figure 2. Positive expression of transgelin in esophageal squamous cell carcinoma (x400).

Table 1. Cofilin-1 protein expression in esophageal cancer and normal esophageal tissues.

Pathological characteristic	Total cases	Positive	Negative	Positive rate (%)	χ^2	P value
Cancerous tissue	68	41	27	60.3	12.473	0.001
Normal tissue	48	13	35	27.1		

Table 2. Transgelin protein expression in esophageal cancer and normal esophageal tissues.

Pathological characteristic	Total cases	Positive	Negative	Positive rate (%)	χ^2	P value
Cancerous tissue	68	37	31	54.4	7.279	0.006
Normal tissue	48	14	34	29.1		

and the differences were statistically significant ($P < 0.05$). The results indicated that the expressions of Cofilin-1 probably were closely related to clinical stages. Cofilin-1 expression in ESCC was not correlated with sex, age, ethnicity, tumor size, or depth of infiltration. There was no significant difference in expression ($P > 0.05$) (Table 3).

The transgelin-positive expression rates in patients with low, moderate, or high differentiation were 37.5%, 57.6%, and 81.8%, respectively and the differences were statistically significant ($P < 0.05$), indicating that transgelin plays an important role in cell differentiation. Transgelin expression in patients without lymphatic metastasis and in those with lymphatic metastasis was 18.8% and 65.4%, respectively. The difference was statistically significant ($P < 0.05$), which shows that transgelin expressions were higher in patients with lymphatic metastasis. At clinical stages I-II and III-IV, the positive expression of transgelin was 44.8% and 61.5%, respectively, but

the difference was not statistically significant ($P > 0.05$). The results indicate that transgelin expression in ESCC has no relationship with sex, age, ethnicity, depth of infiltration, clinical stages, or tumor size ($P > 0.05$) (Table 4).

Discussion

It is well known that esophageal squamous cell carcinoma (ESCC) is prone to invade adjacent regions and to metastasize to lymph nodes [6]. In this study, we identified and functionally characterized Cofilin-1 as an important participant in ESCC progression.

Cofilin-1 is one of the main proteins in charge of cell motility; it is regulated by many factors, such as binding of phosphoinositides, phosphorylation, and subcellular compartmentalization [7,8]. Local activation of Cofilin-1 by uncaging

Table 3. Correlation between Cofilin-1 expression and clinicopathological data.

Characteristics	Total cases	Positive cases	Positive rate (%)	χ^2	P value
Sex					
Male	35	23	65.7	0.885	0.347
Female	33	18	54.5		
Age (yr)					
<50	16	12	75.0	1.890	0.169
≥50	52	29	55.8		
Nationality					
Kazakh	36	22	61.1	0.021	0.884
Han	32	19	59.4		
Tumor size(cm)					
<5	27	18	66.7	0.760	0.383
≥5	41	23	56.1		
Differentiation degree					
High	24	8	33.3	11.546	0.003
Moderate	33	24	72.7		
Low	11	9	81.8		
Depth of infiltration					
Mucosal & submucosa	6	3	50.0	0.948	0.622
Muscular layer	27	15	55.6		
Placenta percreta	35	23	65.7		
Lymphatic metastasis					
No	16	4	25.0	10.887	0.001
Yes	52	37	71.1		
Clinical stages					
Stage I-II	29	11	37.9	10.563	0.001
Stage III-IV	39	30	76.9		

induces lamellipod formation and sets the direction of cell motility [9,10]. The over-expression of cofilin can increase the velocity of cell migration in dictyostelium and in human glioblastoma cells [11,12]. Cofilin-1 is a key factor in cell cycle regulation and plays crucial roles in the pathogenesis and development of neoplasms [13,14]. The over-expression of Cofilin-1 has been detected in the invasive tumor cells in cervical cancer, liver cancer, colon cancer, gastric cancer, pancreatic cancer, and kidney cancer [15–18]. It was found that up-regulated expression of Cofilin-1 was the main factor in determining the poor prognosis of pulmonary adenocarcinoma [19,20].

Few studies have investigated the correlation between Cofilin-1 and ESCC. Jones et al. [21] found that, in normal gastric mucosa tissue, the expression of Cofilin-1 is low; however, its expression increases in cancer tissue. The results prove that Cofilin-1 has a close relationship with gastric carcinoma. In our study, Cofilin-1 expression in ESCC was shown to be related with patients' degree of differentiation, lymphatic metastasis, and clinical stages. Cofilin-1 expression was significantly up-regulated in ESCC tissues compared with adjacent non-cancerous tissues. However, patient ethnicity had no effect on Cofilin-1 expression. The results indicate that Cofilin-1 plays

Table 4. Correlation between transgelin expression and clinicopathological data.

Characteristics	Total cases	Positive cases	Positive rate (%)	χ^2	P value
Sex					
Male	35	20	57.1	0.217	0.641
Female	33	17	51.5		
Age (yr)					
<50	16	12	75.0	3.575	0.059
≥50	52	25	48.1		
Nationality					
Kazakh	36	21	58.3	0.474	0.491
Han	32	16	50.0		
Tumor size(cm)					
<5	27	15	55.6	0.024	0.878
≥5	41	22	53.7		
Differentiation degree					
High	24	9	37.5	6.231	0.044
Moderate	33	19	57.6		
Low	11	9	81.8		
Depth of infiltration					
Mucosal & submucosa	6	2	40.0	1.194	0.55
Muscular layer	27	15	55.6		
Placenta percreta	35	20	57.1		
Lymphatic metastasis					
No	16	3	18.8	10.727	0.001
Yes	52	34	65.4		
Clinical stages					
Stage I-II	29	13	44.8	1.872	0.171
Stage III-IV	39	24	61.5		

a role in the carcinogenesis and development of esophageal squamous cell carcinoma, and it may help determine the degree of malignancy in carcinoma. Further studies are needed to determine whether Cofilin-1 can be used as a pre-diagnosis indicator for esophageal squamous cell carcinoma; whether the expression of Cofilin-1 is closely related with drug resistance; and whether it can be used as a parameter to guide individual chemotherapy.

Transgelin, also known as smooth muscle-22 α , directly binds to the actin cytoskeleton and induces actin bundling to facilitate

the formation of cytoskeletal structures such as stress fibers [22]. Transgelin has been shown to stabilize loose actin gels, leading to actin filament gelation. It is one of the earliest markers of smooth muscle differentiation and has been implicated in many biologic activities, including regulating muscle fiber contractility, cell differentiation, tissue invasion, and tumor suppression [23]. For many years, its function was unknown. Previous studies have shown that transgelin is an actin-binding protein considered a marker of smooth muscle differentiation, and is upregulated in podocytes in several models of podocyte disease [24]. Studies have shown that reduced transgelin levels

have a proliferative effect in vascular smooth muscle cells and prostate tumor cells, and that transgelin levels were significantly reduced in proliferating cells in prostate, lung, breast, glioblastoma, and colorectal cancers [25–28]. Studies have reported the over-expression of transgelin protein in lung cancer, gallbladder cancer, and liver cancer tissue [29,30]. Several studies have been reported varying results [31], and our research team hopes conduct another study with larger sample size in the near future.

To the best of our knowledge, there are few studies on the relationship between transgelin and ESCC. In the present study, we demonstrated that transgelin over-expression in ESCC was correlated with differentiation degree and lymph node metastasis. The results indicate that transgelin is related to the occurrence and development of ESCC. The detection of transgelin is valuable in early diagnosis of esophageal squamous cell carcinoma. However, other studies have reported conflicting results and more experiments are needed to confirm our findings. Identification of transgelin as the specific biomarker of ESCC is an effective approach for the early diagnosis of

tumors. Further studies are needed to better delineate and to provide functional proof of this deduction.

Conclusions

In summary, our results indicate that the role of Cofilin-1 and transgelin in esophageal squamous cell carcinoma is different from that of Cofilin-1 and transgelin in other neoplasms. To study the expression of different proteins will add to the foundation of target gene therapy of esophageal squamous cell carcinoma. Treatment and estimating prognosis of esophageal squamous cell carcinoma has received much research attention [32–34]. Moreover, it also provided a molecular basis for the clinical diagnosis and therapy targeted in this signaling pathway. Further studies are needed to determine if Cofilin-1 and transgelin can be used as pre-diagnosis indicators for esophageal squamous cell carcinoma. Although Cofilin-1 and transgelin may not be independent prognostic factors, they warrant further prospective analysis and more comprehensive study in esophageal squamous cell carcinoma.

References:

- Pu XH, Pu HW, Chen X et al: Expression and its significance of RASSF1A and FGFB3 in esophageal carcinoma. *Yixue Yanjiu Zazhi*, 2010; 27: 11–14
- Lv XP, Pu HW, Gong XJ et al: Proteomic analysis of differentially expressed proteins in esophageal squamous cell carcinoma by MALDI-TOF-MS. *World Chinese Journal of Digestology*, 2011; 19(36): 3682–86
- Zhang Y, Zhang YL, Chen HM et al: Expression of Bmi-1 and PAI-1 in esophageal squamous cell carcinoma. *World J Gastroenterol*, 2014; 20(18): 5533–39
- Du HQ, Chen L, Wang Y et al: Increasing radiosensitivity with the downregulation of Cofilin-1 in U251 human glioma cells. *Mol Med Rep*, 2015; 11(5): 3354–60
- Maleszewski M, Gjaltema RA, Krenning G et al: Enhancer of zeste homolog-2 (EZH2) methyltransferase regulates transgelin/smooth muscle-22 α expression in endothelial cells in response to interleukin-1 β and transforming growth factor- β 2. *Cell Signal*, 2015; 27(8): 1589–96
- Cao HH, Zhang SY, Shen JH et al: A three-protein signature and clinical outcome in esophageal squamous cell carcinoma. *Oncotarget*, 2015; 6(7): 5435–48
- Müller CB, De Bastiani MA, Becker M et al: Potential crosstalk between Cofilin-1 and EGFR pathways in cisplatin resistance of non-small-cell lung cancer. *Oncotarget*, 2015; 28: 3531–39
- Grego-Bessa J, Hildebrand J, Anderson KV: Morphogenesis of the mouse neural plate depends on distinct roles of cofilin 1 in apical and basal epithelial domains. *Development*, 2015; 142(7): 1305–14
- Chen B, Wang Y: Cofilin rod formation in neurons impairs neuronal structure and function. *CNS Neurol Disord Drug Targets*, 2015; 14(4): 554–60
- Zhang HH, Lechuga TJ, Tith T et al: S-nitrosylation of Cofilin-1 mediates estradiol-17 β -stimulated endothelial cytoskeleton remodeling. *Mol Endocrinol*, 2015; 29(3): 434–44
- Huang H, Li X, Hu G et al: Poly(ADP-ribose) glycohydrolase silencing down-regulates TCTP and Cofilin-1 associated with metastasis in benzo(a)pyrene carcinogenesis. *Am J Cancer Res*, 2014; 5(1): 155–67
- Tsai CH, Lin LT, Wang CY et al: Over-expression of Cofilin-1 suppressed growth and invasion of cancer cells is associated with up-regulation of let-7 microRNA. *Biochim Biophys Acta*, 2015; 1852(5): 851–61
- Liu G, Xiang Y, Guo C et al: Cofilin-1 is involved in regulation of actin reorganization during influenza A virus assembly and budding. *Biochem Biophys Res Commun*, 2014; 453(4): 821–25
- Barone E, Mosser S, Fraering PC: Inactivation of brain Cofilin-1 by age, Alzheimer's disease and γ -secretase. *Biochim Biophys Acta*, 2014; 1842: 2500–9
- Li R, Wang X, Zhang XH et al: Ursolic acid promotes apoptosis of SGC-7901 gastric cancer cells through ROCK/PEN mediated mitochondrial translocation of Cofilin-1. *Asian Pac J Cancer Prev*, 2014; 15(22): 9593–97
- Zhang HH, Wang W, Feng L et al: S-nitrosylation of Cofilin-1 serves as a novel pathway for VEGF-stimulated endothelial cell migration. *J Cell Physiol*, 2015; 230(2): 406–17
- Li X, Zhang X, Li X et al: Cyclosporine A protects podocytes via stabilization of Cofilin-1 expression in the unphosphorylated state. *Exp Biol Med*, 2014; 239(8): 922–36
- Wang Y, Kuramitsu Y, Kitagawa T et al: Cofilin-phosphatase slingshot-1L (SSH1L) is over-expressed in pancreatic cancer (PC) and contributes to tumor cell migration. *Cancer Lett*, 2015; 360(2): 171–76
- Peng XC, Gong FM, Zhao YW et al: Comparative proteomic approach identifies PKM2 and Cofilin-1 as potential diagnostic, prognostic and therapeutic targets for pulmonary adenocarcinoma. *PLoS One*, 2011; 6(11): e27309
- Schönhofen P, de Medeiros LM, Chatain CP et al: Cofilin/actin rod formation by dysregulation of Cofilin-1 activity as a central initial step in neurodegeneration. *Mini Rev Med Chem*, 2014; 14(5): 393–400
- Jones BA, Christensen AR, Wise JP Sr et al: Glutathione S-transferase polymorphisms and survival in African-American and white colorectal cancer patients. *Cancer Epidemiol*, 2009; 33: 249–56
- Kaci-Ouchfoun N, Izemrane D, Boudrissa A et al: Transgelin: an androgen-dependent protein identified in the seminal vesicles of three Saharan rodents. *Theriogenology*, 2013; 80(7): 748–57
- Tawfik O, Rao D, Nothnick WB et al: Transgelin, a novel marker of smooth muscle differentiation, effectively distinguishes endometrial stromal tumors from uterine smooth muscle tumors. *Int J Gynecol Obstet Reprod Med Res*, 2014; 1(1): 26–31
- Rao D, Kimler BF, Nothnick WB et al: Transgelin: a potentially useful diagnostic marker differentially expressed in triple-negative and non-triple-negative breast cancers. *Hum Pathol*, 2015; 46(6): 876–83
- Cai J, Chen S, Zhang W et al: Salvianolic acid A reverses paclitaxel resistance in human breast cancer MCF-7 cells via targeting the expression of transgelin 2 and attenuating PI3 K/Akt pathway. *Phytomedicine*, 2014; 21(12): 1725–32

26. Wu X, Dong L, Zhang R et al: Transgelin overexpression in lung adenocarcinoma is associated with tumor progression. *Int J Mol Med*, 2014; 34(2): 585–91
27. Fehrholz M, Speer CP, Kunzmann S: Caffeine and rolipram affect Smad signalling and TGF- β 1 stimulated CTGF and transgelin expression in lung epithelial cells. *PLoS One*, 2014; 9(5): e97357
28. Chunhua L, Donglan L, Xiuqiong F et al: Apigenin up-regulates transgelin and inhibits invasion and migration of colorectal cancer through decreased phosphorylation of AKT. *J Nutr Biochem*, 2013; 24(10): 1766–75
29. Sahasrabudde NA, Barbhuiya MA, Bhunia S et al: Identification of pro-saposin and transgelin as potential biomarkers for gallbladder cancer using quantitative proteomics. *Biochem Biophys Res Commun*, 2014; 446(4): 863–69
30. Zhang R, Shi L, Zhou L et al: Transgelin as a therapeutic target to prevent hypoxic pulmonary hypertension. *Am J Physiol Lung Cell Mol Physiol*, 2014; 306(6): L574–83
31. Apte MV, Yang L, Phillips PA et al: Extracellular matrix composition significantly influences pancreatic stellate cell gene expression pattern: role of transgelin in PSC function. *Am J Physiol Gastrointest Liver Physiol*, 2013; 305(6): G408–17
32. Zemanová M, Staňková B, Ušiakova Z et al: Serum adiponectin relates to shortened overall survival in men with squamous cell esophageal cancer treated with preoperative concurrent chemoradiotherapy: A pilot study. *Med Sci Monit*, 2014; 20: 2351–57
33. Guan X, Wang X, Luo H et al: Matrix metalloproteinase 1, 3, and 9 polymorphisms and esophageal squamous cell carcinoma risk. *Med Sci Monit*, 2014; 20: 2269–74
34. Guo R, Li W, Liu B et al: Resveratrol protects vascular smooth muscle cells against high glucose-induced oxidative stress and cell proliferation *in vitro*. *Med Sci Monit Basic Res*, 2014; 20: 82–92