

## Case Report

# Acute Torsion of Appendicular Mucocele

**Farshid Ejtehad<sup>1</sup>, James Brooks<sup>1</sup>, Hebah Hassan Ali<sup>2</sup> and Vardhini Vijay<sup>1</sup>**

<sup>1</sup>*Surgical Department, The Princess Alexandra Hospital, Harlow, UK*

<sup>2</sup>*The Michael Letcher Cellular Pathology Department, The Princess Alexandra Hospital NHS Trust, Harlow, UK*

Correspondence should be addressed to Farshid Ejtehad; [farshid.e@doctors.org.uk](mailto:farshid.e@doctors.org.uk)

Received 17 January 2017; Accepted 12 April 2017; Published 27 April 2017

Academic Editor: Menelaos Zafrakas

Copyright © 2017 Farshid Ejtehad et al. This is an open access article distributed under the Creative Commons Attribution License, which permits unrestricted use, distribution, and reproduction in any medium, provided the original work is properly cited.

We present the case of an 81-year-old man with a known appendicular mucocele who presented to the emergency department with acute abdominal pain. A CT scan showed a change in orientation of the previously seen ovoid mass with surrounding fat stranding suggesting torsion. An emergency laparotomy with appendicectomy and resection of the caecal pole was performed. We discuss the findings and histopathology.

## 1. Background

Mucocele of the appendix is a term used to describe an appendix that is grossly distended by mucus. The presentation of mucoceles can vary from being an incidental finding at surgery (in 50%) or imaging to having clinical features such as abdominal pain, abdominal mass, nausea, vomiting, and acute appendicitis [1].

On histopathology, different terminologies are used to address the nature of the mucocele such as mucinous adenoma, cystadenoma, or low-grade appendiceal mucinous neoplasm.

In general, a primary neoplasm of the appendix is rare and difficult to diagnose radiologically. It is found in less than 2% of appendicectomy specimens [2] and accounts for 0.5–1% of all gastrointestinal (GI) malignancies [3–5]. Malignancy within a mucocele has an excellent prognosis with over 90% survival [4, 5].

A preoperative diagnosis of an appendicular mucocele has a very important role in its management. In the literature, authors described clinical and radiological indicators to distinguish between pathologies such as appendicitis and appendicular mucocele. These include increased luminal diameter of appendix on radiological imaging, presence of microscopic haematuria, and white blood cell count.

If a mucocele is suspected, a more extensive surgical approach may be required to reduce the risk of complications and achieve better oncological outcome [4, 5].

Pseudomyxoma peritonei can occur due to rupture or invasion of the mucocele when there is a delay in intervention. This is a result of mucus containing epithelial cells leaking into the peritoneal cavity and then proliferating and producing large quantities of mucus [6].

## 2. Case Presentation

An 81-year-old man presented acutely to our general surgical department with a 5-day history of right iliac fossa pain. The pain was gradual in onset, worsening, and left him unable to walk. He also complained of diarrhoea and loss of appetite, but no nausea, vomiting, or weight loss.

On examination, he was haemodynamically stable and had a tender, palpable mass in the right iliac fossa. His inflammatory markers were raised.

Few months prior to this admission, he was referred to the colorectal clinic under the 2-week referral guideline (for suspected cancer) complaining of change in his bowel habit for over 6 weeks. Considering his age, he had a CT colonogram, which had shown a well-circumscribed ovoid soft tissue mass in the small bowel mesentery at the ileocaecal junction (Figure 1). It was predominantly homogenous with soft tissue attenuation similar to muscle. There was no significant fat stranding, desmoplastic change, fibrosis, or features to suggest neoplastic change.

The case was discussed in the local lower gastrointestinal multidisciplinary meeting. The patient's performance status

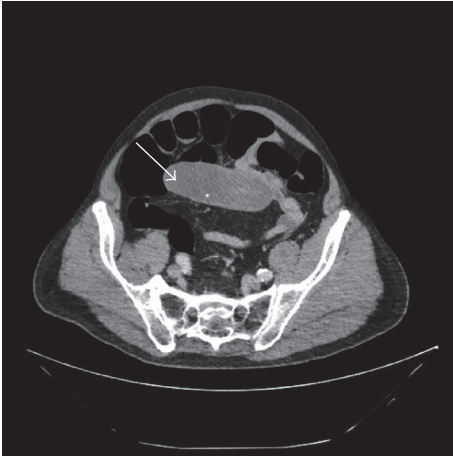


FIGURE 1: Initial CT colonogram showing a well-circumscribed ovoid soft tissue mass in the small bowel mesentery.

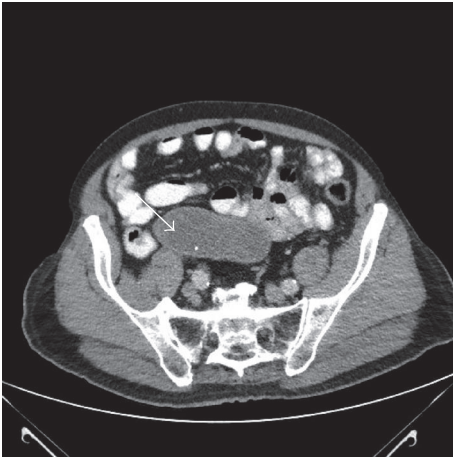


FIGURE 2: Follow-up CT abdomen pelvis showing a dilated tubular structure arising from the medial aspect of the caecum with unchanged features suggestive of a benign appendicular mucocele and no other intra-abdominal pathology.

was poor and his symptoms had settled spontaneously. As the CT did not have sinister features, no invasive surgical intervention was advised at the time. A repeat CT was recommended in 6-month time which still showed a dilated tubular structure arising from the medial aspect of the caecum with unchanged features. The suspicion of an appendicular mucocele (Figure 2) was raised. However, as the patient was still asymptomatic with a poor performance status and no neoplastic features were identified on the scan, the decision not to perform surgery was maintained.

### 3. Investigations

During his acute admission, however, a repeat CT scan of the abdomen showed a change in the morphology of the tubular cystic structure which was now vertical to transvers axis

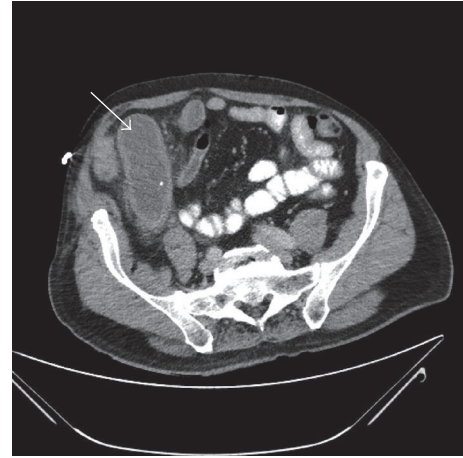


FIGURE 3: CT abdomen pelvis on admission showed a change in the morphology of the tubular cystic structure which was now vertical to transvers axis orientated with thickened walls and fat stranding suggestive of torsion or inflammation of the mucocele.

orientated with thickened walls and fat stranding suggestive of torsion or inflammation of the mucocele (Figure 3).

### 4. Treatment

The patient underwent a laparotomy, which revealed a large fibrotic intraperitoneal mass arising from the appendix and adherent to loops of small bowel. Adhesions to the small bowel were dissected and the mass/appendix was removed by dividing the caecal pole by a linear cutting stapler with a clear margin from the thickened appendicular base.

### 5. Outcome and Follow-Up

The patient had an uneventful postoperative recovery and was discharged home 5 days later.

The specimen was sent for histopathological examination. Grossly, the appendix was cystic and dilated and had a thick wall, resembling an egg. Slicing revealed that the lumen was filled with copious viscid mucus (Figure 4). The microscopic examination (Figure 5) showed that the appendiceal mucosa was almost entirely replaced by intestinal type epithelium with low-grade dysplasia. Purulent exudate of acute inflammation was noted. The background showed chronic inflammation and fibrotic replacement of the muscularis mucosa.

Focally, displaced epithelium was identified within the fibrotic wall. However, the pathologists felt that this was likely to represent a diverticular protrusion rather than a focus of invasion as there was no desmoplastic stroma. The features were consistent with a mucinous cystadenoma.

The patient had a follow-up CT scan 3 months post-operatively which showed no evidence of recurrence or pseudomyxoma peritonei.

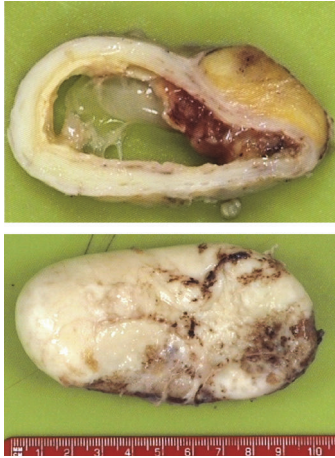


FIGURE 4: Gross appearance of the mucocoele.

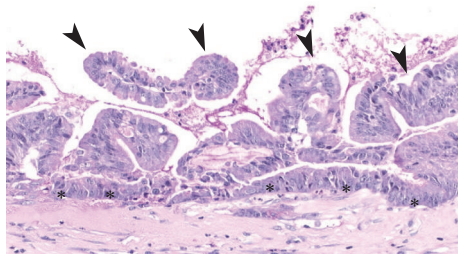


FIGURE 5: Microscopic changes: replacement of the normal appendiceal mucosa with a villiform mucinous epithelial proliferation (arrow heads): crowded columnar cells with basal with elongated, hyperchromatic nuclei (asterisks).

## 6. Discussion

Appendiceal mucinous neoplasms represent a relatively homogeneous group of neoplasms that pursue a predictable clinical course based on tumour stage and grade [7, 8]. The World Health Organization regards any neoplastic epithelial proliferation confined to the appendiceal mucosa as an adenoma. Appendiceal mucinous tumours with extra-appendiceal neoplastic epithelium are classified as mucinous adenocarcinomas and subcategorized as low or high-grade because increasingly severe cytoarchitectural atypia is associated with poorer outcome [7].

Delay in intervention may lead to rupture or invasion of the mucocoele causing complications such as pseudomyxoma peritonei. 5- and 10-year survival rates are predicted at 50% and 10–30%, respectively [6].

The presentation of mucocoeles can vary from being an incidental finding at surgery (in 50%) or radiology to having clinical features such as abdominal pain, abdominal mass, nausea, vomiting, and acute appendicitis [1].

Imaging findings described on plain abdominal radiographs in the literature are curvilinear right iliac fossa calcifications and mass effect on nearby structures [9].

On barium enema studies, displacement of the mesenteric side of the caecum by the appendix [10] and nonfilling of the appendix [11] are frequently found radiological features [12].

On ultrasound an appendiceal mucocoele is seen as a cystic mass with a layered wall and an anechoic or hyperechoic area within the mass [13]. The “onion skin sign” first reported by Caspi et al. [14] describes a cystic mass surrounded by concentric echogenic layers and is now considered to be pathognomonic of an appendiceal mucocoele.

CT appearances preoperatively usually show a round, cystic tubular mass in the location of the appendix [15]. Mucocoeles are well-encapsulated with a smooth wall of variable thickness [9]. CT colonography can reveal abnormalities in the expected position of the appendiceal orifice such as an intraluminal smooth lesion or caecal contour abnormality [9].

Magnetic resonance imaging is useful for differentiating between intraperitoneal and retroperitoneal structures from large mucinous neoplasms [9]. T2 weighted pulse sequences usually show a hyperintense area within the tumour whereas T1 images are usually dependent on the mucin concentration with the signal usually being hypointense or isointense [16]. CT is more sensitive at detecting mural calcifications which is more sensitive in the diagnosis of mucinous neoplasms [16].

In an analysis of CT scans of 70 patients, the most sensitive radiological findings to suggest appendicitis with mucocoele were an appendiceal lumen diameter over 13 mm and cystic dilatation and mural calcification [17]. However, differentiating between benign and neoplastic mucocoeles preoperatively is more difficult. A limited study by Wang et al. in 2013 suggested that irregularity and soft tissue thickening can suggest a preoperative diagnosis of appendiceal mucocoele but the study excluded patients presenting with appendicitis, ruling out a large proportion of cases [15].

Definite diagnosis is only achievable through histopathological examination of the specimen. Therefore, as the method of choice, surgical resection should be considered in cases suspected of appendicular mucocoele. Depending on pathology of the mucocoele, follow-up and surveillance are likely to be necessary.

## Conflicts of Interest

The authors declare that there are no conflicts of interest regarding the publication of this paper.

## References

- [1] A. Dixit, J. H. P. Robertson, S. S. Mudan, and C. Akle, “Appendiceal mucocoeles and pseudomyxoma peritonei,” *World Journal of Gastroenterology*, vol. 13, no. 16, pp. 2381–2384, 2007.
- [2] S. J. Connor, G. B. Hanna, and F. A. Frizelle, “Appendiceal tumors: retrospective clinicopathologic analysis of appendiceal tumors from 7,970 appendectomies,” *Diseases of the Colon and Rectum*, vol. 41, no. 1, pp. 75–80, 1998.
- [3] S. S. Nitecki, B. G. Wolff, R. Schlinkert, and M. G. Sarr, “The natural history of surgically treated primary adenocarcinoma of the appendix,” *Annals of Surgery*, vol. 219, no. 1, pp. 51–57, 1994.

- [4] E. Kalu and C. Croucher, "Appendiceal mucocele: a rare differential diagnosis of a cystic right adnexal mass," *Archives of Gynecology and Obstetrics*, vol. 271, no. 1, pp. 86–88, 2005.
- [5] V. Attarde, P. Patil, A. Apte et al., "Sonographic appearance of a giant appendicular mucocele," *Journal of Clinical Ultrasound*, vol. 39, no. 5, pp. 290–292, 2011.
- [6] K. E. Bevan, F. Mohamed, and B. J. Moran, "Pseudomyxoma peritonei," *World Journal of Gastrointestinal Oncology*, vol. 2, no. 1, pp. 44–50, 2010.
- [7] N. C. Panarelli and R. K. Yantiss, "Mucinous neoplasms of the appendix and peritoneum," *Archives of Pathology & Laboratory Medicine*, vol. 135, no. 10, pp. 1261–1268, 2011.
- [8] J. Misdraji, "Appendiceal mucinous neoplasms: controversial issues," *Archives of Pathology and Laboratory Medicine*, vol. 134, no. 6, pp. 864–870, 2010.
- [9] S. H. Tirumani, M. Fraser-Hill, R. Auer et al., "Mucinous neoplasms of the appendix: a current comprehensive clinicopathologic and imaging review," *Cancer Imaging*, vol. 13, no. 1, pp. 14–25, 2013.
- [10] Y. Yoshida, K. Sato, T. Tada et al., "Two cases of mucinous cystadenoma of the appendix successfully treated by laparoscopy," *Case Reports in Gastroenterology*, vol. 7, no. 1, pp. 44–48, 2013.
- [11] D. J. Miller and J. Skucas, *Examination of the Colon: Practical Diagnosis*, Springer Science & Business Media, 2012.
- [12] R. M. Gore and M. S. Levine, *Textbook of Gastrointestinal Radiology E-Book*, Elsevier Health Sciences, Philadelphia, Pennsylvania, PA, USA, 2015.
- [13] S. H. Kim, H. K. Lim, W. J. Lee, J. H. Lim, and J. Y. Byun, "Mucocele of the appendix: ultrasonographic and CT findings," *Abdominal Imaging*, vol. 23, no. 3, pp. 292–296, 1998.
- [14] B. Caspi, E. Cassif, R. Auslender, A. Herman, Z. Hagay, and Z. Appelman, "The onion skin sign: a specific sonographic marker of appendiceal mucocele," *Journal of Ultrasound in Medicine*, vol. 23, no. 1, pp. 117–122, 2004.
- [15] H. Wang, Y.-Q. Chen, R. Wei et al., "Appendiceal mucocele: a diagnostic dilemma in differentiating malignant from benign lesions with CT," *American Journal of Roentgenology*, vol. 201, no. 4, pp. W590–W595, 2013.
- [16] I. Honnef, M. Moschopoulos, and T. Roeren, "Appendiceal mucinous cystadenoma," *RadioGraphics*, vol. 28, no. 5, pp. 1524–1527, 2008.
- [17] G. L. Bennett, T. P. Tanpitukpongse, M. Macari, K. C. Cho, and J. S. Babb, "CT diagnosis of mucocele of the appendix in patients with acute appendicitis," *American Journal of Roentgenology*, vol. 192, no. 3, pp. W103–W110, 2009.