



# Tracheobronchopathia osteochondroplastica concurrent with peripheral lung cancer: a case report and perioperative considerations

Yong Feng<sup>1</sup>, Linlin Wang<sup>1</sup>, Renxiang Jia<sup>1</sup>, Xiangchao Zhang<sup>2</sup>, Xiaohan Wang<sup>3</sup>, Yana Yuan<sup>4</sup>, Hong Yang<sup>4</sup>, Liwei Xie<sup>5</sup>, Na Li<sup>6</sup>, Xiaoge Wang<sup>7</sup>, Benoit Jacques Bibas<sup>8</sup>, Hojoong Kim<sup>9</sup>, Johannes Schweipert<sup>10</sup>, Yi Ren<sup>1</sup>

<sup>1</sup>Department of Thoracic Surgery, Shenyang Chest Hospital and Tenth People's Hospital, Shenyang, China; <sup>2</sup>Department of Anesthesiology, Shenyang Chest Hospital and Tenth People's Hospital, Shenyang, China; <sup>3</sup>Department of Endoscopic Therapy Center, Shenyang Chest Hospital and Tenth People's Hospital, Shenyang, China; <sup>4</sup>Department of Pathology, Shenyang Chest Hospital and Tenth People's Hospital, Shenyang, China; <sup>5</sup>Department of Radiology, Shenyang Chest Hospital and Tenth People's Hospital, Shenyang, China; <sup>6</sup>Department of Pharmacy, Shenyang Chest Hospital and Tenth People's Hospital, Shenyang, China; <sup>7</sup>Department of Respiratory Medicine, Shenyang Chest Hospital and Tenth People's Hospital, Shenyang, China; <sup>8</sup>Hospital Municipal Vila Santa Catarina Dr. Gilson de Cássia Marques de Carvalho, Hospital Israelita Albert Einstein, São Paulo, Brazil; <sup>9</sup>Division of Pulmonary and Critical Care Medicine, Department of Medicine, Samsung Medical Center, Sungkyunkwan University School of Medicine, Seoul, Republic of Korea; <sup>10</sup>Division of Thoracic Surgery, Department of Visceral, Thoracic and Vascular Surgery, Faculty of Medicine and University Hospital Carl Gustav Carus, Technische Universität Dresden, Dresden, Germany

**Contributions:** (I) Conception and design: Y Feng, L Wang, R Jia; (II) Administrative support: X Zhang, Xiaohan Wang, Xiaoge Wang, Y Feng; (III) Provision of study materials or patients: Y Feng, H Yang, L Xie, N Li; (IV) Collection and assembly of data: Y Yuan, L Xie, R Jia; (V) Data analysis and interpretation: Y Feng, X Zhang, Y Ren; (VI) Manuscript writing: All authors; (VII) Final approval of manuscript: All authors.

**Correspondence to:** Yi Ren, MD. Department of Thoracic Surgery, Shenyang Chest Hospital and Tenth People's Hospital, No. 11 Beihai Street, Dadong District, Shenyang 110044, China. Email: yi498857876@163.com.

**Background:** Tracheobronchopathia osteochondroplastica (TPO) is a rare, benign, chronic disorder of unknown etiology. It is characterized by submucosal nodules, often calcified, which predominantly affect the anterolateral aspects of the trachea and main bronchi, while sparing the posterior bronchial wall. The co-occurrence of TPO and lung cancer is exceedingly rare. This report presents a case of TPO association with early-stage lung cancer, which was managed through surgical intervention. No active treatment was undertaken for the TPO.

**Case Description:** A patient presented with a nodule in the right upper lobe, which was identified during a computed tomography (CT) scan of the chest, suggestive of early-stage lung cancer. Concurrently, multiple calcifications in the cartilaginous rings of the trachea were noted. Bronchoscopy revealed distinctive “pebblestone” nodules along the anterior and lateral tracheal walls, indicative of extensive TPO. The patient underwent bronchofiberscopy, which showed patency in the bronchial lumen of the right lung's upper lobe. A biopsy was not undertaken during this procedure. Comprehensive preoperative tests, including a blood biochemical examination, tumor-marker tests, lung-function tests, head-enhanced magnetic resonance imaging, abdominal ultrasound, and whole-body bone emission CT revealed no significant abnormalities. Despite this, the patient declined a whole-body positron emission tomography (PET)-CT scan. Given the potential malignancy of nodules in the right lung's upper lobe, the lobectomy for lung cancer was carried out, a procedure that would have proceeded irrespective of the presence or absence of TPO. Preoperative planning for potential tracheal intubation difficulties involved consultation with the anesthesiologist, resulting in a smooth intraoperative process. The pathology confirmed invasive adenocarcinoma. Post-surgery, the patient developed an infection in the right lung's lower lobe, identified as *Pseudomonas aeruginosa* and *Klebsiella pneumoniae* through sputum culture and bronchoscopic lavage. Treatment with meropenem for 2 weeks, as guided by drug sensitivity results and respiratory advice, led to an improvement, allowing for discharge. A follow-up lung CT four months post-operation showed inflammation absorption in the right lower lobe.

**Conclusions:** Surgical resection in cases of TPO association with lung cancer may have an increased risk of postoperative pulmonary infection. Proactive intraoperative sputum aspiration by anesthesiologists and the postoperative reinforcement of anti-infection measures, guided by drug sensitivity results, are recommended.

**Keywords:** Tracheobronchopathia osteochondroplastica (TPO); peripheral lung cancer; bronchoscopy; case report

Submitted Mar 13, 2024. Accepted for publication Apr 19, 2024. Published online Apr 25, 2024.

doi: 10.21037/tcr-24-410

View this article at: <https://dx.doi.org/10.21037/tcr-24-410>

## Introduction

Tracheobronchopathia osteochondroplastica (TPO) is an infrequent, benign condition characterized by cartilaginous or bony submucosal hyperplasia protruding into the tracheal lumen, occasionally extending along the bronchial

tree. This disease predominantly affects the anterolateral wall of the trachea (1). The incidence varies based on the study population and symptomatology, with reported prevalence rates ranging from 0.01% to 0.80% (2). A more recent study suggests a prevalence rate of 0.09% (3). Due to current gaps in understanding the etiology and pathogenesis of TPO, standardized diagnostic and treatment guidelines have not yet been established.

The association between TPO and lung cancer is less explored in medical research. This report details the treatment of a patient with early-stage lung cancer and concurrent TPO, who underwent thoracoscopic right upper lobectomy. No active intervention was undertaken for the TPO. The aim of this case report is to elucidate the critical clinical, radiological, and histopathological aspects of tracheobronchial osteochondral hyperplasia, with a particular focus on the perioperative considerations necessary for lobectomy in the context of pulmonary malignancy. This report seeks to augment the clinical understanding of TPO, thereby aiding in the management of similar future cases. We present this article in accordance with the CARE reporting checklist (available at <https://tcr.amegroups.com/article/view/10.21037/tcr-24-410/rc>).

### Highlight box

#### Key findings

- This report details a severe case of intrapulmonary infection following a thoracoscopic lobectomy for a tracheobronchopathia osteochondroplastica (TPO) patient with concurrent peripheral lung cancer. The patient's condition improved with an anti-infection treatment tailored according to drug sensitivity results.

#### What is known, and what is new?

- TPO, a benign, rare, and chronic disease with an unknown etiology, is occasionally identified incidentally during challenging tracheal intubation procedures. Currently, there is no established consensus on the treatment strategy for TPO, reflecting the need for further research and clinical guidelines in this area.
- Lobectomies for TPO association with lung cancer are not commonly reported. Effective communication with the anesthesiologist prior to surgery is crucial to enable collaborative surgical planning. There is an increased likelihood of postoperative pulmonary infection complications. Post-surgery, it is essential to intensify expectoration and anti-infection treatments, tailored according to sputum culture and drug sensitivity results.

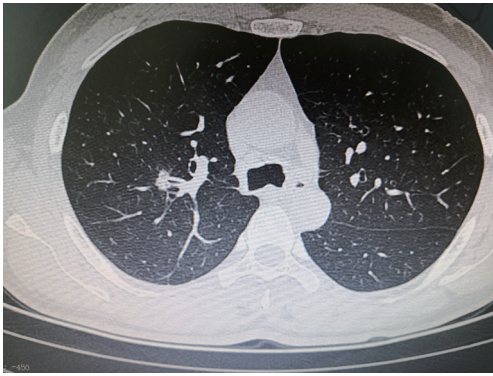
#### What is the implication, and what should change now?

- Performing a lobectomy for TPO association with lung tumors can present challenges (e.g., difficulties related to tracheal intubation during anesthesia). Preoperative planning to address potential difficulties with tracheal intubation, including consultation with an anesthesiologist, is crucial. The lobectomy was carried out for lung cancer, a procedure that would have proceeded regardless of the presence or absence of TPO. However, this may heighten the risk of postoperative pulmonary infection. Thus, heightened vigilance by clinicians, and careful monitoring and management during and after the procedure are required.

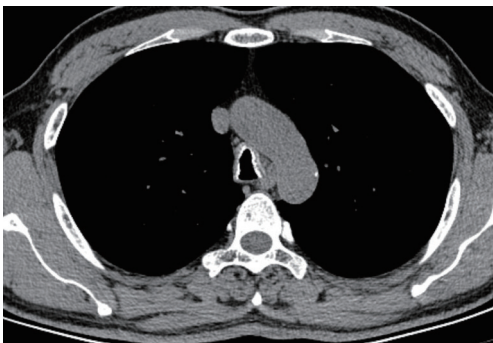
## Case presentation

### Patient information

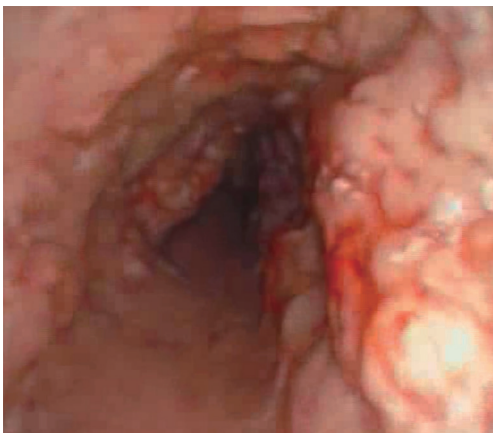
A 51-year-old male patient presented to the Department of Thoracic Surgery at Shenyang Chest Hospital and Tenth People's Hospital following an incidental finding on a computed tomography (CT) scan of the right upper lung lobe, performed one week prior. The patient had a significant occupational history of over 20 years of dust exposure. Clinically, he reported chronic expectoration of yellow and white sputum in substantial quantities, but



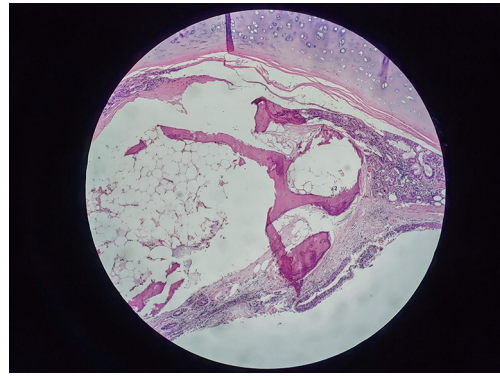
**Figure 1** The nodules located in the upper lobe of the right lung, approximately 15 mm by 12 mm in size, exhibited characteristics such as lobulation, spiculation (resembling burrs), and air bronchogram signs. These features are important in radiographic imaging for assessing the nature of the nodules.



**Figure 2** Calcified nodules were observed on the anterior lateral wall of the trachea.



**Figure 3** Fiberoptic bronchoscopy revealed firm, nodular protrusions on the anterior and lateral walls of the trachea, notably leaving the posterior bronchial wall unaffected.



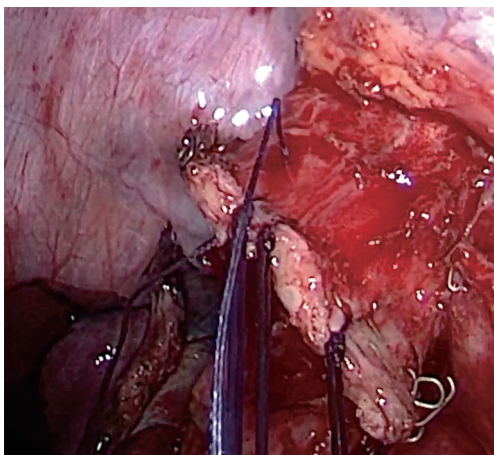
**Figure 4** The histopathological examination of the bronchus's incision margin from the upper lobe of the right lung (hematoxylin eosin stain, magnification  $\times 200$ ) revealed ossification in the bronchial wall. Additionally, there was evidence of calcium salt deposition and the formation of pulp cavities.

denied experiencing cough, chest pain, chest tightness, or dyspnea. He had no personal or family history of cancer. This was the patient's first lung CT examination. The most prominent clinical feature was the production of yellow and white sputum. On physical examination, the patient exhibited clubbing of the fingers, but no other significant symptoms were noted. All the procedures in this study were performed in accordance with the ethical standards of the institutional and/or national research committee(s) and with the Helsinki Declaration (as revised in 2013). Written informed consent was obtained from the patient for the publication of this case report and accompanying images. A copy of the written consent is available for review by the editorial office of this journal.

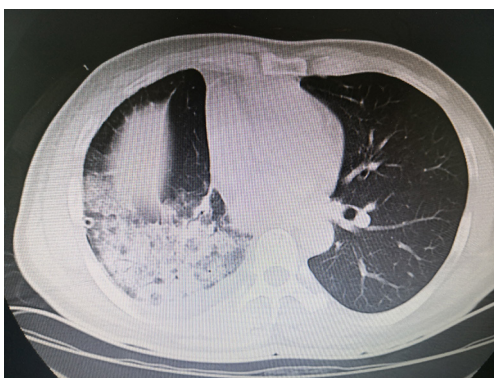
#### *Diagnostic assessment*

Chest CT imaging revealed a 15 mm by 12 mm nodule in the right upper lung lobe. The nodule exhibited lobulation, spiculation, and the presence of an air bronchogram, suggestive of significant peripheral lung cancer (*Figure 1*). Additionally, moderate hyperplasia of the airway wall with multiple calcifications was observed (*Figure 2*). Fiberoptic bronchoscopy demonstrated hard, prominent nodules along the anterolateral mucosa extending from the carina to the left and right main bronchi, evocative of "pebbles", while sparing the posterior bronchial wall (*Figure 3*). Postoperative bronchial margin pathology ossification was observed in the bronchial wall, calcium salt deposition and pulp cavity formation were also observed (*Figure 4*).





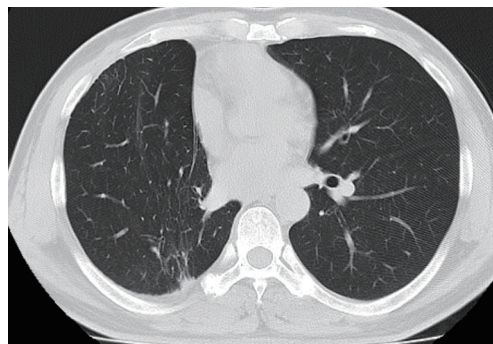
**Figure 5** In the stump bronchus of the right lung's upper lobe, scattered calcified nodules were observed. These nodules were reinforced through intermittent suturing during the operation.



**Figure 6** One week following the resection of the right lung's lower lobe, local consolidation was observed in the same area. Within this consolidated region, an air bronchogram was visible. This finding is significant in the postoperative assessment of lung pathology.

### ***Therapeutic intervention***

The patient underwent a uniportal thoracoscopic radical resection of the right upper lobe for lung cancer, with no active intervention performed for TPO. Given the added complexities presented by TPO, meticulous airway management was paramount. The anesthesiology team opted for a size 35 double-lumen endotracheal tube, thoroughly lubricated with paraffin oil. Intubation, facilitated by a video laryngoscope, was successful, with a subsequent airway examination confirming its cleanliness and the absence of bleeding. Intraoperatively, the resection



**Figure 7** Four months post-surgery, a follow-up examination revealed the resolution of inflammation in the lower lobe of the right lung. This indicates a positive response to the treatment and healing process after the surgical intervention.

of the upper lobe revealed invasive adenocarcinoma, and the mediastinal lymph node dissection was performed. Additionally, scattered calcified nodules were observed at the bronchial stump. To mitigate the risk of a postoperative fistula, the stump was reinforced with sutures (*Figure 5*). At the conclusion of the procedure, the anesthesiologist performed a tracheoscopy and aspirated a minor amount of blood. The patient was extubated gradually upon regaining consciousness.

Postoperatively, the patient developed pneumonia in the right lower lobe (*Figure 6*). Cultures from sputum and bronchoscopic lavage [next-generation sequencing (NGS)] identified *Pseudomonas aeruginosa* and *Klebsiella pneumoniae*. The patient was treated with meropenem for 2 weeks, guided by drug sensitivity results and respiratory consultation. This treatment led to a significant improvement, and the patient was subsequently discharged. At a four-month postoperative follow-up visit, a repeat lung CT indicated resolution of the inflammation in the right lower lobe (*Figure 7*).

### **International Multidisciplinary Team (iMDT) discussion**

#### ***Discussion from Department of Thoracic Surgery, Shenyang Chest Hospital and Tenth People's Hospital***

TPO is a rare, benign condition characterized by the proliferation of cartilaginous or bony submucosal hyperplasia projecting into the tracheal lumen, with rare extensions along the bronchial tree. TPO predominantly affects the anterolateral wall (1). The incidence of TPO

has been reported to vary from 0.01% to 0.80% (2), with a recent study indicating a prevalence of approximately 0.09% (3). The lack of any comprehensive understanding of the etiology and pathogenesis of TPO has led to the absence of standardized diagnostic and treatment protocols. Diagnosis primarily relies on chest CT, bronchoscopy, and histopathological examination (4).

Chest CT typically reveals irregular thickening of the tracheal and bronchial walls, calcification, and small calcified nodules protruding into the lumen. Bronchoscopic examination often demonstrates multiple, hard, pebble-like nodules of varying sizes, primarily located on the anterolateral wall of the trachea and bronchi, sparing the membranous portions. The histopathological interpretation of TPO remains a topic of debate.

While some authors suggest that typical bronchoscopic findings are sufficient for diagnosis (2,5), others emphasize the need to exclude differential diagnoses like tracheal amyloidosis, polychondritis, or papillomatosis (4,6). Devaraja and Surendra (7) observed considerable variability in the pathological features of TPO across different cases. While some cases exhibited only the typical respiratory epithelium without additional abnormalities, the most characteristic feature of TPO includes squamous metaplasia along with calcified cartilage or new bone formation (calcification/ossification) in the submucosal or interstitial plane. Nair *et al.* (3) noted that in 38% of TPO cases, bronchoscopic biopsies revealed coexisting conditions, such as metastatic malignancies, tuberculosis, or nocardiosis, which affect treatment decisions. Thus, if feasible, a bronchoscopic biopsy of TPO lesions is advisable to exclude other pathologies. Our patient underwent bronchofiberscopy, which revealed distinctive “pebblestone” nodules along the anterior and lateral tracheal walls, indicative of extensive TPO. Due to the potential malignancy of nodules in the upper lobe of the right lung, a lobectomy for lung cancer was performed, a procedure that would have been necessary regardless of the presence or absence of TPO. No biopsy was conducted during this procedure.

Liu *et al.* (8) highlighted the diagnostic challenges in clinical practice, noting that radiologists often overlook TPO and that only 30.3% of chest CTs in their study cohort suggested a diagnosis of TPO. This oversight is partly attributed to a focus on pulmonary parenchyma, leading to missed tracheobronchial lesions, and partly to the subtlety of TPO manifestations, which results in these small and sparse nodules being easily overlooked

in CT scans. Nonetheless, pulmonary CT remains the most reliable imaging modality for TPO diagnosis and is crucial for patient follow-up. CT is particularly important in differentiating TPO from conditions with similar bronchoscopic presentations, such as recurrent respiratory papillomatosis (9).

Thoracoscopic lobectomy in patients with peripheral lung cancer association with TPO is uncommon, with few reported cases in literature. Our case appears to represent an incidental association between these conditions, suggesting probable etiopathological relationships that warrant further investigation. As a benign condition, TPO generally has a favorable prognosis in uncomplicated cases (10). The majority of patients with TPO received only symptomatic treatment (7,11). However, the presence of lung cancer in patients with TPO poses unique challenges, particularly during anesthesia and the postoperative period. Previous cases have documented the incidental discovery of TPO during difficult intubations (12) and instances of oral intubation failure necessitating emergency tracheotomy (13). In this case, potential intubation challenges were anticipated and meticulously planned for in collaboration with the anesthesiology team. A size 35 double-lumen endotracheal tube, generously lubricated with paraffin oil, was used. After the muscle relaxants took effect, intubation under video laryngoscopy encountered slight resistance but was ultimately successful. Bronchoscopy post-intubation revealed a clear, unblemished airway. During the procedure, the right upper lung lobe was excised, and the bronchial stump was carefully sutured and reinforced to prevent postoperative bronchopleural fistula formation. At the operation's conclusion, visual fiber bronchoscopy was employed to remove a small amount of blood from the airway. Tracheal intubation was gradually withdrawn once the patient regained consciousness. Throughout the procedure, special care was taken to minimize trauma to the tracheal mucosa and ensure the timely aspiration of airway secretions.

Despite meticulous surgical techniques, the patient developed right lower lobe pneumonia postoperatively. Heo *et al.* explained that TPO may impair the efficiency of clearing respiratory secretions, potentially leading to lower respiratory infections. They also noted that TPO is commonly associated with other disorders and lung diseases, including lung malignancy (14).

Similar pathogens were found in the in culture and bronchoscopic lavage fluid (by NGS) of our patient, who had a long history of occupational dust exposure,

to those reported by Grillo and Wright (15), who found that *Pseudomonas aeruginosa* and other microorganisms like *Klebsiella pneumoniae* were prevalent in the sputum. Treatment with meropenem for 2 weeks, guided by drug sensitivity tests and respiratory consultation, led to a significant improvement. Follow-up pulmonary CT four months post-surgery showed resolution of inflammation in the right lower lobe. These findings align with those reported by Chaurasia *et al.* (16), and further emphasize the importance of bronchoscopic lavage in identifying pathogenic microorganisms for targeted anti-infection therapy in TPO patients.

*Several questions arise concerning the diagnosis and treatment of this patient*

**Question 1. A pulmonary CT scan revealed nodules in the upper lobe of the patient's right lung. Given the high clinical suspicion of malignancy, the patient refused a preoperative whole-body PET-CT scan without a pathological diagnosis. Instead, the patient underwent thoracoscopic resection of the right lung's upper lobe as treatment. To minimize or avoid unnecessary pulmonary lobectomy for benign nodules, what additional pre-surgical tests should be considered?**

**Expert opinion 1: Dr. Benoit Jacques Bibas**

In this case, the patient had a 15 mm central lung nodule that had lobulation, spiculation and air bronchogram sign, which was highly suspicious for a primary lung cancer. Due to the central location of the lesion, navigational bronchoscopy and biopsy with robotic bronchoscopy could serve as diagnostic tools. This could avoid unnecessary resections for benign diseases. Other option would be to perform a CT-guided biopsy of the nodule, even though the nodule is centrally located and very close to the pulmonary vessels. Due to the location of the lesion, feasibility of the procedure would have to be discussed with interventional radiology.

**Expert opinion 2: Dr. Hojoong Kim**

PET-CT is the best method to expect lung cancer, however, bacterial culture using bronchial washing fluid would be a good substitute when patient refuses the PET-CT scan.

**Expert opinion 3: Dr. Johannes Schweipert**

(I) For what reason did the patient refuse PET-CT but gave consent for surgery? Especially in this case with an operational risk factor, it would have been a

good additional decision-making aid. In the case of metastatic disease, unnecessary surgery would have been avoided.

(II) Was there an attempt to get a bronchoscopic biopsy? In *Figure 1*, the tumor seems to be quite close to the B2 (as far as I can see on just one slide) and accessible for bronchoscopy. Or was the TPO also present in the segmental bronchus?

For selected cases we even repeat the procedure if the result isn't conclusive. However, if two samples provide no representative tissue we would also suggest the operation.

(III) I would have considered beginning with an anatomic segmentectomy and performing the lobectomy just in case of malignancy even though this means more expense in time and material.

**Question 2. In typical cases of TPO, an experienced doctor can identify the hyperplastic cartilaginous tissue in the trachea and bronchial mucosa. This tissue is often hard in texture and prone to bleeding during sampling. Such bleeding can complicate the sampling process and potentially harm the patient. Given these risks, is it still essential to obtain a pathological sample through bronchoscopy?**

**Expert opinion 1: Dr. Benoit Jacques Bibas**

Traditional bronchoscopy methods would have a very low yield rate and would not be a good option. Navigational procedures and robotic bronchoscopy could be performed, depending on the availability of the methods. CT-guided biopsy also has a high risk of bleeding and pneumothorax (nodule close to the pulmonary vessels and deep into the parenchyma).

Due to the peculiarities of this case, and the high probability of a malignant nodule, I would consider an anatomical lung resection without pathological sample.

**Expert opinion 2: Dr. Hojoong Kim**

Sometimes tracheobronchial amyloidosis, tuberculosis and aspergillosis would resemble TPO grossly. To excluded other diagnosis, bronchial biopsy is necessary. However, if the surface of the lesion is stony hard, the diagnosis of TPO is very probable and further biopsy procedure is not necessary.

**Expert opinion 3: Dr. Johannes Schweipert**

I agree with most authors that there is no need for a biopsy. The typical CT and bronchoscopic findings are sufficient to make the diagnosis.

**Question 3. Lobectomy in patients with TPO and lung tumors may present challenges with tracheal intubation during anesthesia. Could a lobectomy performed without tracheal intubation reduce or prevent postoperative pulmonary infections in these patients?**

*Expert opinion 1: Dr. Benoit Jacques Bibas*

Anatomical pulmonary resections can be carried out safely without tracheal intubation. There is enough evidence in the literature to ensure that. Studies have shown that indeed it reduces postoperative complications, especially in elderly and frail patients. Personally, I have no experience with this technique. If double lumen intubation could not be performed, my option would be to intubate the patient with a normal orotracheal tube and use an endobronchial blocker.

*Expert opinion 2: Dr. Hojoong Kim*

I don't think so. Postoperative pulmonary infection could be treated by antibiotics, however, bronchopleural fistula (BPF) is the worst complication, thus intubation is essential to provide best environment for operation.

*Expert opinion 3: Dr. Johannes Schweipert*

Despite the fact that non-intubated video-assisted thoracoscopic surgery (VATS) lobectomies are feasible in selected patient I don't think that TPO patients are suitable for this technique. An emergency intubation in lateral decubitus position with a difficult airway must be avoided under any circumstances.

The here proposed procedure for a controlled intubation is plausible.

**Question 4. The patient experienced a pulmonary infection post-surgery, which improved following a 2-week course of meropenem, as guided by drug sensitivity results. Despite the improvement and subsequent discharge, the patient remains concerned about the potential persistence of the pulmonary infection. Are there any recommendations for a more effective drug selection and treatment duration in such cases?**

*Expert opinion 1: Dr. Benoit Jacques Bibas*

TPO is usually asymptomatic. It is estimated that only 51% of cases will develop symptoms. Common symptoms include shortness of breath, persistent coughing, frequent heavy mucus production, and sometimes coughing up blood. Pulmonary function tests usually don't reveal any issues with airflow. Only a few patients experience issues with air passage, typically due to blocked airways.

Moreover, it's been found that severe respiratory infections can be fatal for some individuals. Fiberoptic bronchoscopy exams demonstrated that *Klebsiella* species and *Pseudomonas aeruginosa* are the most common microorganisms involved (17). There isn't a consensus on how to treat TPO because completely removing the nodules isn't feasible. Treatment varies based on the symptoms of the disease, whether there's an infection, and how severe the airway blockage or deformation is. Most patients will be treated directed to other respiratory conditions, such as infection, chronic obstructive pulmonary disease, bronchiectasis, or asthma. These consisted of inhaled corticosteroids, systemic corticosteroids, antibiotics, bronchodilators and respiratory physical therapy (8).

*Expert opinion 2: Dr. Hojoong Kim*

Meropenem is the good choice for TPO patient. However, if drug sensitivity test shows resistance, meticulous selection of antibiotics is needed. Long-term use of antibiotics would be unnecessary unless immunocompromised host.

*Expert opinion 3: Dr. Johannes Schweipert*

Since we are formally dealing with a nosocomial infection, the choice of meropenem, also as a calculated therapy, seems rational. In this case the therapy was carried out according to the resistogram.

It is not quite clear at what point in time the bacteria were identified. I assume the bronchoscopic lavage was only performed postoperatively.

Perhaps we should routinely collect sputum and lavage cultures in TPO patients preoperatively and treat any colonization appropriately to avoid postoperative pneumonia.

The patient's future risk of further lung infections is unlikely to be higher than before the operation. Conservative measures, mucolysis and, if necessary, the recommendation of regular respiratory physiotherapy should be sufficient.

## Conclusions

Surgical interventions for lung cancer in TPO patients require meticulous preoperative anesthetic planning, careful intraoperative management, and postoperative vigilance to prevent bronchial stump fistula and manage lung infections effectively. The identification of pathogens, guided by drug sensitivity results, is crucial for appropriate and effective treatment. We hope that presenting this case will enhance clinicians' awareness and understanding of the disease and its management complexities.



## Acknowledgments

*Funding:* None.

## Footnote

*Reporting Checklist:* The authors have completed the CARE reporting checklist. Available at <https://tcr.amegroups.com/article/view/10.21037/tcr-24-410/rc>

*Peer Review File:* Available at <https://tcr.amegroups.com/article/view/10.21037/tcr-24-410/prf>

*Conflicts of Interest:* All authors have completed the ICMJE uniform disclosure form (available at <https://tcr.amegroups.com/article/view/10.21037/tcr-24-410/coif>). B.J.B. serves as an unpaid editorial board member of *Translational Cancer Research* from October 2022 to September 2024. The other authors have no conflicts of interest to declare.

*Ethical Statement:* The authors are accountable for all aspects of the work in ensuring that questions related to the accuracy or integrity of any part of the work are appropriately investigated and resolved. All the procedures in this study were performed in accordance with the ethical standards of the institutional and/or national research committee(s) and with the Helsinki Declaration (as revised in 2013). Written informed consent was obtained from the patient for the publication of this case report and accompanying images. A copy of the written consent is available for review by the editorial office of this journal.

*Open Access Statement:* This is an Open Access article distributed in accordance with the Creative Commons Attribution-NonCommercial-NoDerivs 4.0 International License (CC BY-NC-ND 4.0), which permits the non-commercial replication and distribution of the article with the strict proviso that no changes or edits are made and the original work is properly cited (including links to both the formal publication through the relevant DOI and the license). See: <https://creativecommons.org/licenses/by-nc-nd/4.0/>.

## References

- Prakash UB, McCullough AE, Edell ES, et al. Tracheopathia osteoplastica: familial occurrence. *Mayo Clin Proc* 1989;64:1091-6.
- Dumazet A, Launois C, Lebagry F, et al. Tracheobronchopathia osteochondroplastica: clinical, bronchoscopic, and comorbid features in a case series. *BMC Pulm Med* 2022;22:423.
- Nair AA, Gupta R, Irodi A, et al. Tracheobronchopathia Osteochondroplastica - to Biopsy or not to Biopsy? A Relook at The Rare Disease. *J Bronchology Interv Pulmonol* 2024;31:57-62.
- Zhu Y, Wu N, Huang HD, et al. A clinical study of tracheobronchopathia osteochondroplastica: findings from a large Chinese cohort. *PLoS One* 2014;9:e102068.
- Cho HK, Jeong BH, Kim H. Clinical course of tracheobronchopathia osteochondroplastica. *J Thorac Dis* 2020;12:5571-9.
- Abu-Hijleh M, Lee D, Braman SS. Tracheobronchopathia osteochondroplastica: a rare large airway disorder. *Lung* 2008;186:353-9.
- Devaraja K, Surendra VU. Clinicopathological Features and Management Principles of Tracheobronchopathia Osteochondroplastica - A Scoping Review. *Indian J Otolaryngol Head Neck Surg* 2023;75:3798-814.
- Liu Q, Hu Y, Lei M, et al. Clinical Characteristics of Tracheobronchopathia Osteochondroplastica: A Retrospective Study of 33 Patients. *Int J Gen Med* 2023;16:3447-55.
- Rodriguez NJV, Manto JT, Sydiongeo-Inocencio PMM, et al. Tracheobronchopathia osteochondroplastica: a case report highlighting the importance of clinico-radiologic correlation. *BJR Case Rep* 2023;9:20230062.
- Jabbardarjani HR, Radpey B, Kharabian S, et al. Tracheobronchopathia osteochondroplastica: presentation of ten cases and review of the literature. *Lung* 2008;186:293-7.
- Wagner RB, Barson PK. Tracheobronchopathia osteochondroplastica diagnosed as a result of difficult intubation. *Anesthesiology* 1979;51:269-70.
- Smith DC, Pillai R, Gillbe CE. Tracheopathia osteochondroplastica. A cause of unexpected difficulty in tracheal intubation. *Anaesthesia* 1987;42:536-8.
- Graziani A, Morgagni F, Terzitta M. Bronchoscopy Evaluation Before Tracheal Cannula Removal in a Patient With Tracheobronchopathia Osteochondroplastica. *Arch Bronconeumol* 2023;59:758.
- Heo JW, Lee EG, Gil B, et al. Tracheobronchopathia Osteochondroplastica Associated with Fibrotic Interstitial Lung Disease. *Intern Med* 2021;60:3463-7.
- Grillo HC, Wright CD. Airway obstruction owing to tracheopathia osteoplastica: treatment by linear tracheoplasty. *Ann Thorac Surg* 2005;79:1676-81.



16. Chaurasia S, Ray S, Chowdhury S, et al. Tracheobronchopathia osteochondroplastica: A rare case of misdiagnosis and difficult intubation. *J R Coll Physicians Edinb* 2022;52:54-6.
17. Leske V, Lazor R, Coetmeur D, et al. Tracheobronchopathia osteochondroplastica: a study of 41 patients. *Medicine (Baltimore)* 2001;80:378-90.

**Cite this article as:** Feng Y, Wang L, Jia R, Zhang X, Wang X, Yuan Y, Yang H, Xie L, Li N, Wang X, Bibas BJ, Kim H, Schweipert J, Ren Y. Tracheobronchopathia osteochondroplastica concurrent with peripheral lung cancer: a case report and perioperative considerations. *Transl Cancer Res* 2024;13(4):2064-2072. doi: 10.21037/tcr-24-410